

## IDENTIFYING AND MANAGING PHARMACEUTICAL COMPLICATIONS

JESSICA STEEN OD, FFAO, DIPL ABO



1

## FINANCIAL DISCLOSURES

- Speaker-Carl Zeiss Meditec, Bausch and Lomb, Oyster Point Pharma, Thea Pharma, Alcon, Allergan
- Advisory Board-Bausch and Lomb, Carl Zeiss Meditec, Santen, Peripherex, Ocuphire, Ocuterra, Oyster Point Pharma, Allergan, Iveric Bio
- Shareholder-Clearside Biomedical (<0.01% ownership)
- *All relevant relationships have been mitigated*

3

## CHARACTERISTICS OF THE EYE

- Highly vascularized, small mass
  - Retinal and choroidal blood supply
  - Results in 'unusually high' susceptibility to ADRs
- Drugs present in systemic circulation can reach ocular structures through choroidal or retinal circulation

4

## THE EYE AND OCULAR ADRS

- Choroid and ciliary body have thin, fenestrated walls through which drug molecules can pass
- Small, lipid soluble molecules can pass into the aqueous
  - Diffuse into avascular structures: lens,
- Most common sites for drug deposition and functional disruption:
  - **Cornea, lens, retina, optic nerve**

5

## OCULAR ADVERSE DRUGS REACTIONS


- As few as 1% of ALL ADRs may be reported
- Ocular adverse effects range from mild to vision threatening
  - Optometrists are often the first to assess OADR

6

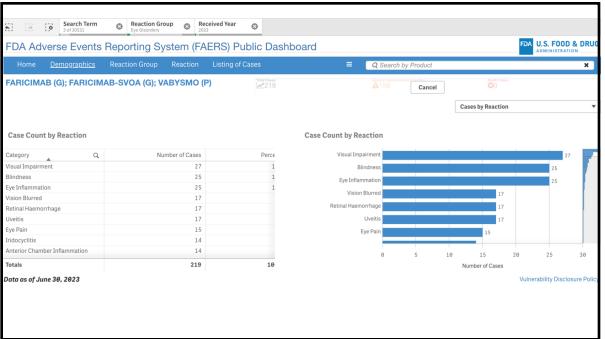
## FDA MedWatch



7



8



10

### LONG TERM SAFETY

- Following approval, the manufacturer continued to monitor adverse effects and clinical benefit
  - May be through a formal phase four trial
- Under reporting has been a significant concern

11

### POSTMARKETING REQUIREMENTS UNDER 505(o)

Section 505(o)(3) of the Federal Food, Drug, and Cosmetic Act (FDCA) authorizes FDA to require holders of approved drug and biological product applications to conduct postmarketing studies and clinical trials for certain purposes, if FDA makes certain findings required by the statute.

We have determined that an analysis of spontaneous postmarketing adverse events reported under subsection 505(k)(1) of the FDCA will not be sufficient to identify an unexpected serious risk of corneal endothelial cell loss. Furthermore, the active postmarket risk identification and analysis system as available under section 505(k)(3) of the FDCA will not be sufficient to assess this serious risk. We have determined that only a clinical trial (rather than a nonclinical or observational study) will be sufficient to identify an unexpected serious risk of corneal endothelial cell loss. Therefore, based on appropriate scientific data, FDA has determined that you are required to conduct the following trials:

4214-1 Conduct a controlled trial to evaluate the corneal endothelial health of eyes treated with faricimab by monitoring the number/density of corneal endothelial cells using specular microscopy at baseline and over a period of at least one year in at least 100 patients receiving faricimab.

The timetable you submitted on January 25, 2022, states that you will conduct this trial according to the following schedule:

Final Protocol Submission: 04/2022  
 Trial Completion: 12/2024  
 Final Report Submission: 04/2025

Vabismo (faricimab)

12

### REPORTING SYSTEMS

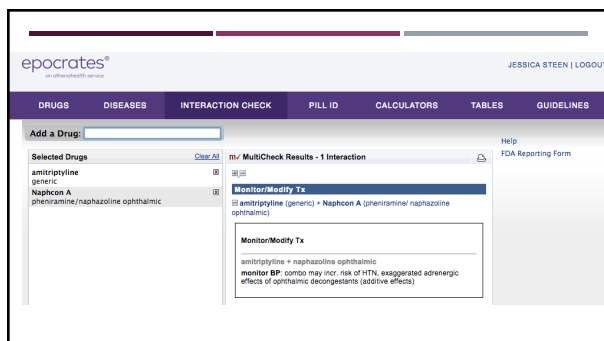
- MedWatch
- WHO spontaneous reporting database
- Canadian Adverse Drug Reaction Information System

13

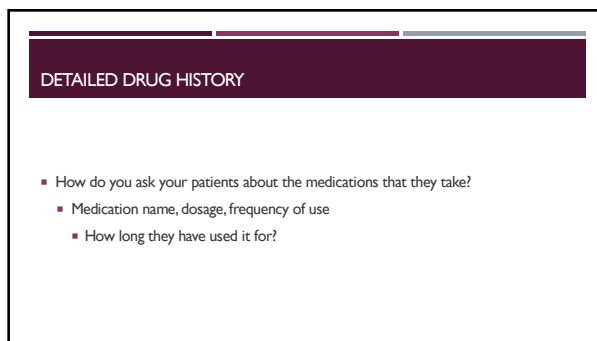
### DETERMINANTS OF ADVERSE DRUG REACTIONS

- Nature of the drug
- Amount of drug administered: dose
- Route of administration
- Age, sex
- Confounding drugs
- History of allergy to drugs
- Individual idiosyncrasy

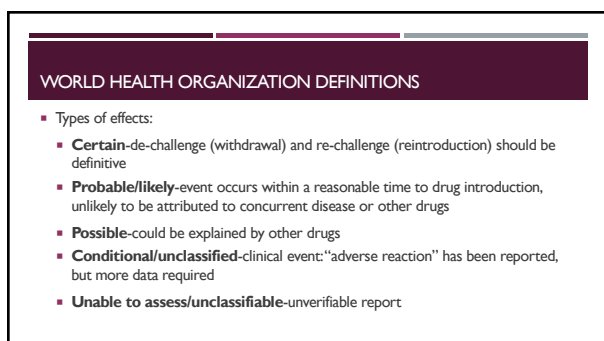
14



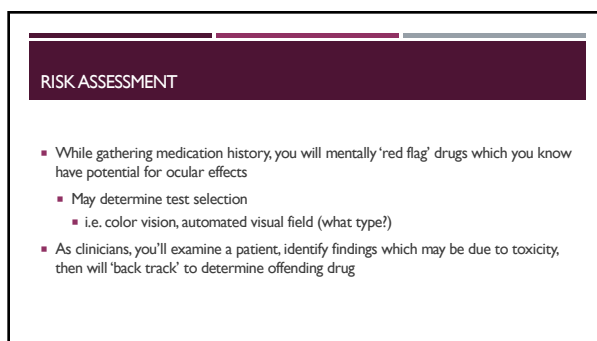
15



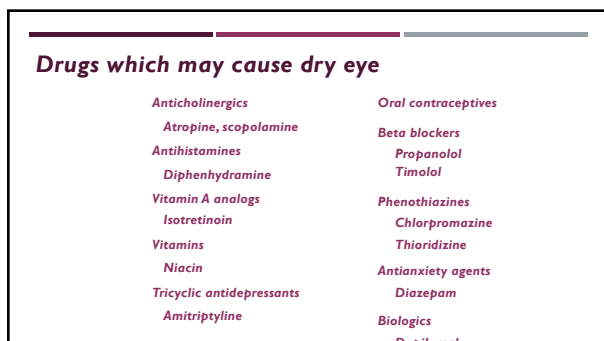
16



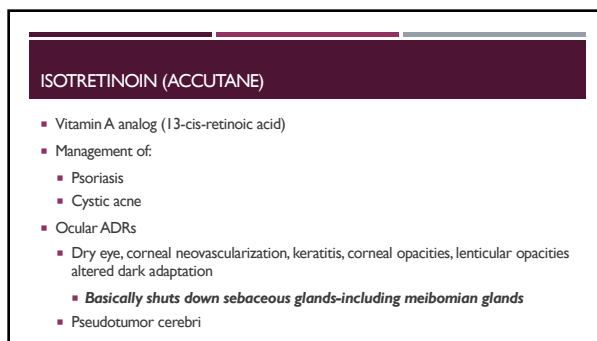
17



18



19



20

## ISOTRETINOIN (ACCUANE)

- Management
  - Advise patient to return for examination if any symptoms of ocular discomfort, redness, decreased CL tolerability
    - Typically within 1 month of treatment
  - Urgent evaluation if decreased vision, headache, transient visual obscuration
    - Evaluate ocular surface, color vision, optic discs
  - Discontinuation alone typically causes resolution of PTC

21

## ORAL CONTRACEPTIVES, HORMONE REPLACEMENT THERAPY

- Ocular adverse effects: ocular surface dryness, decreased tear secretion, reduced goblet cell density, CL intolerance
  - Estrogen-only HRT (vs. estrogen/progesterone therapy) showed greatest aqueous deficiency
- Management: Dry eye treatment: AT, hot compresses, lid hygiene routine, immunomodulatory agents, nutritional supplementation

22

## Drugs which may cause tearing?!

**Adrenergic agonists**  
*Ephedrine (primarily BI)*

**Antihypertensives**  
*Reserpine*  
*Hydralazine*

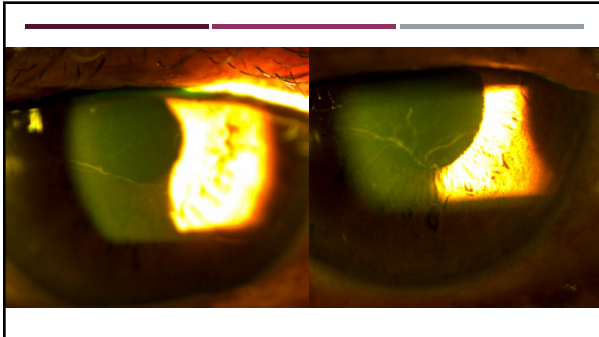
**Cholinergic agonists**  
*Neostigmine*  
*Pilocarpine*

23

## CORNEAL OPACITIES

- Benign, no significant threat to vision
  - Usually dose-related and often reversible
- Appearance of corneal opacities does NOT necessitate reduction or discontinuation of treatment
  - Except when severe corneal toxicity results in visual symptoms
- Medications bind with cellular lipids in the cornea

24



25

## DRUGS CAUSING CORNEAL OPACITIES

- AKA corneal verticillata or vortex (whorl) keratopathy
- Chlorpromazine-posterior stromal and endothelial pigment
- Indomethacin-stromal and epithelial opacities
- Chloroquine & hydroxychloroquine-whorl like epithelial opacities
- Amiodarone-whorl-like epithelial opacities
- Tamoxifen-whorl-like epithelial opacities
- Drugs causing vortex/whorl keratopathy/corneal verticillata = CHAIT
- And...netarsudil 0.02%

26

## CHLOROQUINE/HYDROXYCHLOROQUINE

- Chloroquine (Aralen)
  - Malaria prophylaxis and treatment (short term)
- Hydroxychloroquine (Plaquenil)
  - Autoimmune disease (rheumatoid arthritis, systemic lupus erythematosus)
  - Whorl keratopathy in 30-75% of patients
    - Not related to duration of use, rarely symptomatic, reversible
  - Maculopathy

27

## AMIODARONE (CORDARONE)

- Atrial and ventricular arrhythmia
- Whorl keratopathy and anterior subcapsular lens opacities, optic neuropathy
- May occur within weeks
  - Dose-related (>400mg/day)

28

## ANTICOAGULATION THERAPY

- Warfarin, Apixaban (Eliquis), rivaroxaban (Xarelto), aspirin
- Reduction of stroke and systemic embolism in Afib, prophylaxis of DVT and PE, treatment of DVT and PE, and reduction of recurrent DVT and PE
- Common: Subconjunctival hemorrhage, retinal hemorrhage
- **Never advise a patient to STOP their blood thinning medication after an ocular event**

29

## ANTI-COAGULANTS

- The surgical perspective:
  - **Cataract surgery**
    - Younger surgeons typically do not stop the medication at all (cataract surgery involves minimal bleeding)
  - Retinal surgery—often performed emergently; rarely discontinue tx
  - Intravitreal injections—no change to anti-coagulation tx
  - Glaucoma surgery; failure of trabeculectomy is more common in patients on anti-platelet/anti-coagulative medication—many surgeons discontinue treatment

30

## NSAIDS

- Indomethacin, ibuprofen, naproxen, and others
  - Increased bleeding (subconjunctival hemorrhage, retinal hemorrhage)
  - Stevens-Johnson syndrome
- Long term, high dose NSAIDs also increase the risk of myocardial infarction
- Indomethacin: possible/unlikely: optic neuropathy (ischemic), RPE changes, color vision defect
  - Management: prescribing doctor to discontinue medication—this may require urgent communication (telephone call)
- Remember, any systemic condition that impacts platelet count can increase bleeding risk

31

## PAIN MANAGEMENT ALTERNATIVE

- Acetaminophen
- Antipyretic and analgesic effect—weak anti-inflammatory effect
  - Little to no effect on platelets or inflammation
    - But does increase the blood thinning effect of warfarin
- Typically weaker effect than NSAIDs, but overall, better tolerance
- Well absorbed orally, peak blood levels reached in 30-60 minutes
- Caution in patients with liver disease, or who are at risk for liver disease

32

## LENS CHANGES

33

## CHLORPROMAZINE (THORAZINE)

- Phenothiazine derivative used in the treatment of schizophrenia, hallucinations, delusions
- Alpha-adrenergic blocker
  - Causes sedation
- Anterior subcapsular stellate cataract and corneal pigmentation
- Dose-related

34

## CORTICOSTEROIDS

- Posterior subcapsular cataract
- Activation of glucocorticoid receptors on the lens
- Increased intraocular pressure
- Management: Follow up depends on dose and duration of treatment and concern of IOP/optic nerve findings
- Common in high doses of inhaled steroids—but **corticosteroids by any route** can result in lenticular changes and elevated intraocular pressure
  - Remember, oral steroids are ideally administered in the morning to mimic natural cortisol release patterns

36

## MYDRIATIC & CYCLOPLEGIC EFFECTS

- Phenothiazines
- Anticholinergics
- Antihistamines
- Antianxiety agents
- Benzodiazepines
- Tricyclic antidepressants

*Caution in patients who are primary angle closure suspects*

37

## 66 year old Black female

### History of Present Illness

1. glaucoma follow-up  
 Patient has moderate POAG OD, OS. She is here for 3 month IOP check, DFE, and disc photos. Patient is currently on latanoprost qhs OU, reports good compliance and no toxicities. She needs a refill and pharmacy is the same as on file. She is going on a cruise in November and is wondering if the scopolamine patch that she wears behind her ear will interfere with her glaucoma.

A1c <6% (3 months ago)

### Thoughts?

38

## Drugs which may affect pupil size

<h3>Mydriasis</h3> <ul style="list-style-type: none"> <li>Anticholinergics</li> <li>CNS stimulants</li> <li>Amphetamines</li> <li>Cocaine</li> <li>CNS depressants</li> <li>Barbituates</li> <li>Antianxiety agents</li> <li>Antihistamines</li> <li>Diphenhydramine</li> <li>Phenothiazines</li> <li>Adderall, Ritalin</li> </ul>	<h3>Miosis</h3> <ul style="list-style-type: none"> <li>Opiates           <ul style="list-style-type: none"> <li>Heroin</li> <li>Opium</li> <li>Codeine</li> <li>Morphine</li> </ul> </li> <li>Anticholinesterases           <ul style="list-style-type: none"> <li>Neostigmine</li> </ul> </li> </ul>
--	---

39

## Drugs which may affect intraocular pressure

### Increased IOP

Antihistamines  
Phenothiazines  
Tricyclic antidepressants  
Antimuscarinics

### Decreased IOP

Beta blockers  
Cannabinoids (or not?)  
Ethanol

40

## TOPIRAMATE (TOPAMAX)

- Treatment of epilepsy and migraines
- Can cause bilateral, acute angle closure crisis
  - Suprachoroidal effusion
  - Anterior chamber shallowing
  - Increased IOP
  - Typically occurs quickly—1-14 days after initiation
- Hyperemia, mydriasis, ocular pain, acute myopia (6-8D), "dopamax"

41

## TOPIRAMATE

- Typical symptoms: blurred vision, headache, ocular pain
- 1) Ciliary muscle spasm
- 2) Swelling of lens
- 3) Swelling of the ciliary muscle—leads to forward displacement of lens diaphragm
- Can lead to acute angle closure crisis, induced myopia
- **These patients are symptomatic!**

43

## DRUGS CAUSING UVEITIS

- Account for less than 0.5% of all uveitis cases
- Cidofovir
- Rifabutin
- Bisphosphonates
  - Alendronic acid (Fosamax)
- Checkpoint inhibitors (1%)
  - Anterior, posterior—or panuveitis
- Can be difficult to distinguish between underlying disease process and treatment as the cause

44

## RIFABUTIN & RIFAMPIN

- Treatment of mycobacterium
- Uveitis, "pink tears"
  - Reddish urine, stool, saliva, skin, sputum, sweat
- Management: may require discontinuation and initiation of topical steroid
- Tuberculosis medications: **RIPE**
  - Rifabutin, isoniazid, (pyrazinamide), ethambutol



45

## BISPHOSPHONATES

- Inhibits calcium resorption
  - Used in treatment of malignancy & osteoporosis
- Can cause uveitis, episcleritis, scleritis, non-specific conjunctivitis
  - T cell activation
- Management: treatment of ocular inflammation
  - For scleritis, must discontinue medication

46

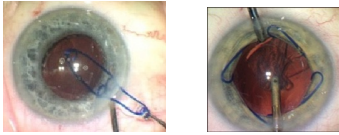
### INTRAOPERATIVE FLOPPY IRIS SYNDROME (IFIS)

- Tamsulosin (Flomax)
  - Alpha one adrenergic blocker for the treatment of benign prostatic hyperplasia
  - Relaxes smooth muscle (including dilator)
  - Also seen in doxazosin, terazosin
- Can cause iris prolapse during intraocular surgery and intraoperative miosis
  - **Discontinuing drug prior to surgery does not seem to reduce risk**
- Also seen with saw palmetto
- Management: Malyugin ring

47

### FLOPPY IRIS SYNDROME

- Solution: Malyugin Ring
  - Also used in other causes of poor dilation-i.e. exfoliation syndrome



49

### Drugs which may cause retinal changes

<b>Interferon</b>	<b>Talc retinopathy</b>
<b>Digoxin</b>	<b>Chloroquine/hydroxychloroquine</b>
<b>Sildenafil</b>	<b>Quinine</b>
<b>Thioridazine</b>	<b>Rosiglitazone</b>
<b>Tamoxifen</b>	<b>Atorvastatin</b>
<b>Elmiron</b>	<b>Fingolimod</b>

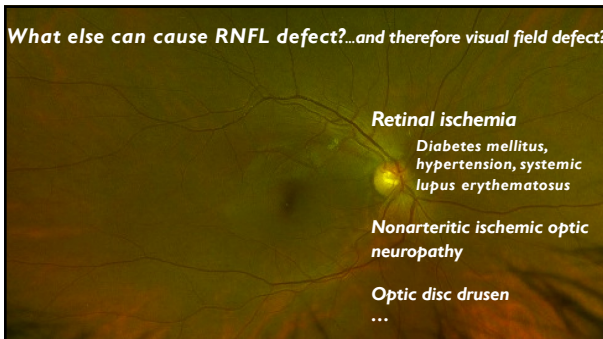
50

### INTERFERON THERAPY

- Treatment of hepatitis C and multiple sclerosis
- Cotton wool spots, conjunctivitis, dry eye
- Possibly due to upregulation of inflammatory cytokine deposition in vascular walls

51

*What else can cause RNFL defect?...and therefore visual field defect?*



- Retinal ischemia**  
Diabetes mellitus, hypertension, systemic lupus erythematosus
- Nonarteritic ischemic optic neuropathy**
- Optic disc drusen**  
...

52

### DIGOXIN

- Treatment of cardiac arrhythmia, congestive heart failure
- Blurred vision, decreased vision (yellow or blue tinged vision), red-green color defect, flickering or flashing lights
  - Visual hallucinations, mydriasis, extraocular muscle paresis
    - Drug found in high doses in retina and choroid-cone dysfunction-Na/K ATPase dysfunction
- Management: Monitor color vision
- Reversible with discontinuation of medication

53



## SILDENAFIL (VIAGRA)

- Inhibitor of phosphodiesterase type 5 (PDE 5) and type 6 (PDE 6)
  - PDE 6 is involved in retinal transduction
  - Also includes Cialis and Levitra
- Treatment of erectile dysfunction
- Visual effects in about 10% of patients taking 100mg dose
  - Blue tinged vision, photophobia
  - Dose related incidence
    - 40-50% at 200mg
- Possible: anterior ischemic optic neuropathy (NAION)

54

## PHENOTHIAZINES

- Chlorpromazine and thioridazine
  - Derivatives of phenothiazine
- Pigmentary retinopathy (salt/pepper fundus)-bind melanin
  - Starts peripherally, moves centrally
  - Can reduce VA, cause color vision changes, reduced dark adaptation
- Changes typically noted 1-3 months after beginning drug

55

## TAMOXIFEN (NOLVADEX)

- Anti-estrogen adjuvant therapy used to treat hormone receptor positive breast cancer (SERM)
  - 20mg daily for 5 years
- OADR <5% of patients
  - 1-2 years after starting
- Crystalline retinopathy, posterior subcapsular cataract—cystoid macular edema
  - Axonal degeneration in the the inner retina
- Similar effects may be seen with aromatase inhibitors
  - i.e. anastrozole (Arimidex)
    - More likely to cause intraretinal hemorrhages

57

## MEK INHIBITORS

- Mitogen-activated protein kinase/extracellular signal-regulated kinase (MAPK/ERK)
- Serous retinal detachment, retinal vein occlusion
  - Oxidative stress and breakdown of the blood-retinal barrier
- Dry eye disease, panuveitis
- Does not typically require discontinuation of therapy

59

## MIRVETUXIMAB SORAVTANSINE (ELAHERE)

- Folate receptor alpha-directed antibody and microtubule inhibitor conjugate (intravenous infusion) on label for the treatment of ovarian, fallopian tube, or primary peritoneal cancer
- Who have received one to three prior treatments
- FDA approved in 2022; permanent J-code July 1, 2023

### WARNING: OCULAR TOXICITY

- ELAHERE can cause severe ocular toxicities, including visual impairment, keratopathy, dry eye, photophobia, eye pain, and uveitis *see Warnings and Precautions (5.1) and Adverse Reactions (6.1).*
- Conduct an ophthalmic exam including visual acuity and slit lamp exam prior to initiation of ELAHERE, every other cycle for the first 8 cycles, and as clinically indicated *see Dosage and Administration (2.3).*
- Administer prophylactic artificial tears and ophthalmic topical steroids *see Dosage and Administration (2.3) and Warnings and Precautions (5.1).*
- Withhold ELAHERE for ocular toxicities until improvement and resume at the same or reduced dose *see Dosage and Administration (2.3) and Warnings and Precautions (5.1).*
- Discontinue ELAHERE for Grade 4 ocular toxicities *see Dosage and Administration (2.4) and Warnings and Precautions (5.1).*

60

## Work with an eye care provider (ophthalmologist or optometrist) to manage ocular events that may occur

### BEFORE STARTING ELAHERE



You will visit an eye doctor for a baseline eye exam, and eye exams throughout your treatment on ELAHERE, or about every 6 weeks during the first 8 cycles of treatment. This will help your healthcare team keep track of any potential changes to your vision or eyes during treatment.\*

\*There may be additional costs associated with eye exams. Please check with your insurance provider for more information.



Your eye doctor may recommend 2 different types of eye drops to help reduce the risk of developing eye-related side effects:

- Prescription steroid eye drops, filled by a pharmacist
- Preservative-free lubricating eye drops, which can be purchased over the counter

Apply the eye drops as directed by your doctor.

Avoid wearing contact lenses during treatment with ELAHERE unless your doctor tells you that you can

61

TO BE COMPLETED—AND SUBMITTED TO THE PRESCRIBING Ophthalmologist—BY THE EYE CARE PROVIDER

Please select the appropriate option:  
 Baseline exam     Scheduled follow-up exam     Follow-up due to patient-reported symptoms

**Note:** As part of their treatment with ELAHERE, your patient is being prescribed ophthalmic topical steroids that may elevate intraocular pressure.

**Symptom Assessment:**  
 Patient reports the following new or ongoing ocular symptom(s): \_\_\_\_\_  
 No symptoms reported

**Visual Acuity\***

	Baseline exam		Current exam	
	Right eye	Left eye	Right eye	Left eye
Best corrected distance visual acuity	20/	20/	20/	20/
Entering distance visual acuity				
Were corrective lenses worn during the assessment?	<input type="checkbox"/> Yes <input type="checkbox"/> No	<input type="checkbox"/> Yes <input type="checkbox"/> No	<input type="checkbox"/> Yes <input type="checkbox"/> No	<input type="checkbox"/> Yes <input type="checkbox"/> No

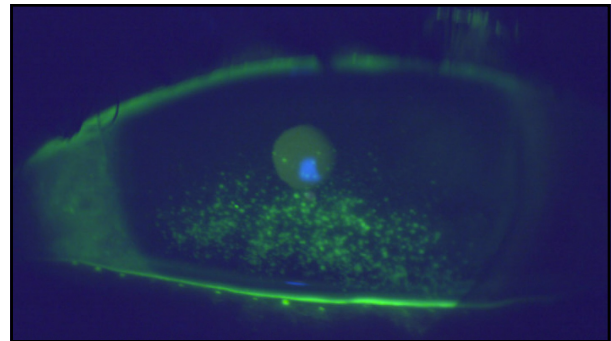
**Optic Nerve Exam\***  
 No abnormal findings

Finding	Severity of finding	Right eye	Left eye	Action
Noncorneal superficial keratitis		<input type="checkbox"/> Yes <input type="checkbox"/> No	<input type="checkbox"/> Yes <input type="checkbox"/> No	Monitor
Confluent superficial keratitis		<input type="checkbox"/> Yes <input type="checkbox"/> No	<input type="checkbox"/> Yes <input type="checkbox"/> No	Monitor
Corneal epithelial defect		<input type="checkbox"/> Yes <input type="checkbox"/> No	<input type="checkbox"/> Yes <input type="checkbox"/> No	Monitor
5-line or more loss in best corrected visual acuity		<input type="checkbox"/> Yes <input type="checkbox"/> No	<input type="checkbox"/> Yes <input type="checkbox"/> No	If yes for either eye, notify prescribing ophthalmologist
Stromal opacity		<input type="checkbox"/> Yes <input type="checkbox"/> No	<input type="checkbox"/> Yes <input type="checkbox"/> No	Monitor
Best corrected distance visual acuity of 20/200 or worse		<input type="checkbox"/> Yes <input type="checkbox"/> No	<input type="checkbox"/> Yes <input type="checkbox"/> No	Monitor
Corneal perforation		<input type="checkbox"/> Yes <input type="checkbox"/> No	<input type="checkbox"/> Yes <input type="checkbox"/> No	Monitor
Grade 3/4 cell in anterior chamber		<input type="checkbox"/> Yes <input type="checkbox"/> No	<input type="checkbox"/> Yes <input type="checkbox"/> No	Monitor
Grade 2/3 cell or flare in anterior chamber		<input type="checkbox"/> Yes <input type="checkbox"/> No	<input type="checkbox"/> Yes <input type="checkbox"/> No	If yes for either eye, notify prescribing ophthalmologist
Grade 3/4 cell or flare in anterior chamber		<input type="checkbox"/> Yes <input type="checkbox"/> No	<input type="checkbox"/> Yes <input type="checkbox"/> No	If yes for either eye, notify prescribing ophthalmologist
Grade 4 hyphema		<input type="checkbox"/> Yes <input type="checkbox"/> No	<input type="checkbox"/> Yes <input type="checkbox"/> No	Monitor

\*Please refer to the ELAHERE prescribing information for complete details on the severity of each finding and the appropriate action.

<https://www.elaherehc.com/pdf/ocular-assessment-form.pdf>

62



63

**Tisotumab vedotin-tftv, for injection 40 mg, Eye Care Consult Form**

This patient has been prescribed tisotumab vedotin-tftv. Tisotumab vedotin-tftv can cause changes in the corneal epithelium and conjunctiva resulting in changes in vision, including severe vision loss, and corneal ulceration. Conduct an ophthalmic exam at baseline, prior to each dose, and as clinically indicated.

The information in this form is important to the prescriber of tisotumab vedotin-tftv to make treatment and dose modification decisions in the event of an ocular adverse reaction.

**INSTRUCTIONS:**  
 Please complete this form and promptly provide it to the prescribing physician. The completed form may be carried by the patient, faxed, or included in electronic medical records.

**WARNING: OCULAR TOXICITY**  
 See full prescribing information for complete boxed warning.

- TIVDAK caused changes in the corneal epithelium and conjunctiva resulting in changes in vision, including severe vision loss, and corneal ulcerations. (5.1)
- Conduct an ophthalmic exam at baseline, prior to each dose, and as clinically indicated. (2.2, 5.1)
- Adhere to premedication and required eye care before, during, and after infusion. (2.2)
- Withhold TIVDAK until improvement and resume, reduce the dose, or permanently discontinue, based on severity. (2.3, 5.1)

64

**PENTOSAN POLYSULFATE SODIUM (ELMIRON)**

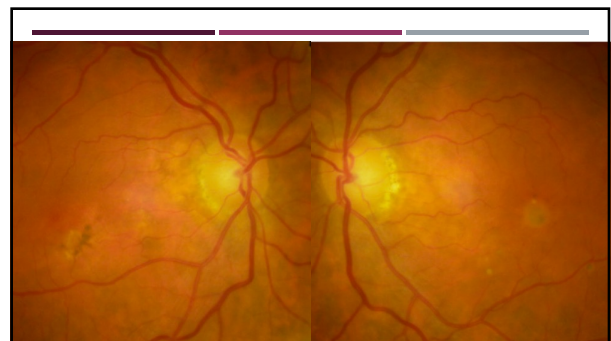
- Semi-synthetic analogue of glycoaminoglycans
  - Regulate cellular permeability at the level of the epithelium of the bladder
- Treatment of interstitial cystitis
  - Chronic regional pain syndrome of the bladder and pelvis
- Median duration of PPS intake 16-17 years
  - Average 14,067 capsules
- Prolonged dark adaptation, metamorphopsia, blurred vision while reading
- Annual eye examinations are recommended

65

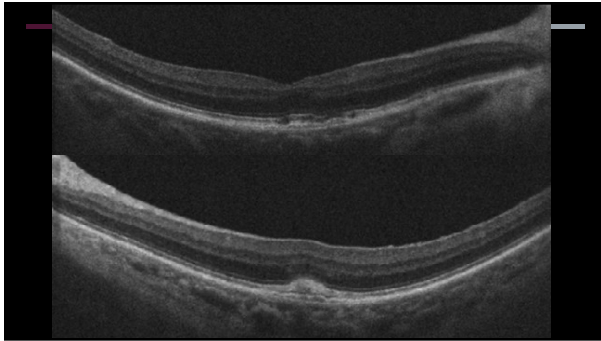
**76 YEAR OLD HISPANIC FEMALE**

- Presents for evaluation of suspicion of glaucoma
- BCVA 20/30 OD 20/40 OS
- IOP 14mm-Hg OD and OS

66



67



68

Medications reconciled today:

Adherence	Medication Name	Sig Desc	Elsewhere	Status
taking as directed	pregabalin 75 mg capsule	take 1 capsule by oral route 2 times every day	Y	Verified
taking as directed	atenolol 100 mg tablet	take 1 tablet by oral route every day	Y	Verified
taking as directed	atorvastatin 20 mg tablet	take 1 tablet by oral route every day	Y	Verified
taking as directed	amlodipine 5 mg tablet	take 1 tablet by oral route every day	Y	Verified
taking as directed	clopidogrel 75 mg tablet	take 1 tablet by oral route every day	Y	Verified
taking as directed	lisinopril 5 mg tablet	take 1 tablet by oral route 3 times every day	Y	Verified
taking as directed	arnica flower (bulk) tincture		Y	Verified
taking as directed	Multi Vitamin 9 mg Iron/15 ml oral liquid		Y	Verified
taking as directed	melatonin 10 mg capsule		Y	Verified
taking as directed	cranberry concentrate-ascorbic acid 4,200 mg-20 mg capsule		Y	Verified
taking as directed	aspirin 325 mg tablet	take 1 tablet by oral route every day for post-angioplasty	Y	Verified
taking as directed	escitalopram 10 mg tablet	take 1 tablet by oral route every day	Y	Verified
taking as directed	timolol maleate 0.5 % eye drops	apply 1 by Ophthalmic route OU BID	N	Verified
taking as directed	Elmiron 100 mg capsule	take 1 capsule by oral route 3 times every day with water, 1 hour before or 2 hours after a meal		Verified

69

### TALC RETINOPATHY

- Dilute IV drugs with talcum powder (magnesium silicate)
  - Also found as a filler in oral tablets which may be crushed and injected
    - Common to inject 10-40 tablets daily
- Magnesium silicate doesn't dissolve in blood stream-seen in retina, liver kidney, spleen
- **Talc retinopathy-seen typically after injecting equivalent of 12,000 tablets**
  - Peripheral retinal neovascularization due to severe ischemia

70

### CHLOROQUINE/HYDROXYCHLOROQUINE

- Chloroquine (Aralen)
- Hydroxychloroquine (Plaquenil)
  - **Photoreceptor (inner segment/outer segment junction) damage**
    - Lysosomal damage leads to photoreceptor and RPE loss
  - "Bull's eye maculopathy", reduced visual acuity, central/paracentral visual field defects
  - Can progress following discontinuation of drug

72

### 2016 GUIDELINES FOR PLAQUENIL MONITORING

- Marmor et al. 2016
- Major risk factors: dose >5mg/kg/day, >5 years of use, reduced glomerular filtration rate, concomitant retinal disease, **concomitant tamoxifen use**
  - Age and liver disease no longer considered to be major risk factors
- Dosage: recommended maximum daily dose of 5mg/kg/day
  - Typical dosage 200mg BID po
  - For a patient who is 130 lbs = 59kg = 6.80mg/kg/day
- At recommended doses, risk of toxicity up to 5 years is under 1% and up to 10 years is 2%
  - Almost 20% after 20 years of treatment

73

### HYDROXYCHLOROQUINE RETINOPATHY

Barnes et al Eye. 2014

74

## 2016 GUIDELINES FOR PLAQUENIL MONITORING

- Baseline examination should be performed to rule out pre-existing maculopathy
  - *What if they have pre-existing maculopathy?!*
- Annual screening after 5 years of treatment within recommended dose and without major risk factors
- SD-OCT, 10-2 Humphrey visual field
  - Consider 30-2 HVF in patients of Asian descent
  - mfERG
- *What information do you need to know—and what information does the managing provider need to know?*

75

## QUININE

- Historically used for the treatment of malaria
- Now used to nocturnal leg cramps
  - Safe dosage <2g (500mg QID)
- Mild toxic reactions (4-8g)
  - Slight reduced toxicity, "flickering" of vision, tinnitus, confusion
- Marked toxicity (>8g)
  - May be used in attempted suicide-visual field loss, loss of vision, coma
  - Can cause optic atrophy

77

## ROSIGLITAZONE

- Thiazolidinedione
  - Type 2 diabetes treatment
- Increases sensitivity to insulin
- May increase macular edema
  - In association with diabetic retinopathy
  - *Possibly secondary to increased VEGF*

78

## ATORVASTATIN (LIPITOR)

- Treatment of hyperlipidemia
- May cause appearance of cystoid macular edema
  - Most common in men between 30 and 50 years of age

79

## Statins in general

*May cause diplopia or ptosis  
Average time to adverse effect was  
8 months*

*Can cause myositis  
Seems to be a localized myositis in  
the extraocular muscles and levator*

81

## FINGOLIMOD (GILYENA)

- Oral medication used in the treatment of multiple sclerosis
  - Sphingosine-1-phosphate-receptor modulator that prevent lymphocytes from leaving lymph nodes
    - Also crosses BBB and has direct effects on the CNS
- Cystoid macular edema (2/1000)
  - Typically occurs within one month of treatment
    - Due to increased vascular permeability
- Examine patient at baseline, then 3-4 months after beginning therapy

82

**Drugs which may cause optic nerve changes**

<i>Ethambutol</i>	<i>Oral contraceptives</i>
<i>Isoniazid</i>	<i>Amiodarone</i>
<i>Vigabatrin</i>	<i>Vitamin A analogs</i>
<i>NSAID (indomethacin)</i>	<i>Tetracyclines</i>
	<i>Tamoxifen</i>

83

**ETHAMBUTOL**

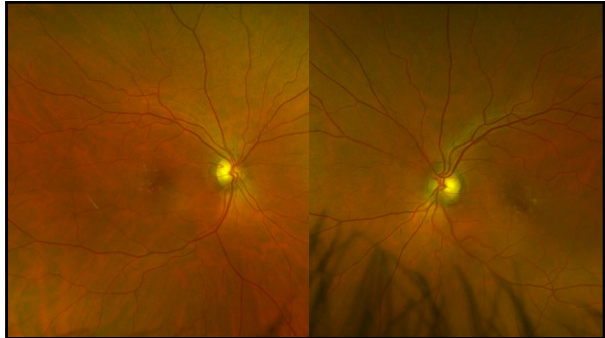
- Treatment of mycobacterium
  - Interferes with mycobacterium nucleic acid structure
- Toxic optic neuropathy
  - Reduced visual acuity, visual field, color vision (R/G)
- Stop treatment as soon as vision affected
  - Vision rarely recovers
- Dose-related response
  - 50% for 60-100mg/kg/day
  - 5-6% for 25mg/kg/day
  - 1% <15mg/kg/day

84

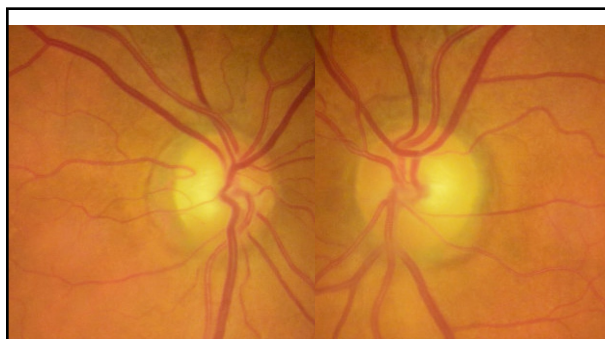**59 YEAR OLD HISPANIC MALE**

- History of mycobacterium tuberculosis (resolved)
- Development of MAC fibrocavitary disease
- Treatment with:
  - Ethambutol 15mg/kg/day
  - Rifampin
  - Azithromycin

85



86

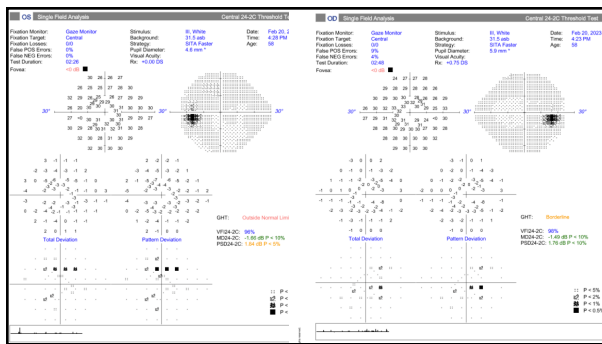


87

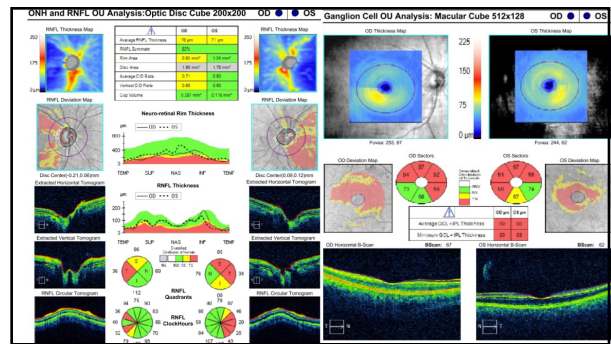
**ISONIAZID**

- Mycobacterium treatment
- Optic neuropathy, red/green color deficiency

90



93



94

**So you've identified ocular toxicity, now what?**

**#1 Assess the level of urgency (i.e. risk of vision loss) and communicate with the prescribing physician**

**...In a way most appropriate for the situation**

95

**VIGABATRIN (SABRIL)**

- Inhibits GABA-T
  - Increases levels of gamma aminobutyric acid (GABA)
    - Inhibitory neurotransmitter
- Highly effective anticonvulsant
  - Selectively increases brain and retinal GABA
  - Not a first line medication due to side effects
- Visual field constriction-30-50% of patients
  - Irreversible
  - Causes damage to photoreceptors and ganglion cells

97

**VIGABATRIN**

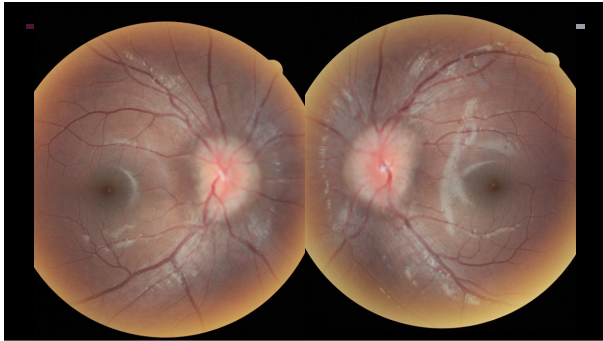- Not commonly prescribed; for patients who have failed on other anti-seizure medications, FDA approved in 2009
- 8 year old patient, non-verbal, severely intellectually disabled due to seizures
- Presented with letter from neurologist which required an eye examination (every 3 months) to rule out optic nerve dysfunction secondary to toxicity
- Ideally—pupil examination, fundus examination, OCT RNFL, HVF, color vision, consideration of electrophysiological testing (VEP, EOG)
  - In this case, the patient was dilated by a technician prior to double checking pupil response and had to settle for a brief view of the optic nerve with BIO

98

**AMIODARONE**

- Anti-arrhythmic drug
- 1. Whorl keratopathy
  - Not a reason for drug discontinuation
- 2. Optic neuropathy
  - Blocks axoplasmic flow = optic disc edema
  - Insidious onset, slow progression, bilateral vision loss (usually)
  - Mean duration of treatment before vision loss = 9 months

99



101

### BILATERAL OPTIC DISC EDEMA

- Presentation of pseudotumor cerebri
- Back to the medication list:
  - Oral contraceptive
  - Vitamin A derivative (Accutane)
  - Tetracycline
  - Indomethacin
- *What symptoms may be present in this patient?*

102

### TETRACYCLINES

- Conjunctival deposits
  - Brownish/greenish/black with tetracycline
  - Bluish discoloration of sclera with minocycline
- Skin discoloration!!

103

### SULFONAMIDE ANTIBIOTICS

- Stevens-Johnson syndrome
  - Ocular involvement in up to 70% of cases
    - Severe ocular surface disease and trichiasis, symblepharon
  - Patients of Japanese and Korean descent are at greater risk
  - Life-threatening
- *After these patients are released from the hospital, they are often in our offices—what are our management considerations?*

104

### ALCOHOL (ETHANOL)

- Short term decrease in intraocular pressure
  - Max effect 1-2 hours after consumption
- Effects eye movements
  - Alcohol horizontal gaze nystagmus test
    - Relatively sensitive and specific

106

*And finally...*

108

## MARIJUANA

- Marijuana (THC) Lowers intraocular pressure by up to 25% (may be more like 15%) for about 2-3 hours
  - *What does this mean for someone attempting to lower their intraocular utilizing a THC-containing product?*
  - Side effects?
- CBD
  - Can act as an antagonist of cannabinoid receptors—and have been shown to slightly **increase IOP** in animal models; more realistically, it has zero effect

109

## BOTTOM LINE

- All medications have adverse effects
- Identifying ocular effects of systemic medications begins with an accurate history
- Potential ocular effects of systemic medications improves with familiarity
- Known adverse effects of systemic medications may be the “lowest hanging fruit”; but are not always the answer
- Communication with the patient’s other managing physicians is integral!

110

[jessicaa.steen@gmail.com](mailto:jessicaa.steen@gmail.com)  
**480.289.0613**

111