ETP – NOW WHAT?

DRS. PATEL AND FINDLEY
COMMONWEALTH EYE SURGERY, LEXINGTON, KY

FINANCIAL DISCLOSURES

- NONE

ETP – NOW WHAT?

- Sometimes things don't go as expected.
- You just did an ETP on this patient and things went sideways
- NOW WHAT!
- "These things DO happen!" Madame Giry.

ETP - LPI

- Indications
- Pupil block from Primary Angle Closure or Acute PAC
- Mechanism
- Allows aqueous trapped in PC an alternate route to AC which allows iris to recede from occluding TM
- Contraindications
- Completely flat AC
- Corneal edema precluding view
- PAS 360 degrees
- NVG
- ICE

ETP – Now What

- Complications of LPI
- Acute IOP spike
- Anterior uveitis
- Closure of the LPI
- Posterior synechiae
- Corneal burns
- "Ghosting," dysphotopsia
- BCSC. Vol. 10, p.193
- Wills Eye Maunal

ETP – LPI #1 IOP spike

- G.G. (45622) 71 yoM
- COAG controlled many years on Travatan and Alphagan with IOP in low 20s
- 12/30/08 with narrow angles
- TA – 23,23
- LPI OD – Diamox 250 x2, Iopidine
- Argon 27 shots, 1200mW,50 mic,.2 mSec. YAG 20 shots, 4 mJ, 80 TE
- Post LPI TA 35 mmHg

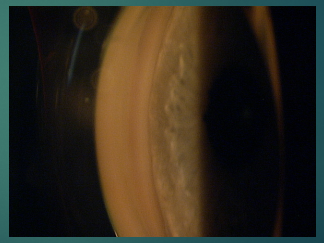

ETP – LPI #1 IOP spike

- TA 35 mmHg
- Diamox 250 x 2 tabs
- TA 32 mmHg @ 4:00 pm
- Sent home with 2 tabs Diamox

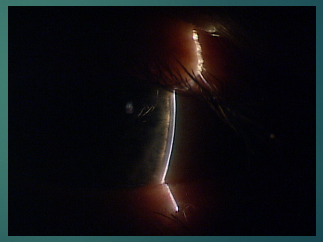

ETP – LPI #1

- On Call services 7:00 pm - Pain OD. Took a pain pill but did not help.
- Advised to take 2 more Diamox and instill Travatan and Alphagan
- On Call services 12:00 am – Pain and nausea.



ETP – LPI #1

- 12/31/08
- TA – 54 mmHg 12:34 am
- Istalol and Iopidine instilled
- Gonio showed angle open TM to SS
- Sent to ER for oral meds

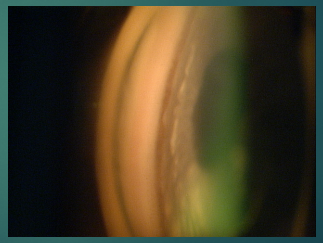

ETP – LPI #1

- 12/31/08 – returns to clinic. Still has a painful OD and nausea
- VA -20/80
- SLE – patent LPI
- Gonio – TM to SS
- TA – 58 mmHg

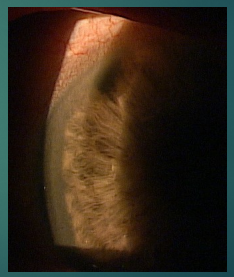

ETP – LPI #1

- TA -54
- Paracentesis

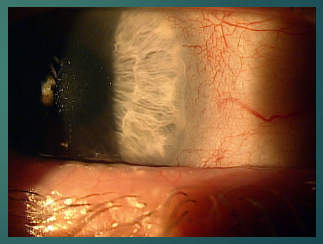

ETP – LPI #1

- 2/3/09 – returns to clinic after spending a month in Destin, FL. While there he saw an ophthalmologist who told him the LPI was non-patent and repeated LPI OD
- SLE – non-patent LPI OD
- TA – 22 mmHg
- Supplemental LPI OD

  YAG 3 shots, 4 mJ
- Post supplemental LPI 22 mmHg

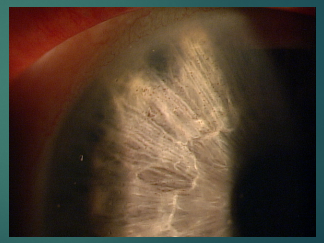

Take home points

Over time COAG can become NAG

- Oral glycerin 50%

  1 -1.5 g/kg
- osmotic gradient →dehydrate vitreous → Lower IOP
- NOT in pts with renal failure ,on dialysis
- HA,CHF, MI, nausea, vomiting…

  BCSC 2016-17. Vol.10. P. 182.

ETP – LPI #2 (different patient)(*)

- S.S. (110617) 56 yoM
- Referred for narrow angles

  +1.75 -0.25 x 69 20/30+

  + 2.00 – 0.50 x 156 20/20
- Slit lamp – narrow angles OU
- Gonio :

  OD CBB visible with anterior insertion of iris to CBB, ant. bowing → deeper with pressure

  OS TM visible with anterior insertion and bowing → deeper
- TA : 18,18 @ 11:24 am



Dynamic gonioscopy ETP – LPI #2 (*)

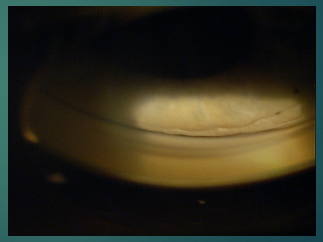

ETP – LPI #2

- Discussed LPI vs Lensectomy → he preferred LPI OS.
- LPI OS
- Argon -
- 10 shots,1100mW,.15mS,50mic
- YAG
- 4 shots, 2.5mJ,13mJ TE
- TA post LPI 23 mmHg

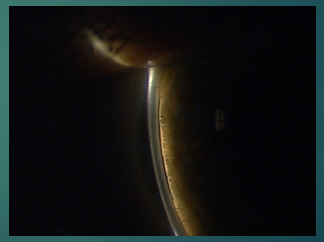

ETP – LPI #2

- 2/11/22 - narrow with patent LPI OS
- TA – 16,23 9:37 am
- LPI OD

  Argon

  6 shots, 1100mW,.15mS,50 mic

  YAG

  11 shots,3.2 mJ,35mJ TE
- TA post LPI 21 mmHg

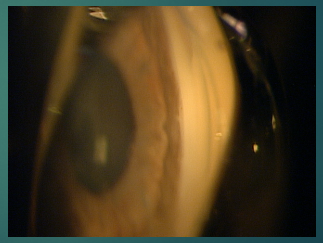

ETP – LPI #2

- 3/8/22 Returns for DST
- SLE – moderate depth OD shallow OS and quiet with patent LPI OU
- TA – 18,28 pre dilation

  23,23 post dilation
- Gonio post dilation

  OD – TM nasal, ATM other quads

  OS – SL superior, ATM inferior, TM nasal and temporal

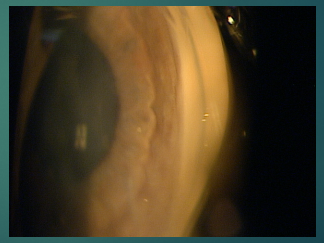

ETP – LPI #2

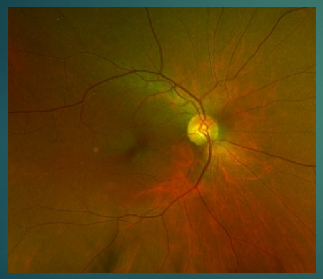

ETP – LPI #2

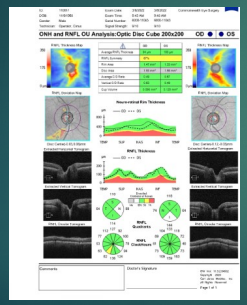

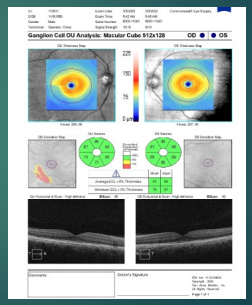

ETP – LPI #2



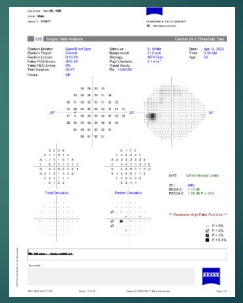

Take home ETP – LPI #2

- Follow off meds (IOP higher OS post LPI)
- Early GCL/VF OD (?)
- Next step
- RTC 4 m repeat VF OCT

ETP – LPI #3 Failed LPI

- D.M. (35639) 73 yoF
- Hx of ACG OS
- S/P LPI OU, CE OS @ UK
- 3/19/19 – Routine dilated exam by local doc. ACG OD.
- VA 3/200
- SLE – injection, MCE, Shallow AC, mid-dilated pupil with LPI
- TA - 55 mmHg

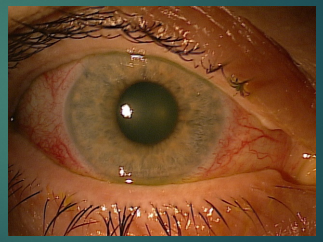

ETP – LPI #3

- Gonio

  OD – no structures visible

  OS – PAS inferior, SS other quads, iris flat.
- Diamox 250 x 2 tabs, Combigan, Iopidine, Rhopressa, Pilo

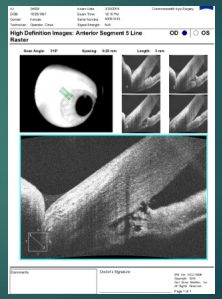

ETP – LPI #3

- Repeat LPI OD
  Argon
  14 shots,.15mS,1100mW,50mic
- YAG
  72 shots,2.3mJ, 165mJ TE
- TA – 40mmHg post LPI
  45 mmHg 30 min later
  36 mmHg
  34 mmHg

ETP – LPI #3

- 3/20/22 Phaco with IOL OD
  TA 22 mmHg
- 3/21/22 –
- UnCorVA 20/40;
- SLE – moderately D & Q, trace cell
- TA 7,Combigan
- 4/9/22 – UnCorVA 20/30
- TA 13 off meds (ran out)

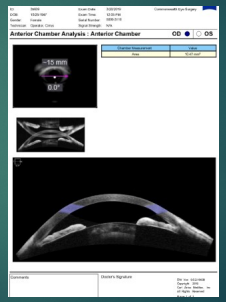

Take home ETP – LPI #3

- LPI doesn't prevent subsequent angle closure by lens (Phacomorphic)



ETP – LPI #4 Failed LPI

- A.A. (105443) 50 yoF
- 3/31/22 At routine exam told she had narrow angles
- UnCVA : OD 20/20; OS 20/30→20
- Slit lamp – narrow, Trace NS
- TA – 8 mmHg, 12 mmHg 10:40am
- Gonio – Anterior to SL OD, TM inferior angle



ETP – LPI #4

- LPI OD (4/16/22)
- Iopidine, Diamox pre
- Argon – 12 shots, 1100mW
- YAG – 20 shots 4.0 mJ
- Post LPI 19 mmHg
- Pred qid x 1 week, bid,qd
- Reports tired multiple days with low BP and HR

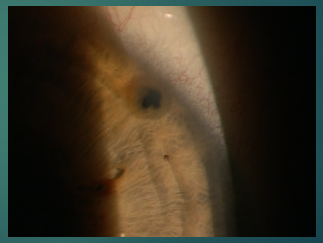

ETP – LPI #4

- 4/30/22 – Slit lamp shows moderate depth with patent LPI OD
- TA – 16 mmHg, 19 mmHg
- LPI OS (no Diamox)

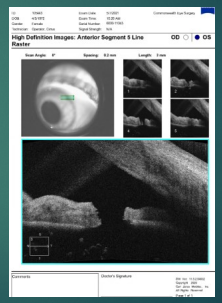

ETP – LPI #4

- 5/7/22 – Saw primary doc for red OD. Told LPI non-patent
- Slit lamp – Non-patent LPI OD, patent LPI OS
- TA – 13 mmHg, 15 mmHg 10:24
- Repeat LPI OD
- Argon – 6 shots, 1100 mW
- YAG 15 shots, 3.6 mJ, 54mJ TE

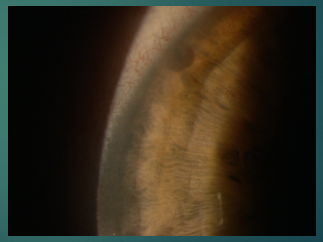

Take home ETP – LPI #4

- Unusual for LPI to occlude, especially so soon after initial laser
- Possible uncontrolled inflammation?
- Pred qid x 1 wk, bid x 1 wk, qd x 1 wk.

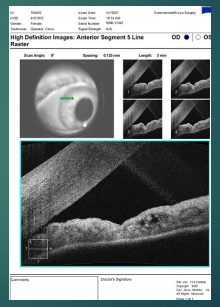

ETP – LPI #5 Dysphotopsia

- G.D.(87198) 68 yoF
- 9/15/71 – Referred for nausea with multiple episodes described "feels like black curtain drawn over OS and she can't see out of it for a few minutes." When vision returns she has a headache. Also reports migraine-like symptoms "small colorful saw tooth halo OS that increases in size and eventually goes away."



ETP – LPI #5

- BVA 20/20
- Slit lamp – shallow and quiet, cortical and 1+N
- TA – 15 mmHg, 15 mmHg 11:17
- Gonio – ATM visible with anterior bowing of iris. Danger of closure
- LPI OS
- Argon – 35 shots , 110 mW
- YAG – 44 shots, 5 mJ
- Post LPI TA – 22 mmHg

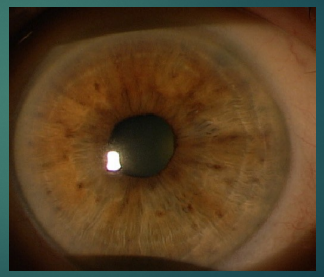

ETP – LPI #5

- 10/6/17 – Seeing a "white halo" in bottom half of vision since LPI.
- Slit lamp – moderate depth, patent LPI
- TA – 14 mmHg, 18 mmHg
- Symptoms may be 2ary to LPI
- DELAY LPI OD
- 11/15/17 – Sx persists
- TA – 14 mmHg, 18 mmHg
- Gonio – CBB with 2+ PTM
- Mx – colored CL, cat surg

Take home ETP – LPI #5

- Dysphotopsia after LPI is a thing
- Prismatic effect of superior tear meniscus
- Consider LPI temporal

ETP - LTP

- ALT
- Argon laser
- 50 um spots, .1 sec, 300-1000mW
- 40-50 spots over 180 degrees
- Treat at junction of anterior pigmented and posterior non-pigmented TM
- Therma damage to collagen fibers causes stretching of adjacent fibers increasing outflow
- SLT
- Frequency doubled Q-switch Nd:YAG 532 nm
- 400 um spot size, 3.0 nS, 0.4-1.5 mJ
- Treat 360 degres, titrate to appearance of bubbles
- Selectively absorbed by pigmented cells in TM sparing adjacent tissue from thermal damage
- Increased monocytes and macrophages in TM increasing outflow

ETP - SLT

- Indications
- First line of tx
- Patient can't tolerate or non-adherent to meds
- Not controlled on meds
- Good for
- POAG
- Pigmentary glaucoma
- PEX
- +/- Angle recession glaucoma
- Contraindications
- Inflammatory glaucoma
- Iridocorneal endotheliopathy syn
- NVG
- Posterior synechial angle closure
- Developmental glaucoma
- Results
- May take 4-6 weeks for full effect
- 80% get decrease in IOP
- 50% maintain lower IOP for 5 yrs
- Best in older patients and PEX

ETP - SLT

- Complications
- IOP spike – 20%, 50-60mmHg
  Pre-op apraclonidine, CAI
- Low grade anterior uveitis –
- Hyphema
- Corneal inflammation, edema (DLK like)
- Persistent elevated IOP
- Reactivation of HSK
- BCSC 2016-17. Vol. 1. P. 190-191.



ETP – SLT #1 Uncontrolled IOP

- G.W. (4982) 55 yoM
- 7/7/07 -Pigmentary glaucoma on Lumigan and Azopt. Spotty F/U.
- TA – 20 mmHg, 17 mmHg
- VF progression OU
- 7/31/07 – CES SLT OD
- SLT 120 shots, 1 mJ, 270 degrees (had previously had 1 quadrant tx with 32 shots)
- Post SLT TA 24 mmHg

ETP – SLT #1

- 8/14/07 – SLT OS
- SLT 160 shots, 1 mJ, 180 degrees
- Post SLT TA – 20 mm Hg
- Continue Lumigan
- 5/8/15 Returns for repeat SLT
- TA – 21, 18 on latanoprost
- SLT OD 104 shots, 1.1mJ
- TA – 12 mmHg



ETP – SLT #1

- Oct 2017 Phaco with IOL OU
- 3/30/22 YAG eval
- TA – 29 mmHg, 20 mmHg off meds
- 4/1/22 YAG OS; 5/13/22 OD
- No post YAG TA recorded
- VF 3/22 →

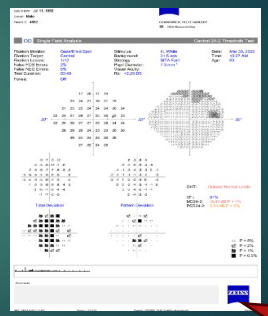

ETP – SLT #1

- 5/13/22 Vision OS dimmer and more blurred than OD since YAG.
- VA – 20/30 OD, 20/20 OS
- TA – 22, 18 mmHg on latanoprost
- Gonio CBB with PTM OU
- Cup/disc – 0.7 OD; .5 x .6 OS
- VF unreliable
- SLT OD – 170 shots, TA 24

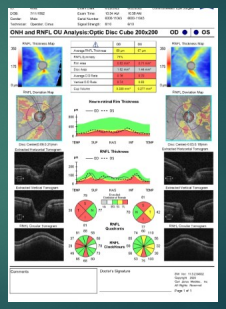

ETP – SLT #1

- 6/22/22 – Vision is foggy
- VA – 20/50, 20/20
- TA – 50, 16 mmHg (Diamox)
- TA – 38, 14 mmHg (sample Rhopressa)
- 6/24/22 – Eye feels better but really red (Rhopressa, latanoprost)
- VA – 20/200
- TA – 50 mmHg, 18 mmHg (D250)
- TA – 46 mmHg(Betimol)
- TA – 42 mmHg (Rocklatan)

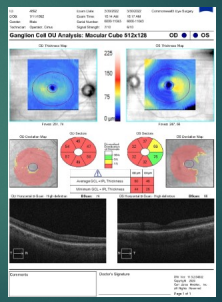

ETP – SLT #1

- 6/28/22 – Vision much better and eye feels good
- VA – 20/25 OD 20/15 OS
- Slit lamp – 1+ cell in AC OD
- TA – 12 mmHg, 22 (Sim, Bet, RockLatan)
- 7/14/22 on Betimol OU, Rocklatan OD. Latanoprost OS
- TA – 29mmHg, 13 mmHg
- TO GLAUCOMA SUB.

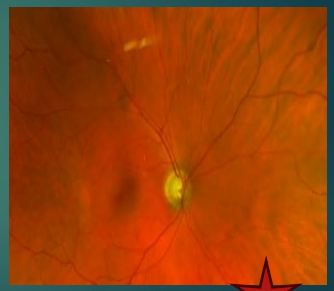

Take Home ETP – SLT #1

- Third times a charm
- Know when to fold em
- S/P SLT x 3 and still on 3 meds with uncontrolled IOP
- Glaucoma subs need work too

ETP – SLT #2 Keratitis

- R.Y. (15926) 40 yoM
- Myopic degeneration and COAG
- VA - 20/50, 20/40 (-10.00)
- TA – 26 , 24
- C.D. - .8 OU
- VF – large blind spots
- Followed 5 yr with TXE and Lumigan added
- TA – range 15 -20 mmHg



ETP – SLT #2

- Allergic response to meds
- 9/6/05 SLT OS – 100 shots, 1mJ, 360 degrees → Acular bid x 1 w.
- 9/8/05 "Foggy vision with red eye"
- VA – 20/400
- SLE – conj injection, epi intact with 3+ stromal cells, AC cells
- TA – 14

ETP – SLT #2

- Switch Acular to PF qid
- Improved over 2 weeks
- 9/23/05 TA – 16, 32 → taper PF
- 10/4/05 TA – 16, 14
- 10/10/05 SLT OD
- 100 shots , 0.8 mJ, 360 degrees
- PF qid post SLT (mild keratitis)
- 11/06/05 TA 13,14 on TXE only

Take home ETP – SLT #2

Some (mild) inflammation after SLT is good. That's how it works.

- Control with NSAID bid x 7 days
- If too much inflammation, keratitis switch to steroid
- "Overkill"

ETP – SLT #3 DLK and uncontrolled IOP

- K.P. (21550) 43 yoM
- S/P Lasik 1/30/03
- S/P Enhancement OU 7/16/09
- Pigment dispersion with OHT pre Lasik

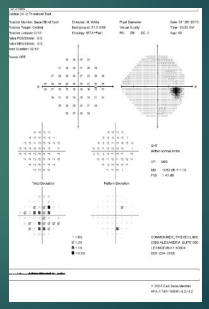

ETP – SLT #3

- Jan. 2010 – Returns for evaluation for Pigmentary Glaucoma.
- TA – 23 , 17 on Xalatan
- 2/2/10 SLT OD – 1.0mJ, 167 shots, 360
- TA – 8 mmHg
- 3/9/10 SLT OS – 1.0 to 1.5 mJ, 163 shots
- TA – 12
- 2/11/11 TA – 26,21 on Travatan Z
- VF inferior nasal step

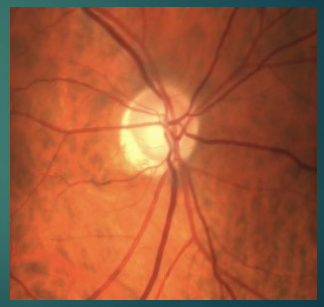

Post SLT → DLK (post Lasik x 2 OU)
ETP – SLT #3

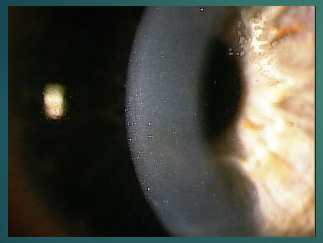


ETP – SLT #3

- 4/19/11 Consult Dr. Sanders
- Paradoxical IOP rise after SLT in PDS/PG
- 3+ PTM OU
- CD - .6 OD , .7 OS
- TA – 27 , 18
- Resume Xalatan, target 18, no laser

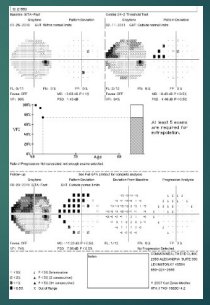

ETP – SLT #3

- Several yrs later – On Travatan Z qhs, Combigan q12h, Alphagan q12h
- VA – 20/20, 20/20
- TA – 12, 14 mmHg
- Tube shunt OD 10/2011
- OS 4/2012
- Cataract OD 2014, OS 2012

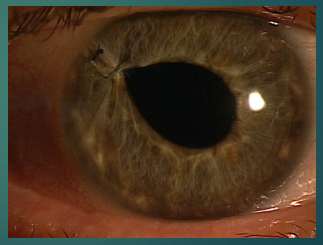

ETP – SLT #3 Take home

- Paradoxical rise in IOP after SLT in PDS
- Special attention to monitoring IOP in post KRS patients

ETP – SLT #4 AC Reaction

- D.H. (51241) 60 yoM
- 8/10/11 CRVO OD

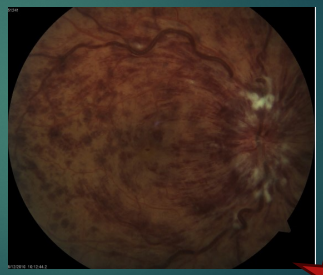

ETP – SLT #4

- 6/5/12 returns for SLT.
- Retina cleared. Small CD.
- SLT OD 1.1 mJ, 161 shots, 360
- Post SLT TA – 26
- 6/15/12 TPC. Fever and nausea. Dx sinusitis. Then saw PCP who told him he had not been on the antibiotic long enough for effect. Called CES – "Did SLT cause…?"

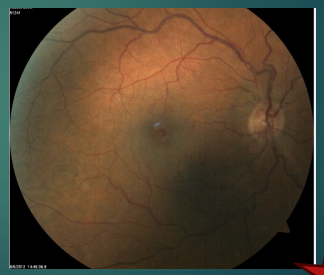

ETP – SLT #4

- 7/31/12 TA 16.15
- SLT OS 1.2-1.4 mJ, 168 shots, 360 degrees
- RTC with complaint of burning sensation after SLT

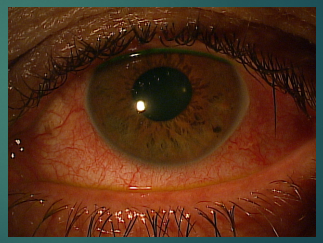

ETP – SLT #4

- SLE with fluorescein shows diffuse keratopathy
- Continue Lumigan and Combigan
- Bromday qd x 3 days

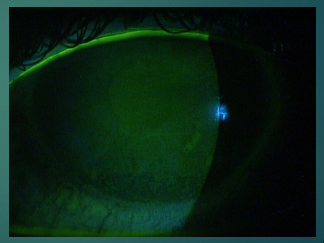

ETP – SLT #4

- RTC 3 days later
- No FBS but has a dull ache.
- SLE show AC cells
- Continue Lumigan and Combigan
- Continue Bromday qd

ETP – SLT #4

- Take home
- Keratopathy after SLT (from all the gtts and lens)
- Inflammation post SLT is expected.
- "If some is good, more is (not) better."

ETP – SLT #5 Corneal Abrasion

- D.G. (21478) 83 yoF
- CE – OD 6/26/08, YAG 12/11/12
- OS 1/27/03, YAG 8/18/06
- "Glaucoma suspect" on Travatan

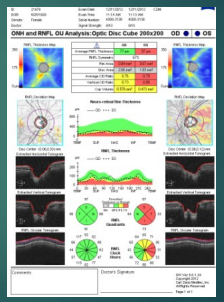

ETP – SLT #5

- 2/17/09 Returns for SLT
- TA – 27, 21 on Travatan OS
- CD - .6 OD , .8 OS
- OCT – NFL normal range OD, thin nasal and inferior OS

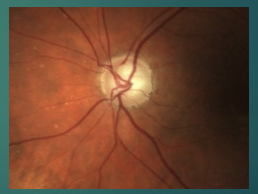

ETP – SLT #5

- 2/17/09 SLT OS 1.1 mJ, 140 shots, 360 degrees
- Patient returns to clinic after SLT with FBS
- SLE – Corneal abrasion
- Zymar and Acular instilled
- BCL

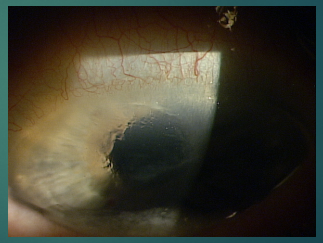

ETP – SLT #5

- 2/23/09 -Note from referring doc
- Abrasion healed in, BCL removed

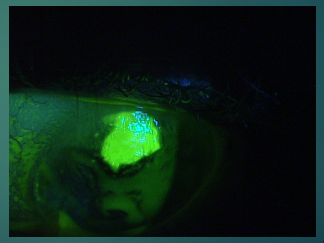

ETP – SLT #5 Take home

- Can have keratopathy (previous case) or corneal abrasion after SLT
- Treat the same as any abrasion (+/- antibiotic), BCL

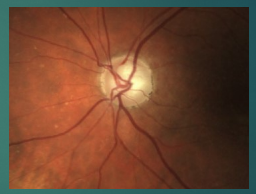

ETP – SLT #6 No Decrease in IOP

- M.R. (101650) 60 yoF
- + Family history of glaucoma. Currently using latanoprost qhs and brimonidine qhs OU.
- Very little reduction in IOP on 2 meds per patient.
- TA – 15, 15
- Gonio – CBB visible with anterior insertion of iris to CBB. Angles are open and candidate for SLT
- CD .75 OU, no Drance heme

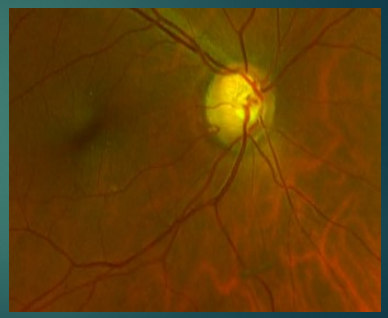

ETP – SLT #6

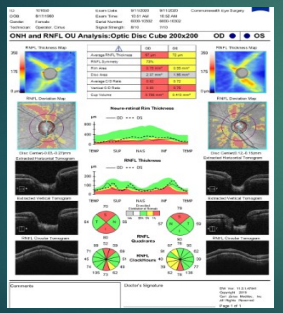

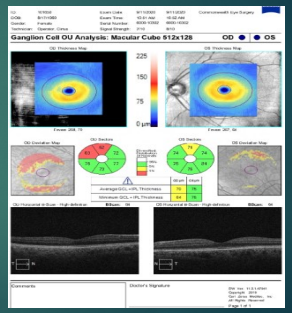

ETP – SLT #6

- 7/24/20 – SLT OD, 228 shots, 1.2mJ
- 9/11/20 – Returns for F/U
- TA – 16, 14 latanoprost only
- IOP unchanged but on less meds
- Patient wants to delay SLT OS
- 10/23/20 Returns for F/U
- TA – 15,17 latanoprost only
- Patient wants to further delay SLT OS

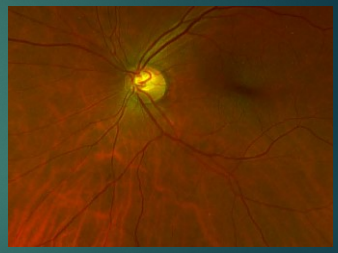

ETP – SLT #6 Take home

- SLT did not reduce IOP but allowed patient to discontinue 1 glaucoma med
- Success from the doctor's point of view
- Not so much from the patient
- Continue meds, maybe change



ETP - YAG

- Indications
- Symptomatic decreased vision from PCO
- Hazy PC blocking view of fundus
- Monocular diplopia
- Anterior capsular phimosis
- Capsular block syn
- Vitreolysis
- Anterior hyaloidotomy
- Removal of IOL ppt/membranes
- Fragmentation of retained lens cortex

- Contraindications
- Inadequate visualization of PC
- Patient or eye movement
- Active inflammation
- Uncontrolled glaucoma
- Suspected CME
- High risk for RD

ETP - YAG

- Complications
- IOL pits
- IOP spike
- RD – axial myopia, young males, trauma, vitreous prolapse, Fam hx RD, pre-existing vitreo-retinal path
- CME
- IOL dislocation
- Corneal edema, abrasion

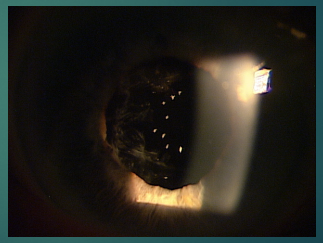

- Wills Eye Manual. P. 424. BCSC Vol. 11, 2016-17. p. 143, 154-57.

ETP – YAG #1 Corneal Abrasion, Hypopyon

- D.S. (42780) 76 yoF
- S/P Phaco w Toric IOL
- OD 7/24/08
- OS 6/26/08
- 11/20/14 Returns for YAG OS
- BVA – 20/100
- YAG OS – 70 shots 1.0 mJ Abraham lens

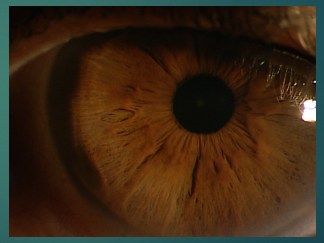

ETP – YAG #1

- 11/22/14 Reports pain and decreased vision
- VA CF OS
- SLE – 2+ injection, 4mm corneal abrasion, edema, hypopyon
- TA – 13 mmHg
- Fundus grossly normal
- No apparent ulcer; hypopyon uveitis vs endophthalmitis
- Tx – Ciprofloxacin q1h, Durezol qid, BCL

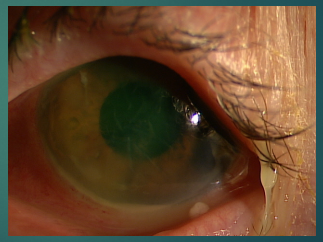

ETP – YAG #1

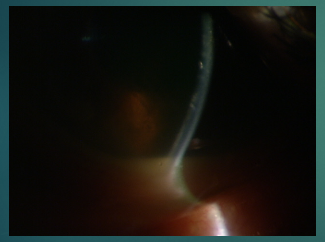

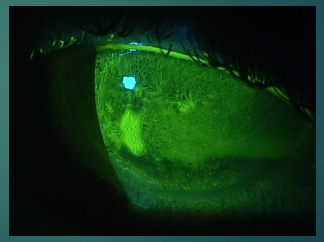

ETP – YAG #1

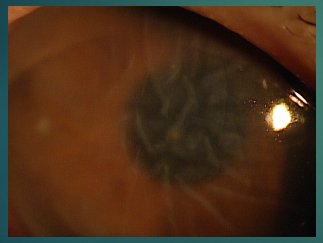



ETP – YAG #1

- 11/23/14 – Continued pain
- VA – CF
- SLE – hypopyon resolved, otherwise sam
- Tx – switch to Vigamox q1h, cont. Durez qid, BCL
- 11/24/14
- SLE – abrasion, deep stromal folds
- Vigamox tid, Durezol qid, E-mycin ung p

ETP – YAG #1

- 11/24,25,26/14 – Epi defect resolved, edema remained but improved, added Medrol dosepack, removed and replaced BCL . TA 18.
- 12/1,4,11,19/14 Continued slow improvement.
- VA 20/125
- SLE – SEI-like infiltrates. TA – 16.
- Durezol bid x 1 w, qd x 1 w

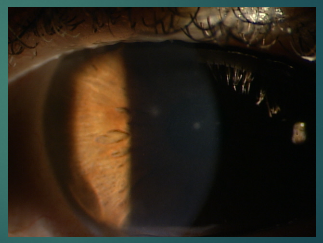

ETP – YAG #1

- 1/20/95 – Much better
- VA – 20/60 MRx -2.00 -0.75 x 150 20/30 (Monovision)
- Tx – artificial tears
- 3/24/15 – Doing well.
- VA – 20/60, J1+
- SLE – cornea clear
- Tx – Release to local O.D.

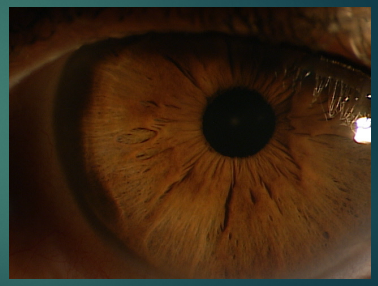

ETP – YAG #1 Take home

- Stuff happens

ETP – YAG #2 Retained Lens, IOP Elevated

- R.P (42952) 53 yoM
- S/P Phaco with IOL OD 2008
- 3/8/19 – RTC for YAG OD; COAG on latanoprost qhs
- VA – 20/50
- SLE – IOL with PCO, retained lens material OD
- TA – 15
- YAG – 59 shots, 1.7 mJ, 164 TE

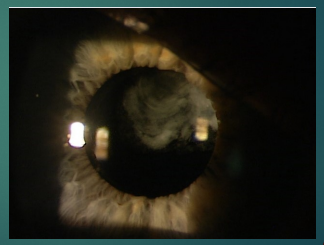

ETP – YAG #2

- Post YAG TA
- TA – 40, 42 @ 2:09 pm → Simbrinza
- TA – 34 @ 2:44 pm
- TA – 32 @ 3:32
- Sampled Simbrinza bid
- Diamox 250 mg 6 tabs (qid)
- Durezol qid
- F/U local O.D. in 3 days



ETP – YAG #2

- Take Home
- Monitor post YAG TA in patients with COAG and patients with retained lens material or posterior capsule distention
- These patients may need topical steroids post YAG (retained lens material, PCD)

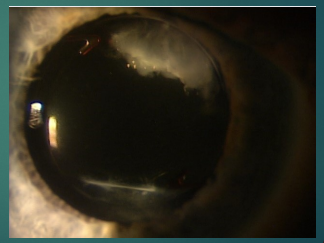

ETP – YAG #3 IOP Spike, CNVM

- L.W. (107834) 59 yoF
- Cataract surgery in Malaysia OU
- Myopic degeneration
- 8/2/21 – Sent for YAG OD
- BVA - 20/30 BAT 20/400
- SLE – IOL with anterior capsular phimosis, PCO
- TA – 17
- YAG OD – 128 shots, 3.6 mJ, 461

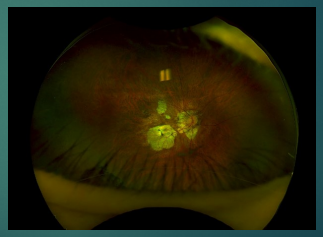

ETP – YAG #3

- 8/3/21 – Nauseated and dizzy, vision blurred. Using pred qid x 4 days, bid x 4 days
- VA – CF (after paracentesis 20/60)
- SLE – MCE
- TA – 68 mmHg @ 11:34
- Post paracentesis → 21 (Diamox,lopidine)
- TA – 37 mmHg @ 12:41
- Post 2nd paracentesis – 19 (Comb)
- TA – 20 mmHg @ 2:12
- Home with Diamox, Combigan,pred

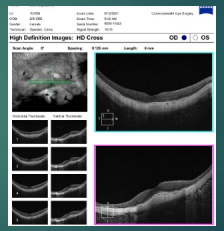

ETP – YAG #3

- 8/4/21 – Feels much better. Diamox, Combigan, pred
- VA – 20/20
- TA – 11 mmHg
- Tx – Cont. pred bid, Combigan
- 8/12/21 – Returns reporting straight lines look wavy
- VA – 20/25
- Mx – Directly to retinal sub

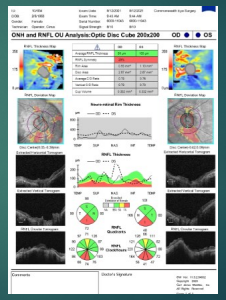

ETP – YAG #3 Take home

- Comorbidities happen
- Improved BVA after YAG but new onset metamorphopsia
- Did the YAG cause the CVM?

ETP – YAG #4 Subluxed IOL

- M.L. (93661) 59 yoM
- Hx of trauma (divulged later)
- 11/14/18 CE + IOL OD – IOL in sulcus centered slightly inferior
- 12/17/18 CE + IOL OS – zonular laxity but IOL in bag
- 3/15/09 – Returns for YAG
- BVA – 20/30 BAT 20/150
- YAG – 64 shots, 2.5 mJ, 164 TE

ETP – YAG #4

- 3/21/19 – Returns post YAG. He was told "something moved" during YAG.
- VA – 20/40
- MRx - Plano -1.00x168 20/20
- SLE – IOL edge visible thru undilated pupil
- TA – 18
- Mx – Schedule reposition or exchange

ETP – YAG #4

- 6/27/19 – Returns reporting on 6/11 he was run over by a car in his apt. complex
- 11/19/20 – Reposition IOL with iris sutures
- 11/20/20 – 1 Day post-op
- VA – 20/20
- SLE – IOL centered with iris sutures
- TA – 19 mmHg
- 12/17/20 – 4 week post-op
- 20/20

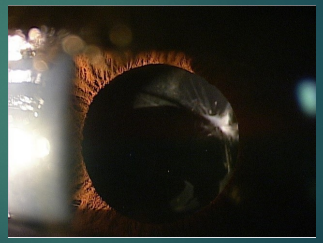

Take Home ETP – YAG #4

- If difficulty at CE may also have problem with YAG (IOL in sulcus, zonular laxity)
- Hx of trauma
- Evaluate IOL position and check for pseudophakodonesis before and after YAG

ETP – YAG #5 Subluxed IOL

- H.F. (29185) 66 yoM (not me)
- Phaco + IOL OD 2/7/05
- OS 7/16/96
- MSPPV/SBP OD 7/14/05 RRD
- OS 8/11/05 RRD
- YAG OD 10/17/06 81shots,1.0mJ
- OS 8/5/16 62 shots, 2 mJ
- IOL OD (12/3/20)→

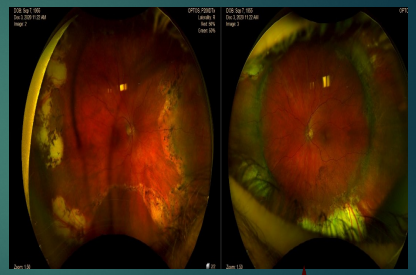

ETP – YAG #5

- 12/3/20 – Returns with sudden decreased vision OD x several days.
- BVA – OD 20/50
- OS 20/150,J2(monovision)
- SLE – iridodonesis with IOL visible thru undilated pupil
- TA – 22 mmHg OU
- Retina flat on buckle
- Mx – reposition IOL OD (12/8/20)

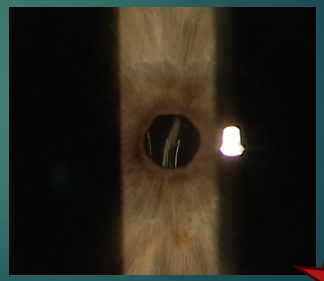

ETP – YAG #5

- 12/9/20 1 day post-op
- VA – 20/150
- SLE – moderate corneal edema, 4+ cell, iridodonesis, IOL centered with iris sutures
- TA – 31 mmHg → Combigan

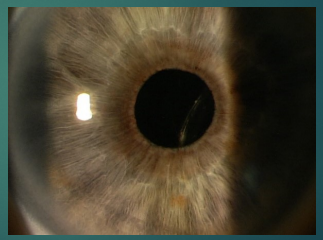

ETP – YAG #5

- 12/11/20 – Reports vision better
- BVA – 20/60 → 30
- SLE – mild corneal edema, 3+ cells, iris sutured PCIOL
- TA – 18 mmHg
- Tx – Cipro 500 mg bid, PGB
- F/U local optometrist 1 week

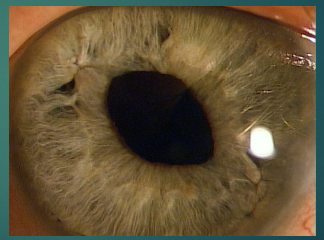

ETP – YAG #5

- 12/16/20
- BVA – 20/40
- TA – 46 → Diamox, Combi →26
- 12/18/20
- BVA – 20/30
- TA – 26 on Combigan
- 1/19/21 - TA 18 → d/c Combi
- 2/2/21 – BVA -20/20
- TA – 33 mmHg → latanoprost

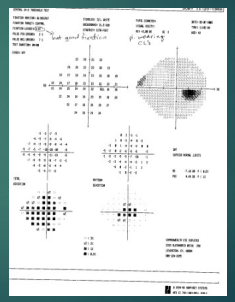

ETP – YAG #5 Take Home

- When performing YAG after MSPPV and SBP
- "Be vewwy, vewwy careful…"
- CE OD 2/5/05 → RD with SBP → 7/14/05 → YAG 10/17/06 → IOL subluxed 12/3/20

ETP – YAG #6 Capsular Remnants

- R.H. (101044) 58 yoF
- PDR s/p PRP OU
- Phaco + IOL OD 8/17/20
- OS 8/24/20
- 12/4/20 – Returns for YAG eval
- BVA - OD 20/40 BAT 20/400
- OS 20/25 20/80
- SLE PCO OD > OS

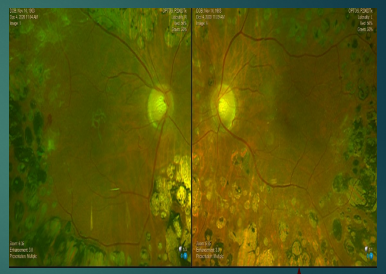

ETP – YAG #6

- 12/4/20 YAG OD 37 shots, 3.6mJ
- 12/11/20 OS 44 shots, 3.6mJ
- 1/22/21 – Returns for decreased vision OD that started 2 weeks after YAG OD
- VA – 20/50-2
- SLE – Salzmann's nodules, capsular remnant on visual axis OD
- TA – 20 mmHg

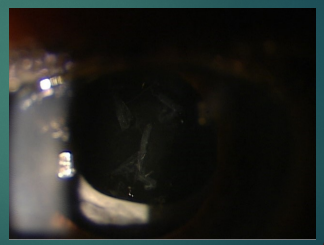

ETP – YAG #6

- Supplemental YAG OD
- 36 shots, 3.6 mJ
- BVA post supplememtal YAG 20/25
- Note anterior capsule as well

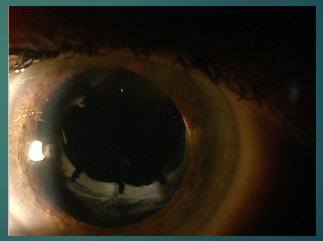

ETP – YAG #6 Take Home

- Can have capsular remnants after YAG that are visually bothersome to patient.
- Confirm capsular remnants vs vitreous opacities
- "You said I would never have to do this again!"
- Bill ?
- "If you like your insurance, you can keep your insurance."

ETP - YAG #7 Capsular Remnants Take 2

- C.C. (94623) 67 yoF
- S/P RK – 2 incisions superior cornea OU (???)
- Phaco + IOL OD 3/11/19
- OS 3/18/19
- 11/13/19 – Returns for YAG eval
- 11/15/19- YAG OD 51,2.7mJ
- 11/27/19 OS 18,2.8
- (Photo 10/8/21) →

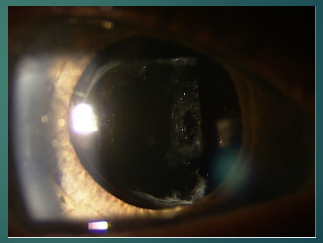

ETP - YAG #7

- 2/6/21 – Vision in OD is like looking thru a film, changes with blink
- BVA – 20/30
- To retina for vitrectomy
- 10/8/21 Return again for YAG
- BVA - 20/20
- SLE – capsular remnant
- Warn – MAY have floaters again
- YAG OD – 60 shots, 3.6 mJ

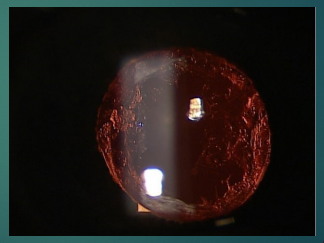

ETP - YAG #7 Take Home

- Confirm whether symptoms are from capsular remnants or vitreous debris
- Best candidates for Floaterectomy are pseudophakes post YAG
- YAG after Floaterectomy may reintroduce floaters

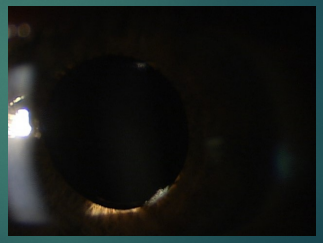

ETP – YAG # 8 Lens Remnants

(25844) 56 yoF

- Hx of Staphyloma OU and laser for peripheral retinal tears OS.
- Phaco + IOL OD 6/17/14
- OS 4/29/14
- Axial length – OD 33.83,OS 33.22
- IOL power OD -3.0, OS -2.0
- YAG OD somewhere, sometime

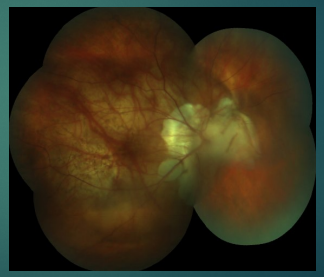

ETP – YAG # 8

- 11/23/21 Returns for YAG eval
- CC of decreased vision and floaters, told she had debris behind IOL
- BVA – 20/30 OD, 20/60 OS
- SLE showed cortical material inferior OD and temporal OS

ETP – YAG # 8

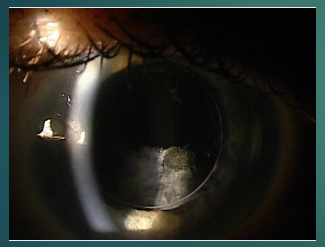

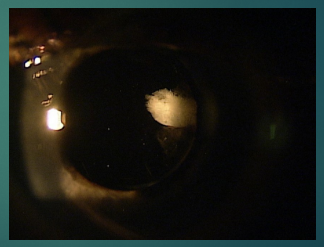

ETP – YAG # 8

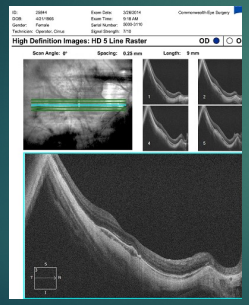

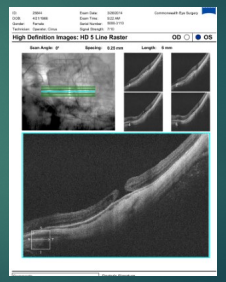

ETP – YAG # 8

- NO SUPPLEMENTAL YAG
- Back to retina for floaters
- If they dare they can remove the cortical remnants along with vitrectomy

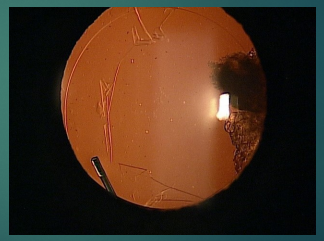

Take Home – NO.
JUST NO.

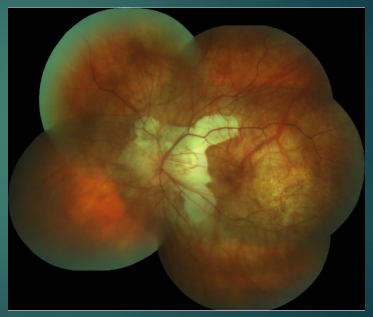

ETP – YAG #10 "Dendrites" or YAG

- M.B. (98937) 74 yoF
- RCS with AK OD 12/12/19
- OS 12/19/19
- 3/19/21 – Returns for decreased vision, YAG eval. Dx HZO OD 6 weeks ago. Treated with pred and Valtrex. Finished course.
- BVA – OD 20/20 BAT 20/50
- OS 20/20 20/70
- SLE – OD 3 corneal scars. PCO OU.

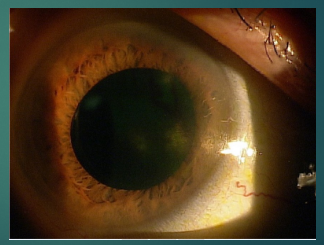

ETP – YAG #10

- SLE – Flourescein pattern as shown OD.
- Tx – resume pred qid and Valtrex 500 tid po. NO YAG OD. BUT CAN YAG OS.
- YAG OS – 39 shots, 3.6 mJ
- Follow up with local eye doc 1 week
- RTC 2 weeks. Clinic before YAG.

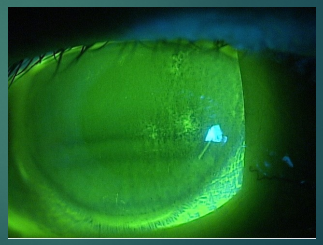

ETP – YAG #10

- 4/9/21 – Returns for possible YAG OD. Post YAG OS. Reports she is seeing better since YAG. Using pred qid and finished Valtrex.
- BVA – OD 20/30, OS 20/20
- SLE – clear cornea OD, dendrites resolved
- YAG OD – 61 shots, 3.4 mJ
- Continue pred qid and resume Valtrex 500 tid x 14 days

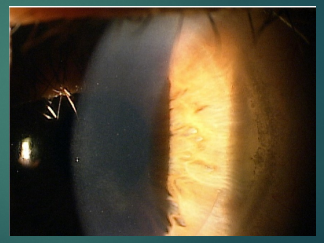

ETP – YAG #10 Take Home

- Potential for reactivation of HSK after YAG.
- This patient had reactivation before YAG.
- No YAG until eye is quiet.
- Treat prophylactic to try to prevent recurrence.

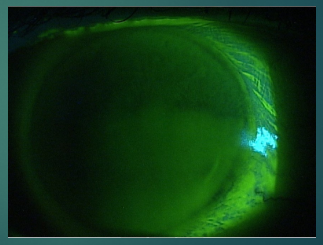

ETP – YAG #11 CME after YAG

- L.A. (104441) 70 yoF
- Phaco + IOL OD 3/4/21
- OS 2/25/21
- At pre-op visit 3/4 VA 20/25 OS
- 7/8/21 – Returns for decreased VA and YAG eval.
- BVA – OD 20/70, OS 20/150
- SLE – IOL with PCO OU.
- TA – 8, 10 mmHg

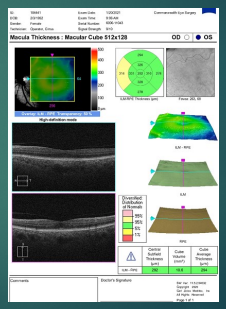

ETP – YAG #11

- YAG OS – 45 shots, 3.4 mJ
- 8/20/21 Returns for YAG OD but reports VA no better since YAG OS.
- BVA OS – 20/400
- SLE – shows normal anterior segment with open capsule
- Fundus – CME OS

ETP – YAG #11

- Sample Durezol qid OS
- Cancel YAG OD
- Refer to retina (saw her same day)
- Retinal eval:
- Trace CME OD, VMA + CME OD
- Continue Durezol add ketorolac
- Follow up 4-6 weeks

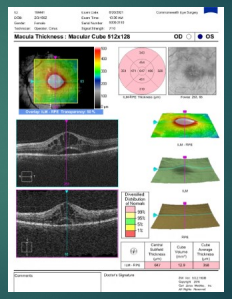

ETP – YAG #11 Take Home

- CME post YAG treated same as post CE.
- May involve retinal sub. We did in this case because of degree of CME.
- Consider delay second eye YAG (or CE) until first eye clear.
- Prophylactic treatment of fellow eye for YAG.

ETP – YAG #12

- M.W. (101443) 67 yoF
- Phaco + IOL OD 7/23/20 (NEAR)
- OS 8/24/20
- 11/12/21 – Returns for decreased vision OU, YAG eval.
- BVA – OD 20/50 BAT 400
- OS 20/40 70
- SLE – IOL with PCO OU
- YAG OD – 65 shots, 3.6 mJ

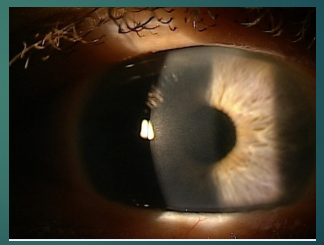

ETP – YAG #12

- 11/16/21 – OD red, swollen, aches and vision blurred. Was started on pred acetate q2h. Redness and swelling better but discomfort continues.
- BVA – 20/50, J3
- SLE – stromal cells OD
- TA – 18, 16 mmHg
- Tx – stop pred and resume PGB q2h x 2 days then qid
- RTC 3 days



ETP – YAG #12

- 11/19/21 – Reports vision a little better but has to strain to read.
- BVA – 20/30, J1
- SLE – stromal cells remain but improved
- TA – 18 mmHg
- Tx – Continue PGB qid.
- RTC 4-6 days

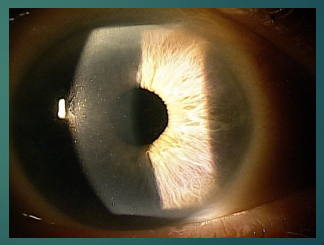

ETP – YAG #12

- 11/23/21 – Vision is better but not as good as before YAG.
- BVA – 20/50, J2
- SLE – stromal cells much improved
- Tx – Taper PGB bid x 4 days, qd x 4 days
- RTC 1 week
- 12/2/21 – NO SHOW

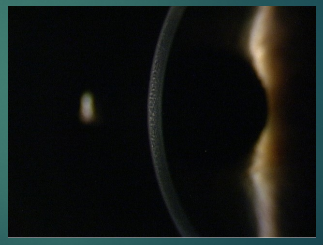

ETP – YAG #12

- Take Home

ETP – YAG #13

- M.B. (46162) 73 yoF
- Phaco + IOL OD 4/6/09
- OS 4/27/09
- Returns for YAG
- 1/8/13 YAG OD – 81 takes,1.0mJ
- 12/17/12 OS – 106, 1.0 mJ
- Note capsular runout

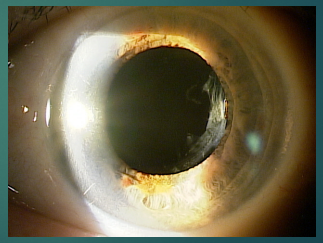

ETP – YAG #13

- Take Home
- If the capsulotomy extends past the edge of the IOL then vitreous can migrate into the posterior and anterior chamber and increase risk of …

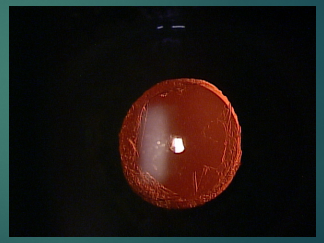

ETP – YAG #13 (**)

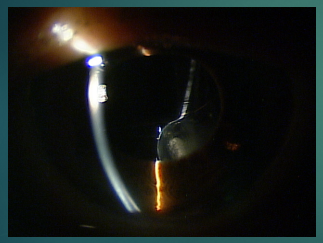

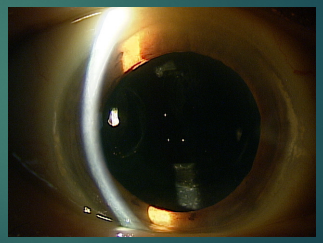

ETP – YAG #13

- Vitreous in AC
- Other fish to fry

"Ya'll Come Back Now, Ya Hear"