


Optometric
Education
Consultants




OCT Interpretation

Red, Yellow, and Blue Disease, What is Real Disease, and What is Physiologically Normal?

Greg Caldwell, OD, FAAO

Mackinac Island Northern Escape
Optometric Education Consultants
Sunday, August 20, 2023




2

Disclosures- Greg Caldwell, OD, FAAO

All relevant relationships have been mitigated

- The content of this activity was prepared independently by me - Dr. Caldwell
- Lectured for: B&L, BioTissue, Dompe, Santen
 - Disclosure: Receive speaker honorariums
- Advisory Board: Dompe, Tarsus
 - Disclosure: Receive participant honorariums
- I have no direct financial or proprietary interest in any companies, products or services mentioned in this presentation
 - Disclosure: Non-salaried financial affiliation with Pharmanex
- Envelope: PA Medical Director, Credential Committee
- Healthcare Registries – Chairman of Advisory Council for Diabetes and AMD
- The content and format of this course is presented without commercial bias and does not claim superiority of any commercial product or service
- Optometric Education Consultants – Scottsdale, AZ, Pittsburgh, PA, Sarasota, FL Barcelona, Spain, Orlando, FL, Mackinac Island, MI, Quebec City, Canada, and Nashville, TN- Owner




3

Disclosures- Greg Caldwell, OD, FAAO

All relevant relationships have been mitigated

Concepts discussed in this lecture can be applied to any OCT platform

The content and format of this course is presented without commercial bias and does not claim superiority of any commercial product or service



4

Financial Obligations



5

My Practice

- I am a clinician first then a scientist
- Some are scientists first then clinician
- I need to simplify for patient and patient care.
- Science is great, but not good if there isn't a clinical application.
- Some lectures are science based without clinical application.
- My lecture will be a hybrid. Showing clinical applications of the science

It is wonderful to have someone who's juggling so many aspects of optometry [scientific, clinical experience, teacher & lecturer]. It is refreshing and very informative. -Sarah





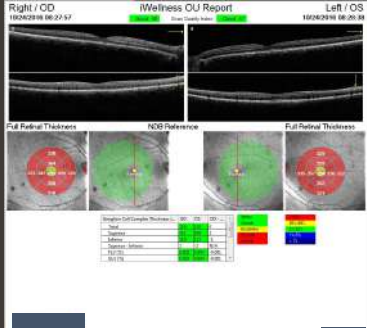

6

Question

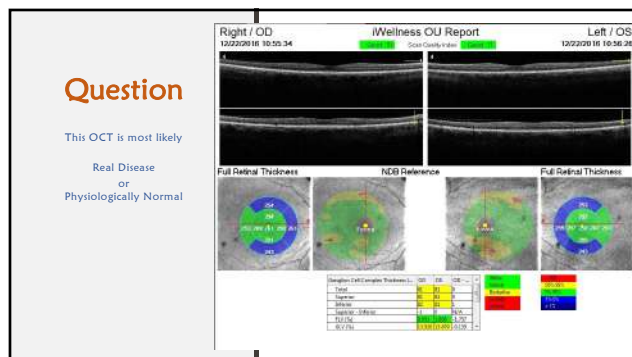
This OCT is most likely

Real Disease

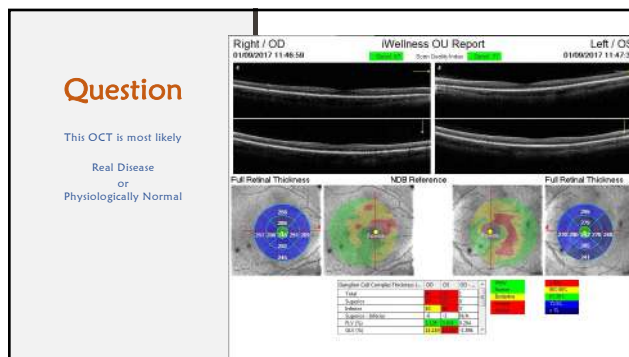
Physiologically Normal



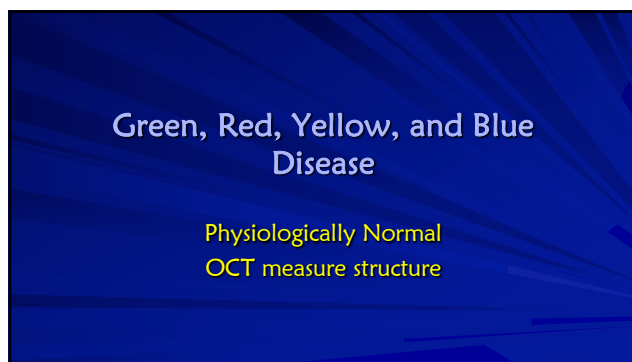
7



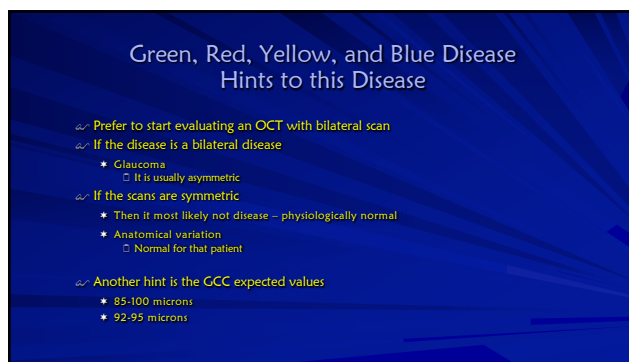
8



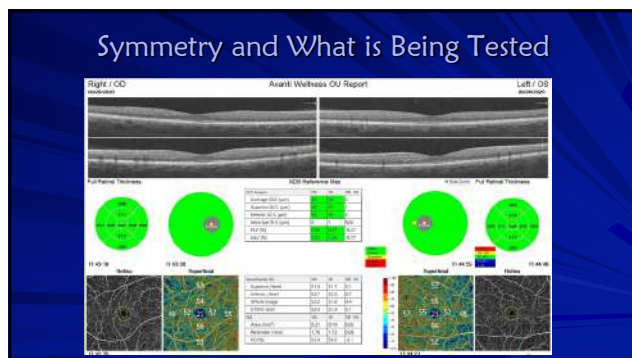
9



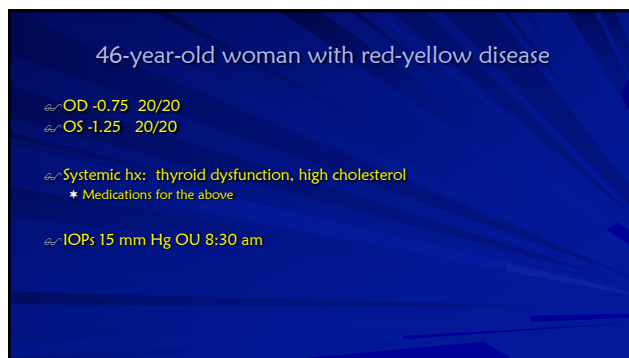
10



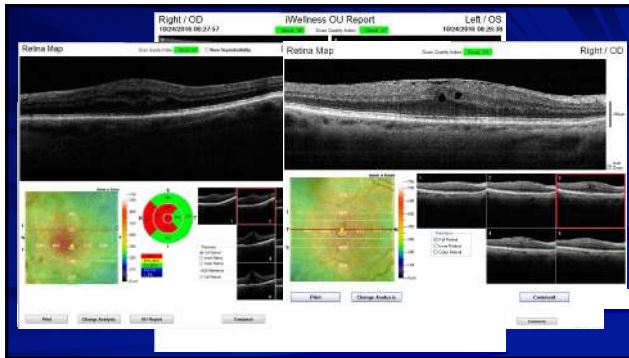
11



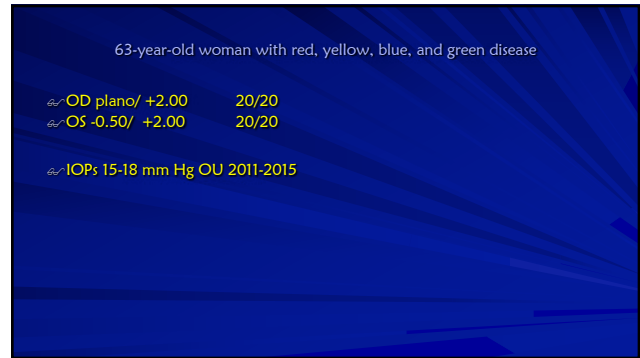12



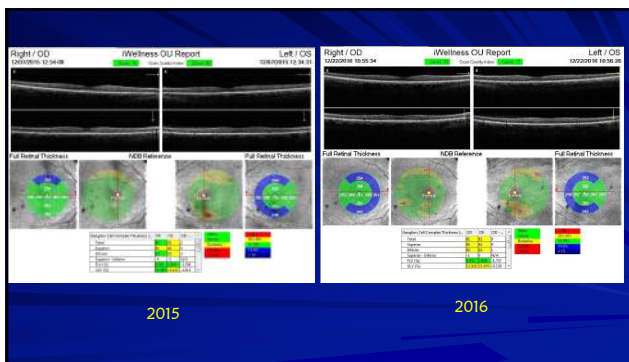
13



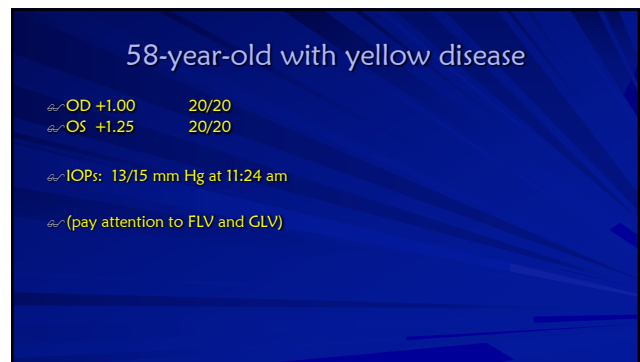
14



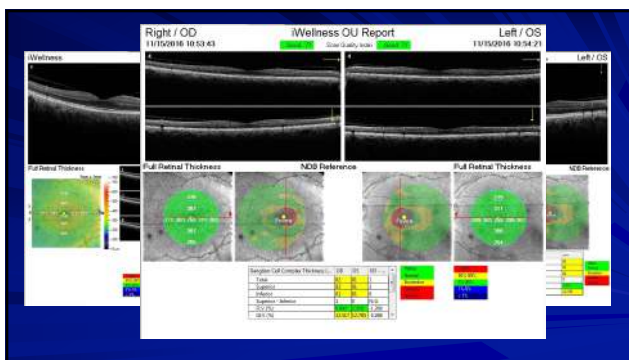
15



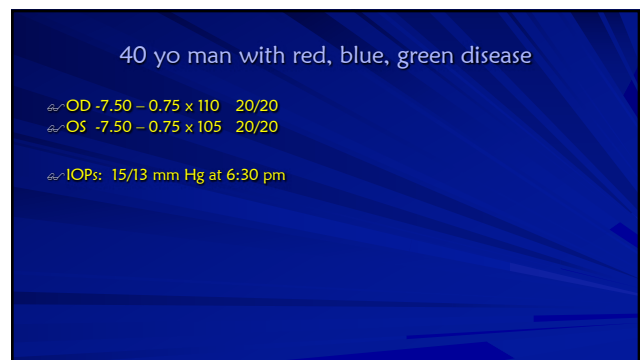
16



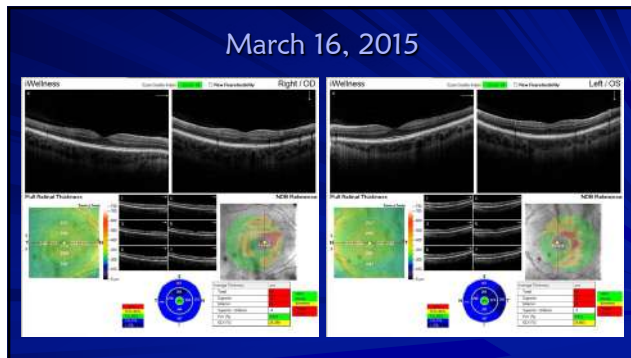
17



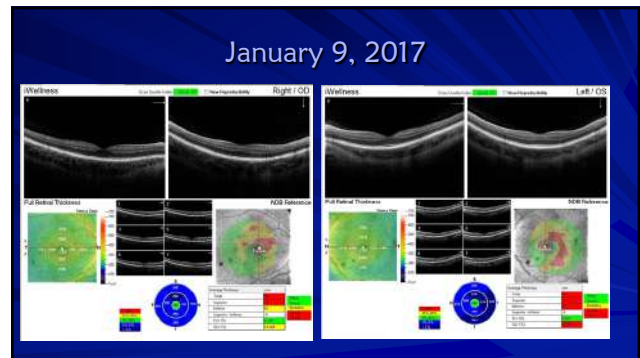
18



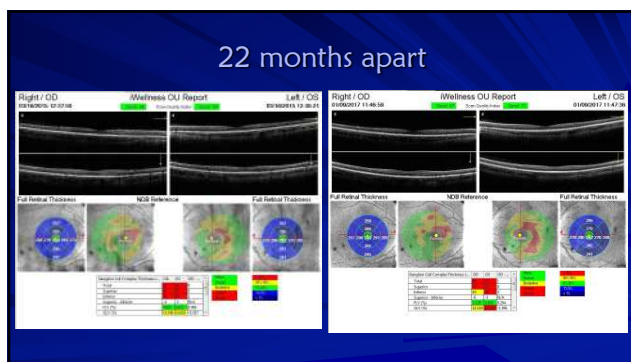
19



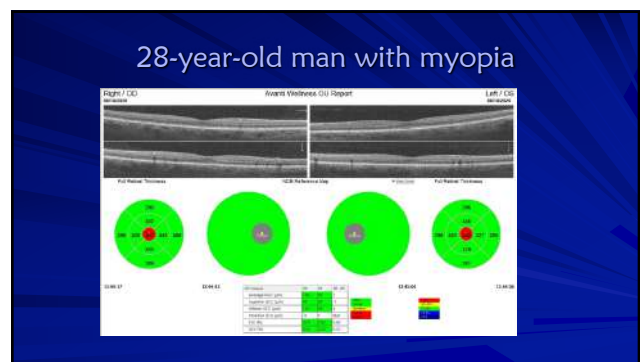
20



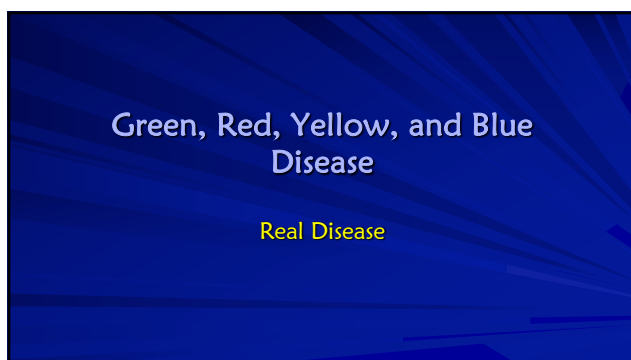21



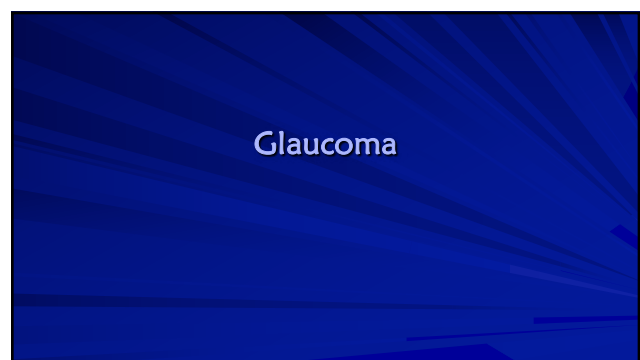
22



23

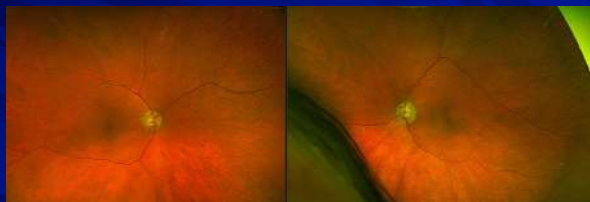


24

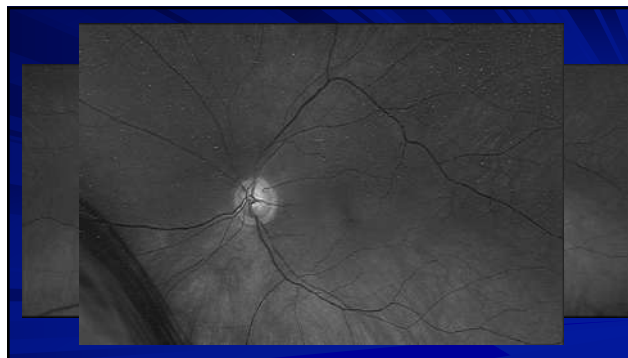


25

Where does glaucoma damage the NRR of the ONH?

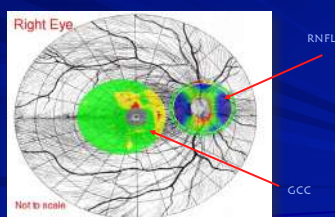


26



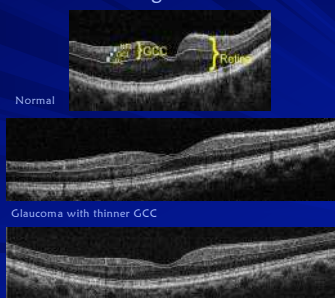
27

Overlay of the RNFL and GCC



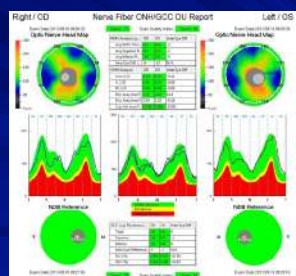
28

GCC Thinning in Glaucoma

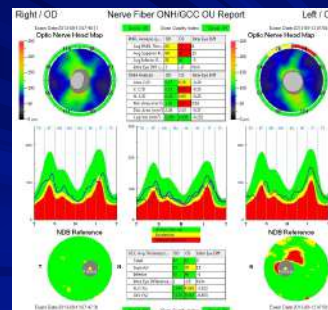


29

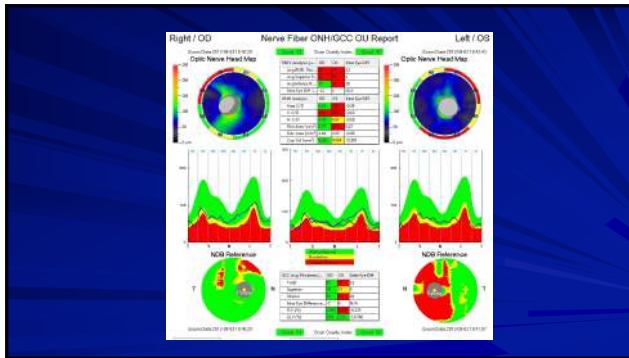
NFL and GCC



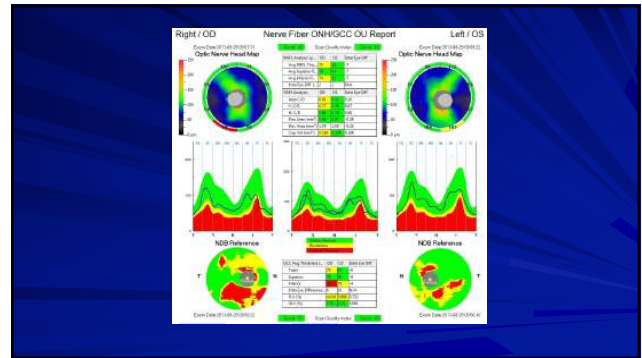
30



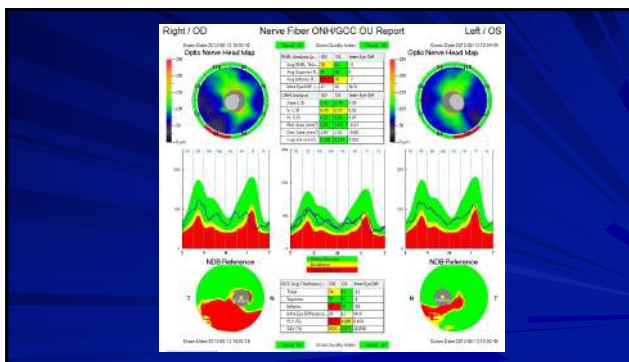
31




32



33



34



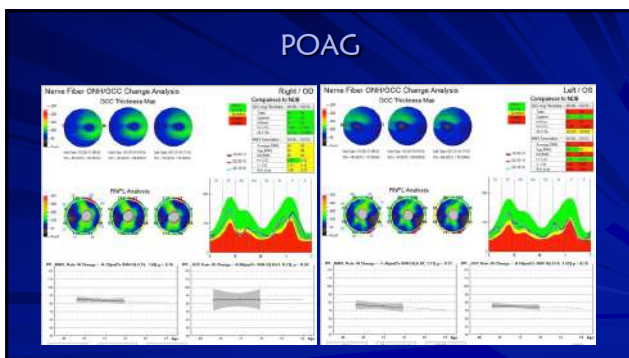
Optometric
Education
Consultants

Question

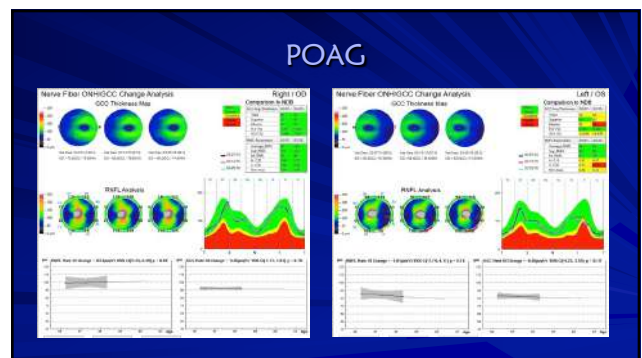
Which measurement on the OCT for glaucoma assessment will typically be more accurate?

- A. Nerve Fiber Layer - NFL
- B. Ganglion Cell Complex - GCC

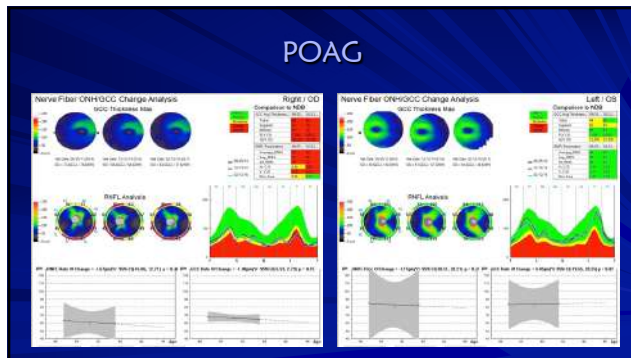
35



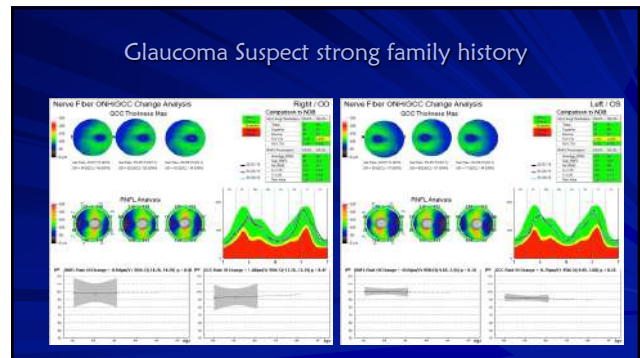
36



37



38



39

Question

Which part of the eye is most likely to change due to age?

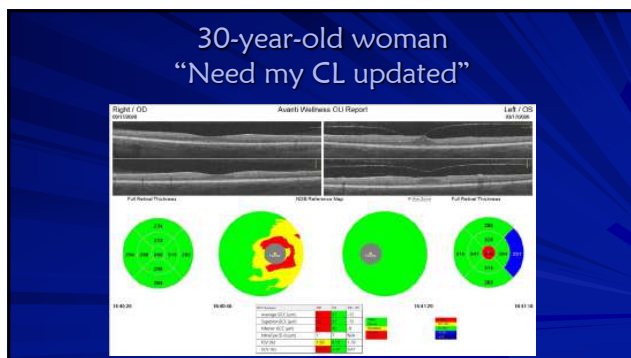
- A. Cornea
- B. Retina
- C. Vitreous
- D. Optic Nerve

40

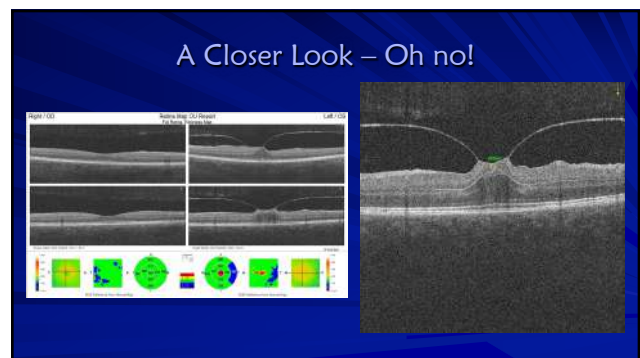
Question

Which eye is most abnormal?

41

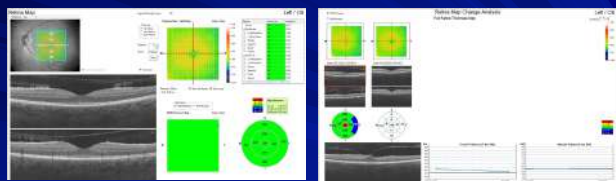


42



43

Phew – Lucky! June 16, 2020



44

The International Vitreomacular Traction Study Group Classification of Vitreomacular Adhesion, Traction, and Macular Hole

Main Outcome Measures: Optical coherence tomography-based anatomic definitions and classification of vitreomacular adhesion, vitreomacular traction (VMT), and macular hole.

Results: Vitreomacular adhesion is defined as perifoveal vitreous separation with remaining vitreomacular attachment and unperturbed foveal morphologic features. It is an OCT finding that is almost always the result of normal vitreous aging, which may lead to pathologic conditions. Vitreomacular traction is characterized by anomalous posterior vitreous detachment accompanied by anatomic distortion of the fovea, which may include pseudocysts, macular schisis, cystoid macular edema, and subretinal fluid. Vitreomacular traction can be subclassified by the diameter of vitreous attachment to the macular surface as measured by OCT, with attachment of 1500 µm or less defined as focal and attachment of more than 1500 µm as broad. When associated with other macular disease, VMT is classified as concurrent. Full-thickness macular hole (FTHM) is defined as a foveal lesion with interruption of all retinal layers from the internal limiting membrane to the retinal pigment epithelium. Full-thickness macular hole is primarily if caused by vitreous traction or secondary if directly the result of pathologic characteristics other than VMT. Full-thickness macular hole is subclassified by size of the hole as determined by OCT and the presence or absence of VMT.

Conclusions: This classification system will support systematic diagnosis and management by creating a clinically applicable system that is predictive of therapeutic outcomes and is useful for the execution and analysis of clinical studies.

45

VMA versus VMT Focal or Broad Attachment

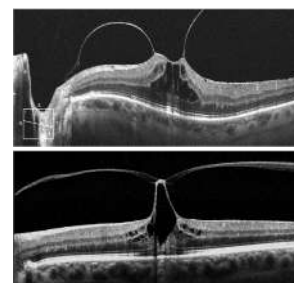
Table 4. The IVDV Classification System for Vitreomacular Adhesion, Traction, and Macular Hole

Attachment from	IVDV Classification System for Vitreomacular Adhesion, Traction, and Macular Hole
VMA	<p>Definition: Existence of perifoveal vitreous vitreous detachment from the retinal surface. Vitreous attachment of the vitreous surface within a 5-mm radius of the fovea. No lamellar change in broad contact or underlying retinal tissue.</p> <p>Classification: By size of attachment area: Focal (<1500 µm) Broad (≥1500 µm, profiled in RPE and may include some of adjacent) By presence of concurrent retinal conditions: Isolated Concurrent</p>
VMT	<p>Definition: Existence of perifoveal vitreous vitreous detachment from the retinal surface. Vitreous attachment of the vitreous surface within a 5-mm radius of the fovea. Disruption of macular architecture and distortion of the foveal surface (internal/external macular schisis) and/or elevation of the foveal tissue.</p> <p>Classification: By size of attachment area: Focal (<1500 µm) Broad (≥1500 µm, profiled in RPE and may include some of adjacent) By presence of concurrent retinal conditions: Isolated Concurrent</p>

46

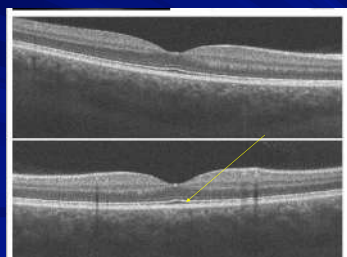
Question

Which eye has the better visual prognosis?



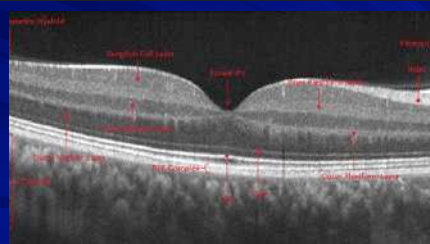
47

What is this layer called?



48

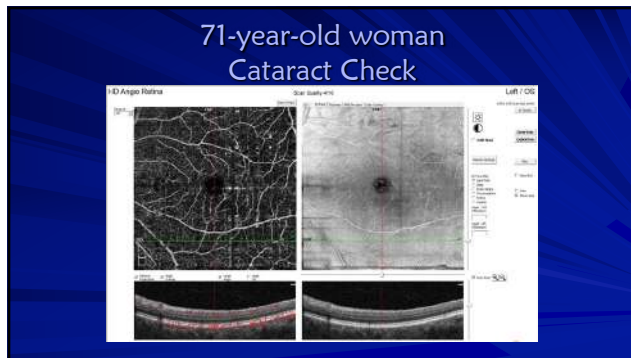
The ellipsoid zone (EZ) is considered to be formed mainly by mitochondria within the ellipsoid layer of the outer portion of the inner segments of the photoreceptors. However, it was previously known as the junction between the photoreceptor IS/OS.



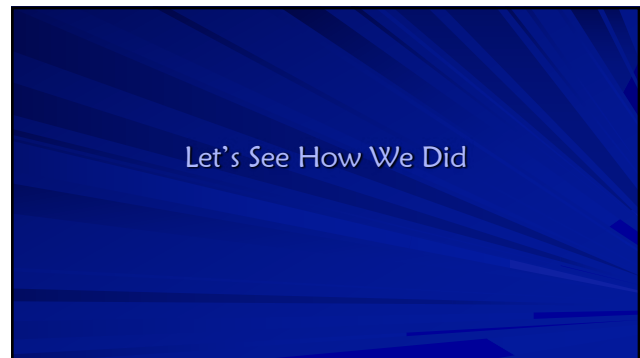
49



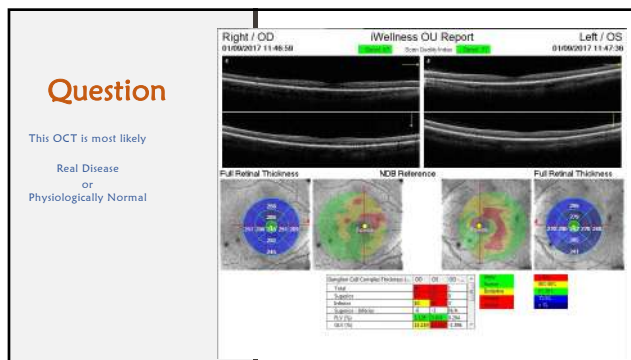




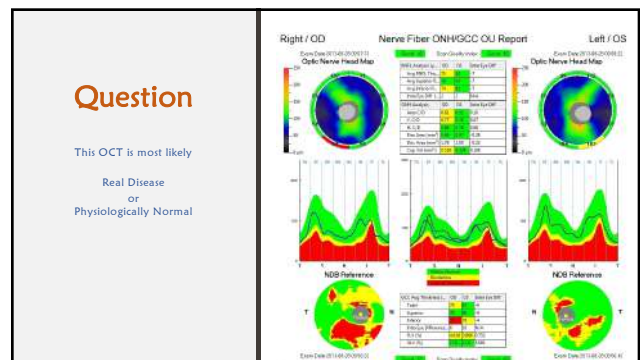
62



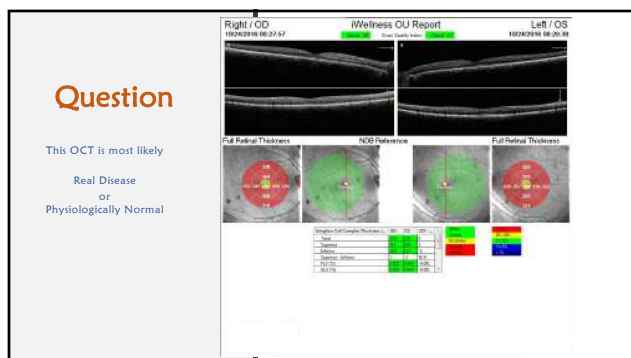
63



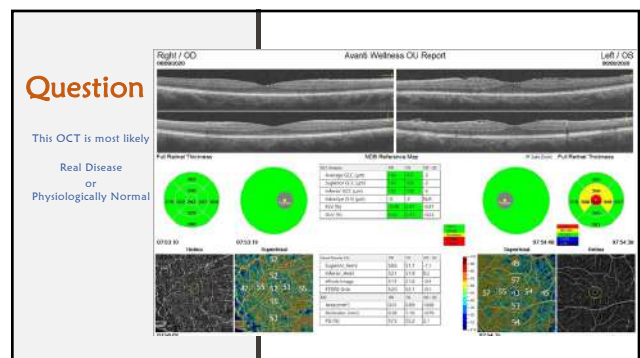
64



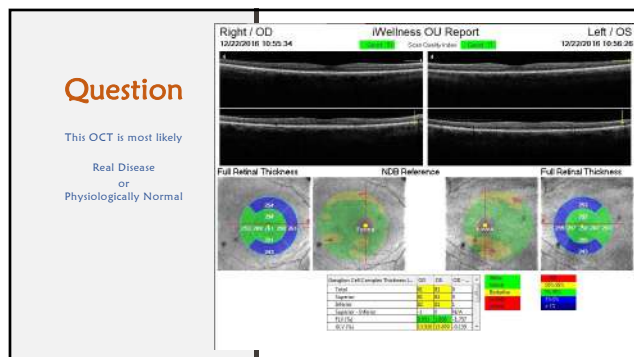
65



66



67



68

Green, Red, Yellow, and Blue Disease Hints to this Disease

- ⚡ Prefer to start evaluating an OCT with bilateral scan
- ⚡ If the disease is a bilateral disease
 - Glaucoma
 - It is usually asymmetric
- ⚡ If the scans are symmetric
 - Then it most likely not disease – physiologically normal
 - Anatomical variation
 - Normal for that patient
- ⚡ Another hint is the GCC expected values
 - 85-100 microns
 - 92-95 microns

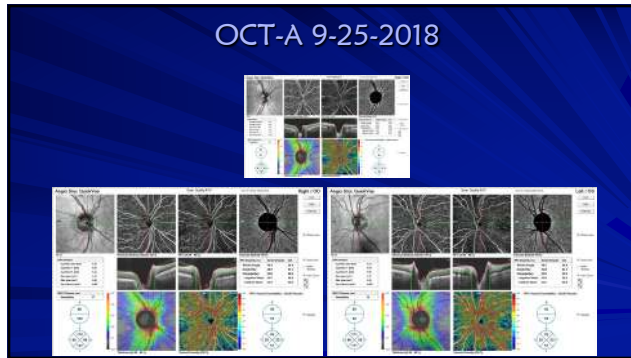
69

A Few Cases to Pull it Together

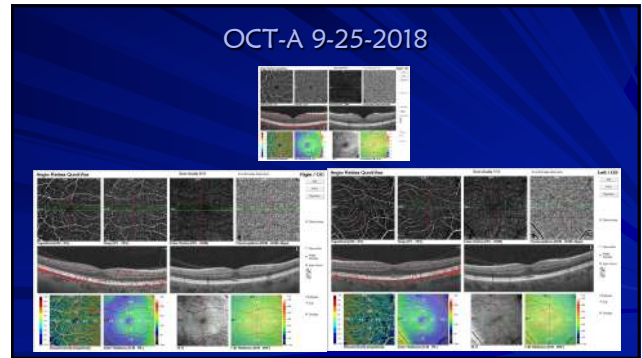
70

54-year-old man

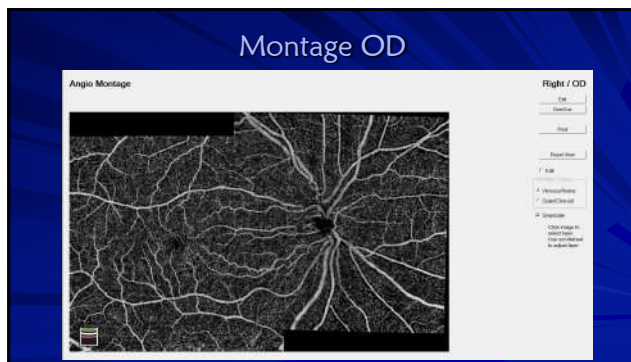
- ⚡ Ocular Hypertension since 2014
 - No treatment
- ⚡ Pigment Dispersion
- ⚡ Baseline IOP or Tmax 26/26
 - 2014 – March 2018
- ⚡ Today 30/32, new Tmax 9-25-18



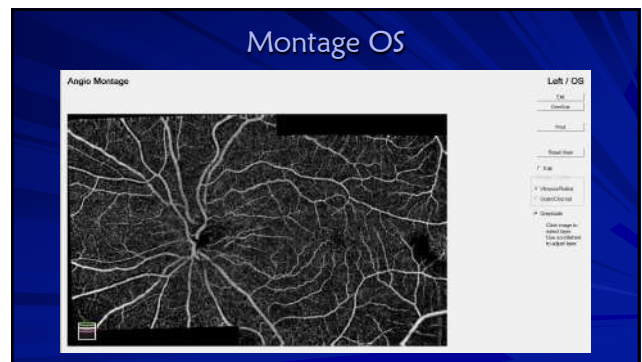
74



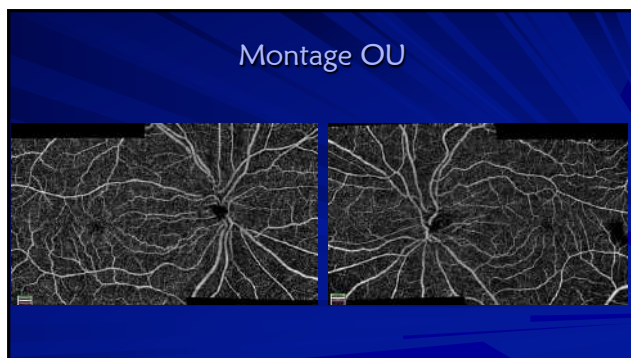
75



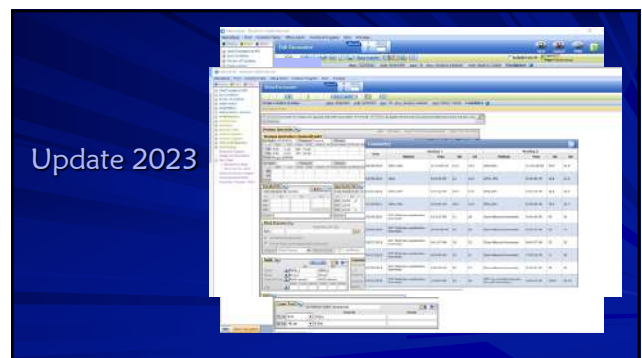
76



77

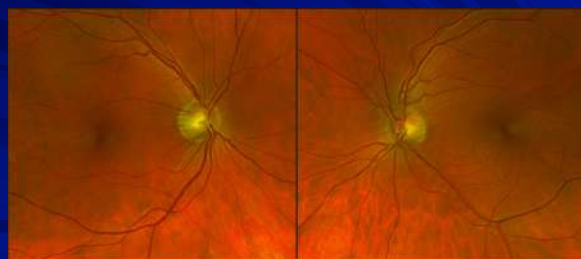


78



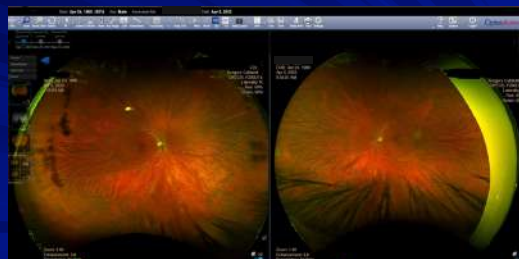
79

March 29, 2021



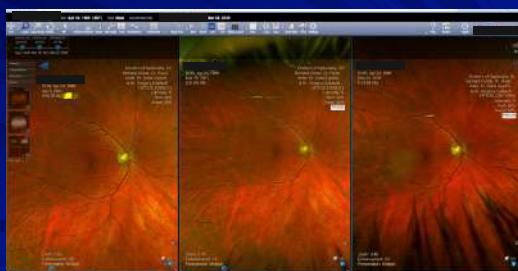
80

April 5, 2023



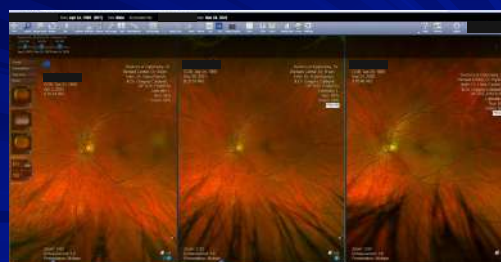
81

2020- 2023



82

2020-2023



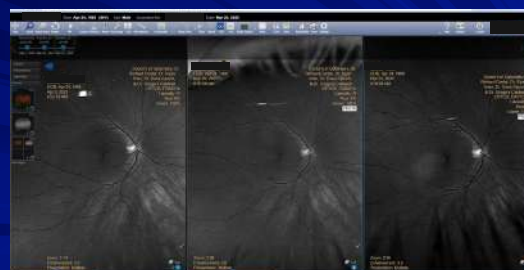
83

March 29, 2021



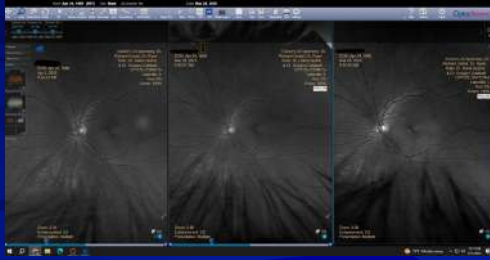84

2020 -2023




85

2020 -2023




86

June 28, 2023

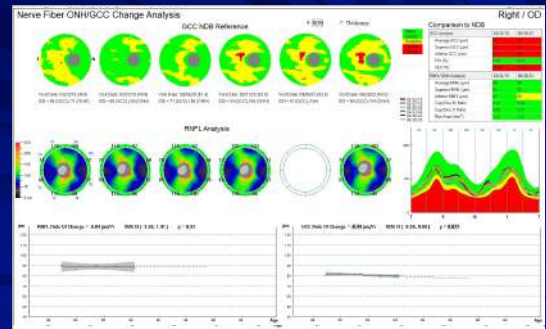


87

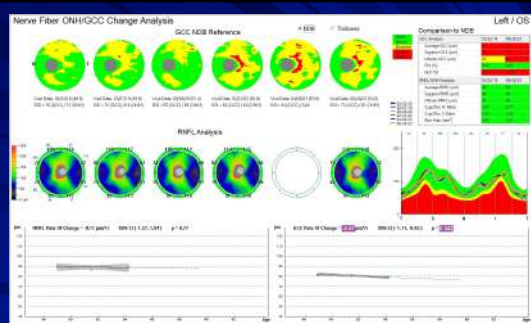
2018 - 2023



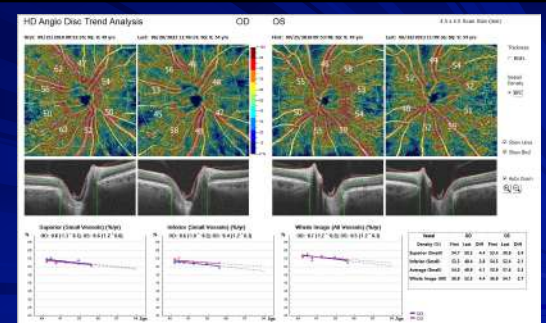
88



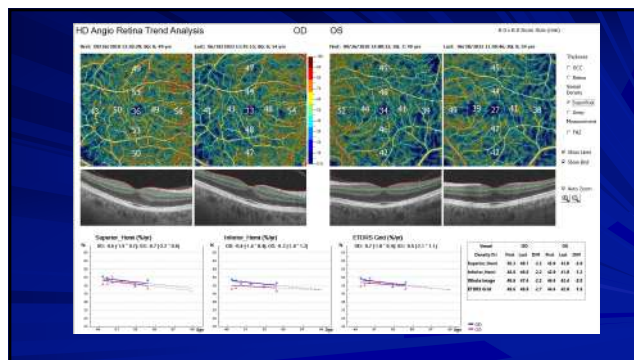
89



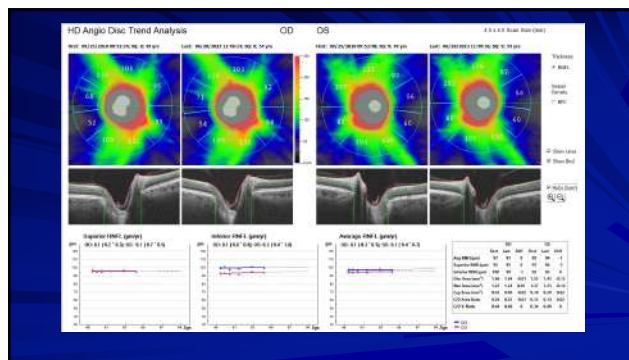
90



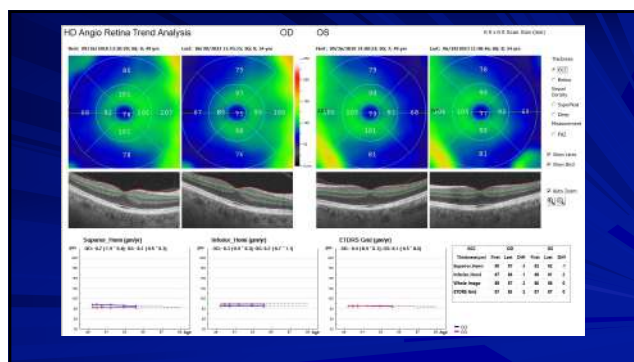
91



92



93

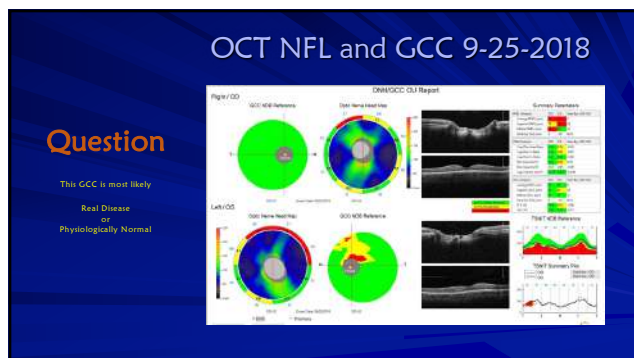


94

IOPs 38 and 32

- Ocular hypertension versus glaucoma reviewed with patient
- OCT results reviewed with patient
- Patient elects to monitor
 - * RTC in 4 months for IOP ck and Visual Field 24-2 OU

95



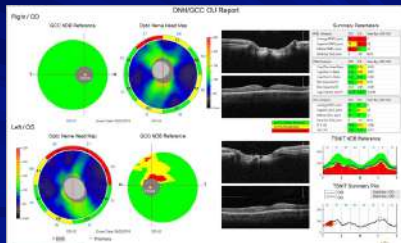
96

79-year-old man

- POAG, OS > OD
- Lumigan 0.01% QD OU
- Combigan BID OU
- Changed to Cosopt (generic)
 - * June 2020 due to insurance
 - * Did get


97

OCT NFL and GCC 9-25-2018



98

VF OD and OS 1-26-2018




99

VF OD and OS GPA 1-26-2018



100

March 22, 2023



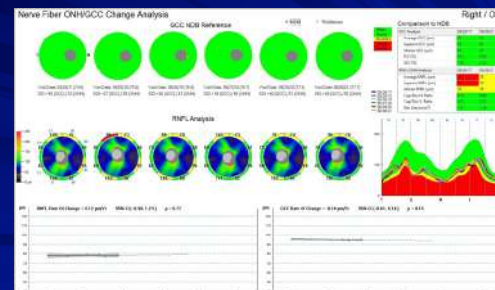
101

12-03-2010 to 3-22-2023




102

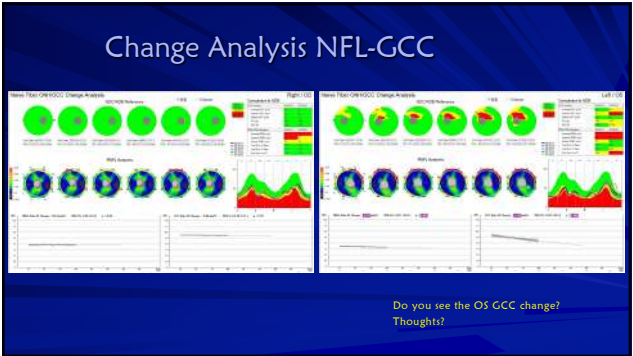
Update 2021- June 8, 2021



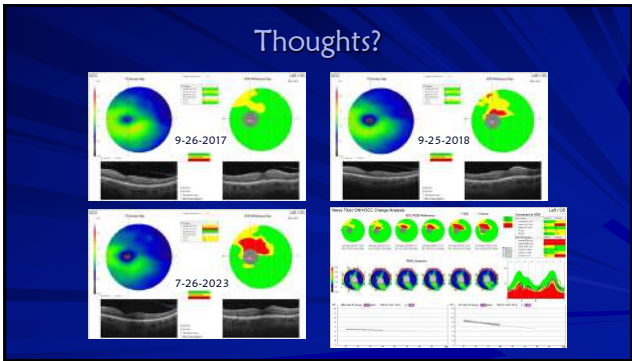
103



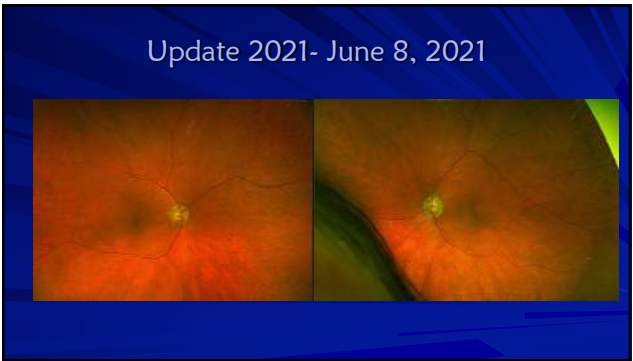104



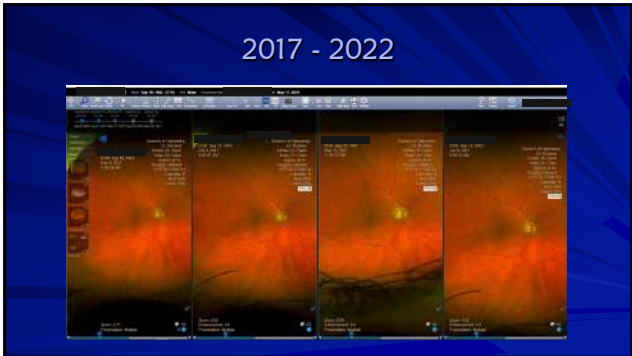105



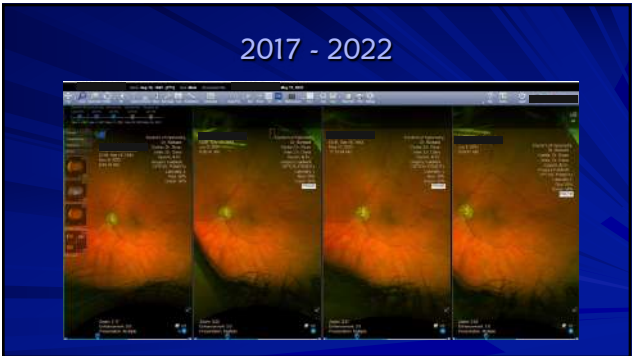106



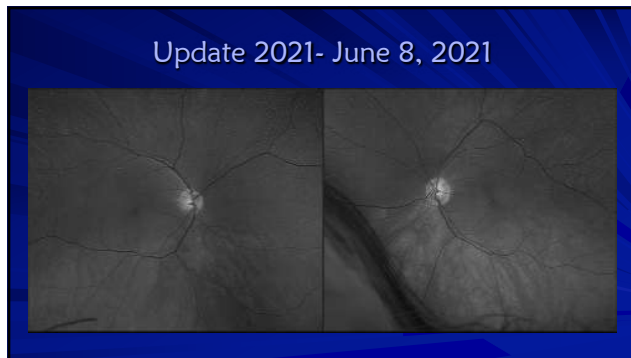
107



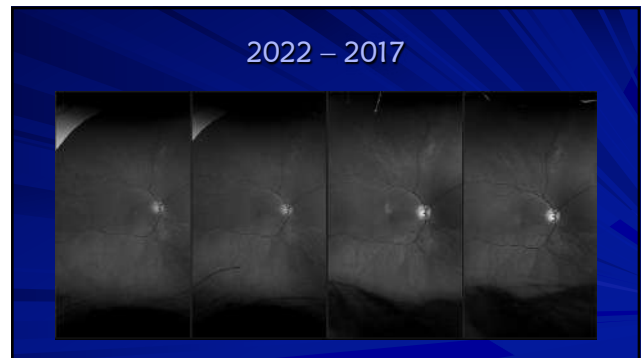
108



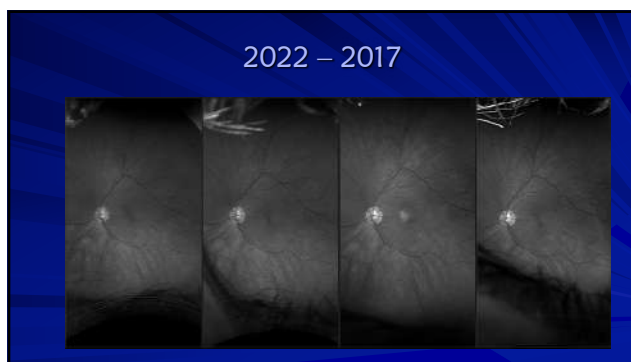
109




110



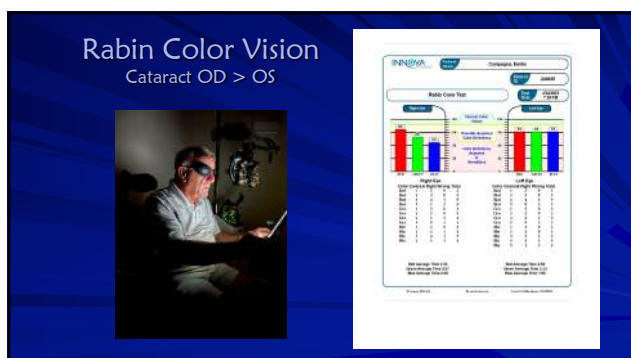111



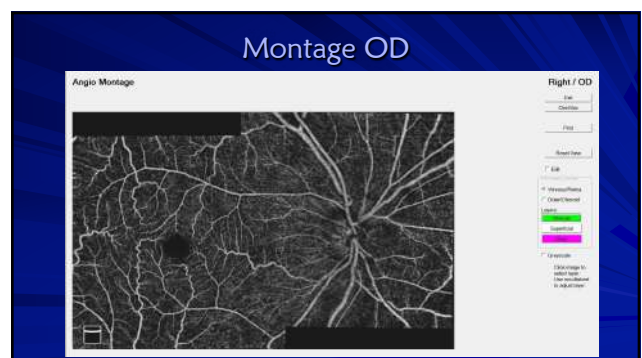112



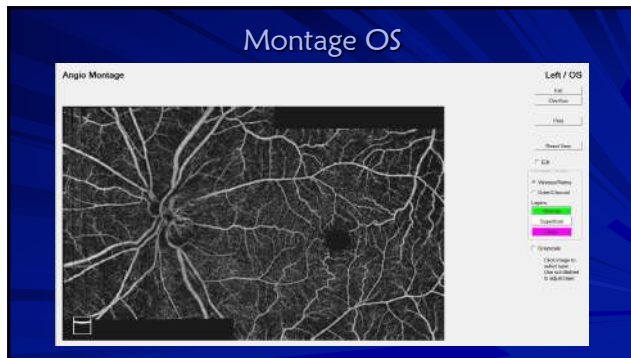
113



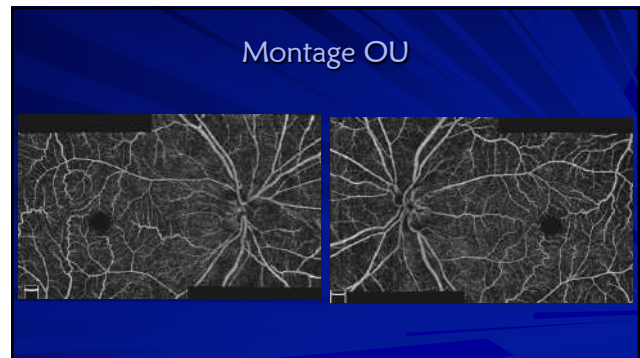
114



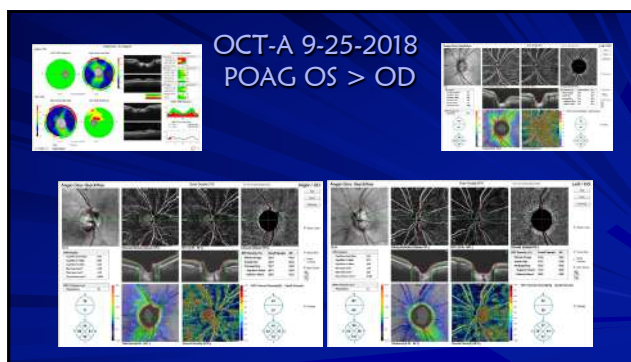
115



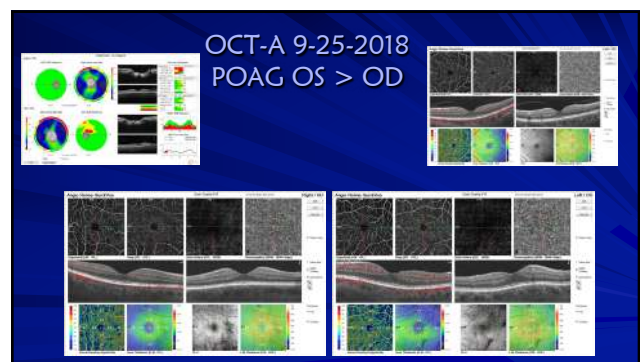
116



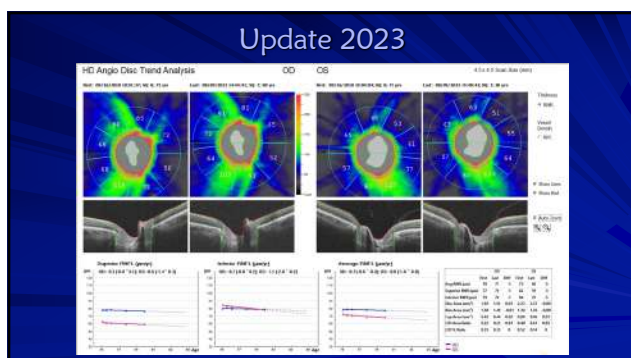
117



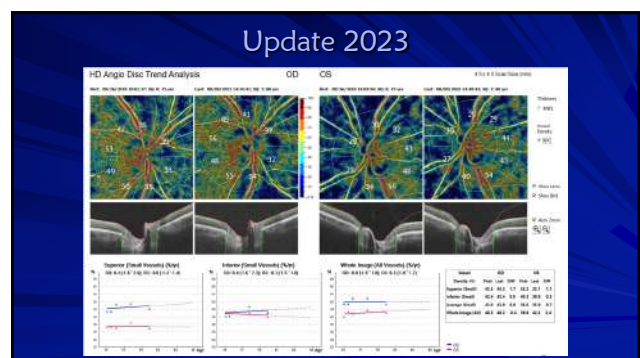
118



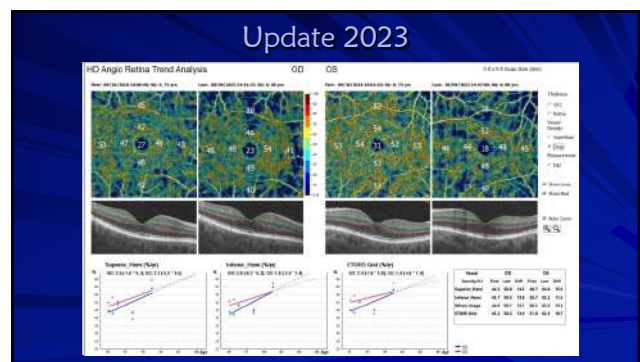
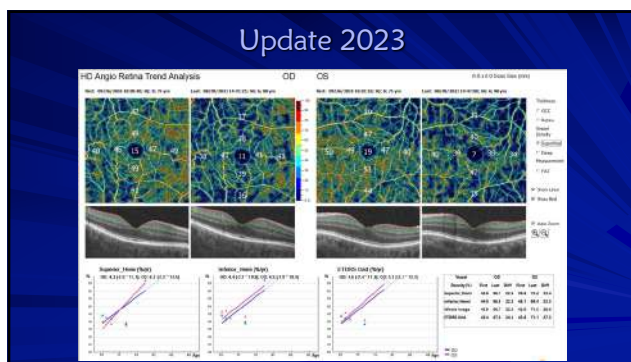
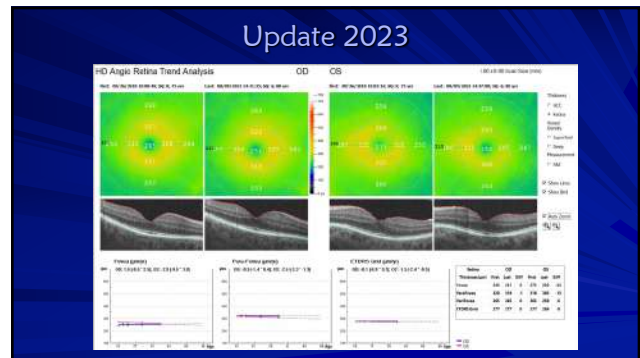
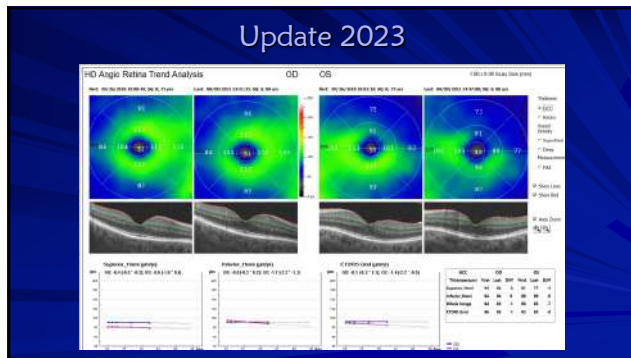
119



120



121





Optometric
Education
Consultants

Questions and Thank You!

OCT Interpretation

Red, Yellow, and Blue Disease, What is Real Disease, and What is Physiologically Normal?

Greg Caldwell, OD, FAAO

Mackinac Island Northern Escape
Optometric Education Consultants

Sunday, August 20, 2023

