


US EYE

NAVIGATING NEURO-OP: NIGHTMARES AND NONSENSE

Joseph Sowka, OD, FAAO, Diplomate

US EYE

DISCLOSURE:

- Joseph Sowka, OD, in the past 24-months, has been a Consultant/ Speaker Bureau/ Advisory Board member for B&L. Dr. Sowka has no direct financial interest in any of the diseases, products or instrumentation mentioned in this presentation. All relevant relationships have been mitigated. He is a co-owner of Optometric Education Consultants (www.optometricedu.com)

Optometric Education Consultants

The ideas, concepts, conclusions and perspectives presented herein reflect the opinions of the speaker; he has not been paid, coerced, extorted or otherwise influenced by any third party individual or entity to present information that conflicts with his professional viewpoints.

US EYE

WHY DO NEURO-OP?

US EYE

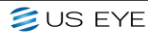NEURO-OP IS A FINANCIALLY REWARDING SPECIALTY


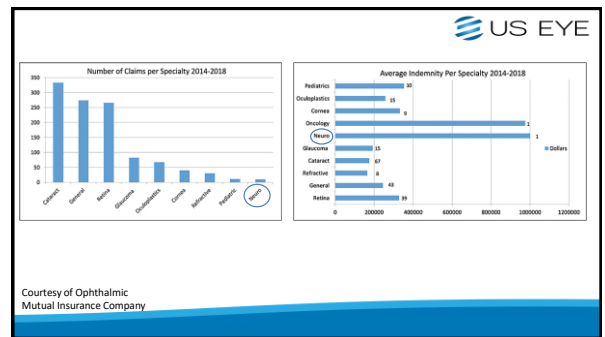




US EYE

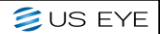NEURO-OP IS A FINANCIALLY REWARDING SPECIALTY...SAID NOBODY EVER






Neuro-Op

- Not enough neuro-ophthalmologists
 - 45 fellowship spots; only 25 filled
- High risk
- Is this urgent? Can it wait?
- Complicated
- Diagnose and Adios
- Schedule-busting

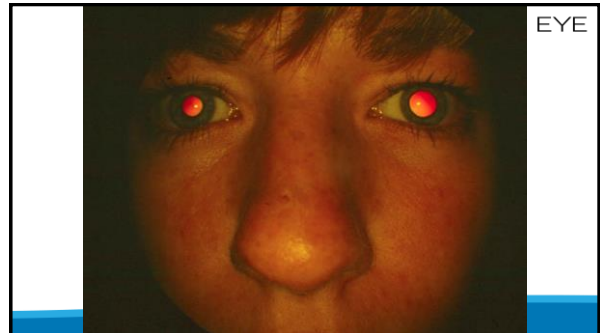

NIGHTMARE OR NONSENSE?



- 23 YOF: Sudden onset pupil dilation with ipsilateral headache
- Medical Hx: normal
- BVA: 20/20 OD, OS
- Pupils:
 - 3 mm anisocoria, OS larger, anisocoria greater in bright illumination. Previously isocoric. (-) RAPD, (+) Accom
- Remainder of exam normal
 - No double vision, ptosis, no medication use
- Similar incident 2 days antecedent, resolved within hours

EYE



BENIGN EPISODIC PUPILLARY MYDRIASIS



- Episodic unilateral mydriasis
 - Lasts minutes to weeks
- Accompanied by blurred vision and headache
- Young, healthy females (*may have migraine history*)
- Peculiar sensations about affected eye
 - Often progresses to headache
 - Not typical migraine
- Defective accommodation
- Lid and motility defects not present
- Extensive medical testing unremarkable

BENIGN EPISODIC PUPILLARY MYDRIASIS



- Increased sympathetic activity?
 - Reverse Horner's syndrome – not likely
- Pupil paralysis following migraine?
 - Tends to last longer – not likely
 - No ophthalmoplegia
- Spasm of segment(s) of iris dilator muscle?
 - Round pupil, so not likely
- Pharmacologically dilated?
 - Parasympatholytic – no light or near reactivity
 - Sympathomimetic – can mimic and must R/O

BENIGN EPISODIC PUPILLARY MYDRIASIS

- Anisocoria greater in bright than dim
 - Parasympathetic dysfunction
 - Not an aneurysm
 - Edinger-Westphal lesion?
- Migraine variant – most likely etiology
- Treatment – none except to avoid unnecessary testing

Pupil Rules

- Anisocoria greater in dim = sympathetic dysfunction
 - Horner's syndrome- look for dilation lag
 - Miotic use
- Anisocoria greater in light = parasympathetic dysfunction
 - CN 3 palsy
 - Tonic pupil
 - Pharmacologic or traumatic pupil
 - No reactivity?

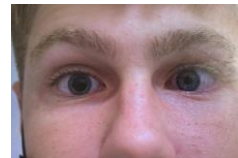Pupil Rules

- Fixed and dilated and unresponsive to light or near = pharmacologic or iris trauma
- Isolated dilated pupil with no ptosis or motility deficit is not an emergency or urgency



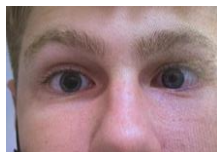Pupil problem

- 14 year old male
- Onset if blurred vision OD in school
- Classmate notes dilated pupil
- Motility fine
- Mild headache
- Goes to school nurse- calls parent
- In ER until midnight
- CT head normal



Pupil problem

- Pupil fixed and dilated
- Unresponsive to light and near
- Medical hx:
 - Recently sampled Qbrexza (glycopyrronium)
 - Anticholinergic indicated for topical treatment of primary axillary hyperhidrosis in adult and pediatric patients 9 years of age and older



ADVERSE REACTIONS:
Most common adverse reactions (incidence ≥5%) are dry mouth, dry eyes, nasal dryness, dry throat, dry skin, constipation. Local side reactions: headache, dizziness, burning/stinging and pruritus were also common (≥5%) [6, 7].

RULE: ISOLATED DILATED PUPIL IS ALMOST NEVER AN ANEURYSM

Ambulatory patients with isolated dilated pupil more likely to harbor iris or ganglion (Adie's) lesion or medication misadventure than CN 3 palsy

Comatose patient is a different story

Risk of angiography is much higher than risk of aneurysm in this setting

No imaging needed

Nightmare or nonsense?



- 78 YOM- Acute onset diplopia, blurred vision, and dilated pupils
 - Went to ED-worked up for stroke
 - CT/CTA/MRI/MRI all normal
 - Reviewed reports-everything in order
- Referred by colleague after exam
 - Vision improving, pupils less dilated, endpoint nystagmus, non-specific horizontal diplopia
- Pt on anti-muscarinic for bladder

NIGHTMARE OR NONSENSE? 78 YOM



- Acute onset diplopia, blurred vision, and dilated pupils
 - Went to ED-worked up for stroke
 - CT/CTA/MRI/MRI all normal
 - Reviewed reports-everything in order
- Referred by colleague after exam
 - Vision improving, pupils less dilated, endpoint nystagmus, non-specific horizontal diplopia
- Pt on anti-muscarinic for bladder
- Mydriasis and blurred vision = ??
- What about that history?
- Outcome?



Take care with VES/care



- 56 YOF
- Treated glaucoma
- IOP suddenly in mid 30s with meds
- Bilateral blurred vision and dilated pupils

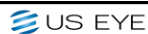Case of the curbside consult



- Conference focusing on neurological issues
- 48 YOF-wife of society president
- Complaints of memory loss and loss of smell and taste (Pre-COVID)
 - Fearful of neurodegenerative condition.
- Hx of tonsillectomy two months earlier
- Facial and persistent jaw pain
- Seen by multiple specialists (neuro, ENT, PCP)
- Put on multiple medications including at least 2 oral antibiotics
- Personal experience with Mucinex
- Outcome?



ITS NOT ALWAYS A BRAIN TUMOR. THINK ABOUT MEDICATION TOXICITY



Toxicities




- Blurred vision and dilated pupils
- Ethambutol
 - Toxic optic neuropathy
 - Follow every 1-2 months
- Amiodarone/ Pacerone
 - Toxic optic neuropathy
- Vigabatrin
 - Anticonvulsant for refractory focal epilepsy in children 2 years of age or older
 - May cause permanent, concentric peripheral visual field loss, thought to be secondary to drug-induced injury to both the retinal photoreceptors and the retinal ganglion cells and their axons.

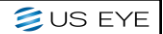NIGHTMARE OR NONSENSE?



- 94 YOM; referred for partial CN 3 palsy
- Already dilated by tech in another office
 - PERRL (-) RAPD?
- No pain
 - Never had a headache in his life
- Pacemaker; HTN; kidney disease



RULE



**Never dilate a patient
with cranial nerve III
palsy**

NIGHTMARE OR NONSENSE?




- Dx: Partial CN 3 palsy
 - with pupil sparing(?)
- Lack of pupil involvement and no head pain helpful in threat assessment
- Age 94 years
 - Male life expectancy US 2022: 80.1 years
- Needed imaging: CT/CTA and MRI/MRA
- Worked with ER
- Kidneys couldn't take contrast; Pacemaker precluded MR
- Only got brain CT- no bleed; "stroke"

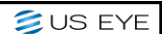One week follow up




- Now has progressed to complete CN 3 palsy



NIGHTMARE OR NONSENSE?

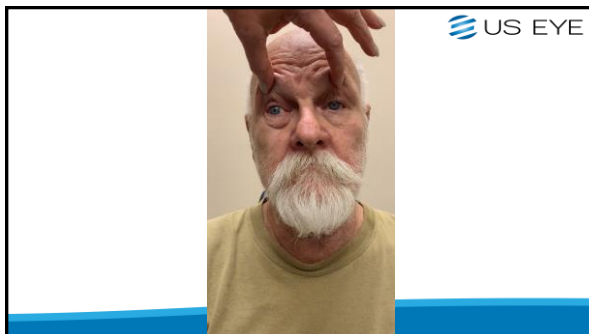



- Pt has ~~expectedly~~ progressed to complete pupil sparing CN 3 palsy
- Imaging insufficient but shows no hemorrhage
- Most likely ischemic-vascular and will be about 50% improved in 6 weeks and recovered around 12 weeks
- Will watch for aberrant regeneration



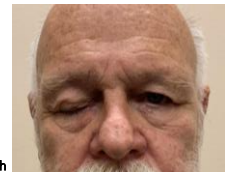
NIGHTMARE OR NONSENSE?

- 70 YOM: Sudden onset of retro-orbital pain followed by double vision x 1 week
 - Getting progressively worse
- + HTN, +DM, +hypercholesterol
- 20/30 OD, 20/20 OS
- Day before hurricane



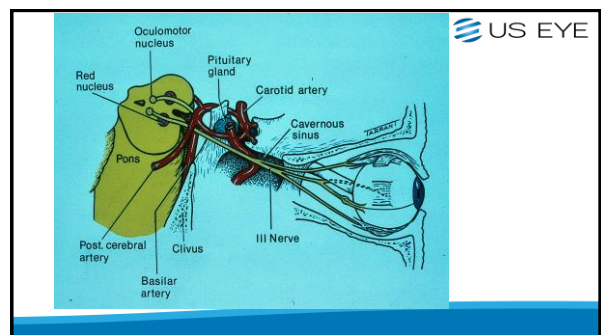
NIGHTMARE OR NONSENSE?



- Sudden onset of retro-orbital pain followed by double vision x 1 week
 - Getting progressively worse
- + HTN, +DM, +hypercholesterol
- 20/30 OD, 20/20 OS
- Day before hurricane
- Needed imaging:
- CT/CTA; MRI/MRA
- Presumptive DX: microvascular ischemia
- Imaging normal
 - 6 weeks- markedly improved; ptosis resolved; patch




CN III Palsy Clinical Picture

- An eye that is down and out with a ptosis
- Adduction, elevation, depression deficits
- Isocoric or anisocoric







- Pupil involved CN III palsy is posterior communicating (PCOM) aneurysm until proven otherwise- emergency
 - Needs ER STAT and admission
- Incomplete palsy is PCOM aneurysm until proven otherwise
 - Regardless of pupil
- 30% of CN III palsy are caused by aneurysm**
- Pain is pain
 - Only helpful when not present
- Vasculopathic CN III will resolve in time
- Life threatening posterior communicating aneurysm will rupture in time





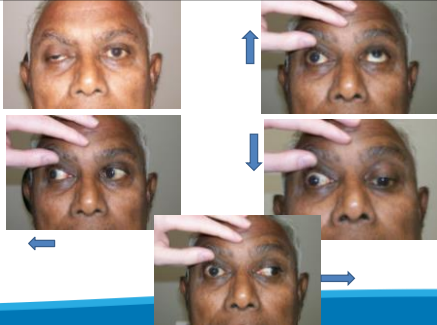
Rules for CN III palsy imaging

- High suspicion of aneurysm: DSA (gold standard)
- CT/CTA is preferred non-invasive imaging for CN III palsy
 - CT for SAH
- CTA requires contrast- renal impairment prefers MRI/MRA
- CTA superior to MRI when patient can't have MRI
 - Pacemaker, claustrophobia
- MRI superior for non-aneurysmal causes (tumor)
 - MRA adds very little time to scan
- Recent study shows majority of CN 3 palsy patients do not get the appropriate urgent imaging.




NIGHTMARE OR NONSENSE?

- 63 YOM: Sudden onset of orbital pain x 3 days
- + DM; +HTN
- On coumadin
- Pacemaker

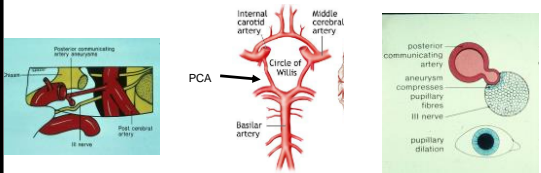


5 mm unresponsive 3 mm responsive



Dx: Right pupil involved CN 3 palsy from aneurysm

- 50% die from aneurysm rupture w/i 29 days
- 20% die within 48 hours
 - Needs emergency care and time counts- just send to ER?

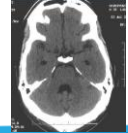

The diagram illustrates the Circle of Willis, a ring of arteries at the base of the brain. It shows the internal carotid artery, middle cerebral artery, anterior cerebral artery, posterior cerebral artery, and basilar artery. A posterior communicating artery aneurysm is shown compressing the oculomotor nerve (CN III), leading to pupillary dilation. Labels include: Internal carotid artery, Middle cerebral artery, Circle of Willis, PCA (Posterior communicating artery), Basilar artery, posterior communicating artery aneurysm, aneurysm compresses oculomotor fibres, III nerve, and pupillary dilation.

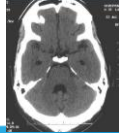
ER PHYSICIAN ENCOUNTERING A PATIENT WITH AN EYE PROBLEM



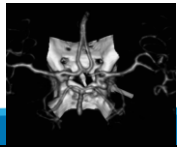
JUST BECAUSE THEY STICK THEIR HEAD IN A TUBE DOESN'T MEAN THAT THE CAUSE WILL BE FOUND



THE WORLD'S BEST NEURORADIOLOGIST CAN'T HELP YOU IF YOU DON'T ORDER THE SCAN, ORDER THE RIGHT SCAN, AND TELL THEM WHAT TO LOOK FOR.



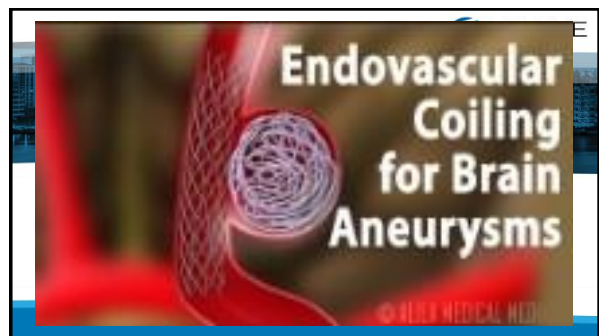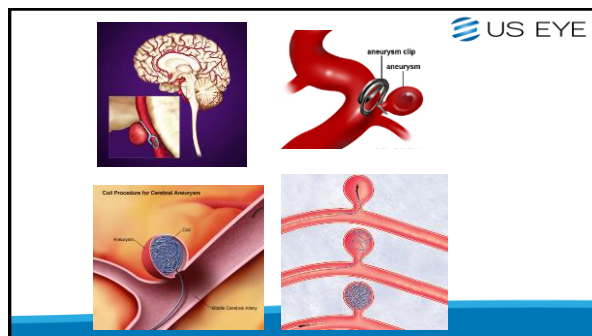
- Sent to ER with detailed notes, recommendations, and cell phone#. Called triage nurse in advance
 - Pupil involved right third nerve palsy
 - Most likely cause: intracranial aneurysm of posterior communicating artery
 - Needs CT/CTA/ neurosurgical consult STAT
 - Can't have MRI due to pacemaker
 - Was in scanner within 45 minutes
 - Leaking but unruptured aneurysm confirmed with CTA
 - Endovascular therapy with coils successful (2 procedures)
 - Hospitalized 23 days
 - Ptosis improved, motility and pupil didn't, but he *did* live



Pseudo-Von Graefe's sign
Secondary aberrant regeneration
Never diabetes

Still More Clues


- CN III palsy caused by aneurysm
 - 20% die within 48 hrs from rupture
 - 50% overall die
 - Average time from onset to rupture – 29 days
 - 80% rupture w/ 129 days
 - Many never make it to hospital
- Ruptured aneurysms
 - 5% surgical mortality
 - 60% functional impairment post-op
- Unruptured aneurysms
 - No mortality; 75% with normal outcomes; 50% with CN III recovery



US EYE

What to say to the ER doc

- Don't say, "This patient has double vision"
- Say, "This patient has an aneurysm of the posterior communicating artery and is going to DIE if he doesn't get to neurosurgery immediately!"



US EYE

Neuroimaging for the primary care OD

- Disclosure: I do not read MRIs (There are ODs that do- I'm not one of them)
 - What you don't know can hurt you a whole lot
 - That's the reason for residencies in radiology and subspecialties in neuroradiology
 - Thinking that I am as good is irresponsible (e.g. neuroradiologist identifying ciliary body on MRI)
- Rules for ECP: order the correct scan and read the report to ensure that the right thing was done
- If you have questions, doubts, or concerns, reach out to the radiologist
- Form a relationship with an imaging center- find out about the practice
 - Some have better results with MRA and others with CTA



US EYE

What to order

- Disc edema/suspect papilledema: Brain MRI with and without contrast looking for mass lesion, hydrocephalus, hemorrhage, flattened globe, empty sella; MRV looking for cerebral venous sinus thrombosis.
- Optic nerve/chiasmal disease: MRI orbits and chiasm with and without contrast with fat suppression
- Snowball in a snowstorm
- Optic neuritis/suspect MS: MRI orbits and chiasm with and without contrast with fat suppression; MRI brain with and without contrast (also need MOG and aquaporin antibodies, but that's another lecture)
- Homer Syndrome: Brain MRI with and without contrast; CTA (or MRA) head and neck looking for cerebral artery dissection; MRI chest with lung apex and brachial plexus
 - Homer protocol or sympathetic plexus
- Suspected aneurysm (CN 3 palsy): CTA/CT and MRA/MRI with concentration to Circle of Willis
 - If high risk aneurysm- send to ER and tell them what to do.
- Don't just send to the ER without helping them. They won't get it right.

83 YOM

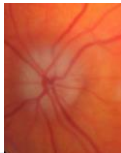- Diabetic; LBS in 300s;
- A1C around 11
- Pupils normal MRI ordered through PCP
- Indication for imaging: Brain ischemia
- What 2 errors were made here?

NIGHTMARE OR NONSENSE?



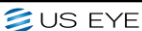- 64 YOF: Call from VRH ER physician (Friday 3 pm)
 - "Pt woke up blind OS, but has some improvement; has RAPD; head CT normal; can you please see her?"
- 20/25 OD, 20/30 OS; RAPD OS
 - 15 lbs weight loss, frontal/occipital headache, malaise
 - Blames everything on COVID



- Dx: AAION from GCA
- Back to ER with recommendations; called and cell#
 - ESR, CRP, Platelets
- Call back from ER
 - ESR 96- "What do we do now?"
 - Admit; begin 250 mg IV solumedrol Q6H x 3 days (12 doses) followed by 80 mg oral prednisone until seen by rheumatology
 - Needs TAB or TAU; do you want help arranging?
- Call from admitting hospitalist 2 hours later
 - Same questions and consult

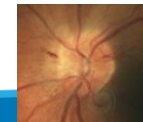
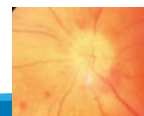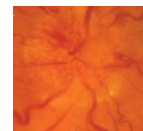
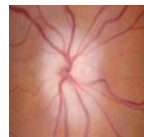

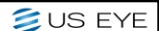
ANTERIOR ISCHEMIC OPTIC NEUROPATHY



- Hypoperfusion of the posterior ciliary arterial supply to the anterior optic nerve head.
- May be arteritic (AAION) or non-arteritic (NAAION)
- Mechanical factors and atherosclerotic disease play a role in the non-arteritic form while vasculitis contributes in the arteritic form.
- Unilateral presentation but high incidence of subsequent contralateral involvement
 - AAION

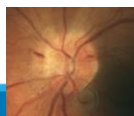
AAION VS NAAION



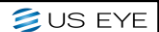NAAION



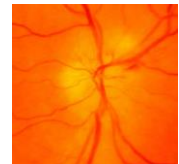
- Risk factors:
 - Hypertension, diabetes, atherosclerotic disease, small optic nerves
- Inferior arcuate field defects
- Hyperemic swollen nerve- disc at risk
- Progressive moderate vision loss with potential recovery
- Late 30s/ early 40s and beyond
- Painless



AAION



- Pallid optic nerve swelling with flame hemorrhages, arteriole attenuation and NFL infarcts
- Pain (of some sort)
- Severe optic nerve dysfunction
- Visual field defects
- Giant cell arteritis/ PMR- risk factors
- Typically 70s, uncommon under 60
 - Any patient over 50 is at risk
- High risk bilateral involvement
 - 65% within 10 days



Diagnosis

- Careful history: Must directly ask about nonvisual symptoms
 - Headache (present in over 90%), scalp tenderness, jaw claudication (almost diagnostic), ear pain, arthralgias, temple pain and/or tenderness, malaise, intermittent fevers
- Examination
- Laboratory studies elevated
 - Erythrocyte sedimentation rate
 - Lowered by statins and NSAIDS
 - C-reactive protein
 - Not affected by statins and NSAIDS
 - Elevated platelet count

Initial symptoms in GCA

- Headache
- PMR
 - Chair, hair, stair,
 - Fair(?)
- Fever
- Visual symptoms without vision loss
 - TIA, diplopia
- Weakness, malaise, fatigue
- What do all of these things have in common?

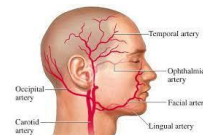
A normal exam

Vision Loss and Ocular Findings in GCA

- AION
- CRAO
- PION
- TIA
- Transient diplopia

Headache and pain in GCA

- Temporal
- Occipital
- Neck
- Ear
- Jaw
- Scalp



AAION

Diagnosis

- Prodrome, GCA symptoms
- Elevated ESR/CRP (combination of the two gives high specificity [97%])
- Elevated platelet count (acute phase reactant)
- Ophthalmoscopy
- Fluorescein angiography
- Temporal artery Biopsy
 - Negative biopsy: Read the report: "No giant cells, no active arteritis"
 - Focal interruption of the internal elastic lamina = healed arteritis

Treatment

- Prompt steroids and hydration
- Consider IV when vision loss present
 - Very effective in prevention of second eye
 - Occasionally restores vision
 - Best done through ER
 - 250 mg solumedrol QID x 3 days followed by orals

AAION versus NAAION

- Think AAION >> NAAION
 - Systemic symptoms of GCA
 - TVOs/TIAs
 - AION + cilioretinal artery occlusion
 - Evidence of posterior ciliary artery occlusion on FA
 - Multiple unexplained CWS
 - Early massive vision loss
 - Bilateral simultaneous vision loss
 - Chalky white optic disc edema
 - Elevated
 - ESR/CRP
 - Platelets

Hayreh SS, Podhajsky PA, Zimmerman B. Ocular giant cell arteritis: ocular manifestations. Am J Ophthalmol. 1998 Apr;125(4):521-6.



NAAION IS DIAGNOSED IN THE NEGATIVE. GET THE TESTS DONE PROMPTLY WITH AION



**REMEMBER THE E'S IN GCA:
ELDERLY, ESR IS ELEVATED, ONLY SEES THE BIG E
ON THE EYE CHART, AND ITS AN E~~U~~RGENCY**

66 YOF

ESR = 96

- New onset sudden vision loss
 - VA: 20/400 (longstanding macular scar)
 - Noticed inferior vision loss x 1 day
 - Inferior arcuate scotoma
- OD disc edema- mild pallor, no hemorrhages or telangiectasia
- OS disc- small, crowded disc at risk; C/D < 0.2
- Mild headache- relieved by OTC
- Malaise and loss of appetite- lost 7 lbs over 4 weeks
- No jaw claudication or temporal head pain
- What to do?



**ANY ACUTE VISION LOSS IN THE ELDERLY IS
GCA UNTIL PROVEN OTHERWISE**



What to say to the ER doc

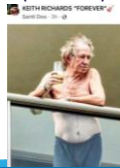- Don't say, "This patient has blurred vision"
- Say, "This elderly patient has suddenly lost vision in one eye and will go totally blind from giant cell arteritis if they aren't treated with steroids immediately!"



Nightmare or Nonsense?

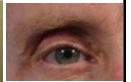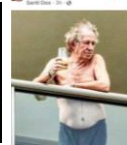
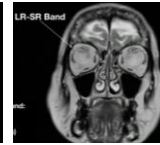
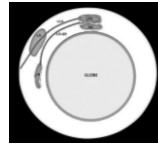
- 78 YOWM
- Undergoes premium cataract surgery
- 20/25 OD, OD; J1-J2 OU
- Develops intermittent horizontal diplopia at distance
- Worse when driving at night and watching baseball and basketball on TV
- Exophoric at near; eso posture at distance
 - Commitant in right and left gaze

NOW FOR SOME NEURO-OP NONSENSE THAT IS REALLY HELPFUL: THE SAGGING (SAGGY?) EYE SYNDROME



Sagging (Saggy?) Eye Syndrome

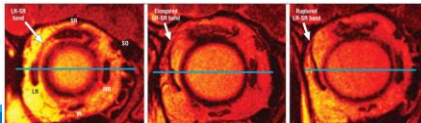
- Age-related orbital connective tissue degeneration
 - Baggy eyelids, superior sulcus deformity, aponeurotic blepharoptosis, previous blepharoplasty or similar cosmetic surgery.



Sagging (Saggy?) Eye Syndrome

- The LR-SR band ligament interconnects the SR and LR pulleys, suspending the LR vertically within the orbit
- SES is a manifestation of age-related, orbital connective tissue degeneration.
- Downward displacement, termed sag, of the LR pulley may symptomatically cause "divergence paralysis" esotropia for distant targets.
- SES represents a mechanical cause of acquired, adult horizontal and vertical strabismus.

Chaudhuri Z, Demer JL. Sagging eye syndrome: connective tissue involution as a cause of horizontal and vertical strabismus in older patients. JAMA Ophthalmol. 2013;131(5):619-25.




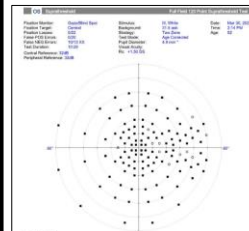
Sagging (Saggy?) Eye Syndrome


- Widespread rectus pulley displacement and EOM elongation, associated with LR-SR band rupture
 - causes acquired vertical and horizontal strabismus.
 - Small-angle esotropia or hypertropia may result from common involutional changes in EOMs and orbital connective tissues that may be suspected from features evident on external examination.
- Common Findings and complaints:
 - Horizontal diplopia (tends to be worse when tired), most noticed driving (at night) when turning to look at side view mirrors. Also when watching TV at distance (with fatigue).
 - Eso posture at distance and exo or ortho at near
 - May be vertical as well
 - MRI is confirmatory, not diagnostic
 - Treated with prism
 - Pt responded to 2 PD BO in driving glasses; Fresnel first then permanent, still peeved that he has to wear glasses



Nightmare or Nonsense?

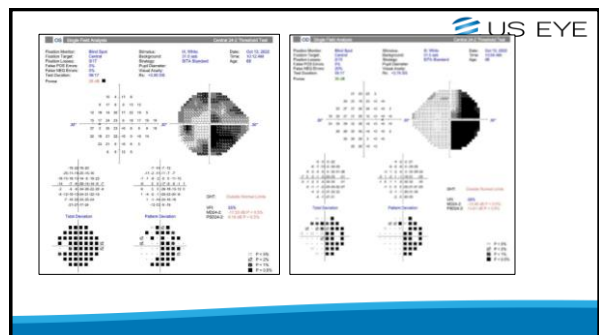
- 52 YOWM
- States LEE was about 2 years ago w/o dilation
- Pt reports that he has noticed peripheral "blind spot" OS>OD mostly when driving. Pt has not noticed an overall change in VA with other daily activities other than driving. States that glasses do not seem to improve the "blind spot".
- BVA 20/20 OD, OS
- PERRL (-) RAPD
- Examination normal; C/D 0.2/0.2 OD, OS; pink and distinct





- MRI brain with and without contrast:
- 3.4 x 2.3 x 3.9 cm lobulated sellar/ suprasellar mass. Compression and displacement of chiasm and posterior displacement of midbrain. Mild hydrocephalus. Differentials include macroadenoma with infarction and hemorrhage, epidermoid cyst, craniopharyngioma. Mild hydrocephalus.
- Craniotomy with near complete removal of tumor.
- Lost to follow up but spouse has called twice thankful for finding his brain tumor.

- ### Nightmare or Nonsense?
- 68 YOWM
 - Cataract surgery OU 3/22
 - Capsule haze- YAG OU
 - BVA 20/25 OD, OS
 - "VISION IS WORSE NOW THEN BEFORE MY SURGERY". "BRIGHT LIGHTS BOTHER ME AND I AM MISSING LETTERS WHEN I READ"
 - Feels surgery was botched
 - Exam normal- referred to retina
 - Retinal referral- few drusen; mild RPE changes; mild VMT
 - Possible old NAAION- neuro referral (10/22)



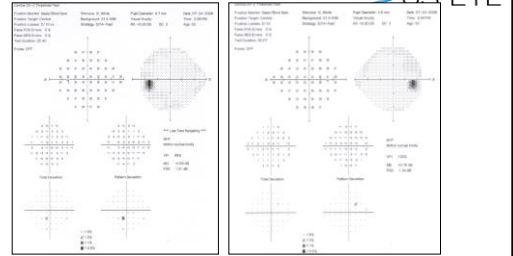
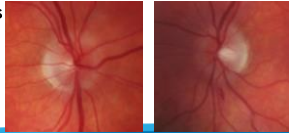
- MRI with and without contrast- brain
- CONCLUSION:**
1. Thin-walled suprasellar lobulated cystic lesion which follow CSF signal in all sequences, measuring 3.2 x 4.7 x 3.4 cm and extends predominantly to the left, exerting mass effect and the left optic pathways, left medial temporal lobe structures, left cerebral peduncle, as well as on the left lateral and third ventricles. There is 4 mm left to right midline shift, at the level of the anterior third ventricle. No definite solid component, restricted diffusion, or internal enhancement identified. The finding is most suggestive of a suprasellar arachnoid cyst.

- ### NIGHTMARE OR NONSENSE?
- 33 YOM: Occipital HA x 4 mos
 - Visual aura with HA
 - Worsens when standing after sitting
 - Relieved by sleep
 - Denies vision loss, nausea, diplopia, pain on eye movement, behavioral changes
 - Age appropriate physical normal
 - Referred by PCP

NIGHTMARE OR NONSENSE?



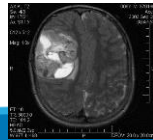
- 20/20 OD, OS with myopic correction
- Pupils, EOMs, conf fields normal OU
- Biomicroscopy normal OU
- IOP 12 mm Hg OU
- Nasally obliquely inserted nerves



NIGHTMARE OR NONSENSE?



- Co-manage with PCP- internist
- Complete blood work blood workup including FTA-ABS/RPR; Lyme titer; CBC w/differential
- MRI w and w/o contrast of brain and orbits
 - Pt had MRI done and mass was identified in fronto/parietal region more toward right side
 - Outcome?

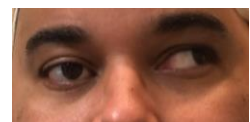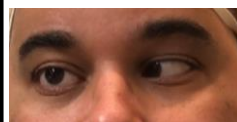

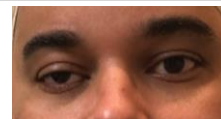
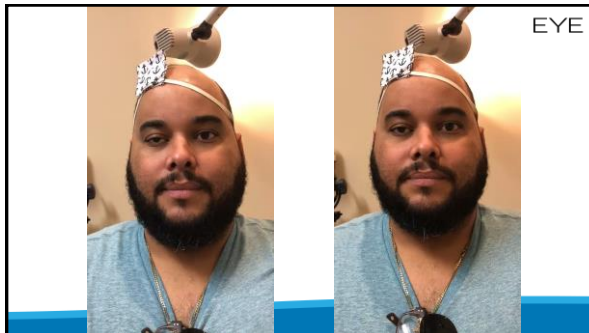A NORMAL VISUAL FIELD DOES NOT MEAN THAT
THERE
ISN'T ANYTHING WRONG

Nightmare or Nonsense?



- 39 YOM:
- Previous history of migraine developed a new and worsening headache.
- He presented to a hospital emergency room where he underwent a non-contrast enhanced computed tomography (CT) and magnetic resonance imaging (MRI) which were subsequently interpreted as normal.
 - His headache was attributed to migraine, and he was medicated as such and discharged.
- Three days later, he developed horizontal and vertical diplopia





Nightmare or Nonsense?

- His visual acuity and visual fields were normal.
- He manifested a right pupil-sparing, external partial cranial nerve three palsy and concurrent right sixth nerve palsy. He also complained of worsening headache and lethargy.
- Where is the lesion?
- Let's contact the radiologist for a second reading...

Nightmare or Nonsense?

- He was immediately sent for repeat imaging to include contrast-enhanced MRI of the parasellar area and MRA to rule out intracavernous aneurysm and pituitary apoplexy.
- Imaging revealed a pituitary macroadenoma with intratumor hemorrhage consistent with pituitary apoplexy.
- Lateral spread into the right cavernous sinus and possible spread into the left cavernous sinus as well.
- No mass effect on the optic chiasm or prechiasmatic intracranial portion of the optic nerve.
 - Hence normal acuity and fields
- The patient was immediately admitted for endocrinological and neurosurgical evaluation

Pituitary apoplexy

- Pituitary apoplexy is a severe and potentially fatal medical condition complicating 2-12% of pituitary adenomas and characterized by the variable association of headache, vomiting, visual impairment, ophthalmoplegia, altered mental state and consciousness, lethargy, and panhypopituitarism.
- Hemodynamic instability may be result from adrenocorticotrophic hormone deficiency, which can be fatal.
- Occurs due to a rapid expansion, mainly caused by hemorrhage or infarction of a preexisting (known or unknown) adenoma

Pituitary apoplexy

- Most common presenting symptom occurring in 90 % of patients is sudden onset of severe headache
 - Commonly described as frontal or retro-orbital.
 - Pituitary apoplexy is often overlooked as a possible cause of "thunderclap headache" where diagnostic evaluations tend to direct to more common causes of this presentation including subarachnoid hemorrhage, cerebral venous sinus thrombosis, and cervical artery dissection.
- Approximately 50% have visual abnormalities
 - Blurred vision
- Cranial nerve palsy (CN III) or palsies
 - Cranial nerve VI most common, followed by CN III
- Visual field defects
 - Bitemporal hemianopsia
- Facial weakness

Pituitary apoplexy

- Most symptomatic patients undergo CT scanning in an emergency setting due to the clinical suspicion of acute intracranial hemorrhage
- Acute hemorrhagic infarct may be seen on CT
 - Non-hemorrhagic infarcts will usually show no abnormalities without intravenous contrast
- MRI with contrast is the most effective imaging in cases of suspected pituitary apoplexy
 - MRI is superior to CT

Pituitary apoplexy

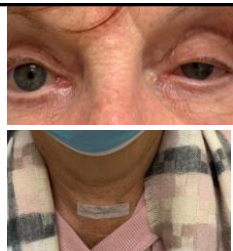
- Positive outcome in most cases
 - Conservative medical treatment
 - Stabilize and replace diminished pituitary hormones
- Surgical decompression
 - Trans-sphenoidal or subfrontal transcranial approach
 - Patients with visual impairment and neuro-ophthalmic dysfunction will be selected for surgery.
- Patient was medically stabilized, and surgery delayed due to COVID lock down
- Ultimately underwent successful surgical decompression

Summary of 4 mass lesions

- Vision normal in each case
- Vertical field loss in 2 cases; 2 cases normal fields
- Headache in 2 cases; none in 2 cases
- Diplopia and ophthalmoparesis in 1 case, none in 3 cases
- No disc pallor in any case
- No disc edema in any case
- Conclusion: mass lesions do not follow expected rules

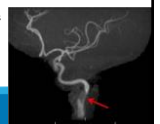
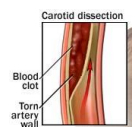
Nightmare or Nonsense

- 78 YOF: Sudden onset of ptosis and miosis OS
- Immediately following parathyroid surgery
- Headache and eye pain
- Dilation lag and positive lopidine test
- Dx: Acute Horner syndrome
- Possible causes:
 - Lung cancer
 - Carotid dissection
 - Direct surgical trauma to the nerve
 - Migraine



Carotid Dissection

- Carotid artery dissection presents with the sudden or gradual onset of ipsilateral neck or hemicranial pain, including eye or face pain
 - Post traumatic
 - Roller coaster, whiplash, chiropractic manipulation
 - Post surgical
 - Neck dissection, endarterectomy
 - Spontaneous
- Often associated with other neurologic findings including an ipsilateral *Horner's syndrome*, TIA, stroke, anterior ischemic optic neuropathy, subarachnoid hemorrhage, or lower cranial nerve palsies
 - Of those who develop a stroke
 - 52% within 6 days; 67% within first week; 89% within 2 weeks; none after 31 days
- Horner's from suspected carotid dissection should go to ER
 - Most concerning cause for new onset painful Horner syndrome

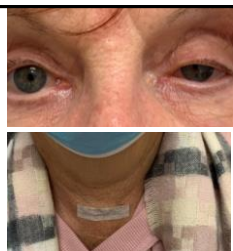
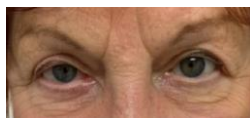

What to say to the ER doc

- Don't say, "This patient has a little ptosis and a little pupil."




- Say, "This patient has a carotid artery dissection and will stroke out unless they get a CTA and referred to a stroke neurologist now!"




US EYE

Nightmare or Nonsense?


- 75 YOF
- Sudden onset painless double vision
 - Worse at distance and left gaze
- Denies headache, jaw claudication, TIA, weightloss
- NIIDM; HTN
- No vision change
 - 20/30 OD, OS with cataracts
- Fundus exam normal
 - No disc edema



US EYE



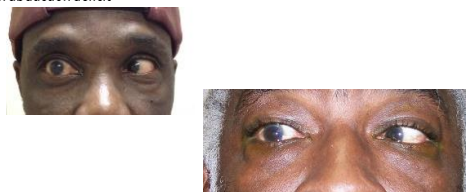
US EYE



US EYE

CN VI Palsy


- Hallmark sign is horizontal diplopia, greater at distance, with an abduction deficit



US EYE

CN VI Palsy

- Check motilities at distance
- Forced duction testing



US EYE

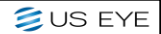CN VI Management

- Each case of CN VI palsy should be classified as traumatic or non-traumatic.
- Non-traumatic cases should be subdivided as neurologically isolated (just CN VI palsy) or non-neurologically isolated (something else).
- Additionally, patients should be ascribed to one of 3 groups: children, young adults, and older adults



CN VI Demographic Groups

- Older adults (**usually not bad**)
 - Vascular disease common- resolves-3mos
 - Consider GCA over 60 yrs
- Children (**maybe bad**)
 - Presumed viral illness, trauma, malignancy (**50%**)
- Young adults (**usually bad**)
 - Vascular disease (**4%**) and idiopathic (**13%**) uncommon
 - Usually complicated CN VI palsy (hemiparesis, Horner's syndrome, facial paresis)
 - Cerebrovascular accidents involving the pons, aneurysm (typically within the cavernous sinus) or neoplasm (**33%-cavernous sinus, pons, MS (24%)**).



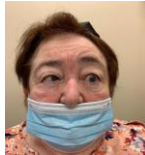CN VI Palsy in Older Adults

- In cases of isolated CN VI palsy in older adults with a history of diabetes or hypertension, neuroimaging and other extensive evaluation can be deferred, unless the palsy progresses, fails to improve over 3 months, or other neurologic complications develop.
- Ischemic vascular palsies typically progress over several days, but progression over two weeks warrants neuroimaging.



Outcome

- Discussed MRI- deferred
- Recommend patching to function
- Educated expected course
- 6 week f/u- markedly improved
 - Diplopia reduced and motility better
- Resolved without complications at 12 weeks.
- Rule: Ischemic microvascular palsies are allowed to get worse over 1 week and be no better at 2 weeks, but are not allowed to get worse over 2 weeks.
- Rule: Pts are only allowed to have one microvascular palsy at a time.

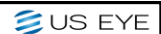

When is it a nightmare?

- 77 YOM: Pt and sister presents insistent on cataract surgery.
- BVA 20/40 OD, 20/70 OS with commensurate NS
- Chronic horizontal diplopia that has recently gotten worse (2 weeks)
 - Left abduction deficit ~ 40%
- Medical history: Inoperable chondrosarcoma with lysis of clivus extending to left petrous apex and occipital condyle with sphenoidal, ethmoidal and temporal bone involvement. Compression of jugular vein. Has undergone ~ 50 radiation treatments.
 - Vocal paralysis
 - Cranial nerve IX, X, XII palsies
- Imaging obtained: CT with contrast (pacemaker precludes MRI)-new soft mass in left nasopharynx
 - Likely squamous cell carcinoma



WHEN LOOKING FOR MASS CAUSE OF CN VI PALSY,
THE BASE OF THE PONS AND CAVERNOUS SINUS ARE
TWO COMMON HIDING SPOTS



IF YOU ARE WATCHING A PRESUMPTIVE ISCHEMIC CN
VI PALSY AND YOU ARE WRONG, YOU LIKELY HAVE
NOT
HURT THE PATIENT.

Case

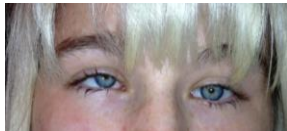- A 25-year-old woman was involved in a minor automobile accident where she was hit by another driver. The accident was reportedly minor, with no initial injury to either driver, and both cars were able to be driven away. She felt that she experienced only a mild-to-moderate bump during the accident with no head trauma or loss of consciousness. However, immediately upon waking the next morning, though she had no physical pain, she experienced profound double vision.

What is the likely cause?

- A subarachnoid hemorrhage
- A third nerve palsy
- Orbital fracture
- Fourth nerve palsy
- Sixth nerve palsy

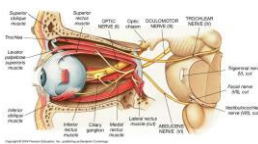
Case

- She described the diplopia as vertical and worse at near. She had a distinct right hyper deviation which, on alternate cover test, worsened in left gaze and right head tilt. This was a signature motility of a cranial IV (trochlear) palsy.




CN IV Anatomy

- Exits the midbrain posteriorly and decussates
- Longest course
- Travels around tentorium, through cavernous sinus, through SOF
- Most prone to trauma



CN IV Palsy

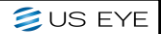- Longstanding CN IV palsy may present with diplopia from decompensation
 - Observe old photos for head tilt (*Facebook Tomography*)
- Rule of 40-30-20-10
 - 40% traumatic
 - 30% idiopathic
 - 20% vascular
 - 10% CNS lesion





CN IV Management

- Isolated, non-traumatic:
 - Evaluate for ischemic diseases
 - Non-ischemic causes of non-traumatic, isolated CN IV palsy rare
 - Look for longstanding decompensation
 - Increased vertical vergences
 - Old photos

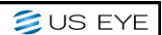

When is it a nightmare?

- 73 YOM; New onset vertical diplopia
 - Left 4th nerve palsy
 - Relieved by 2 PD BD
- *"Doc, I also noticed that my gripper is off"*
 - Mild left-handed weakness
- Medical history: Treated lung cancer
 - Currently on maintenance chemotherapy
- Approach and outcome?



NEVER DIAGNOSE IDIOPATHIC (OR ISCHEMIC)
ANYTHING IN A PATIENT WITH A HISTORY OF
CANCER



Neuro-op Nightmares That We Can All See

- Cranial nerve 3 palsy from aneurysm
 - They will die without treatment
- AAION
 - They can go bilaterally blind without treatment
- Cervical artery dissection
 - They can have a catastrophic stroke
- Know what to do, and be willing to help. Know what to say.

