Optometric Education Consultants

Conversations in Retinal Vascular Disease

Joseph Sowka, OD, FAAO, Diplomate
Greg Caldwell, OD, FAAO
Rita Singh, MD

DISCLOSURE:

Dr. Joseph Sowka: All relevant relationships have been mitigated.
Dr. Greg Caldwell: All relevant relationships have been mitigated.

Dr. Rita Sing: No disclosures

Optometric Education Consultants

Case From ODs on Facebook School of Medicine

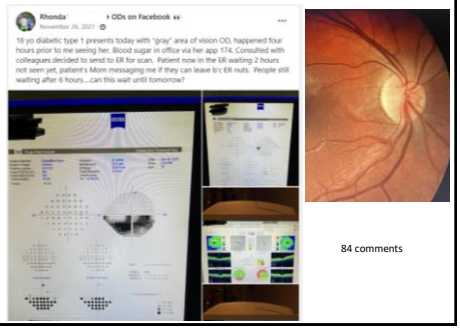

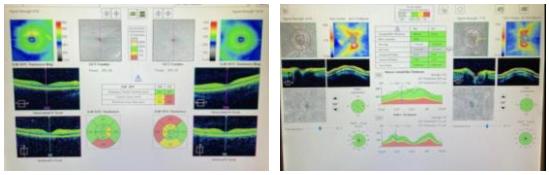

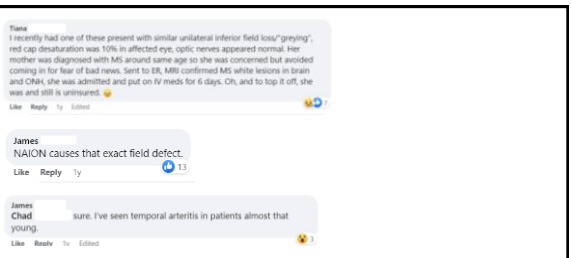

Elizabeth
Nerves don't appear swollen. My first case of this was a 22/24 yo I had to send for imaging. Was diagnosed with MS. Did she have an APD? Did you check brightness acuity or red cap?
Like Reply 1y

Rhonda Author
Elizabeth I didn't note an APD and did not do the red cap
Like Reply 1y

Elena
Elizabeth There is mild ONH edema on OCT
Like Reply 1y

Elena Collier
Rhonda If you look at OCT, there is some mild ONH edema. So likely diabetic papillitis with NAION. No need for ER. Just get BS under control, order MRI, and if clear, just monitor til it resolves.
Like Reply 1y 2

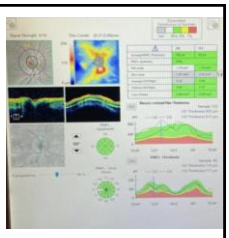

Paul
Yes it can wait until tomorrow
Like Reply 1y

Marc
Is she on birth control..... NAION
Like Reply 1y 3

Josh
I would think a diabetic papillitis is the most likely cause based on the information given. Careful recheck of APD maybe confirm with red cap. I'd also want a fundus photo. I would probably boot to retina and let them sort it.
Like Reply 1y Edited

Jay
Josh that would be a variation of NAION, and ONH would be swollen with fundus eval
Like Reply 1y

Josh
Rhonda Wendekier this may be a bit of a stretch but is there a bit of a blurred margin at 12 o'clock on the nerve?
Like Reply 1y 3

Jill
Young female most likely optic neuritis. Rule out/in MS with mri brain and orbits with and without contrast with Flair sequences. Could have been done outpatient including IV steroids but considering the holidays (and T1DM) probably best they admit given steroids and issues this will create with BS. Hopefully neurologist will get involved in the ER
Like Reply 1y 1

Dorothy Group expert
AiON
Like Reply 1y

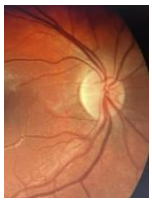

Hello Greg,

Can you please help me with this patient? I saw her yesterday at my office, she is my patient. I want to high school with her Mother. She is an 18 year old type I diabetic. She presented yesterday saying that she couldn't see the bottom half of her vision OD since finishing basketball practice yesterday. In the past she could mention intermittent areas of "gray vision" that would come and go but not lasting more than 15 minutes. I thought these intermittent episodes were possibly ocular migraines secondary to lasting 15 minutes or so. She and her Mother admit that her blood sugar hasn't been the best lately, in office yesterday via her app her blood sugar was 174. Currently she is on an insulin pump. Currently she is not taking BCP, she tried it in the past and hasn't taken it for two months.

Entering uncorrected acuities were 20/40 out of each eye, which is consistent with past exams. I did not refract her. I did not note an APD but was thinking there might likely was one present after seeing her VF. IOP was normal. I did not do color vision testing or the red cap test. You will see her VF attached. There is a hemianopsia OS. I've also attached her fundus photos and OCT. I consulted with an OMD yesterday and her advised me to send her to the ER for a scan secondary to vision loss. I should have known better, I realize this now, as the ER was a complete nightmare, but I was hoping Dr Budd, the OMD on call would have seen her. He did not. The only doctor that saw her was the "stroke doctor" and he seemed annoyed that she was seen at the ER.

They did do a CT scan as well as some blood work. I have attached the results from the patient portal that her Mother sent to me via a screen shot. I put this out on DEI on FB and some Doctors had similar presentations and it turned out to be NAION and MS. Some were saying they saw a little ONH edema and this could be early diabetic ONH swelling. I was also getting criticized for sending her to the ER. However, in the past I did have patients with ischemic optic neuropathies and some responded well to IV steroids some were left untreated and had vision loss for the rest of their lives. And due to the sudden onset and lasting vision loss I felt it needed attention ASAP.

I am really bothered by the lack of concern and support and I am worried about her vision.

What would you do here? MRI on Monday??? I really need help in managing this patient and it seems I am not getting anywhere. I spoke to her Mom this morning and her vision is still the same.

Thank you for your help.

Rhonda

From: Greg Caldwell <[redacted]>
Date: November 27, 2021 at 4:11:04 PM EST
To: Joe Sowka <[redacted]>
Subject: Fwd: BB info

I was going to suggest she send to me, will you help me?

Dr. Greg Caldwell
Fellow of the American Academy of Optometry and Diplomate, American Board of Optometry
814-931-2030 mobile #

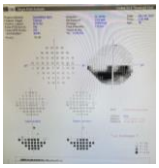

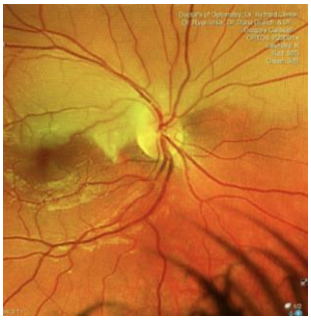

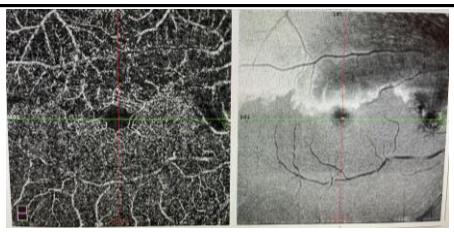

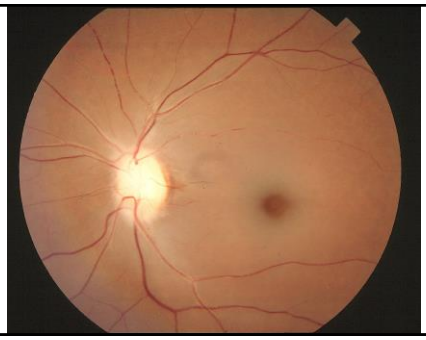

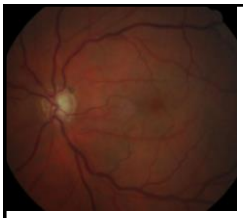

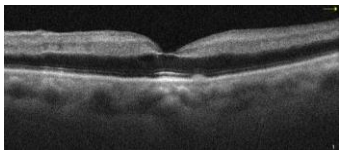

CRAO: Etiology

- Emboli from heart or carotid lodging at lamina
- Intraluminal thrombosis
- Dissecting aneurysm
- Vasospasm
- Arteriolar necrosis
- Giant cell arteritis

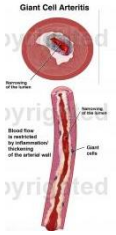

CRAO: Treatment ?

- Paracentesis
- Carbogen
- Digital massage
- Hyperventilation
- Urokinase/streptokinase
- 1-24 hr window of opportunity
- Does anything work?

CRAO: Systemic Considerations

- Atherosclerosis
- Carotid artery disease
- GCA
- Antiphospholipids ABS
- Infectious endocarditis
- Vasospastic disease
- Cardiac arrhythmia
- Clotting factor abnormalities
- Hypertension
- Diabetes
- Cardiac valve disease
- Cardiovascular disease
- Hyperlipidemia
- Disc drusen
- Mural thrombosis
- Hyperviscosity syndromes

CRAO: Complications

- CVA
- MI-Main cause of death
  - 9 yr mortality 56%
- Fellow eye involvement if GCA cause
  - ESR and CRP for GCA
- Cardiology/ internal medicine
- Neo not common

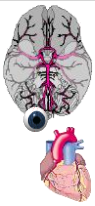

James' Outcome

- Referred for medical care
- Diagnosed with hypertension, NIDDM, hypercholesterolemia
- Returns for ocular follow up 3 months later
  "I'm scared"
- Several toes amputated from diabetes
- Passed away from MI within year

BRAO; cilioretinal AO

- BRAO nearly always embolic
- Greater risk of cardiac mortality
- Cilioretinal AO- branch of PCA- high risk of GCA

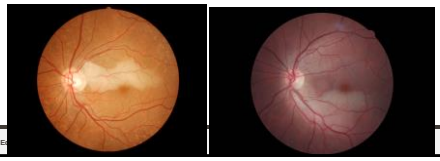

Guidelines

- Any patient with suspected TIA or those with acute retinal ischemia should be evaluated urgently in order to identify those at high risk of immediate cerebral infarction and cardiac ischemia

Guidelines for the prevention of stroke in patients with stroke or transient ischemic attack: a guideline for healthcare professionals from the american heart association/american stroke association. Stroke 2014; 45: 227-276

Adapted from Drs. Nancy Newman and Biousse; 2015

All Patients with Acute Retinal Arterial Ischemia

- MUST have immediate brain imaging
  - Brain MRI with DWI >>> Head CT
- Including patients with transient visual loss (presumed of vascular origin)

Presence of cerebral ischemia portends higher risk of stroke

Adapted from Drs. Nancy Newman and Biousse; 2015

Concurrent Acute Brain Infarcts in Patients with Monocular Visual Loss

- ¼ with acute retinal ischemia had acute brain infarction (anywhere) on brain DWI-MRI
  - Infarctions often small, multiple, ipsilateral to retinal ischemia, asymptomatic

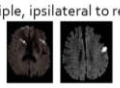

  - DWI-MRI abnormal in:
    - 33% with CRAO/BRAO vs 18% with TVL
    - 28 % with embolic vs 8% non-embolic retinal ischemia

Adapted from Drs. Nancy Newman and Biousse; 2015

Study #2

Co-occurrence of Acute Retinal Artery Occlusion and Acute Ischemic Stroke: Diffusion-Weighted Magnetic Resonance Imaging Study

JUNWON LEE*, SEUNG WOO KIM*, SUNG CHUL LEE, OH WOONG KWON, YOUNG DAE KIM, AND SUK HO BYEON

Am J Ophthalmol 2014; 157: 1231-1238

Adapted from Drs. Nancy Newman and Biousse; 2015

Co-occurrence of acute retinal artery occlusion and acute ischemic stroke: Diffusion-weighted magnetic resonance imaging study

- 33 patients with CRAO (18) and BRAO (15)
- Evaluated similarly to acute stroke patients (DWI)
- ¼ with acute retinal ischemia had acute brain infarction (anywhere) on brain DWI-MRI
  - 5/18 CRAO; 3/15 BRAO
  - Infarctions often small, multiple, ipsilateral to retinal ischemia, may be asymptomatic
  - Abnormal DWI-MRI strongly correlated with major cause of stroke (even when neurologically asymptomatic)

Adapted from Drs. Nancy Newman and Biousse; 2015

DWI in Acute Retinal TIA/Ischemia

- DWI-MRI identifies subgroup of patients at very high risk of major stroke
- DWI-MRI needs to be performed within 24/48 hours of visual loss to allow for effective prevention of recurrent stroke

Adapted from Drs. Nancy Newman and Biousse; 2015

Tell the patient:

- "Go to the Emergency Department"
- "Tell them you had a retinal stroke"
- Do not send these patients to their PCP, cardiologist, neurologist, neuro-ophthalmologist
- Do not try to obtain the workup yourself

Adapted from Drs. Nancy Newman and Biousse; 2015

Ode to an Artery Occlusion

When the vision is poor and the fundus is pale,
An emboli has caused the fail.
Heroic measures are rarely helpful,
And vision return is doubtful.
In an Oldie, always remember giant cell it may be.
Hurry and get an ESR and CRP.
The retina is infarcted and dead,
So neo you should not dread.
But here is where you must not choke,
Send them to the ER because they are having a stroke

Joseph Sowka, OD

The Case of the Colored Flashing Lights

- 45 YOHF presented with colored "map-like" phosphenes and small black flashing spots OD x two weeks
- Noted that she had to "look between the lights" to see out of her right eye.
  - 20/20 OD, OS
- Medical history was unremarkable except for treated migraines
- Lost 1 pregnancy

OptometricEdu.com/Webinars

So,
What's your diagnosis?

Management…?

Case Continued

- She returned four days later complaining of decreased vision in the right eye, which had reduced to counting fingers at ten feet.
  - Macular edema, more extensive hemorrhaging, cotton wool spots, disc edema and dilated vessels
- Underwent IV Kenalog injections and showed improved vision of 20/70 OD during follow up examinations.
  - Released by retinal specialist
  - No medical evaluation

Now What?



Are there any tests that you would like to order?

CRVO: Systemic Considerations

- *Hypertension*
- *Hyperviscosity*
- CV disease
- Sickle
- Polycythemia
- Hyperlipidemia
- Autoimmune factors
- Homocysteine
- *Diabetes*
- Syphilis
- Cardiovascular disease
- Leukemia
- Carotid artery disease
- Sarcoid
- Clotting abnormalities

Treatment & Management

- Referred blood work through PCP
  - DM, HTN, hypercoag, ANA, antiphophospholipid antibodies, anticardiolipin, PT, PTT, ESR, CBC with diff
- Elevated erythrocyte sedimentation rate
- Mildly elevated cholesterol level.
- Elevated anti-cardiolipin IgM antibodies
  - Suggestive of antiphospholipid antibody syndrome
  - She was recommended for long term anti-coagulant therapy to prevent future thrombotic events, but patient never followed through.

Case Continued

- Seven months later the patient returned with the same signs and symptoms in her right eye.
- At this time, the vision was markedly more decreased with more evidence of ischemia
  - CF @ 6'
- She was referred to a hematologist
- Now on anti-coagulation therapy

Central Retinal Vein Occlusion

- Thrombotic/atherosclerotic phenomenon
- Properties of blood and vein act in concert
- Vascular flow and vessel wall abnormalities
- Problem at lamina
  - Turbulent flow
  - Decreased luminal pressure
  - Thrombus
- Perfused; non-perfused; indeterminant
- Evolving condition

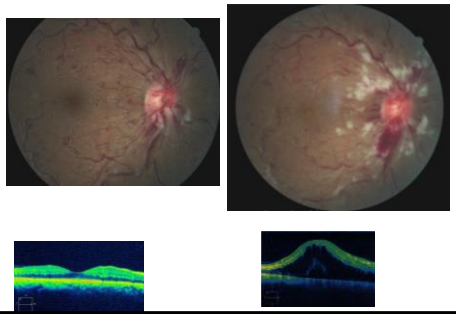

Primary antiphospholipid antibody syndrome

- Thrombotic disorder
- Secondary antiphospholipid syndrome
  - Associated several autoimmune diseases but most often systemic lupus erythematosus
- Primary antiphospholipid syndrome is not associated with further systemic disease
- Recurrent vascular thrombosis, pregnancy loss and positive anticardiolipin or lupus anticoagulant are all characteristics of this disorder

Primary antiphospholipid antibody syndrome

- Phospholipids are identified by the body as "foreign."
  - The antiphospholipid antibodies are produced against the "foreign" antigen.
- The antibodies appear to react with the cell membranes causing irritation or stimulation, thus disrupting the coagulation cascade
- This disruption leads to abnormal blood clotting and inhibits normal phospholipid binding.
- Propensity of clot formation is within the venous and arterial portions of the vascular tree, especially targeting the retinal vessels and placenta

Ok, now that we have warmed up… Let's see if we can figure this one out.

50 YOIF

- POAG OU x 10 years- medically controlled
  - PGA, beta blocker
- Hx CVA at age 17
  - No cause found
- N/S x 1 year
- Presents with sudden onset vision loss OD (6 hrs)
  - IOP 22 mm OU; using PGA, not using beta blocker
- 20/100 OD; 20/20 OS; 3+ RAPD OD
  - Never present before

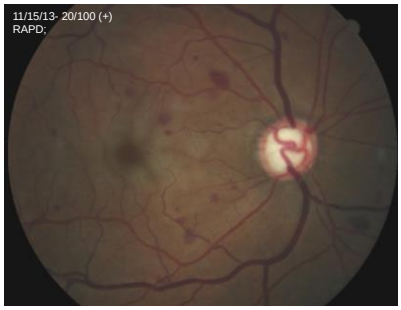

So, What are your thoughts?

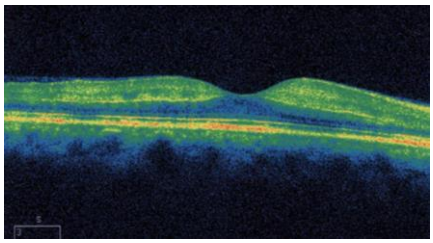

- Recommend retinal consult for angiogram- pt initially declines
  - Pt ultimately sees retinal specialist next day
- Angiogram *normal*.
  - Normal arterial filling 'somewhat delayed' venous filling. No evidence of edema or ischemia- pt released

- Pt returns 6 days later
- Some visual improvement
  - 20/60 OD
  - RAPD now grade 2
  - IOP 12 mm OU
  - Ischemia
- f/u 1 mos

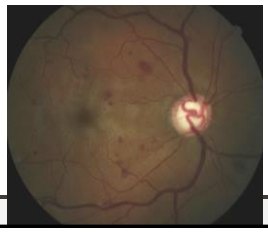

- Pt returns 3 weeks later
- Vision improved to 20/30
- RAPD diminished to grade 1

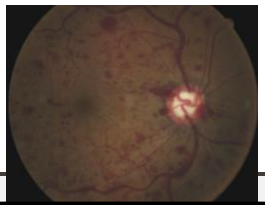

So,
What are your thoughts?

- CRVO? CRAO? Variant?
- Reappointed for 1 month
- Pt returns as scheduled- vision improved
  - 20/25+
  - RAPD disappeared

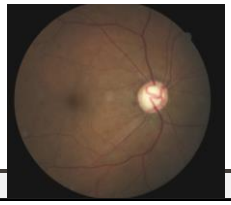

Questions

- Artery or vein occlusion?
- Why OCT and FANG normal?
- How does RAPD form and disappear over 2 months?

Now a Twist

- 47 YOBM
- Obese
  - 400 lbs (and that's being kind!)
- Headaches x 3 months
- Vision reduction x 2 months
  - 20/50 OU
- BP: 212/155 RAS

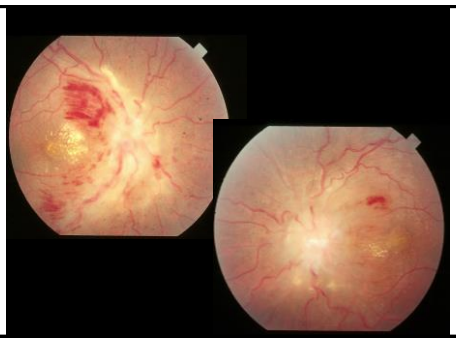

So, What do you think?

Just a Routine Exam…

- 72 YOWM
- No visual or ocular complaints
- HTN x 20 years
- Lifetime smoker
- Reasonably compliant with meds

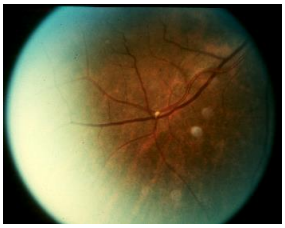

Now What?



Are there any tests that you would like to order?

Asymptomatic Retinal Emboli

- Cholesterol emboli are the most commonly encountered (80% of emboli) while fibrin-platelet emboli represent 14% of emboli and calcific emboli account for just 6% of visible retinal emboli

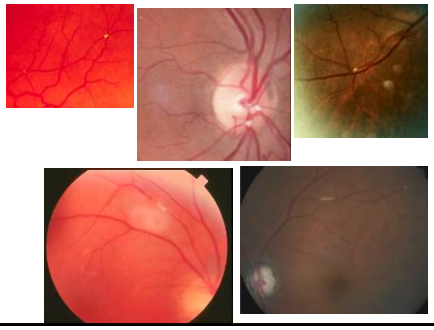

Visible Retinal Emboli

- Fibrin/platelet aggregate (Fisher plaque-carotid in origin, also walls of arteries and valves of heart)
  - Dull gray or white
  - Readily migrate through vascular system producing symptoms (AF)
- Hollenhorst- cholesterol (carotid in origin)
  - Refractile, glistening, yellow
  - Most common (87%) of all emboli
  - Typically do not occlude artery
  - Malleable and allows for blood to pass though the artery may appear totally blocked
  - Will readily break up and move distally, so will not be seen typically in patients complaining of AF
  - common cause of AF
- Calcific (cardiac)
  - Dull white and non-refractile
  - Usually from valvular calcification
  - Most likely to cause artery occlusion and stroke

Asymptomatic Retinal Emboli

- The proper approach to managing asymptomatic retinal emboli is truly not known.
- The most common associated systemic disease is hypertension, cardiovascular disease and stroke.
- In many studies, the prevailing risk factor for retinal emboli is smoking.

Asymptomatic Retinal Emboli

- Patients should be evaluated by an internist for hypertension, coronary artery disease, diabetes, and carotid artery disease
- A complete physical with stress echocardiogram, fasting glucose, lipid levels, blood chemistry with cardiac enzymes, magnetic resonance angiography, transthoracic and transesophageal echocardiography may be indicated, especially for patients with symptomatic retinal emboli.

Asymptomatic Retinal Emboli

- No consensus on the need for carotid ultrasonography in patients with asymptomatic retinal emboli
  - Majority of these patents do not have high grade carotid stenosis
- There is no clear indication for carotid endarterectomy in patients with asymptomatic retinal emboli, even with concurrent high grade carotid stenosis
  - There does seem to be a benefit to carotid endarterectomy in patients with symptomatic retinal emboli and high grade carotid stenosis