Grand Rounds
Improving Eye Care and Outcomes for Patients

Greg A. Caldwell, OD, FAAO
Optometric Education Consultants

Sunday, March 5, 2023

Disclosures- Greg Caldwell, OD, FAAO

All relevant relationships have been mitigated

- Lectured for: Alcon, Allergan, Aerie, B&L, BioTissue, Kala, Maculogix, Optovue, RVL, Heru, Santen
  - Disclosure: Receive speaker honorariums
- Advisory Board: Allergan, Alcon, Dompe, Eyenovia Tarsus, Visus
- I have no direct financial or proprietary interest in any companies, products or services mentioned in this presentation
  - Disclosure: Non-salaried financial affiliation with Pharmanex
- Envolve: PA Medical Director, Credential Committee
- Healthcare Registries – Chairman of Advisory Council for Diabetes and AMD
- The content of this activity was prepared independently by me - Dr. Caldwell
- The content and format of this course is presented without commercial bias and does not claim superiority of any commercial product or service
- Optometric Education Consultants – Pittsburgh, PA, Sarasota, FL, Muncie, IN, Scottsdale/Phoenix, AZ, Orlando, FL, Mackinac Island, MI, Nashville, TN, and Quebec City, Canada - Owner

Optometric Education Consultants

H.A.T.E Medications in Neuro-Op Toxicity

- Hydroxychloroquine – Plaquenil
  - Toxic Neuro-Retinopathy
- Amiodarone
  - Keratitis and anterior ischemic optic neuropathy
- Tetracycline analogs: doxycycline and minocycline
  - Pseudotumor cerebri, hypersensitive UV, hyperpigmentation
- Ethambutol
  - Optic neuropathy

Hate – 71-Year-Old Woman

- With Lupus and hypertension
- Medications:
  - Colazapam
  - Plaquenil 200 mg BID, 15 years
  - 81 mg ASA
  - Prednisone
  - Losartin
- VA 20/25 OD/OS (mild cataracts)
- Patient was told to see an ophthalmologist in 2013

2016

2016

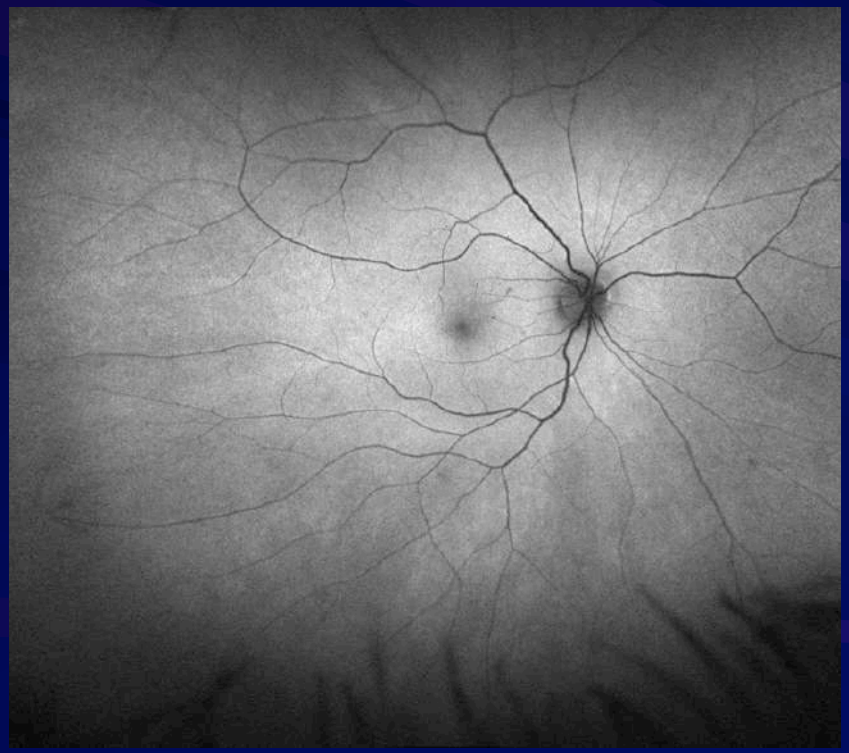

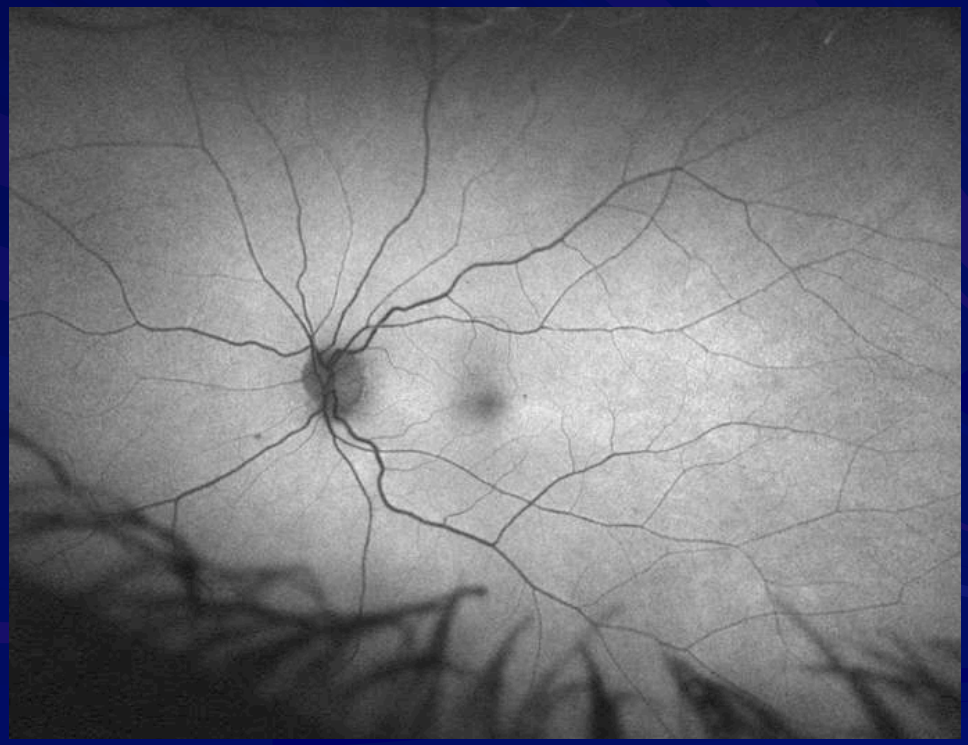

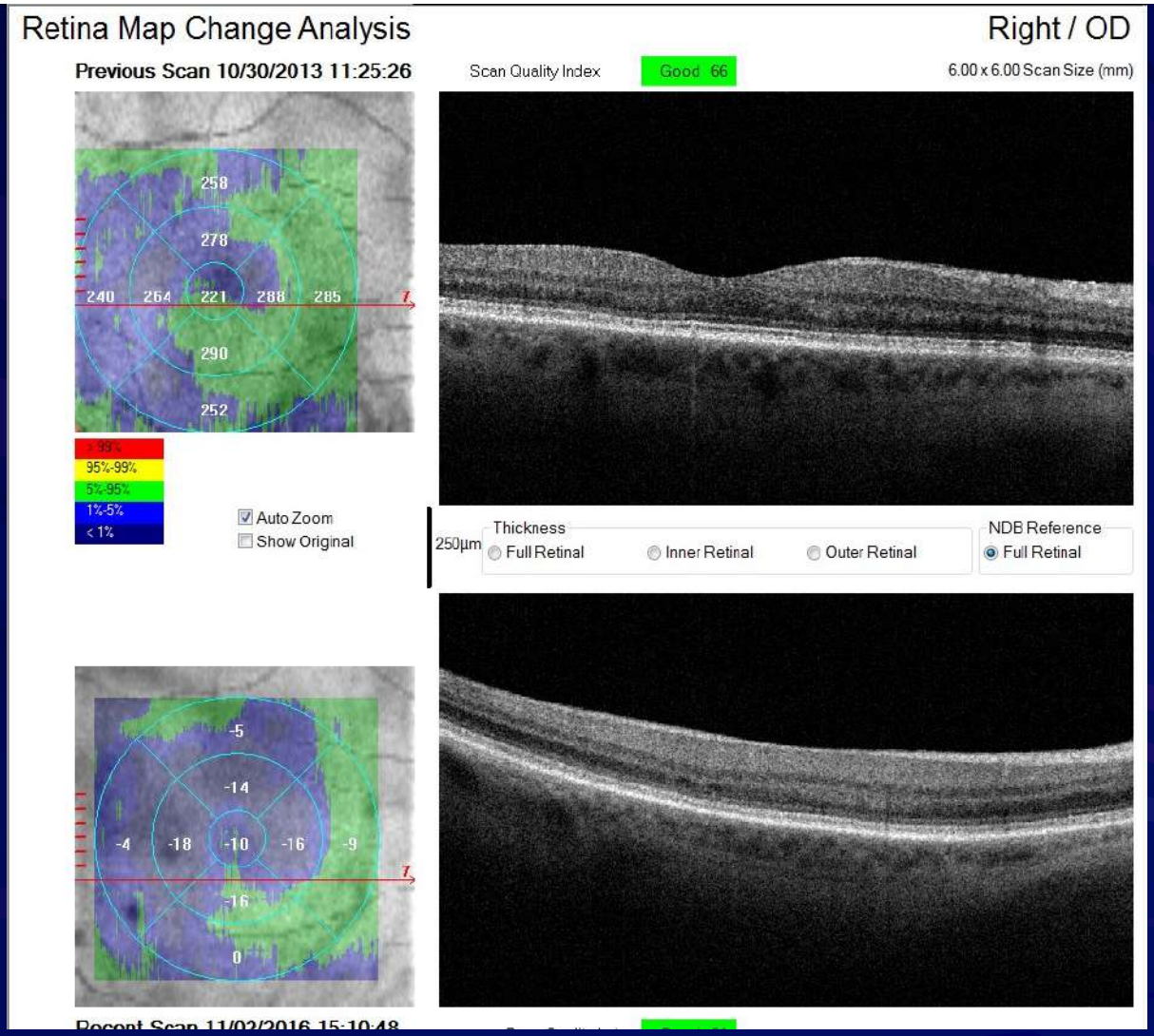
Retina Map Change Analysis
Right / OD
Previous Scan 10/30/2013 11:25:26
Scan Quality Index
Good 66
6.00 x 6.00 Scan Size (mm)
258
278
240
264
221
288
285
290
252
95%-99%
5%-95%
1%-5%
< 1%
Auto Zoom
Show Original
250µm
Thickness
Full Retinal
Inner Retinal
Outer Retinal
NDB Reference
Full Retinal
-5
-14
-4
-18
-10
-16
-9
-16
0

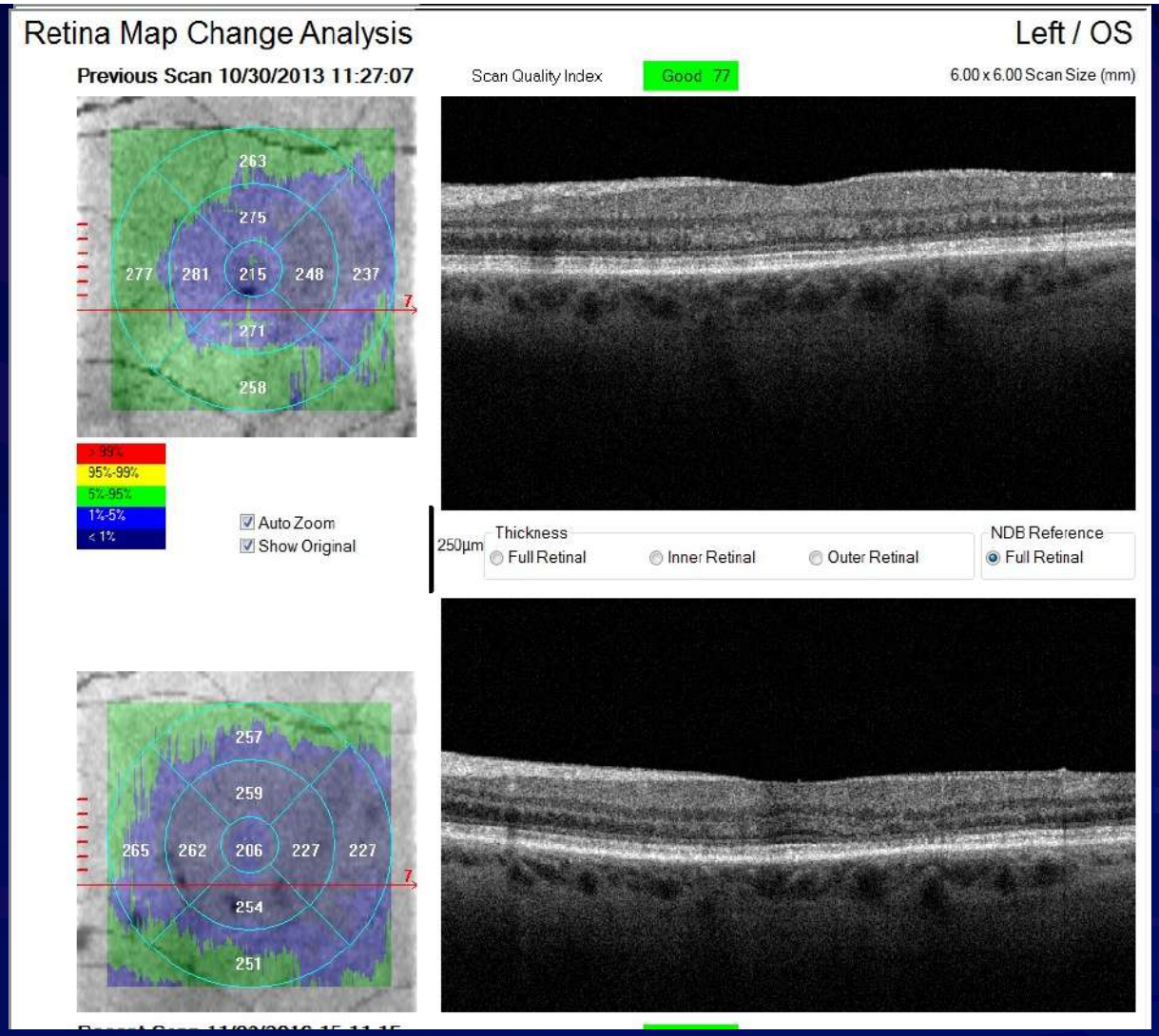
Retina Map Change Analysis
Left / OS
Previous Scan 10/30/2013 11:27:07
Scan Quality Index
Good 77
6.00 x 6.00 Scan Size (mm)
263
275
277
281
215
248
237
271
258
> 99%
95%-99%
5%-95%
1%-5%
< 1%
Auto Zoom
Show Original
250µm
Thickness
Full Retinal
Inner Retinal
Outer Retinal
NDB Reference
Full Retinal
257
259
265
262
206
227
227
254
251

Case 10

hAte- 65-year-old woman

- Referred by an optometrist due to corneal edema and map-like anterior opacities
  - Impression is EBMD versus corneal degeneration
- Patient reports decreasing vision over past 6-9 months
  - Especially at near
- Vision 20/50 OU

Cornea OD

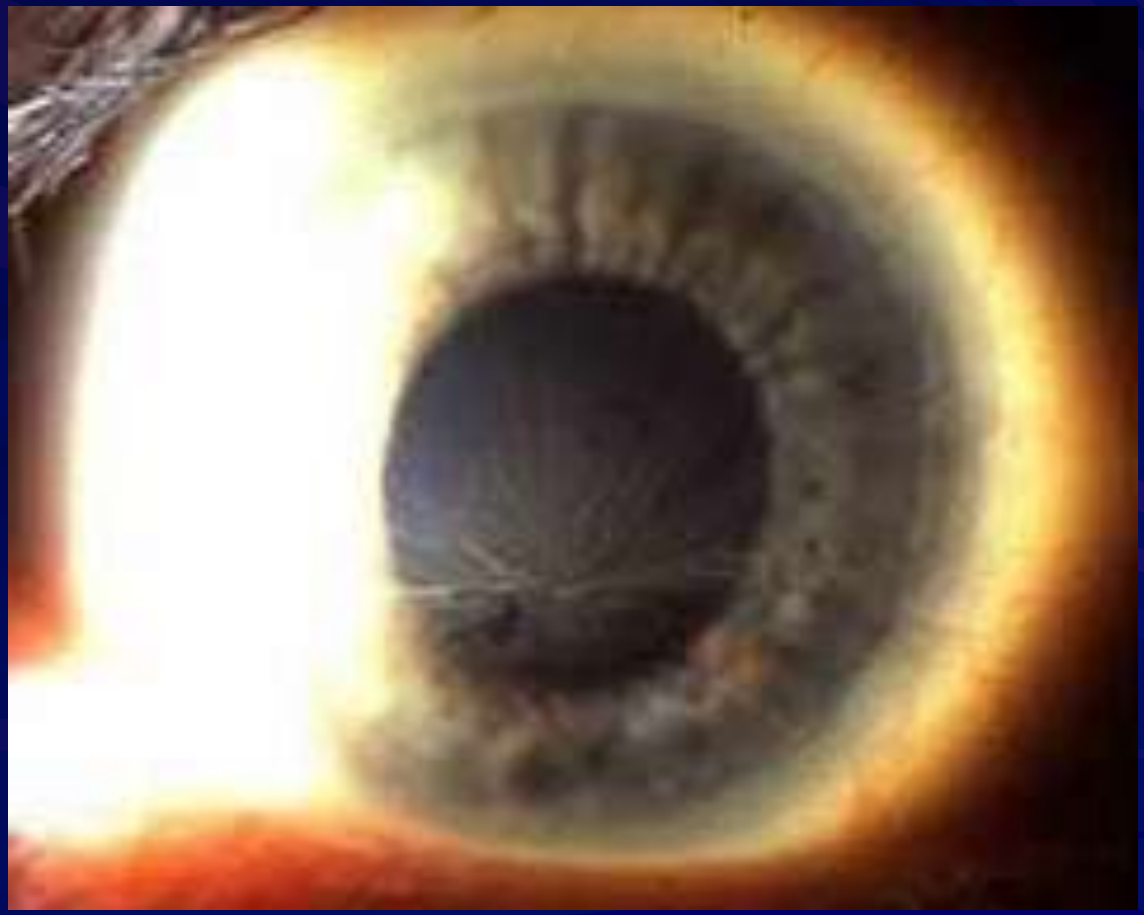

Patient's Medications

- Baby ASA
- Lanoxin
- Synthroid
- Glucophage
- Pravochol
- Amiodarone
- Neurotin
- Zoloft
- Vitamin E

Topography

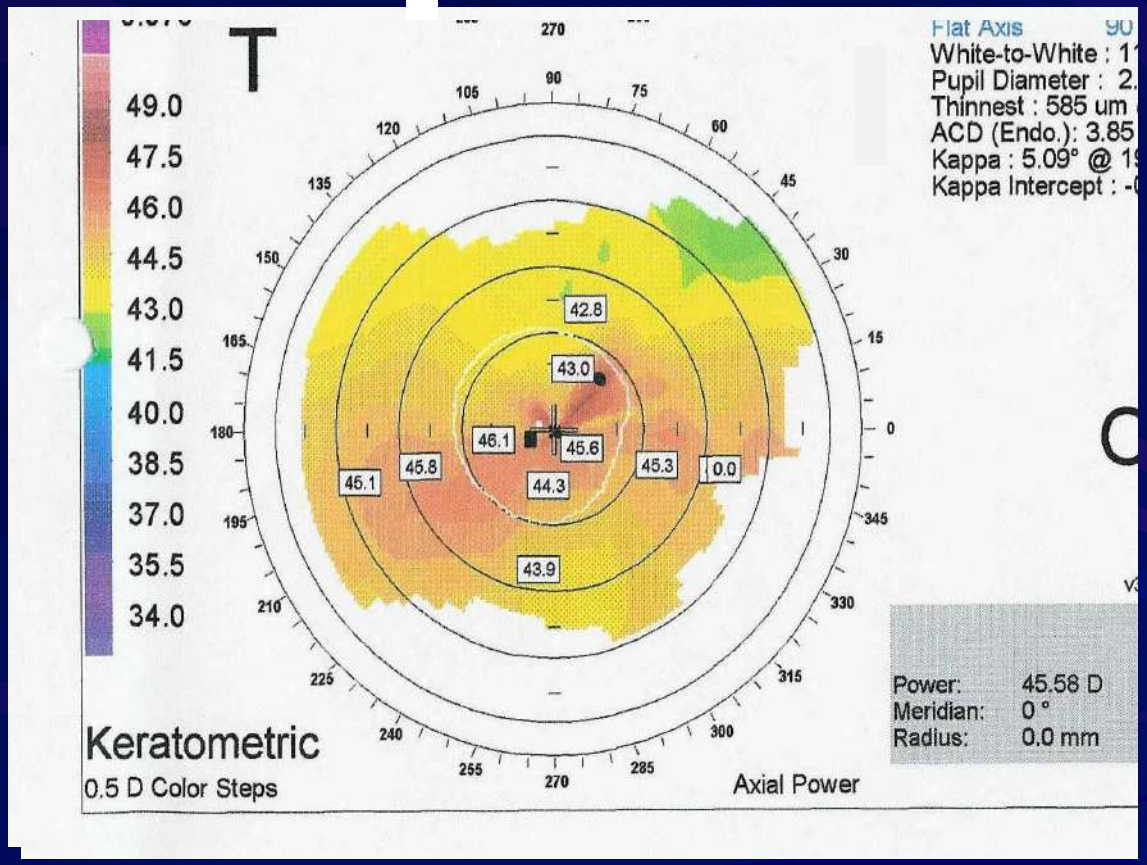
T
49.0
47.5
46.0
44.5
43.0
41.5
40.0
38.5
37.0
35.5
34.0
Flat Axis
White-to-White :
Pupil Diameter :
Thinnest : 585 um
ACD (Endo.): 3.85
Kappa : 5.09° @
Kappa Intercept :
42.8
43.0
46.1
45.6
45.8
45.1
44.3
45.3
0.0
43.9
Power: 45.58 D
Meridian: 0 °
Radius: 0.0 mm
Keratometric
0.5 D Color Steps
Axial Power

Topography

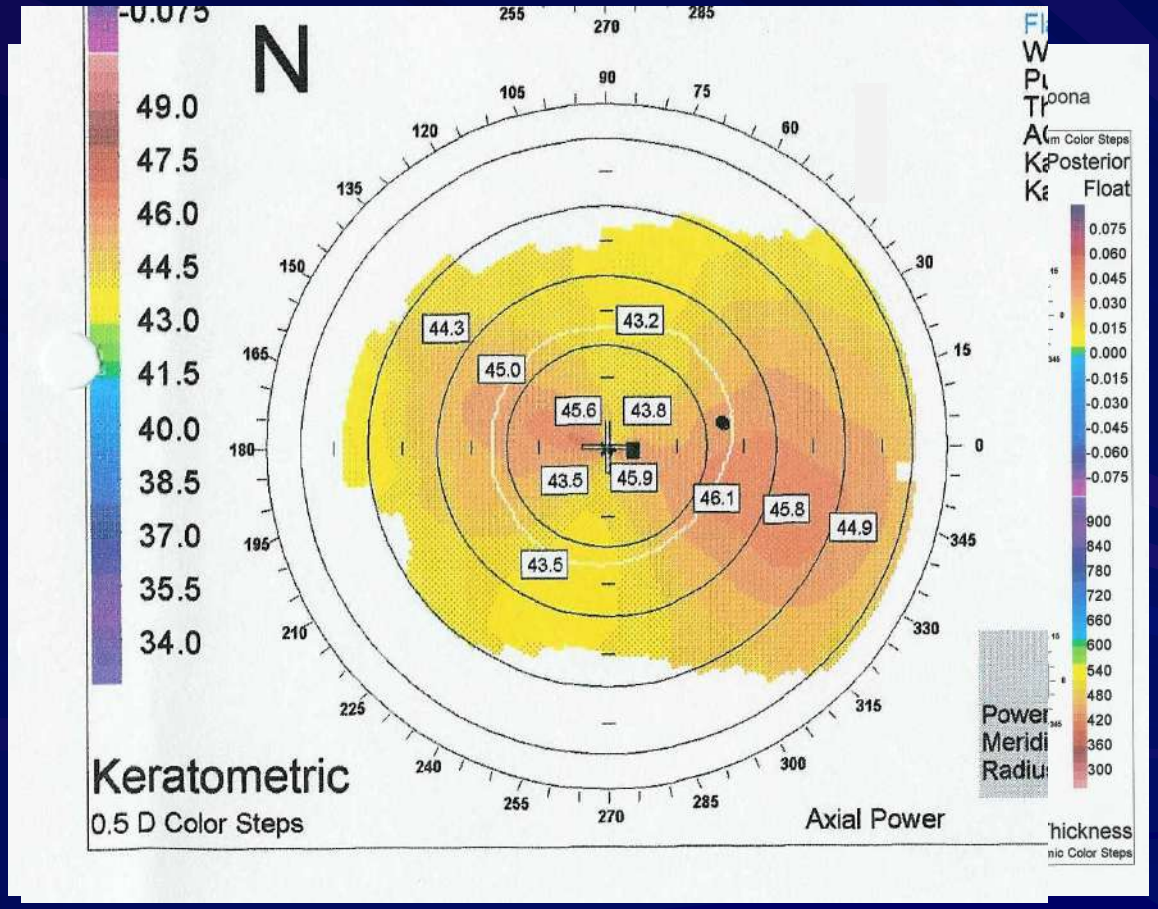
N
49.0
47.5
46.0
44.5
43.0
41.5
40.0
38.5
37.0
35.5
34.0
44.3
43.2
45.0
45.6
43.8
43.5
45.9
46.1
45.8
44.9
43.5
Keratometric
0.5 D Color Steps
Axial Power
Posterior
Float
0.075
0.060
0.045
0.030
0.015
0.000
-0.015
-0.030
-0.045
-0.060
-0.075
900
840
780
720
660
600
540
480
420
360
300

Called Primary Care Physician to Discuss Findings

- D/C amiodarone
- Primary Care Physician switches patient to diltiazem

Class	Action	Drugs
I	Sodium channel blockade	Quinidine, Procainamide, Disopyramide, Lignocaine, Mexiletine, Tocainide, Flecainide, Phenytoin
II	ß-adrenergic blockade	Propranolol, Acebutolol, Carvedilol, Esmolol …
III	Prolong repolarisation	Amiodarone, Bretylium, Sotalol, Difetilide, Azimilide
IV	Ca2+ antagonism	Verapamil, Diltiazem, Semotiadil

6 Months Later

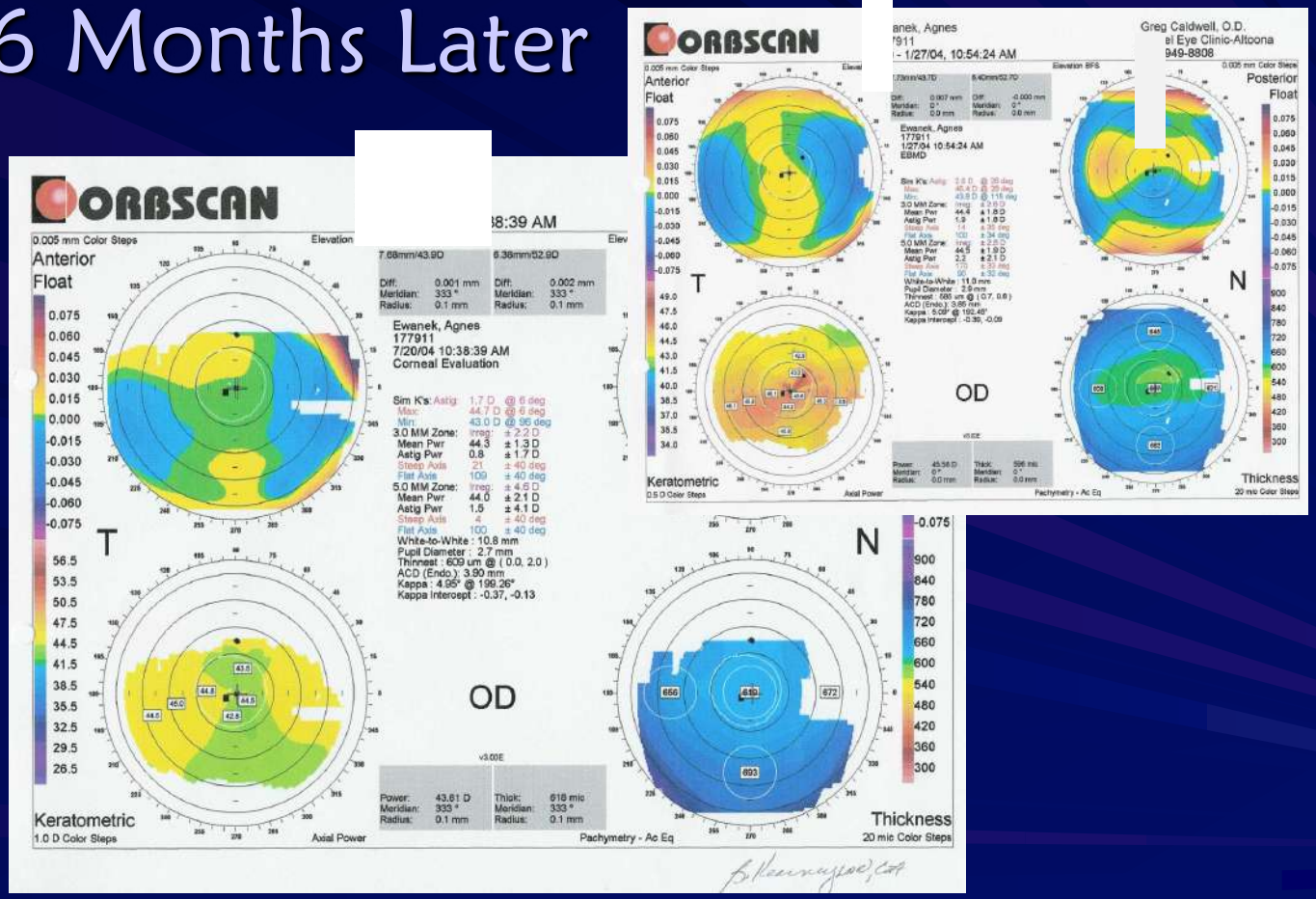

20/25 BVA

OD

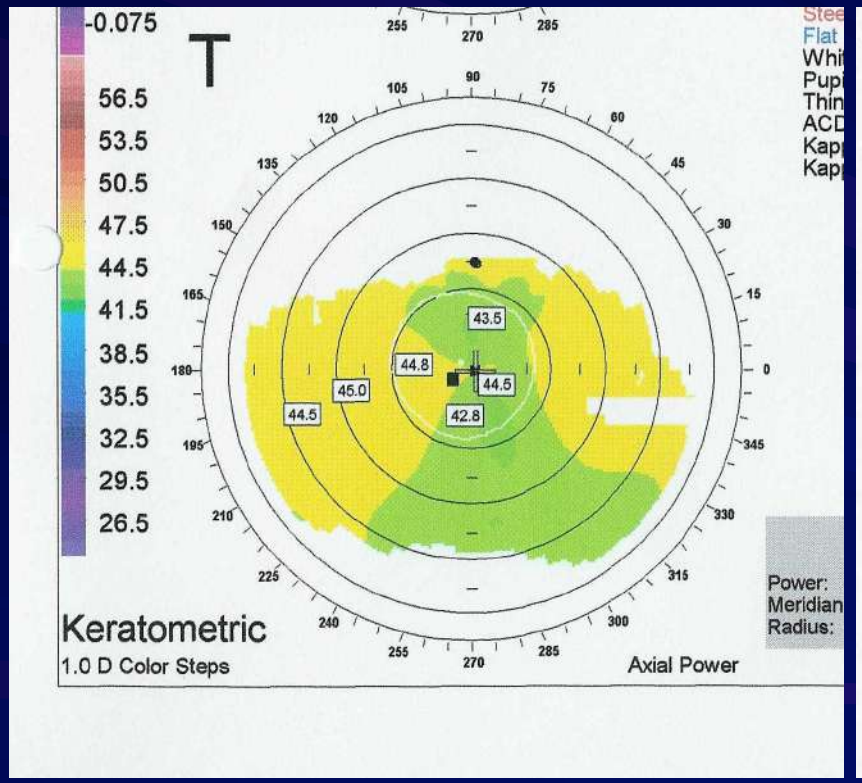
-0.075
56.5
53.5
50.5
47.5
44.5
41.5
38.5
35.5
32.5
29.5
26.5
T
43.5
44.8
45.0
44.5
44.5
42.8
Keratometric
1.0 D Color Steps
Axial Power
Power:
Meridian
Radius:

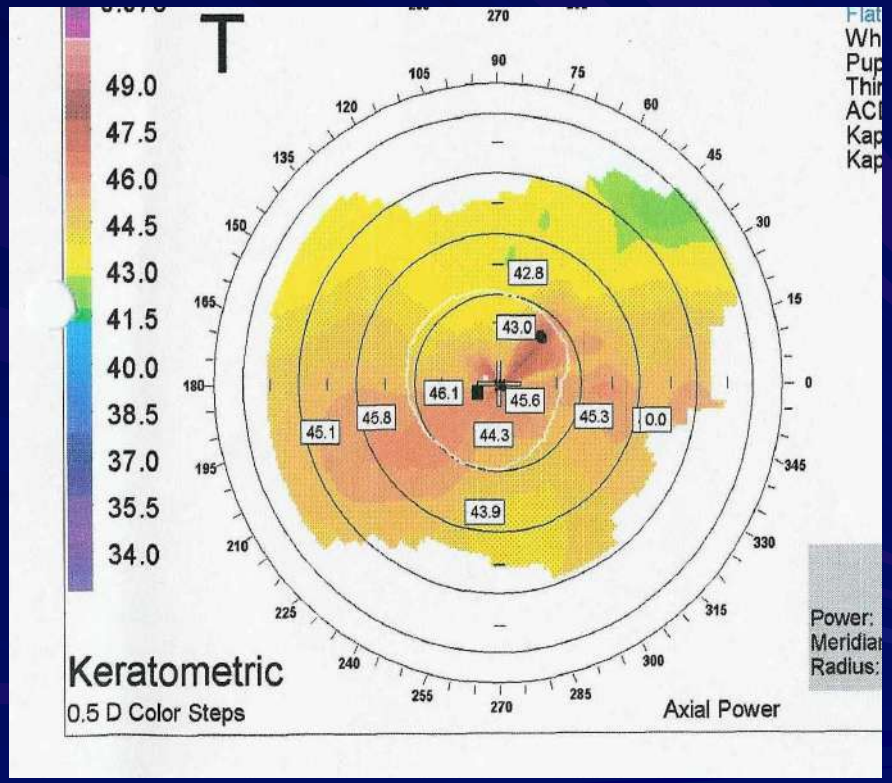
49.0
47.5
46.0
44.5
43.0
41.5
40.0
38.5
37.0
35.5
34.0
T
42.8
43.0
46.1
45.6
45.1
45.8
44.3
45.3
0.0
43.9
Keratometric
0.5 D Color Steps
Axial Power
Power:
Radius:

6 Months Later

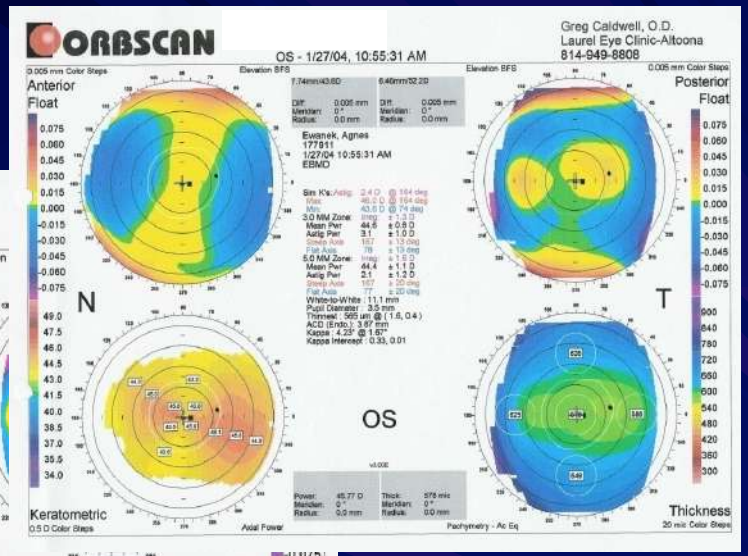

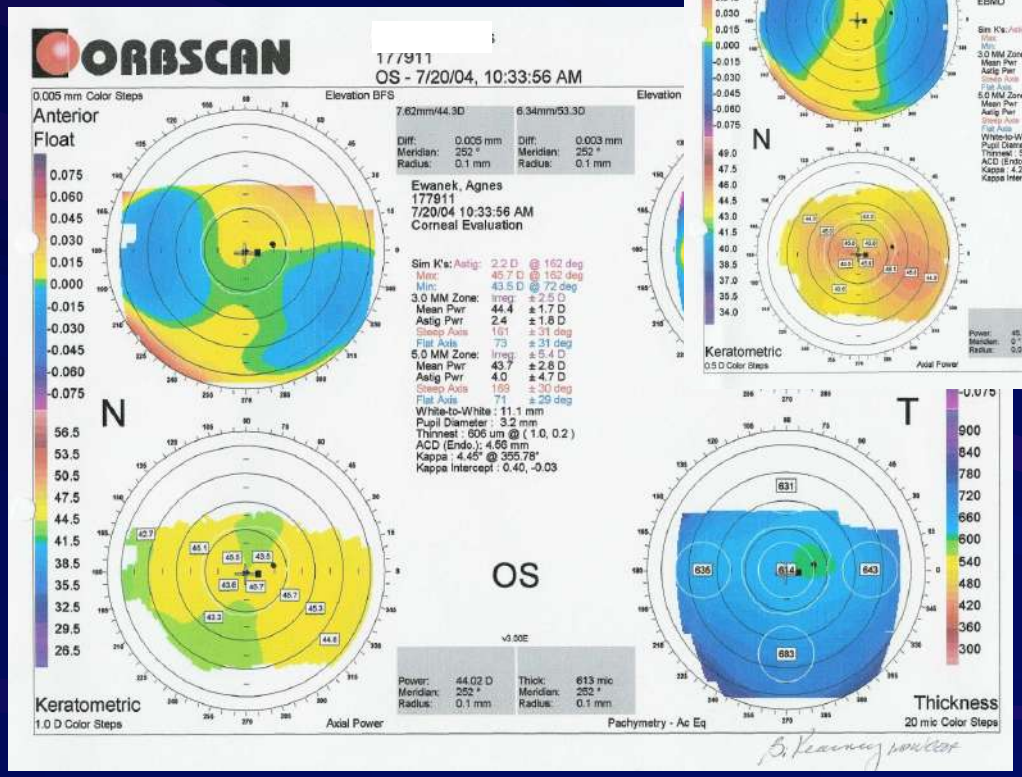

20/25 BVA

OS

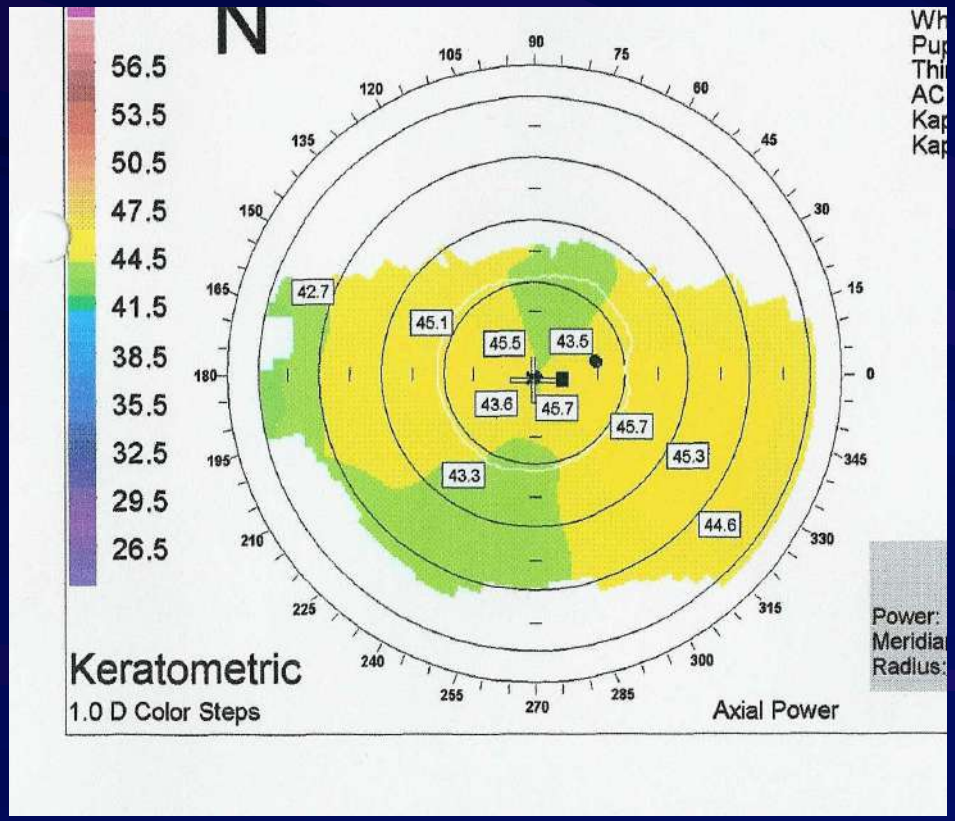
N
56.5
53.5
50.5
47.5
44.5
41.5
38.5
35.5
32.5
29.5
26.5
42.7
45.1
45.5
43.5
43.6
45.7
45.7
45.3
43.3
44.6
Keratometric
1.0 D Color Steps
Axial Power

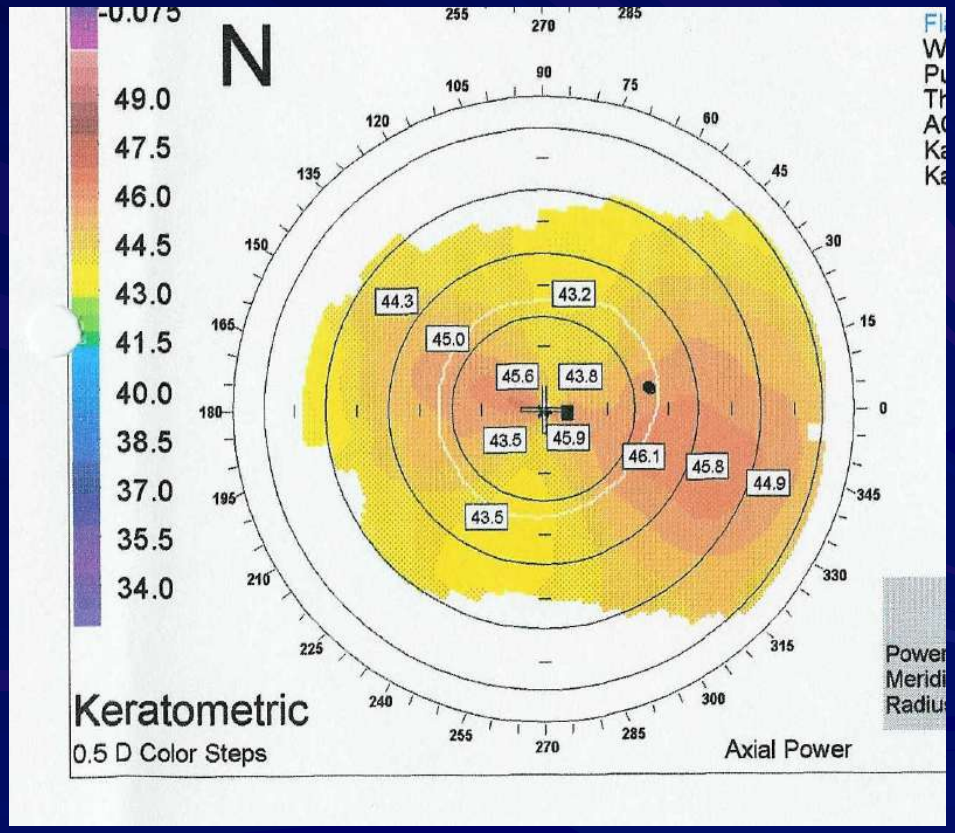
N
-0.075
49.0
47.5
46.0
44.5
43.0
41.5
40.0
38.5
37.0
35.5
34.0
44.3
43.2
45.0
45.6
43.8
43.5
45.9
46.1
45.8
44.9
43.5
Keratometric
0.5 D Color Steps
Axial Power

Amiodarone Ocular Side Effects

- Halos and colored lights, reported symptoms
- Corneal opacities
  - Epithelial basal cell layer
  - Bilateral, dose and duration related
  - Reversible
  - Dot, Linear, cornea verticillata (whorl like pattern found later)
- Conjunctiva, lens, retina and optic nerve deposits
- Optic neuropathy has been reported
  - Unilateral and bilateral cases

http://www.optometry.co.uk/articles/20020517/patel20020517.pdf

Cornea Verticillata (Whorls)

- Drug-induced
  - Amiodarone
  - Chloroquine/hydroxychloroquine
  - Tamoxifen
  - Chlorpomazine
  - Indomethacin

Another Patient Complaining of Blurry Vision Taking Amiodarone

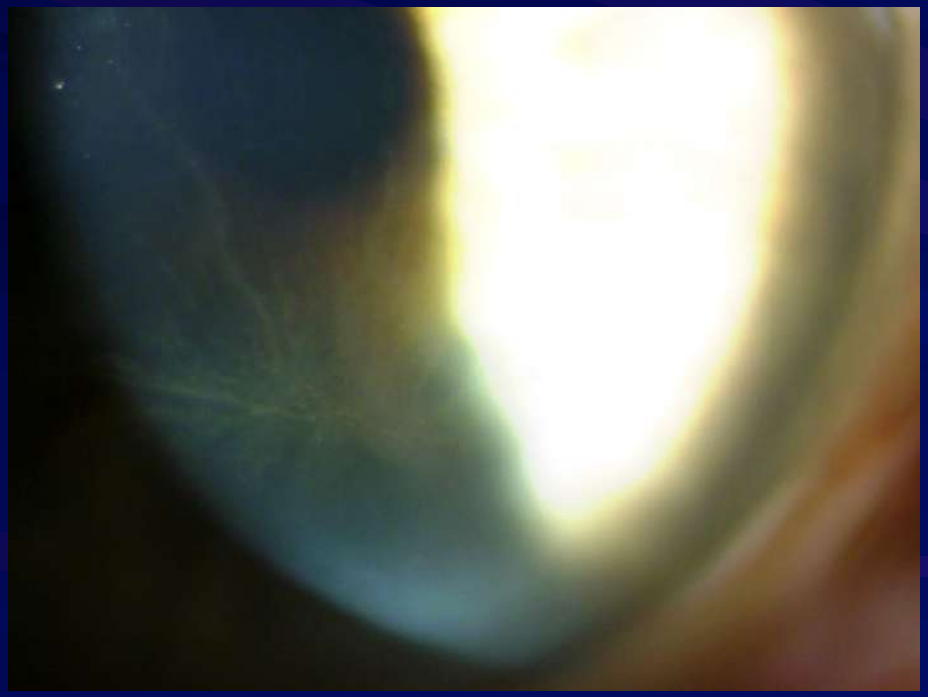

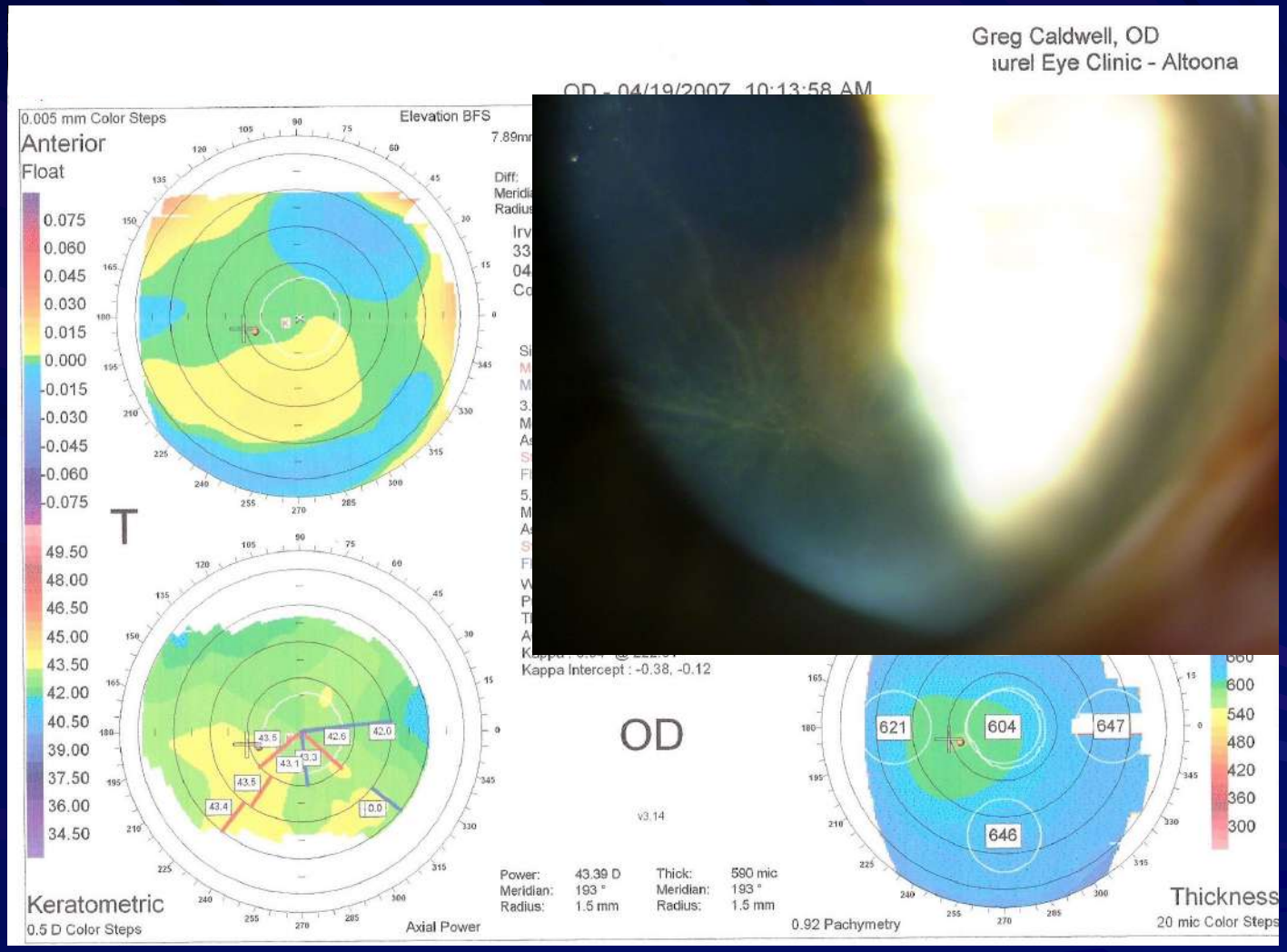
Greg Caldwell, OD
urel Eye Clinic - Altoona
0.005 mm Color Steps
Elevation BFS
Anterior
Float
0.075
0.060
0.045
0.030
0.015
0.000
-0.015
-0.030
-0.045
-0.060
-0.075
T
49.50
48.00
46.50
45.00
43.50
42.00
40.50
39.00
37.50
36.00
34.50
Kappa Intercept : -0.38, -0.12
OD
v3.14
Power: 43.39 D
Meridian: 193 °
Radius: 1.5 mm
Thick: 590 mic
Meridian: 193 °
Radius: 1.5 mm
Keratometric
0.5 D Color Steps
Axial Power
621
604
647
646
600
540
480
420
360
300
Thickness
20 mic Color Steps
0.92 Pachymetry

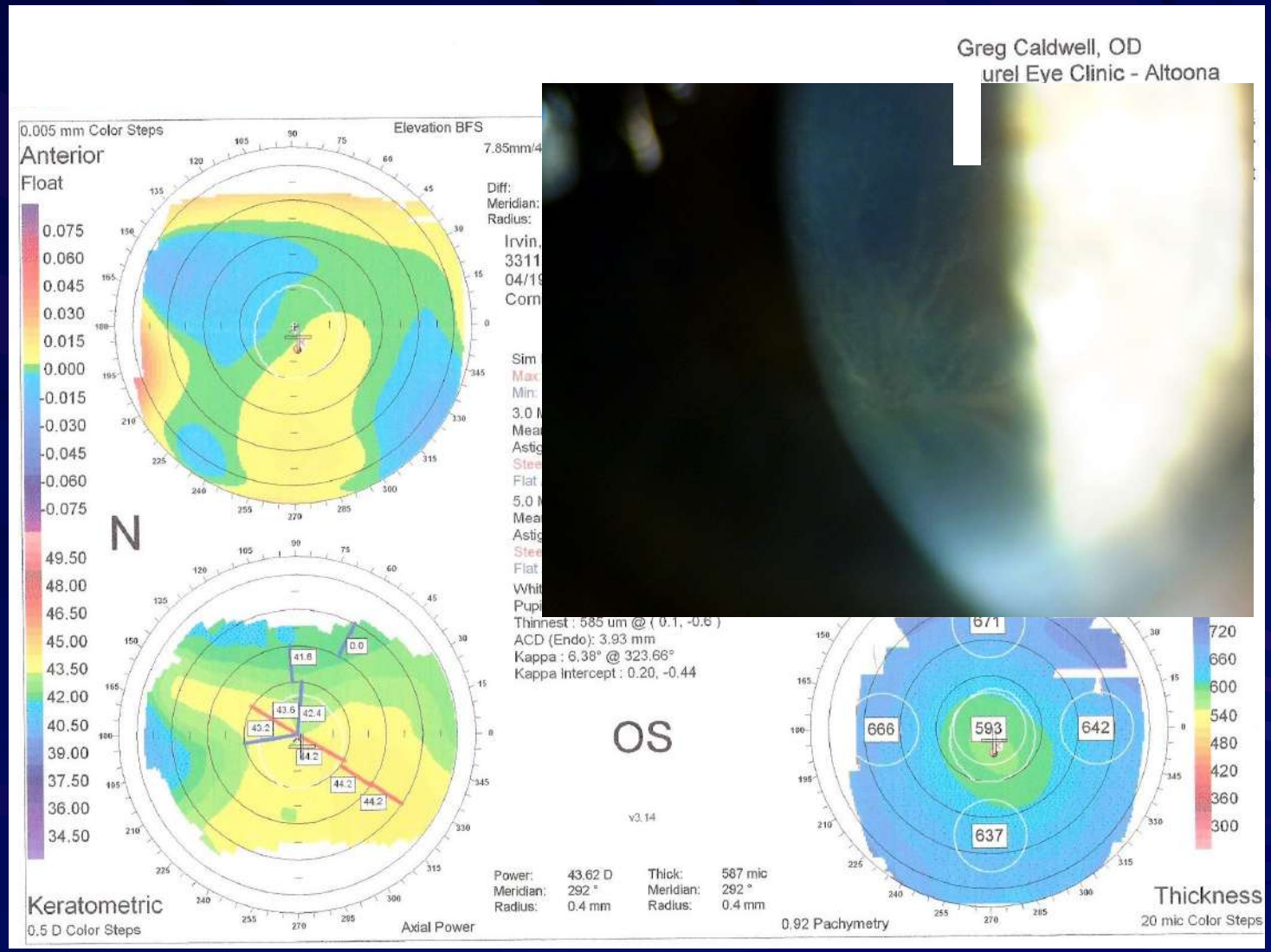
Greg Caldwell, OD
urel Eye Clinic - Altoona
0.005 mm Color Steps
Elevation BFS
Anterior
Float
0.075
0.060
0.045
0.030
0.015
0.000
-0.015
-0.030
-0.045
-0.060
-0.075
N
49.50
48.00
46.50
45.00
43.50
42.00
40.50
39.00
37.50
36.00
34.50
Keratometric
0.5 D Color Steps
Axial Power
Thinnest : 585 um @ (0.1, -0.6)
ACD (Endo): 3.93 mm
Kappa : 6.38° @ 323.66°
Kappa Intercept : 0.20, -0.44
OS
v3.14
Power: 43.62 D
Meridian: 292 °
Radius: 0.4 mm
Thick: 587 mic
Meridian: 292 °
Radius: 0.4 mm
0.92 Pachymetry
Thickness
20 mic Color Steps
720
660
600
540
480
420
360
300
671
666
593
642
637

Case 11

67-year-old man complains of vision slowly deteriorating over the past 8 months

- History of NA-ION 10 months ago OD
- Patient sees family physician for physical due to recent NA-ION
  - Patient has not been to PCP for 35 years
  - Patient started Cardarone
  - VA 20/80 OD 20/25 OS (9 months ago)
- VA 20/400 OD 20/200 OS (today)
- CF: severe constriction OU
- SLE: vortex corneal whorls OU

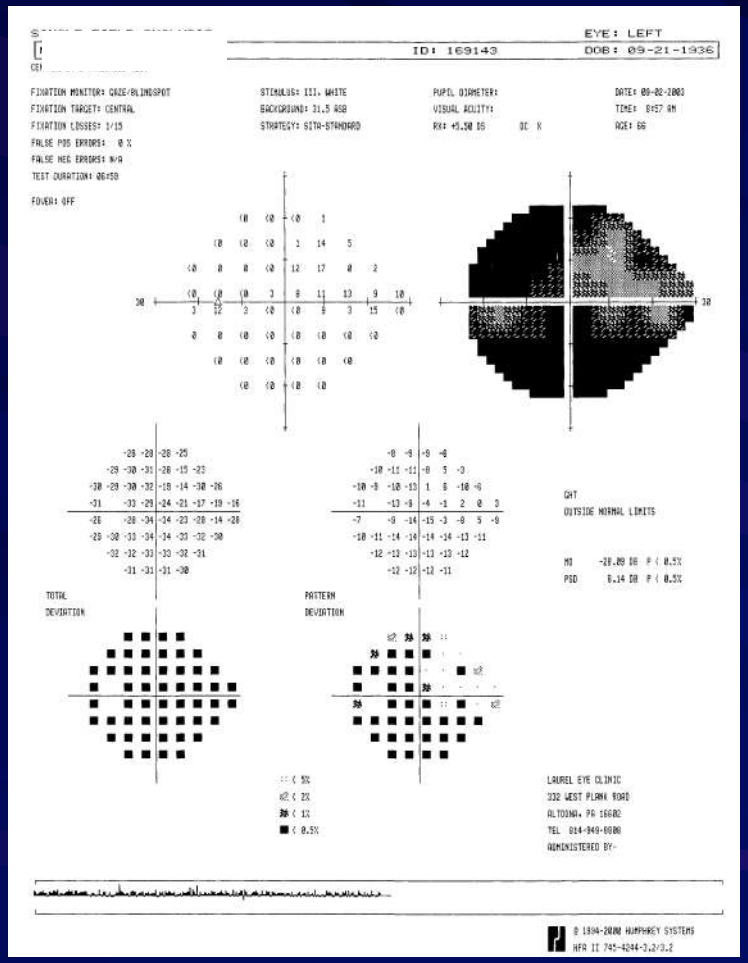
EYE: LEFT
ID: 169143
DOB: 09-21-1936
FIXATION MONITOR: GAZE/BLINDSPOT
FIXATION TARGET: CENTRAL
FIXATION LOSSES: 1/15
FALSE POS ERRORS: 0 %
FALSE NEG ERRORS: N/A
TEST DURATION: 06:58
FOVEA: OFF
STIMULUS: III, WHITE
BACKGROUND: 31.5 ASB
STRATEGY: SITA-STANDARD
PUPIL DIAMETER:
VISUAL ACUITY:
RX: +5.50 DS DC X
DATE: 09-02-2003
TIME: 8:57 AM
AGE: 66
OUTSIDE NORMAL LIMITS
MD -28.89 DB P < 0.5%
PSD 6.14 DB P < 0.5%
TOTAL DEVIATION
PATTERN DEVIATION
LAUREL EYE CLINIC
332 WEST PLANK ROAD
ALTOONA, PA 16602
TEL 814-949-0000
ADMINISTERED BY-
© 1994-2000 HUMPHREY SYSTEMS
HFA II 745-4244-3.2/3.2


EYE: RIGHT
ID: 169143
DOB: 09-21-1936
FIXATION MONITOR: GAZE/BLINDSPOT
FIXATION TARGET: CENTRAL
FIXATION LOSSES: 4/13 XX
FALSE POS ERRORS: 2 %
FALSE NEG ERRORS: N/A
TEST DURATION: 06:59
FOVEA: OFF
STIMULUS: III, WHITE
BACKGROUND: 31.5 ASB
STRATEGY: SITA-STANDARD
PUPIL DIAMETER:
VISUAL ACUITY:
RX: +5.75 DS DC X
DATE: 09-02-2003
TIME: 9:06 AM
AGE: 66
LOW PATIENT RELIABILITY
OUTSIDE NORMAL LIMITS
MD -30.53 DB P < 0.5%
PSD 3.85 DB P < 0.5%
TOTAL DEVIATION
PATTERN DEVIATION
LAUREL EYE CLINIC
332 WEST PLANK ROAD
ALTOONA, PA 16602
TEL 814-949-0000
ADMINISTERED BY-

Amiodarone Optic Neuropathy

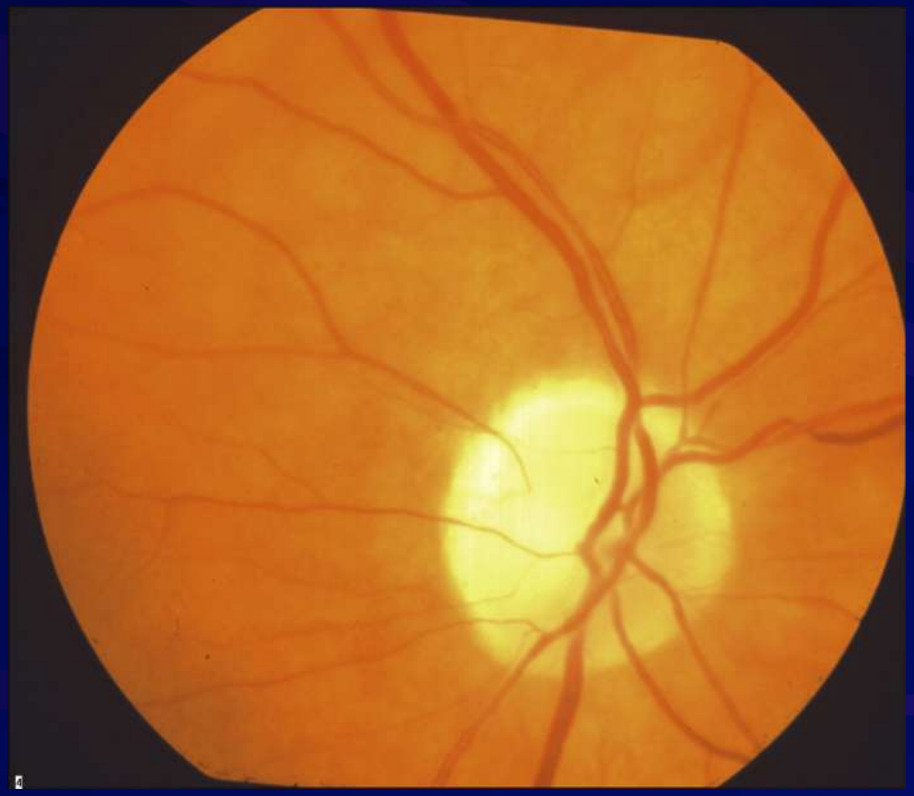

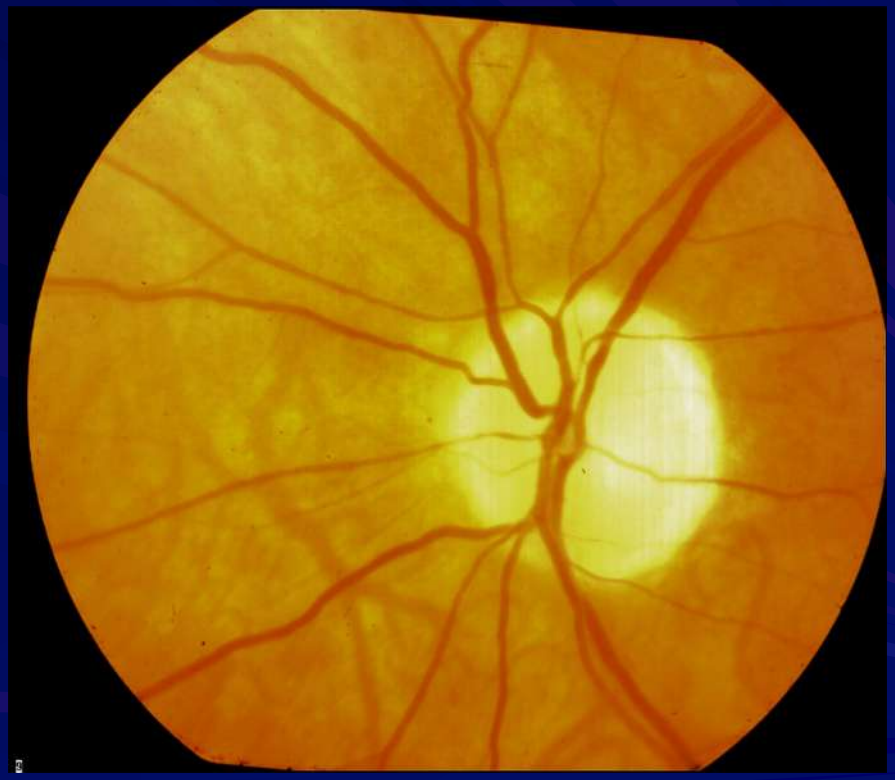

haTe-Doxycycline and Minocycline

Benign intracranial hypertension

"It's not rare if it's in your chair"

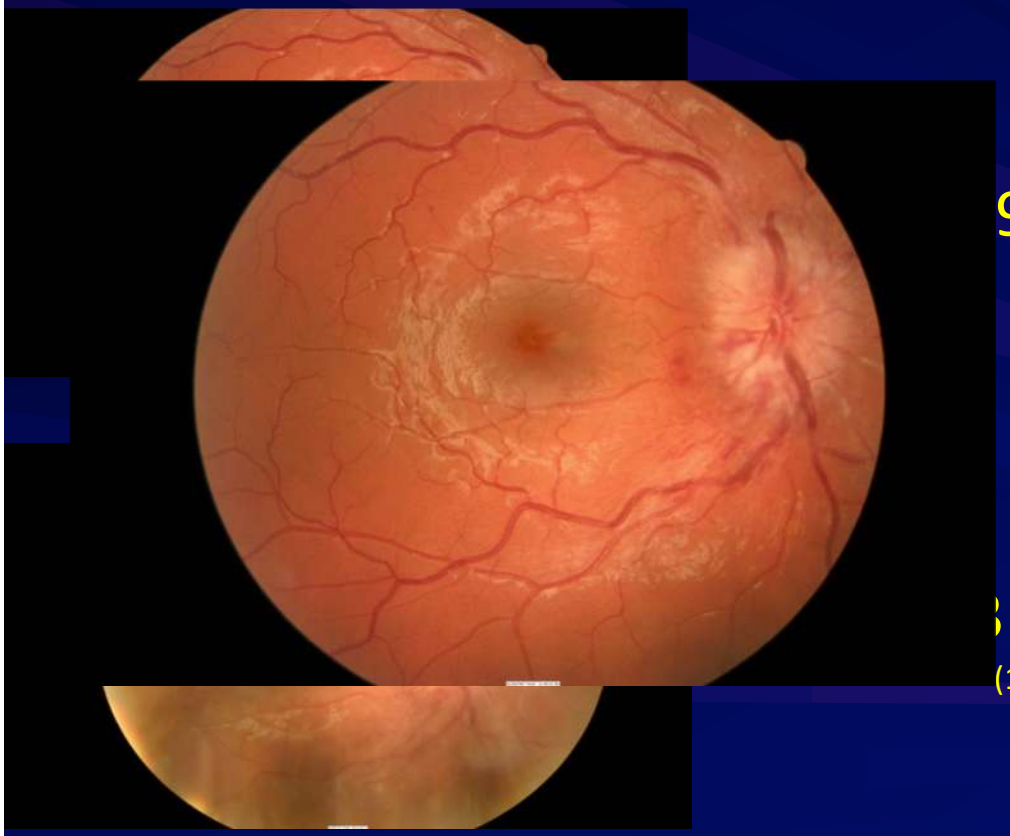

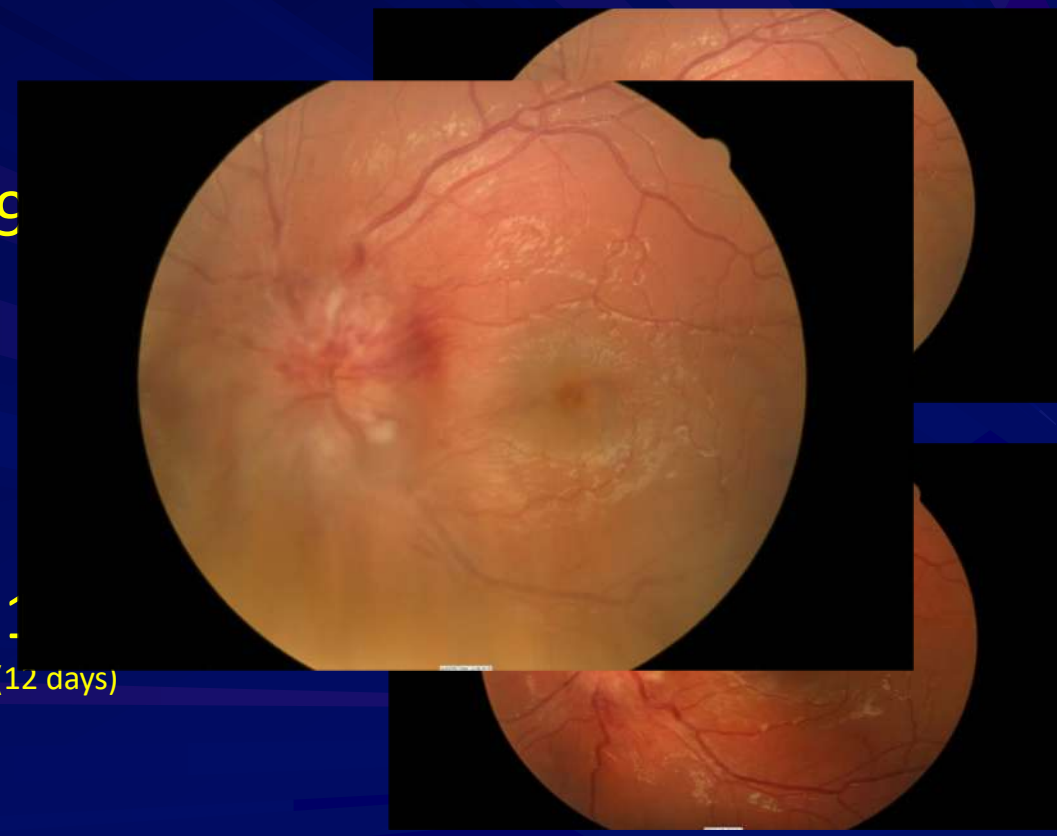

(12 days)

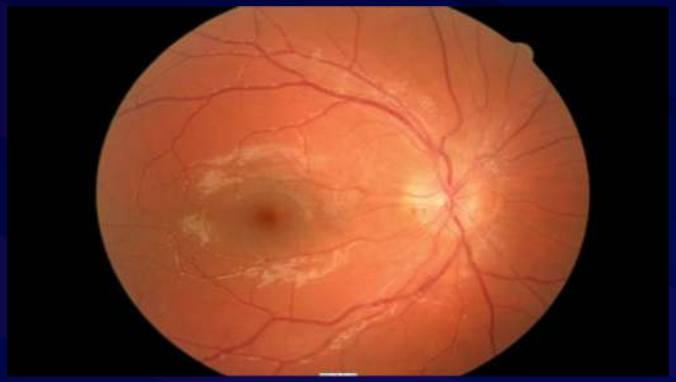

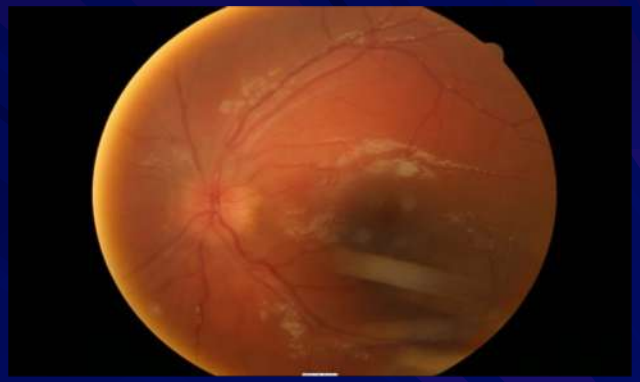

9-13-2010
(25 days)

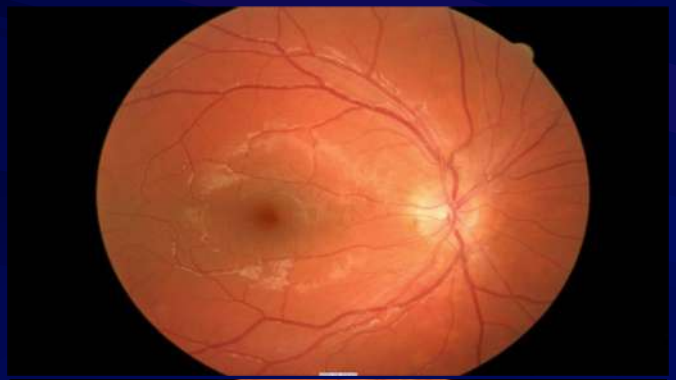

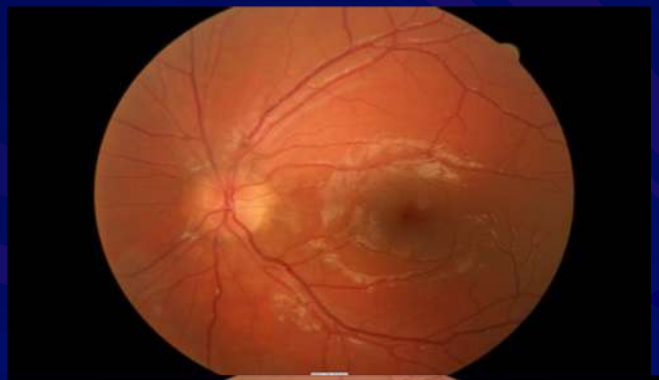

10-6-2010
(48 days)

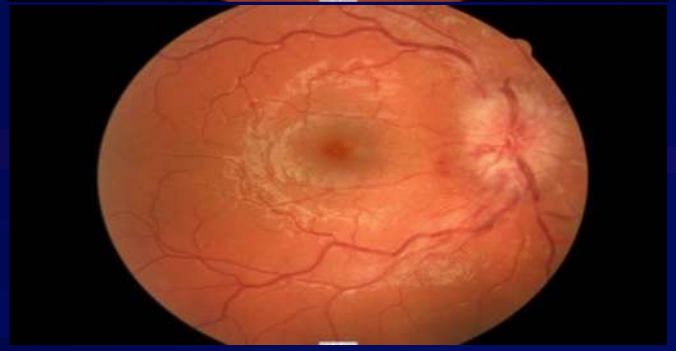

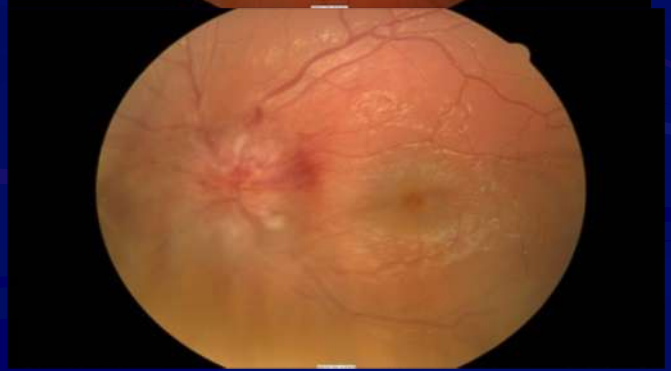

8-19-2010

OMG

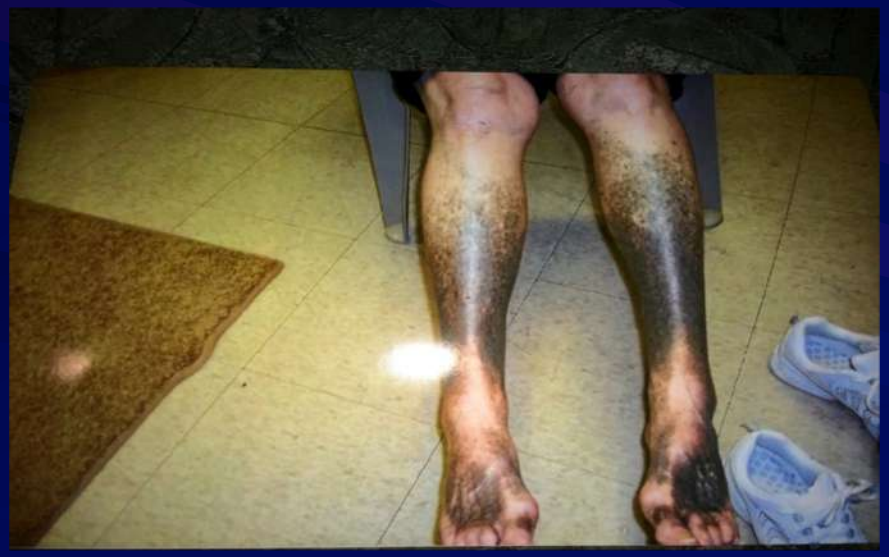

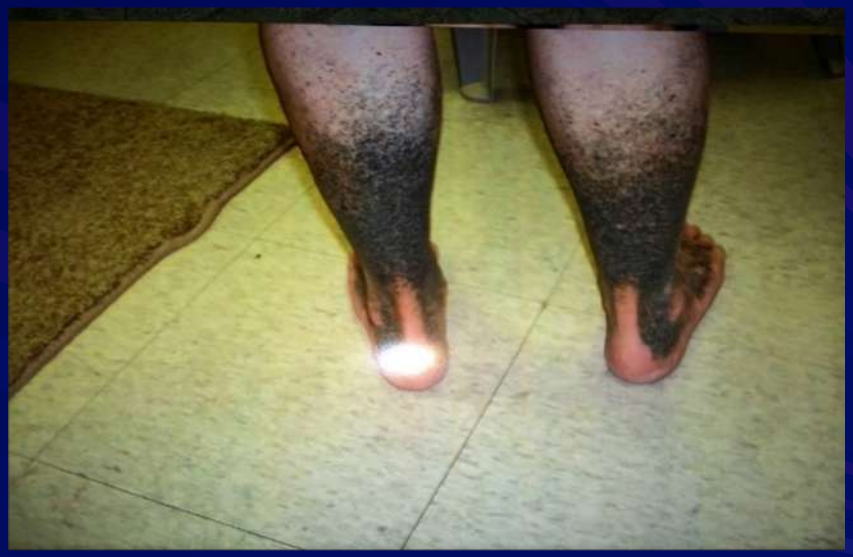

6 Months Later

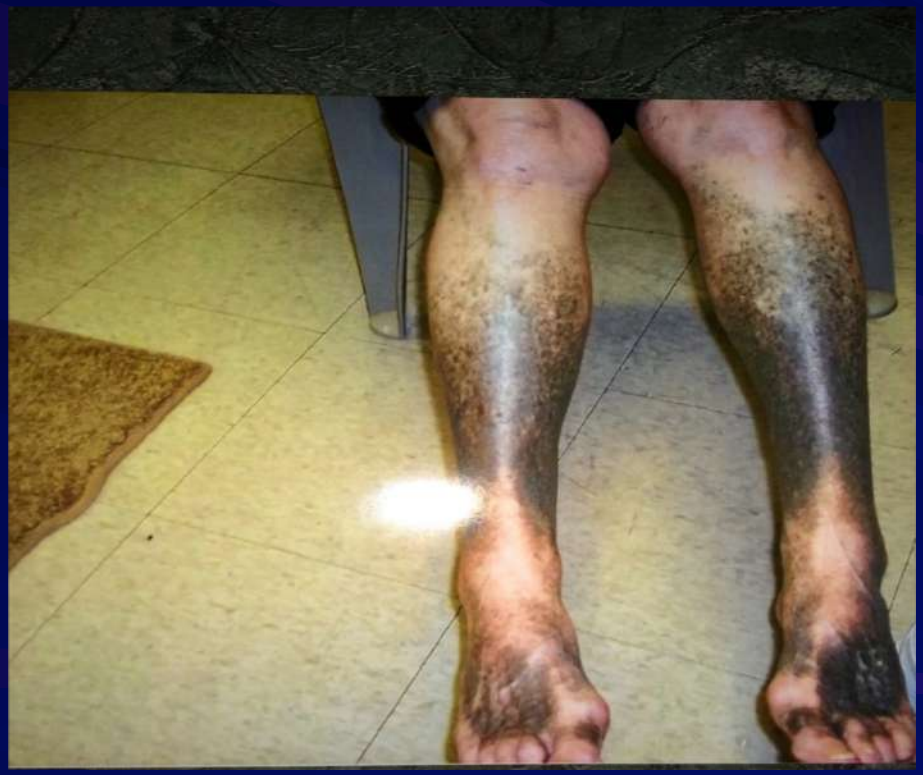

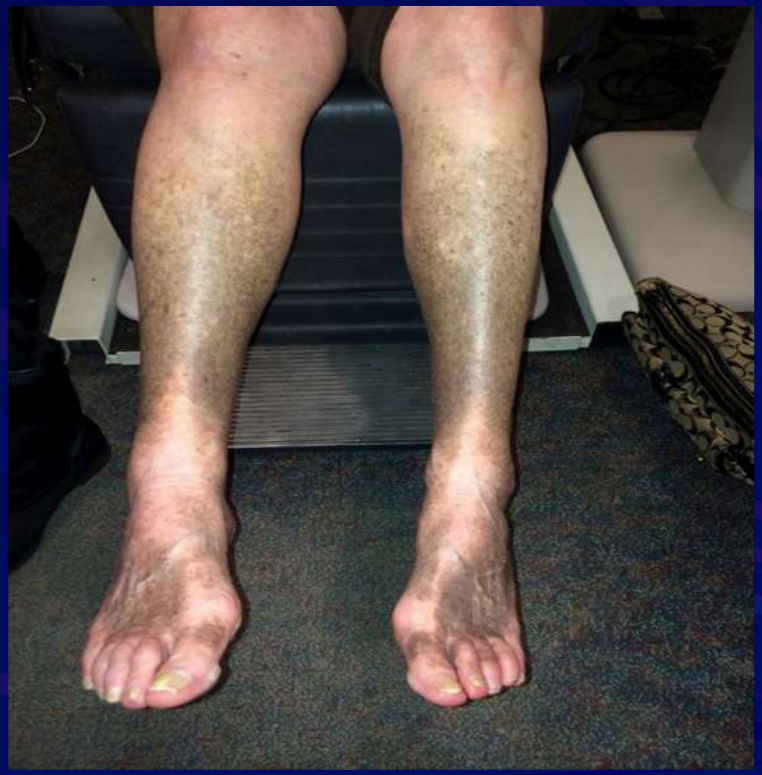

1 Year Later

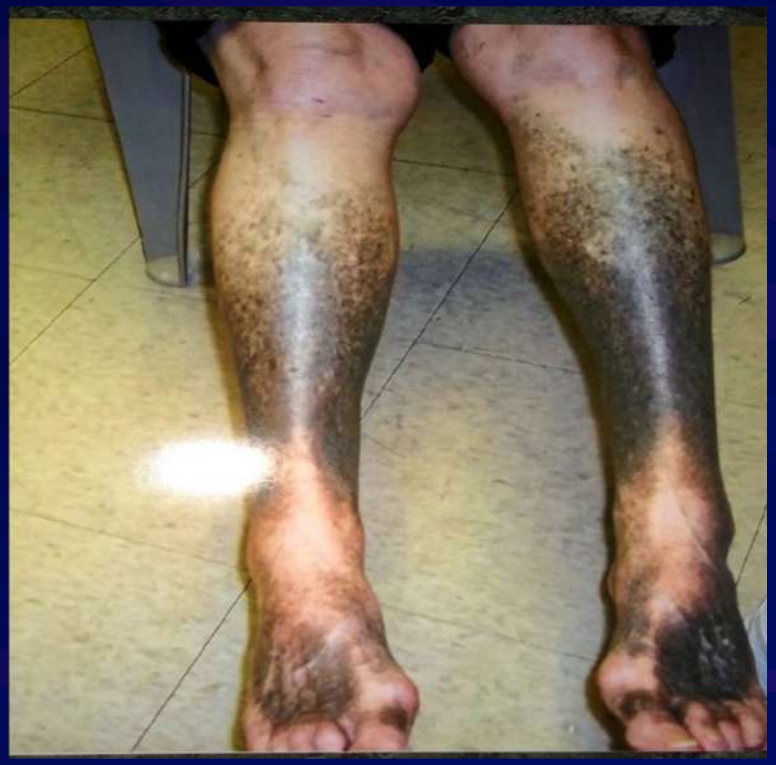

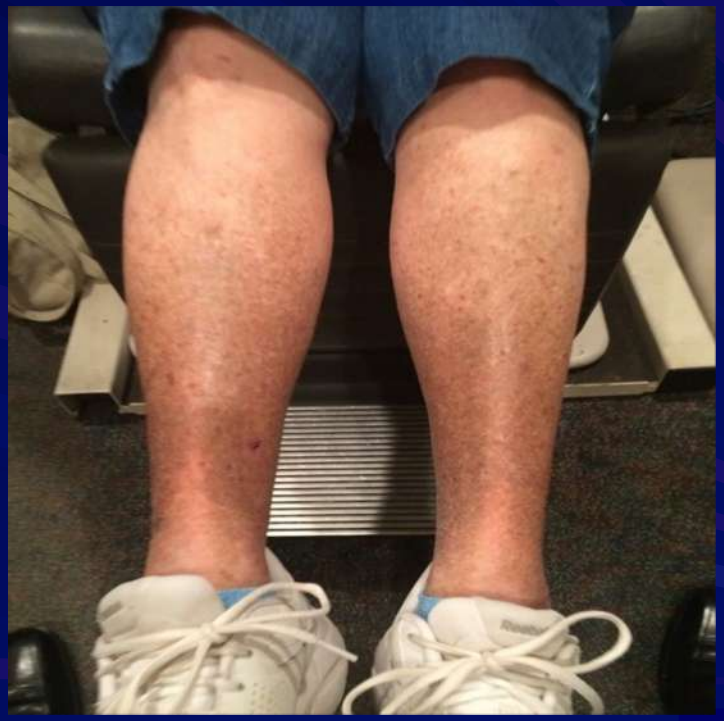

hatE- 81-year-old woman

- Calls the office reporting decreased vision (3-13-19)
  - Was warned vision could decrease due her medications
  - Glaucoma patient
- Mycobacterium avium infection
- Ethambutol, rifampin, and azithromycin
  - Ethambutol started October 2017
- Glaucoma patient
  - Was on latanoprost and Rhopressa
  - Had KDB
    - No glaucoma drops currently

3/13/19 20/30, 20/100, 20/25

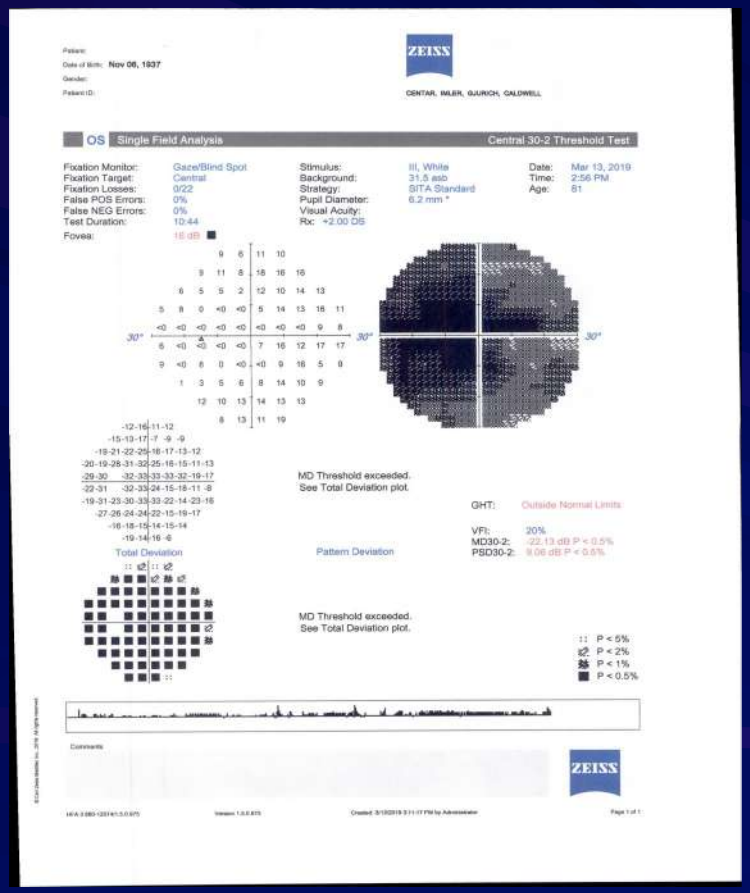

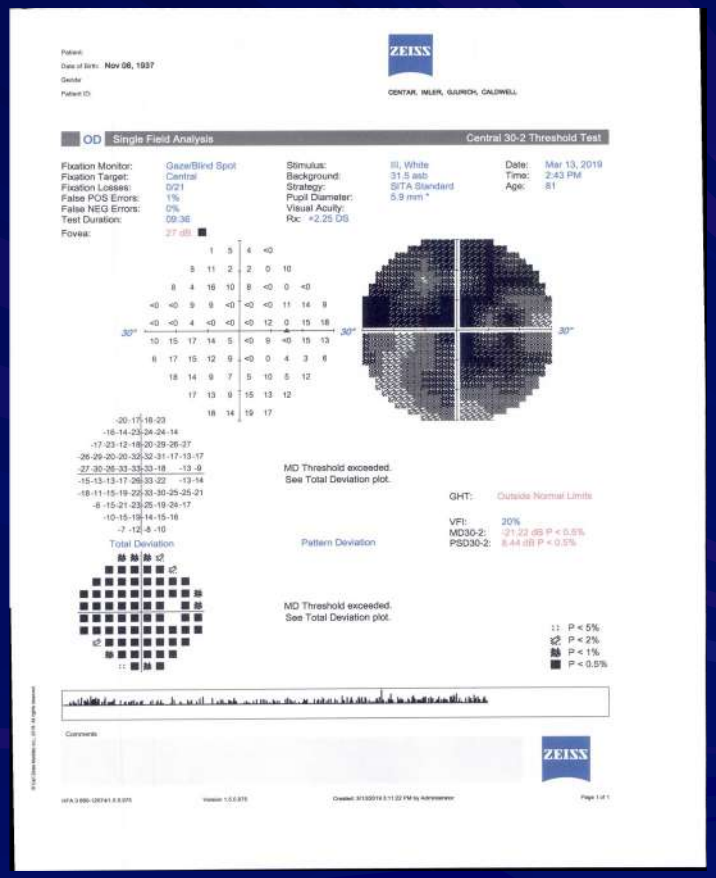

4/29/19 20/25, 20/50, 20/20

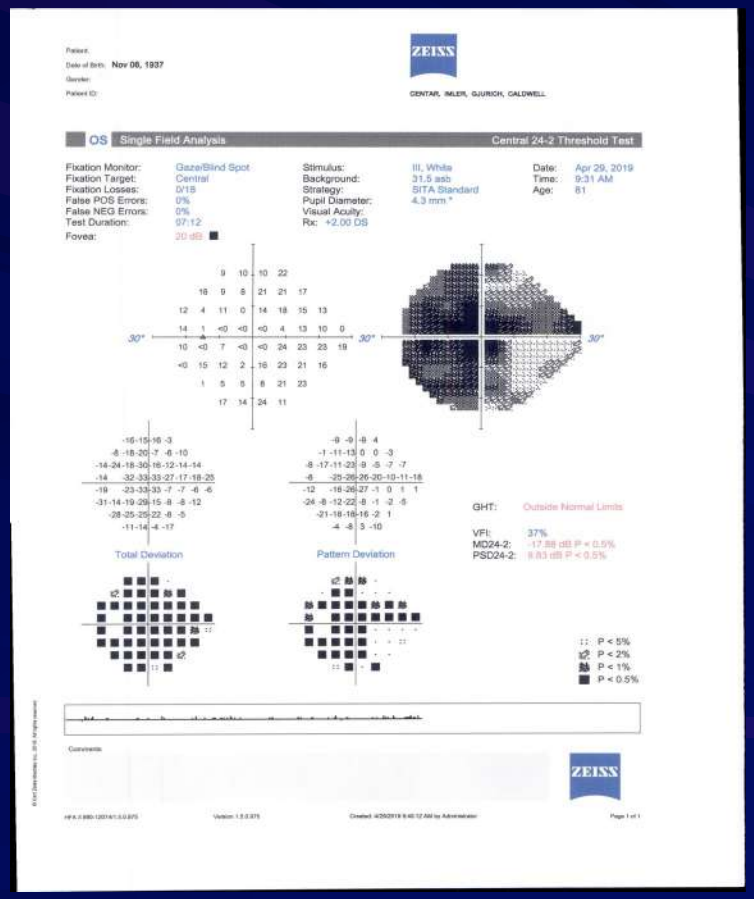

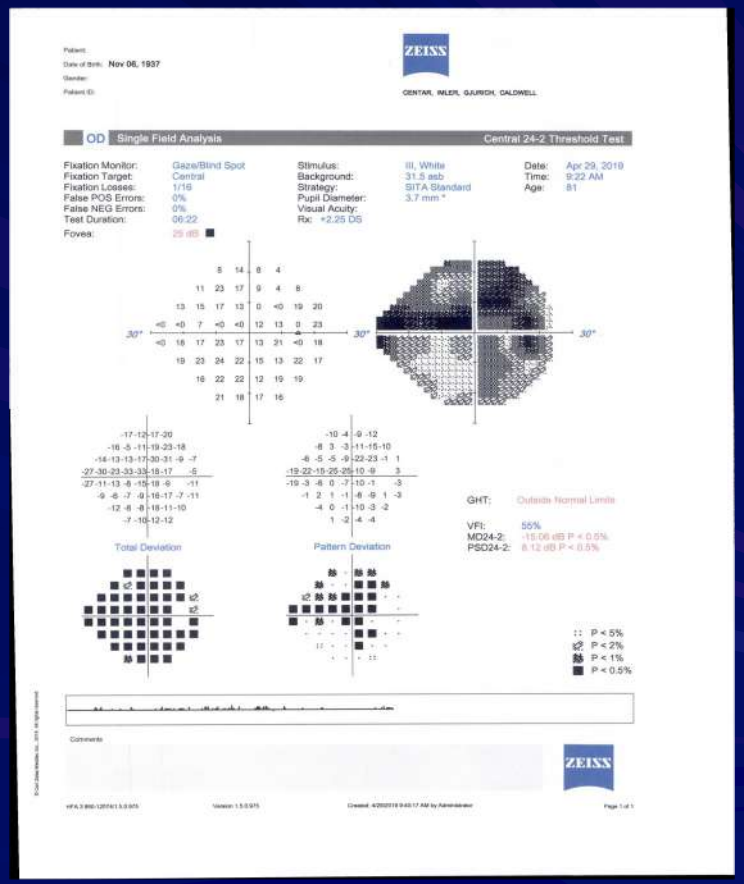

7/29/19 20/20, 20/25, 20/20

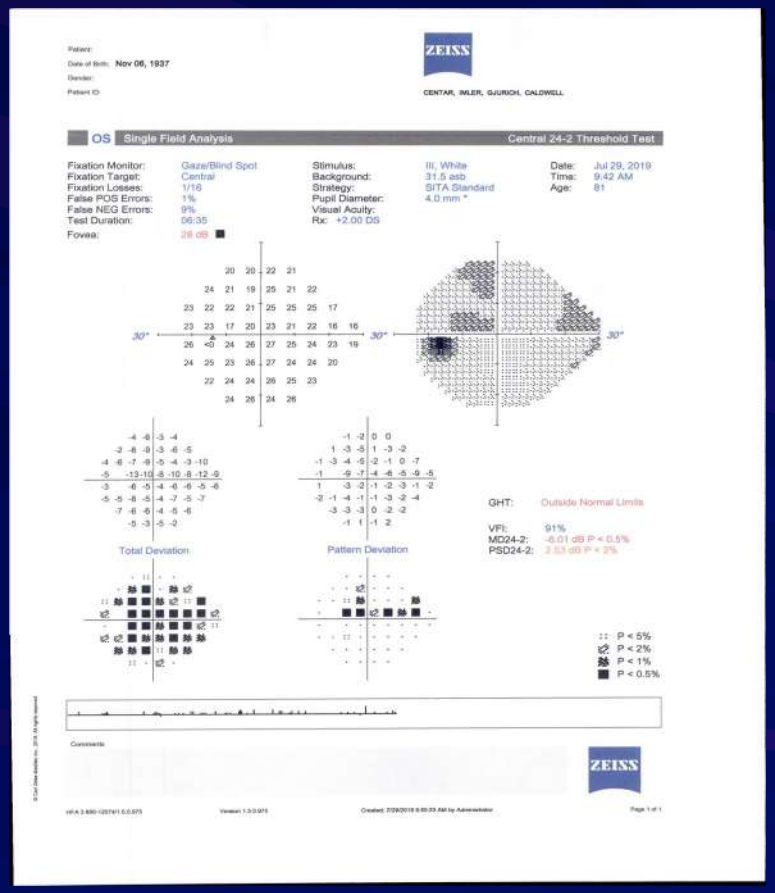

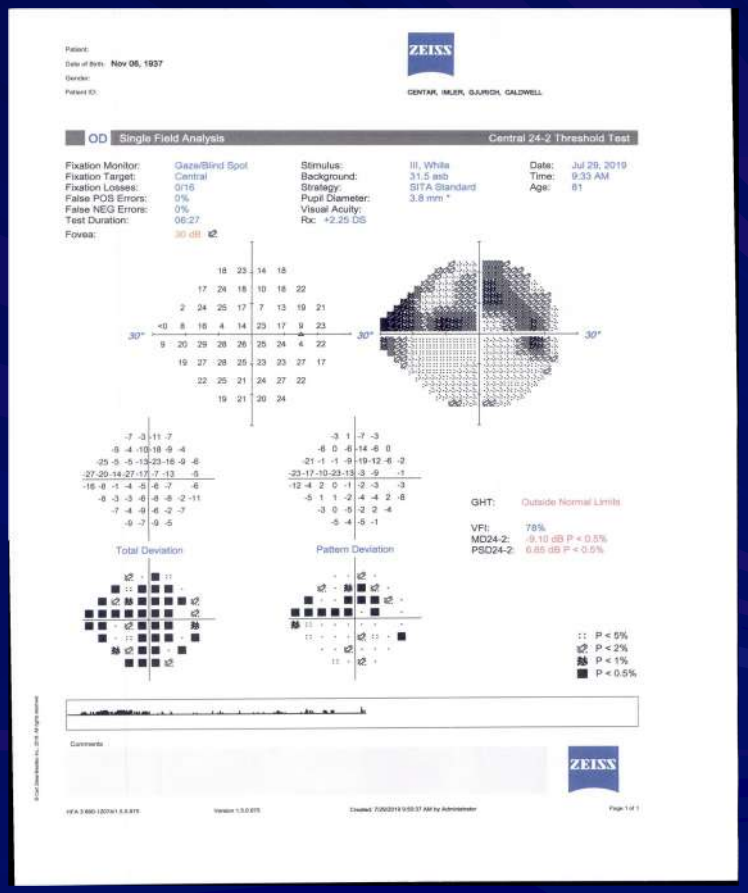

Progression

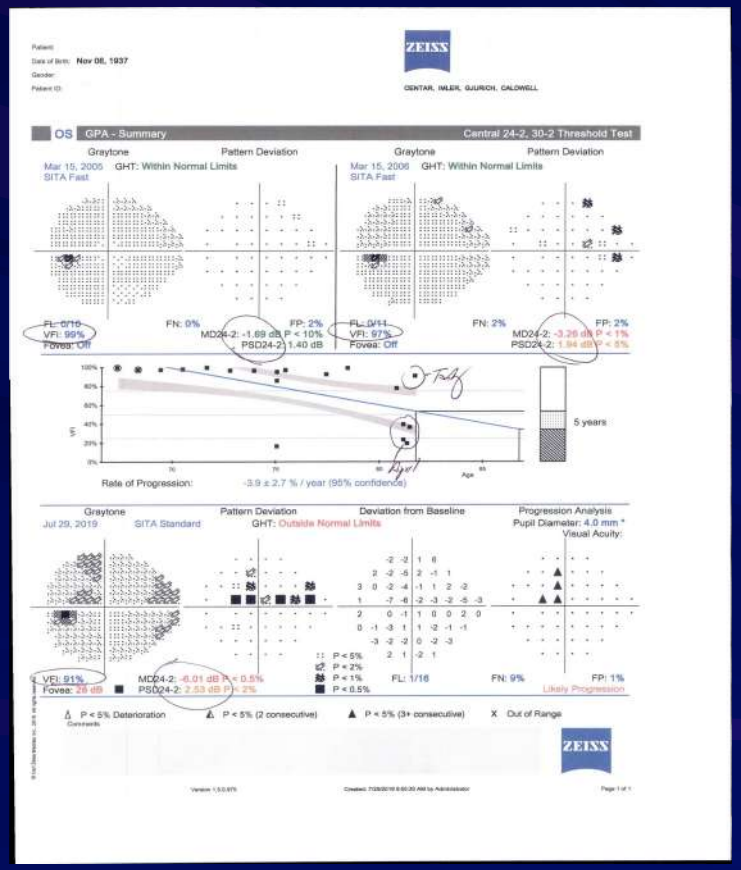

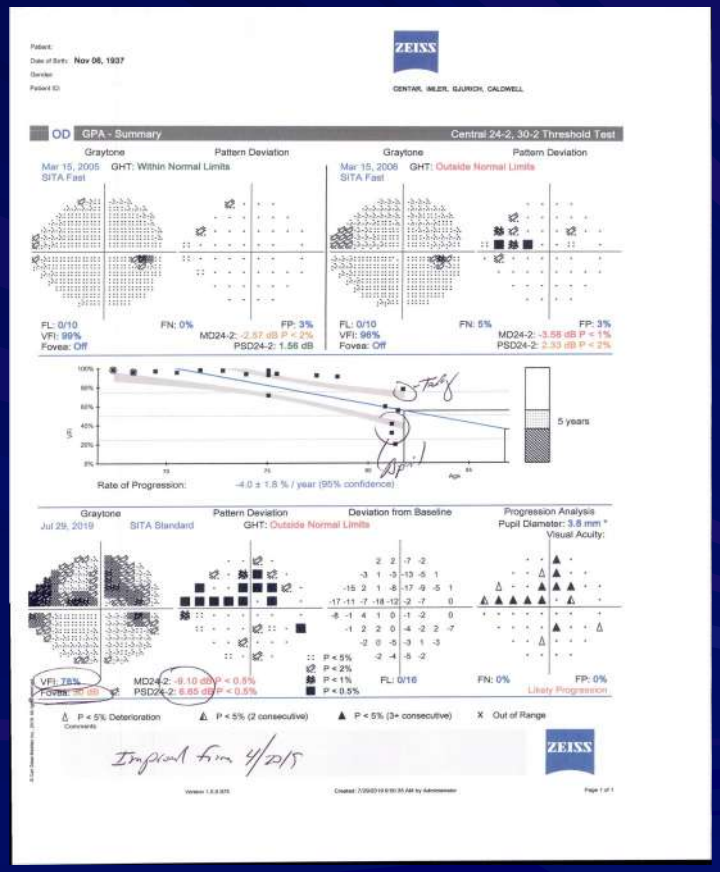

Optometric Public Service Announcement

Pay Very Close Attention

80-year-old man

- Reports a sudden loss of vision OD
- Vision is count fingers at 2 feet OD and 20/25 OS
- APD OD grade 4
- Fundus photos OU

Photos OU

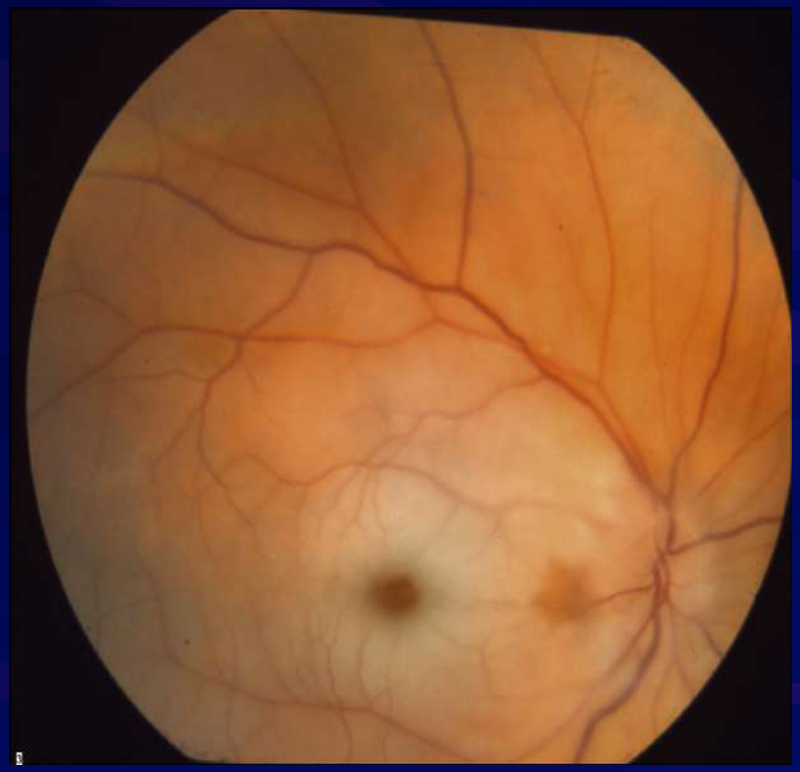

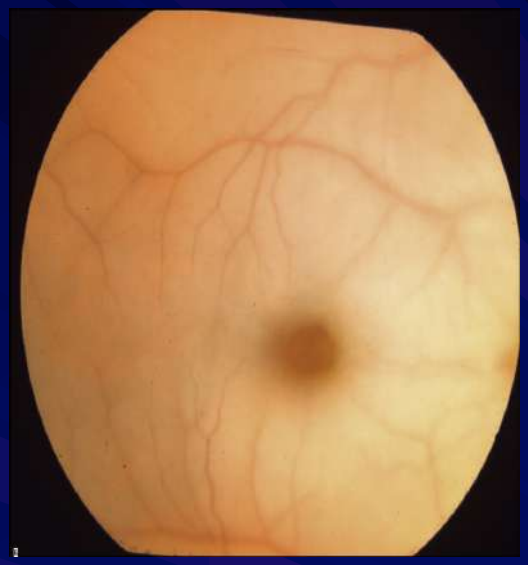

CRAO Treatment/Work-Up/Follow-Up?

- Anterior cham racentesis (le 24 hours)
- STAT blood wo
  - 2-10% of all CRAO nbosis from Giant Cell Arteritis (GCA)
  - Sed-rate
  - C-reactive protein
    - Qualitative or quan
  - CBC with diff
- Monitor for n larization, e o weeks

CRAO, BRAO, TIA (amaurosis fugax)

- Acute Stroke Ready Hospital
  - Certification recognizes hospitals that meet standards to support better outcomes for stroke care as part of a stroke system of care
  - Developed in collaboration with the Joint Commission (TJC), eligibility standards include:
  - Dedicated stroke-focused program
  - Staffing by qualified medical professionals trained in stroke care
  - Relationship with local emergency management systems (EMS) that encourages training in field assessment tools and communication with the hospital prior to bringing a patient with a stroke to the emergency department
  - Access to stroke expertise 24 hours a day, 7 days a week (in person or via telemedicine) and transfer agreements with facilities that provide primary or comprehensive stroke services.
  - 24/7 ability to perform rapid diagnostic imaging and laboratory testing to facilitate the administration for IV thrombolytics in eligible patients
  - Streamlined flow of patient information while protecting patient rights, security and privacy
  - Use of data to assess and continually improve quality of care for stroke patients
- Warn hospital if suspicion for GCA
- 20% of stroke or heart attack within 3 years
- However of those who experienced CVA or MI
  - 80% were within 24-48 hours; those remaining
  - 50% occurred in 2 weeks
  - Majority within the next 90 days
- Not PCP, not retinologist, just the Acute Stroke Ready Hospital!

Acute Stroke Ready Hospital

- Is the basic level stroke hospital, better than not certified
  - This was created in 2015
- If you have access to a: (Even Better)
  - Primary Stroke Center
  - Thrombectomy-Capable Stroke Center
  - Comprehensive Stroke Center even better

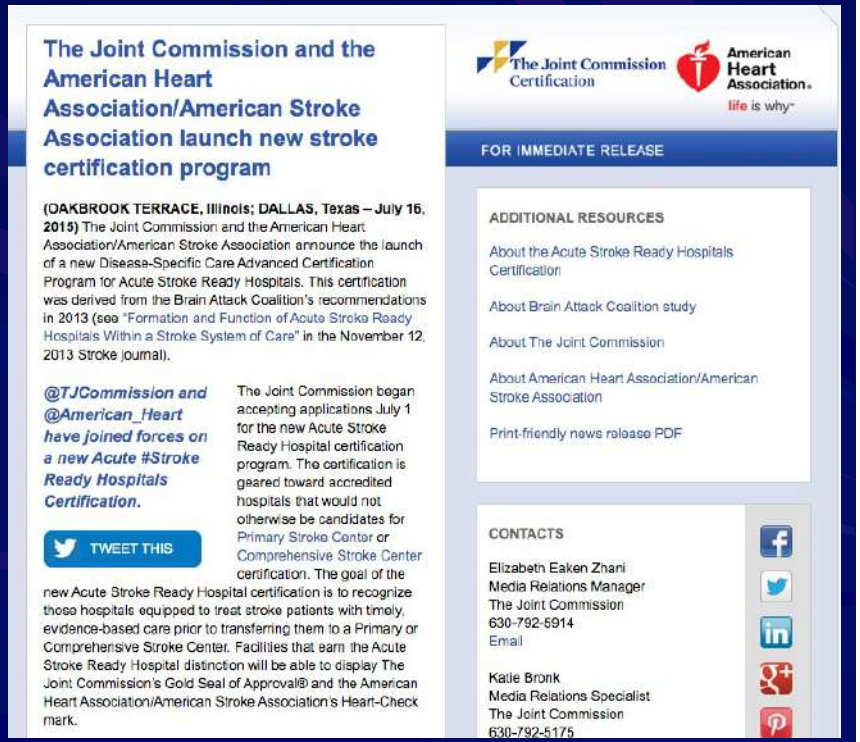

The Joint Commission and the American Heart Association/American Stroke Association launch new stroke certification program

The Joint Commission Certification

American Heart Association. life is why

FOR IMMEDIATE RELEASE

(OAKBROOK TERRACE, Illinois; DALLAS, Texas – July 16, 2015) The Joint Commission and the American Heart Association/American Stroke Association announce the launch of a new Disease-Specific Care Advanced Certification Program for Acute Stroke Ready Hospitals. This certification was derived from the Brain Attack Coalition's recommendations in 2013 (see "Formation and Function of Acute Stroke Ready Hospitals Within a Stroke System of Care" in the November 12, 2013 Stroke journal).

@TJCommission and @American_Heart have joined forces on a new Acute #Stroke Ready Hospitals Certification.

TWEET THIS

The Joint Commission began accepting applications July 1 for the new Acute Stroke Ready Hospital certification program. The certification is geared toward accredited hospitals that would not otherwise be candidates for Primary Stroke Center or Comprehensive Stroke Center certification. The goal of the new Acute Stroke Ready Hospital certification is to recognize those hospitals equipped to treat stroke patients with timely, evidence-based care prior to transferring them to a Primary or Comprehensive Stroke Center. Facilities that earn the Acute Stroke Ready Hospital distinction will be able to display The Joint Commission's Gold Seal of Approval® and the American Heart Association/American Stroke Association's Heart-Check mark.

ADDITIONAL RESOURCES

About the Acute Stroke Ready Hospitals Certification

About Brain Attack Coalition study

About The Joint Commission

About American Heart Association/American Stroke Association

Print-friendly news release PDF

CONTACTS

Elizabeth Eaken Zhani
Media Relations Manager
The Joint Commission
630-792-5914
Email

Katie Bronk
Media Relations Specialist
The Joint Commission
630-792-5175

COUNTY	FACILITY NAME	Acute Stroke -ready; Comprehensive stroke Center; or Primary Stroke	CITY	ZIP	EXPIRES
CHESTER	Phoenixville Hospital	Primary Stroke Center	Phoenixville	19460	9/24/2021
CHESTER	Paoli Hospital	Primary Stroke Center	Paoli	19301	7/12/2021
CLEARFIELD	Penn Highlands Healthcare - DuBois	Primary Stroke Center	DuBois	15801	7/14/2020
CLINTON	Lock Haven Hospital	Acute Stroke - Ready	Lock Haven	17745	10/13/2020
COLUMBIA	Berwick Hospital	Acute Stroke - Ready	Berwick	18603	7/9/2021
CRAWFORD	Meadville Medical Center	Primary Stroke Center	Meadville	16335	3/29/2022
CUMBERLAND	UPMC - Pinnacle Hospitals - West Shore Campus	Primary Stroke Center	Mechanisburg	17050	11/8/2021
CUMBERLAND	UPMC Pinnacle Carlisle	Primary Stroke Center	Carlisle	17015	7/28/2020
CUMBERLAND	Geisinger Holy Spirit Hospital	Primary Stroke Center	Camp Hill	17011	8/18/2020
DAUPHIN	UPMC - Pinnacle Hospitals - Community Osteopathic	Primary Stroke Center	Harrisburg	17109	11/8/2021
DAUPHIN	UPMC - Pinnacle Hospitals - Harrisburg Campus	Primary Stroke Center	Harrisburg	17105	11/8/2021
DELAWARE	Main Line Hospital - Riddle Memorial Hospital	Primary Stroke Center	Media	19063	8/4/2020
DELAWARE	Taylor Hospital	Primary Stroke Center	Ridley Park	19078	11/6/2021
DELAWARE	Crozer Chester Medical Center	Primary Stroke Center	Upland	19013	11/6/2021
DELAWARE	Delaware County Memorial Hospital	Primary Stroke Center	Drexel Hill	19026	7/4/2020
ERIE	Millcreek Community Hospital	Primary Stroke Center	Erie	16509	1/8/2021
ERIE	UPMC Hamot	Comprehensive Stroke Center	Erie	16550	7/11/2021
FRANKLIN	Wellspan Waynesboro Hospital	Primary Stroke Center	Waynesboro	17268	9/17/2021
FRANKLIN	Wellspan Chambersburg Hospital	Primary Stroke Center	Chambersburg	17201	10/19/2021
INDIANA	Indiana Regional Medical Center	Primary Stroke Center	Indiana	15701	7/7/2020
LACKAWANNA	Regional Hospital of Scranton	Primary Stroke Center	Scranton	18510	5/7/2021
LACKAWANNA	Geisinger Community Medical Center	Primary Stroke Center	Scranton	18510	5/18/2021
LACKAWANNA	Moses Taylor Hospital	Primary Stroke Center	Scranton	18510	11/8/2021
LANCASTER	Lancaster General Hospital	Primary Stroke Center	Lancaster	17604	3/16/2021
LANCASTER	WellSpan - Ephrata Community	Primary Stroke Center	Ephrata	17522	9/12/2021
LANCASTER	UPMC Litiz	Primary Stroke Center	Litiz	17543	8/18/2020
LEBANON	Good Samaritan Hospital, The	Primary Stroke Center	Lebanon	17042	9/15/2020
LEHIGH	St. Luke's Hospital – Bethlehem	Comprehensive Stroke Center	Bethlehem	18015	8/28/2020

2:04 LTE

Amy Lynn Schaag ▶ ODs on Facebook 👀

November 27, 2018 ·

Last week I saw this [80-year-old male] patient with acute CRAO. I sent him for STAT GCA bloodwork and told him and his daughter that a carotid US should be done soon to evaluate risk for stroke (I did not make that part sound emergent). Unfortunately, he had a stroke the very next day. Since I make it a point to learn from mistakes, I did some research and found this article:

https://www.aao.org/eyenet/article/crao-harbinger-of-ischemic-stroke

...which states that patients with acute CRAO should always be sent to the ER for immediate stroke eval including MRI. How many of you do this? If not, why? And have you ever been burned? Thanks.

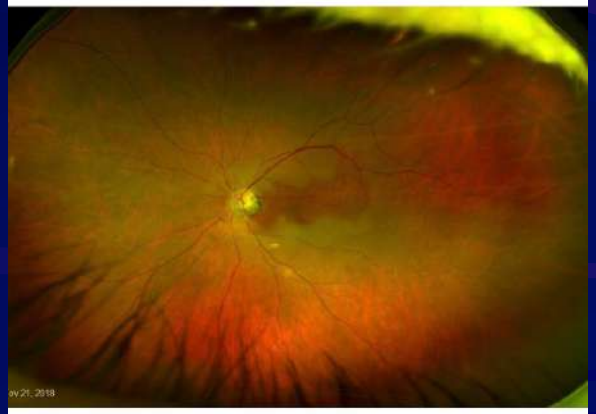

April 8, 2020 - COVID 19

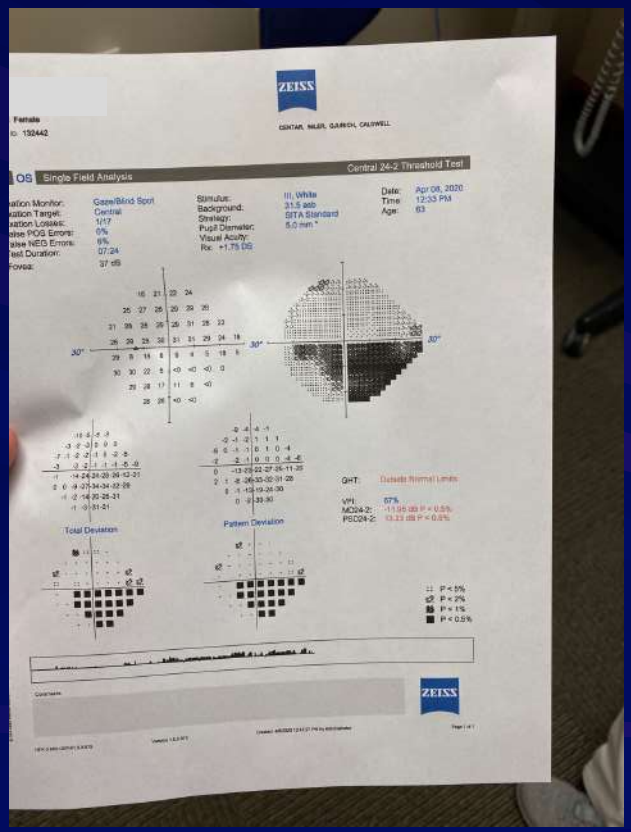

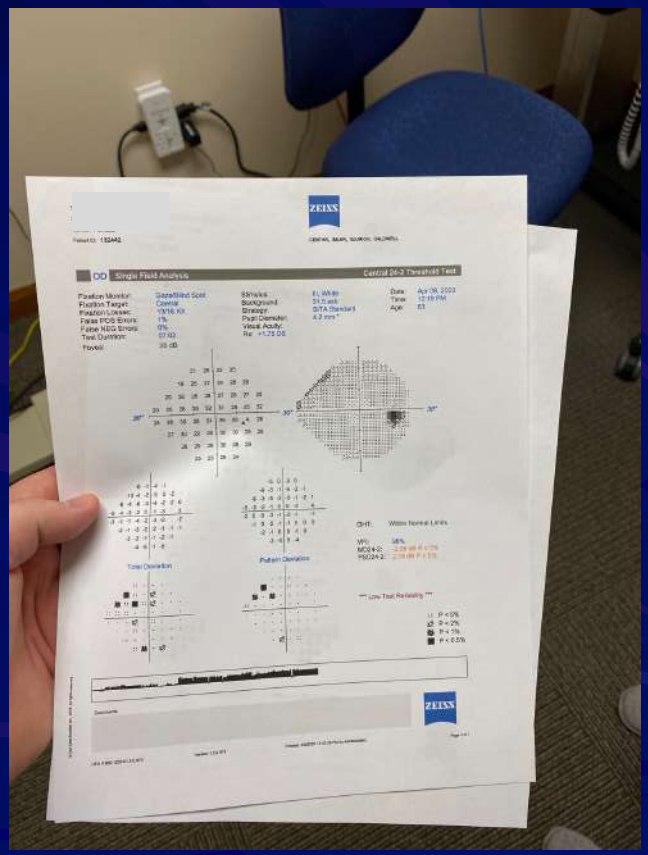

April 8, 2020 - COVID 19

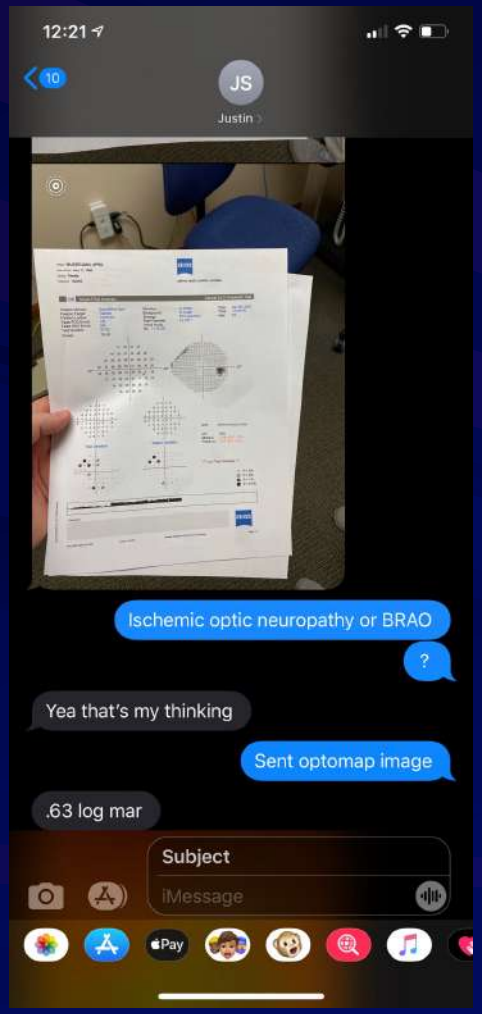

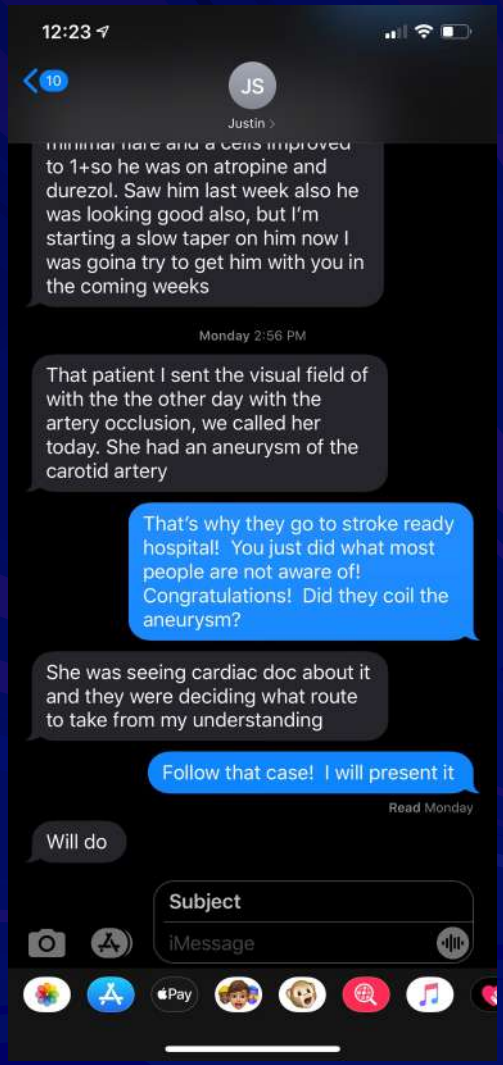

April 5, 2020 – COVID 19 Times

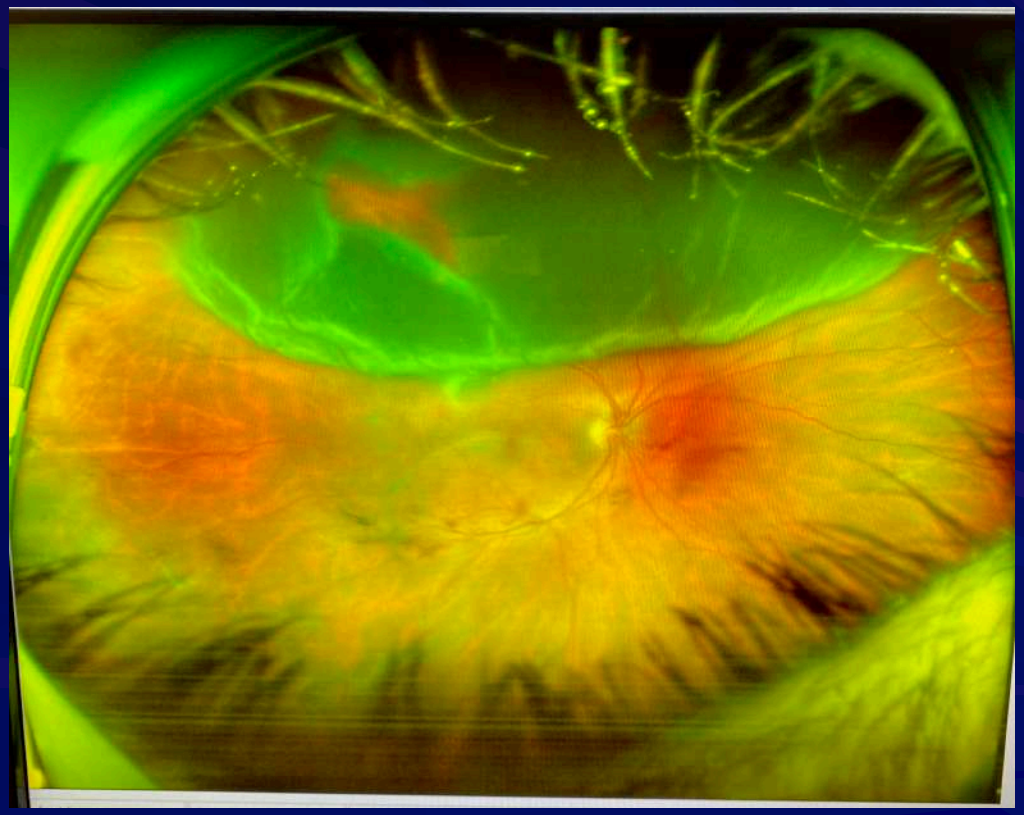

Case 1

25-year-old man

- Patient has been to 3 ophthalmologists and 1 optometrist in the past year
- Patient complains of a "ghost image" OS
- Has had 4 dilated exams in past year, and no diagnosis yet
- He is very passionate that his vision is clear OD and "ghosty"OS
  - He wants to know why

"Ghost Image" OS

Va 20 / 20
cc / 20

Current Correction
R -2.50-1.00 x 180
L -3.25-1.00 x 180

EOMS: full, unrestricted
CT: ortho D/N

PERRL (-)APD
CF: full by FC OU

- SLE-unremarkable
- Fundus-unremarkable
- Previous unremarkable tests
  - Topography
  - Fluorescein angiography
  - CAT scan
  - MRI

Any Thoughts About "Ghost Images"?



6

[redacted]

OS - [redacted] 1:11:22 PM

0.005 mm Color Steps

Elevation BFS

Anterior Float

0.075
0.060
0.045
0.030
0.015
0.000
-0.015
-0.030
-0.045
-0.060
-0.075

7.83mm/43.1D | 5.97mm/56.5D

[redacted] 1:11:22 PM

Sim K's: Astig:	1.1 D	@ 91 deg
Max:	46.1 D	@ 91 deg
Min:	44.9 D	@ 1 deg
3.0 MM Zone:	Irreg:	± 1.6 D
Mean Pwr	45.3	± 1.1 D
Astig Pwr	0.9	± 1.2 D
Steep Axis	107	± 40 deg
Flat Axis	20	± 40 deg
5.0 MM Zone:	Irreg:	± 3.9 D
Mean Pwr	43.9	± 2.4 D
Astig Pwr	1.9	± 3.0 D
Steep Axis	95	± 42 deg
Flat Axis	8	± 42 deg

White-to-White : 11.5 mm
Pupil Diameter : 3.6 mm
Thinnest : 371 um @ (0.1, -0.2)
ACD (Endo.): 3.43 mm
Kappa : 5.00° @ 321.29°
Kappa Intercept : 0.26, -0.21

Elevation BFS

0.005 mm Color Steps

Posterior Float

0.075
0.060
0.045
0.030
0.015
0.000
-0.015
-0.030
-0.045
-0.060
-0.075

N

T

49.0
47.5
46.0
44.5
43.0
41.5
40.0
38.5
37.0
35.5
34.0

38.5
39.9
41.9
45.8
44.8
46.3
44.8
44.9
45.3
44.3
42.7
45.8
45.8
45.0
42.3
43.3

OS

v3.00E

900
840
780
720
660
600
540
480
420
360
300

506
552
379
535
580

Keratometric

0.5 D Color Steps

Axial Power

Pachymetry - Ac Eq

Thickness

20 mic Color Steps

How I felt when I finally realized keratoconus starts posteriorly

Forme Fruste Keratoconus

- Treatment
- RGP lens in office and trial frame over refraction
  - Eliminated "ghost image"
- Patient currently only in spex
  - Not interested in RGP lens
- RTC 1 year, BVA and topographies

Case 2

Advanced Keratoconus

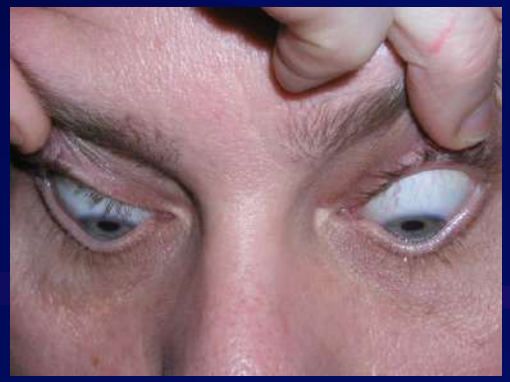

Topography OD

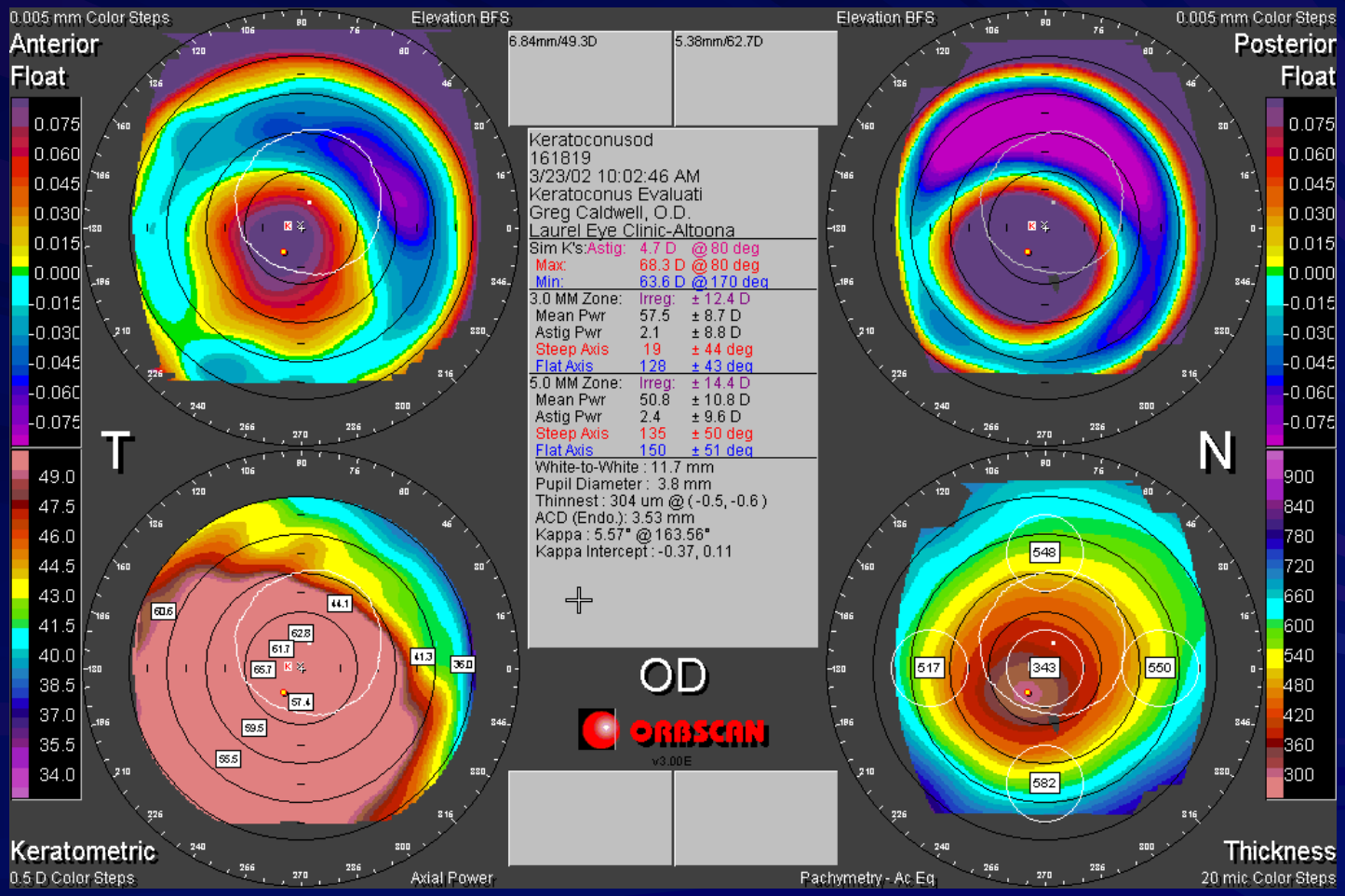

Topography OS

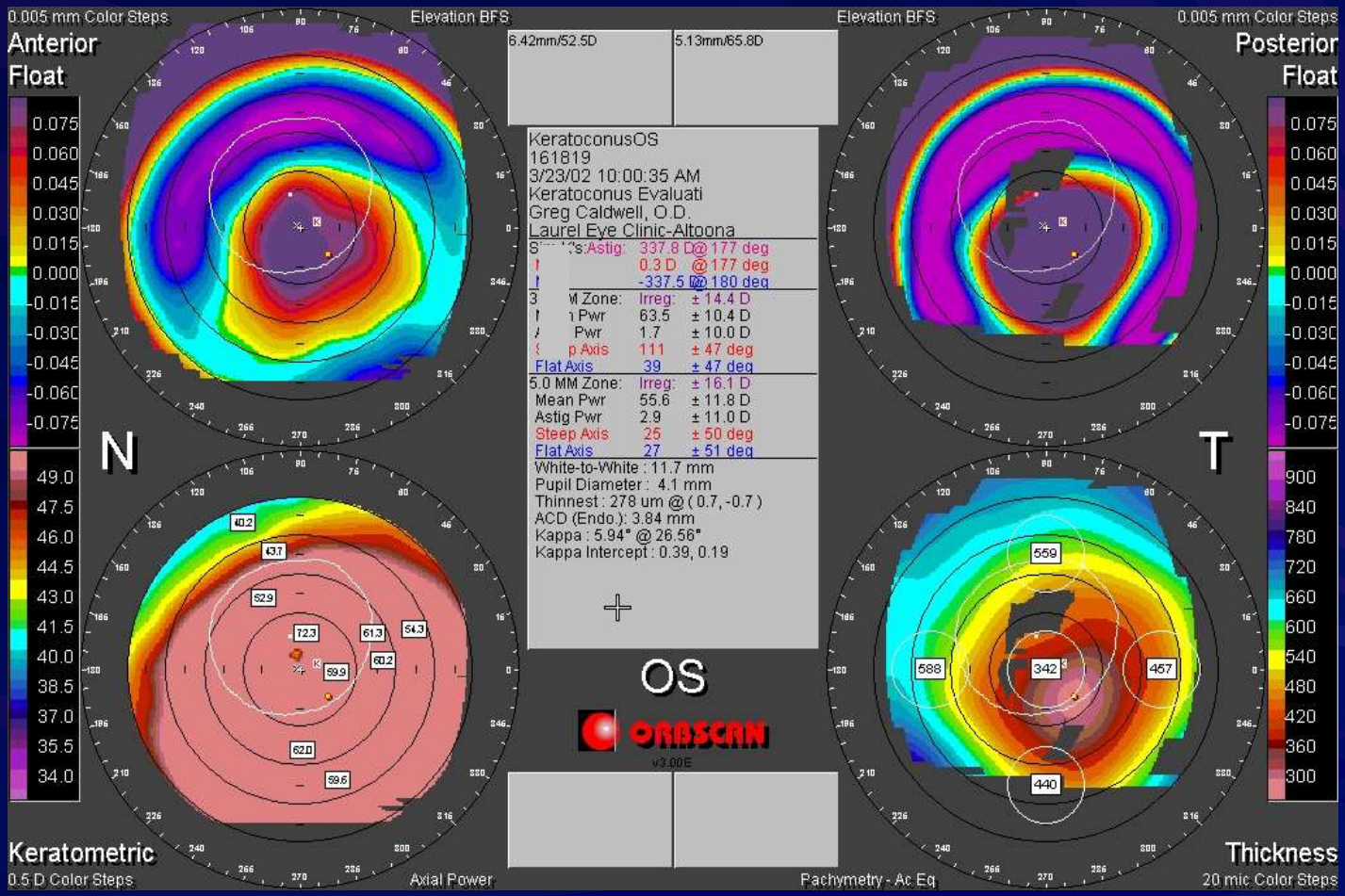

What happens when the posterior cone gets too steep and Descemet's membrane ruptures?

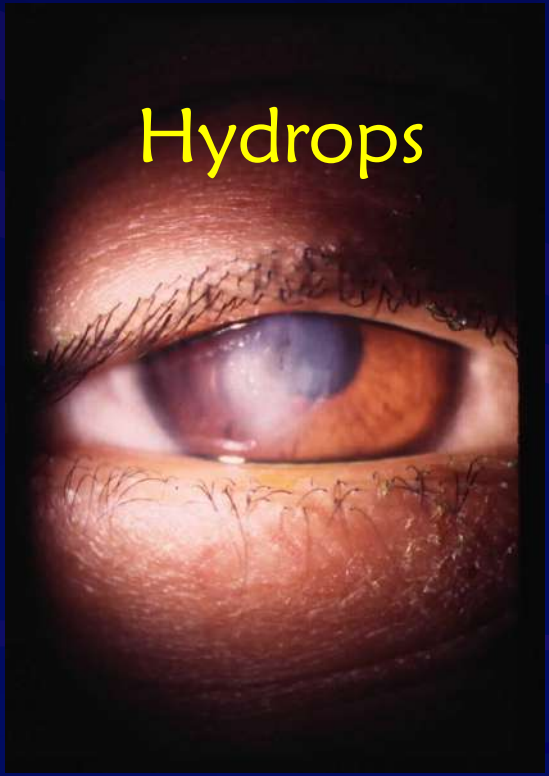

Keratoconus

- **Progressive corneal disease**
  - Focal thinning, steepening, bulging, and irregular shape
  - Loss of biomechanical strength
  - Bilateral, asymmetric, clinically non-inflammatory
- **Caused by a combination of genetic and environmental factors**
  - Allergies and eye rubbing
- **Onset in puberty**
  - Typically progressive to 4th decade of life
  - Previously estimated 1:2000 (1986 US), more recent estimate 1:375 (2017 Netherlands)

Normal

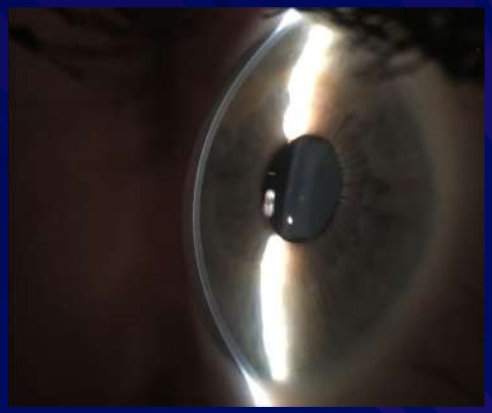

KC



Photos courtesy of Dr. John Gelles, O.D. of CLEI

Conventional Management of Keratoconus

Increasing complexity of interventions and loss of best corrected visual acuity with disease progression

Disease Severity

Corneal Transplant

Intrastromal Ring Segments

Specialty and Scleral Lenses

Rigid Contact Lenses

Eyeglasses

Vision management options do not stop disease progression

Importance of Early Diagnosis in Keratoconus

- As keratoconus progresses, it becomes more challenging to manage
- Progressive keratoconus often results in:
  - Loss of visual acuity
  - Decreased tolerance to contact lens wear, caused by the ongoing changes in the cornea
- The earlier progressive keratoconus is diagnosed, the sooner treatment can be provided that may slow the progression of the disease.[1]
- **Important to diagnose and educate patients before visual function is lost**
- CXL is an early intervention intended to slow or halt the progression of keratoconus

1. Gelles, J. D., OD, FIAO, FCLSA. (2017, April). The Optometrist's Role in Keratoconus Management. Advanced Ocular Care.

LOOK OUT FOR KC!

- **Look out** for warning signs in medical history
  - History of eye rubbing
  - Family & genetic predispositions
- **Look out** for visual complaints
  - Blurred vision
  - Distortion of images
- **Look out** for refractive anomalies
  - Distortion of mires on keratometry
  - Error messages on autorefractors
  - Unsatisfactory attempts at vision correction & progressive loss of UCVA & BCVA
  - Increasing astigmatism

Cross-linking Procedure Summary

1. Remove epithelium

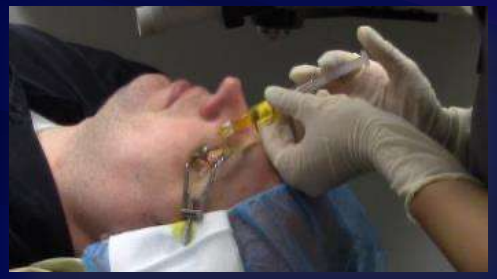

2. Soak cornea Photrexa® Viscous (riboflavin 5'-phosphate in 20% dextran ophthalmic solution) for 30 minutes

3. Check for flare

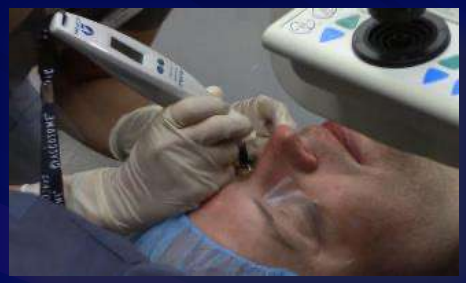

4. Once flare is observed, measure corneal thickness

If corneal thickness is less than 400 um, instill 2 drops of Photrexa *(riboflavin 5'-phosphate in ophthalmic solution)* until the corneal thickness increases to at least 400 μm

5. Irradiate for 30 minutes

Continue applying Photrexa Viscous *(riboflavin 5'-phosphate in 20% dextran ophthalmic solution)* during irradiation.

* Refer to prescribing information for entire FDA-approved procedure

Descemet's Stripping Endothelial Keratoplasty DSEK

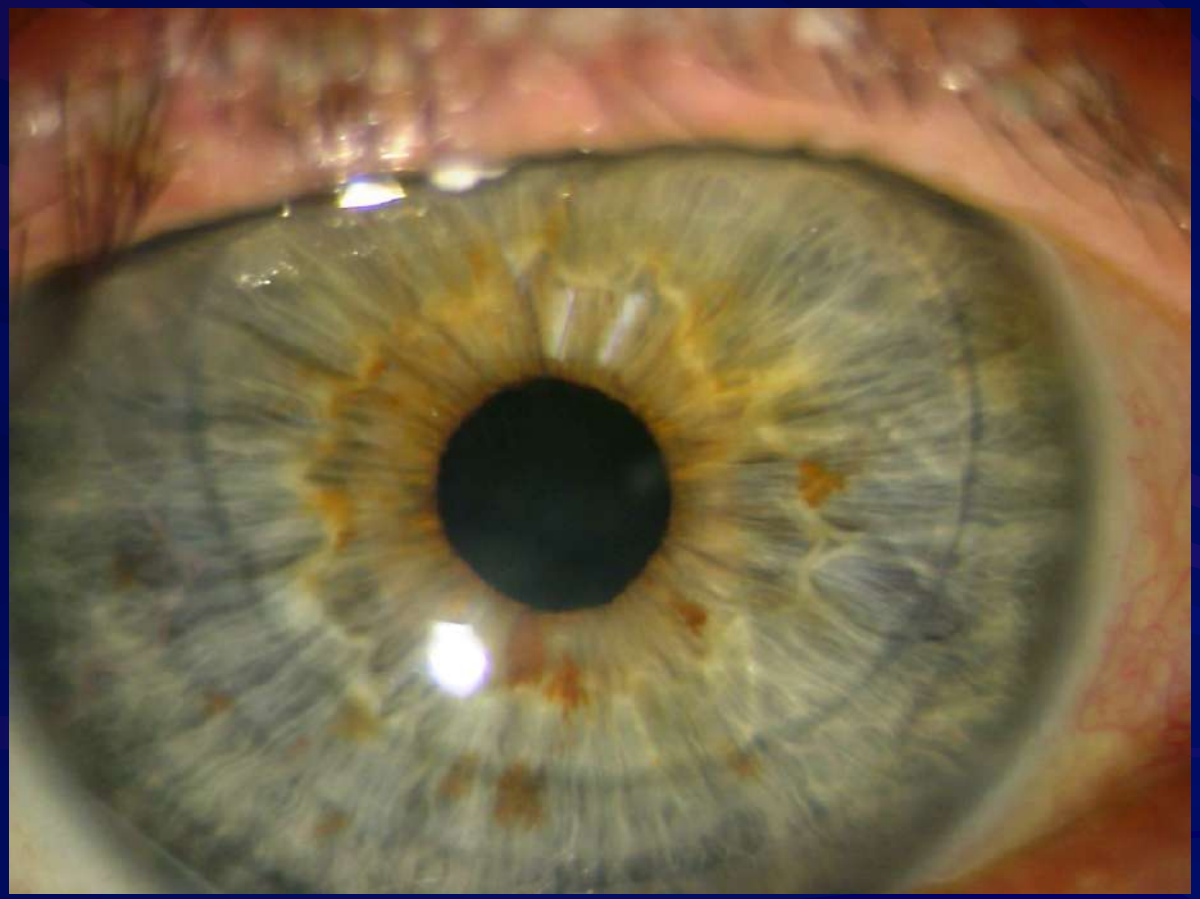

Case 3

28-year-old man

- Had LASIK 14 months ago
- His right eye is now very blurry
- He tried calling for an appointment the center is now closed

Va 20 / 40
cc / 20

Current Correction
R +0.50-7.00 x 040
L -0.25 sphere

EOMS: full, unrestricted
CT: ortho D/N

PERRL (-)APD
CF: full by FC OU

- SLE-trace fibrosis at flap edges, no stain
- SLE-few multi-directional striae OD>OS
- SLE-clean interface OU
- Fundus-unremarkable



graphy
OD

- Diagnosis:
  - Keratectasia 2° LASIK
- RGP OD 20/20-2
  - This lasted for about 3 months
  - Multiple RGPs later due to progression of astigmatism to 8.5 D (BVA 20/50-2)
  - Finally PKP was done Jan 2006

Case 4

43-year-old man

- Called your office today
- Eye pain in the right eye since this morning
- OD 20/80 OS 20/20
- Externals: normal
- Review of Systems: unremarkable

Slit Lamp Evaluation

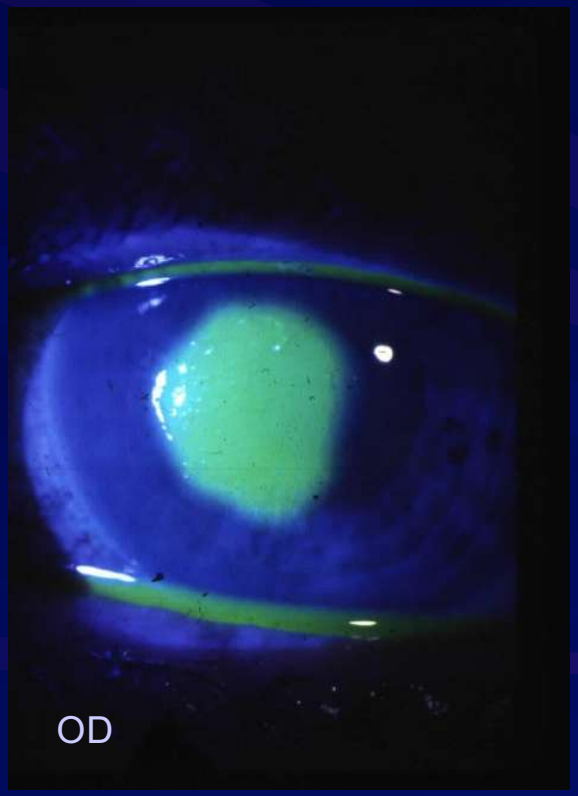

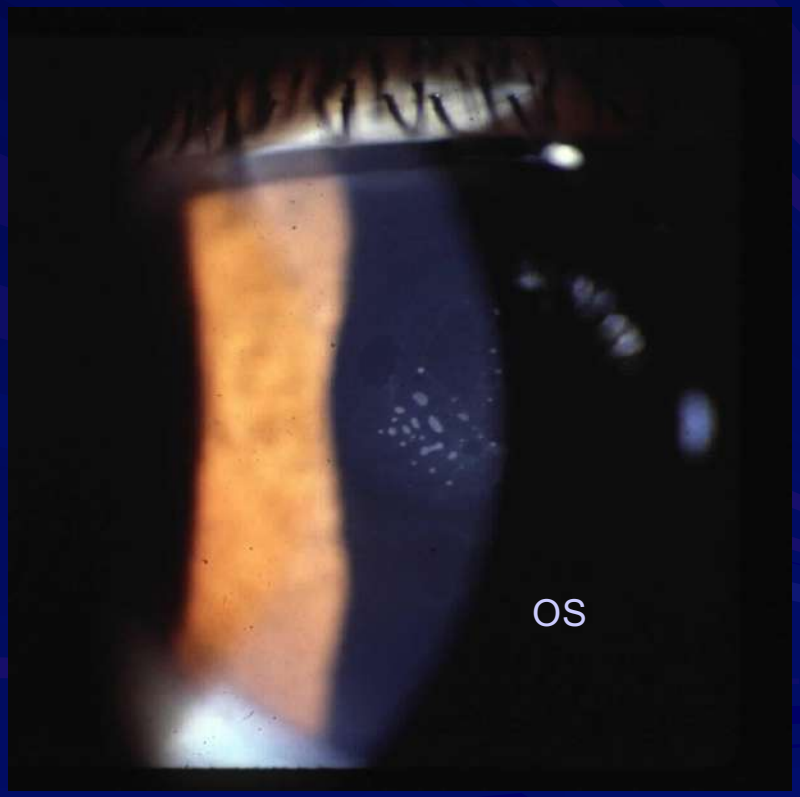

43-year-old male further history reveals

- Fourth time in past 24 months
- Uses Muro 128
  - Gtts qid
  - Ung qHS
- Diagnosis:
  - Recurrent Corneal Erosion secondary to Epithelial Basement Membrane Dystrophy (EBMD)

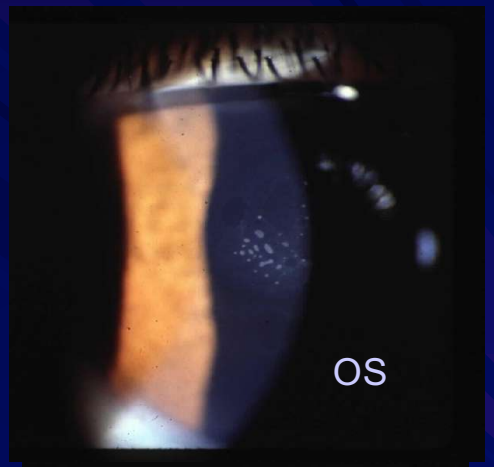

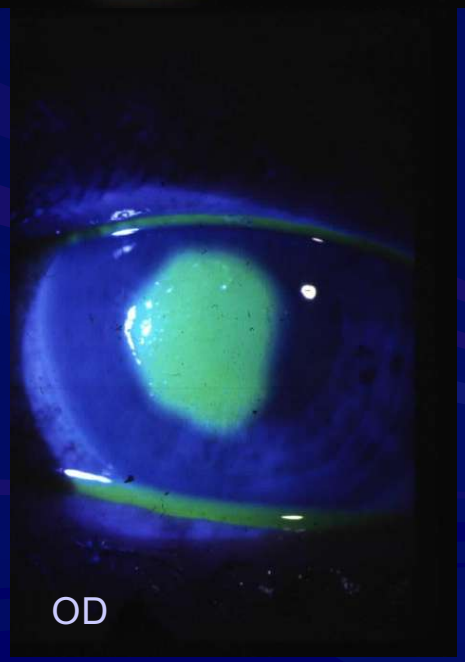

Treatment

- Antibiotic, topical
- Pain management
  - Depending on severity
    - Bandage contact lens
    - Oral ibuprofen (200 mg) (16)
      - Maximum 3200 mg daily
    - Oral acetaminophen (500 mg) (6)
      - Maximum 3000* mg daily
    - Oral narcotic (need DEA number)
      - Lortab (500/5)
      - They provide good pain relief
      - A degree of sedation
      - Tend to minimally impact the digestive system and kidneys
      - It's not that they're dramatically more potent than OTC analgesics like aspirin, acetaminophen, ibuprofen or naproxen
    - Topical NSAID

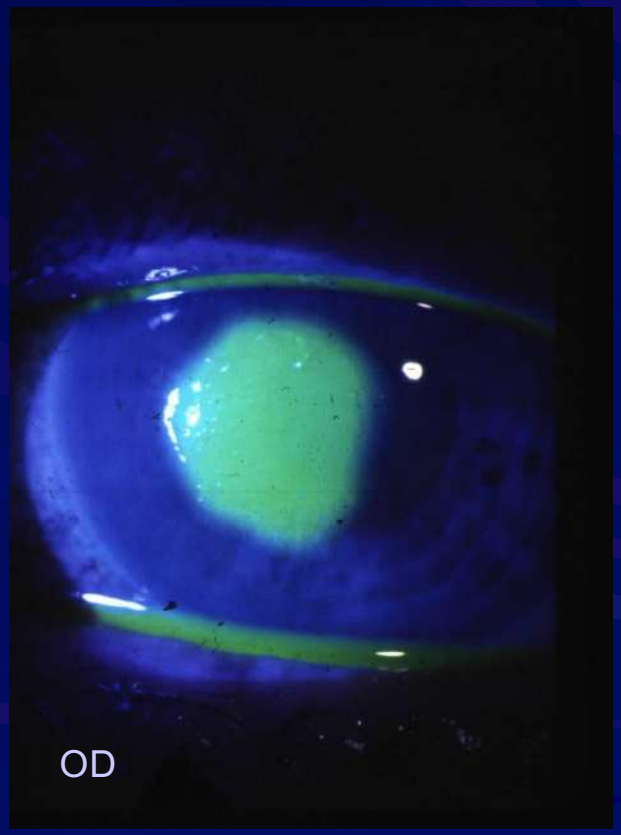

Review of Map-Dot-Fingerprint

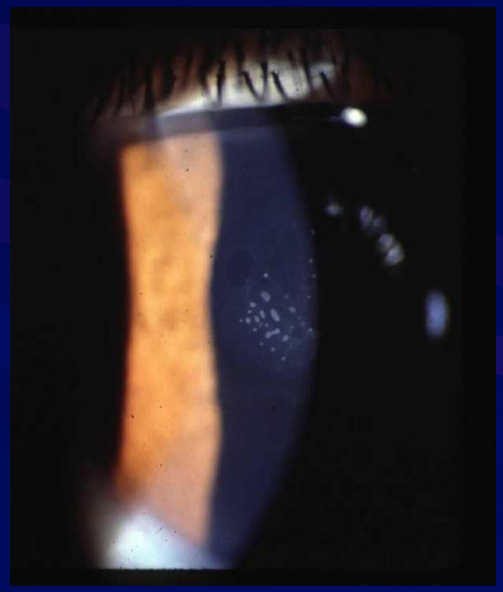

Treatment Options

(Once Abrasion Resolved, to Help Prevent Recurrence)

- Medically
  - Hypertonics
    - Gtts
    - Ung
  - Bandage contact lens
    - Nocturnal
  - Doxycycline/Minocycline
  - Amniotic membrane (PROKERA™)
- Surgical/Procedures
  - Anterior stromal micropuncture
  - Debridement
    - Chemically
    - Mechanically
      - Beaver blade/diamond burr
  - Excimer phototherapeutic keratectomy (PTK)

When is it time for surgical procedure?

Answer: medical treatment failure

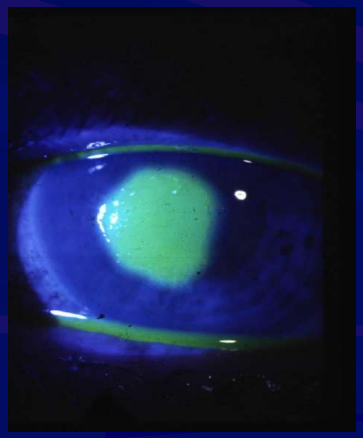

The Basics of Amniotic Membrane

The Amniotic Membrane

- The amniotic membrane is the innermost lining of the placenta (amnion)
- Amniotic membrane shares the same cell origin as the fetus
  - Stem cell behavior
- Structural similarity to all human tissue

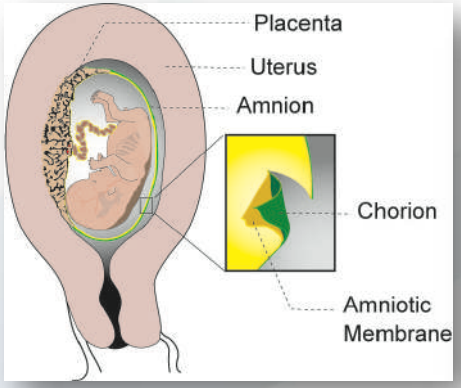



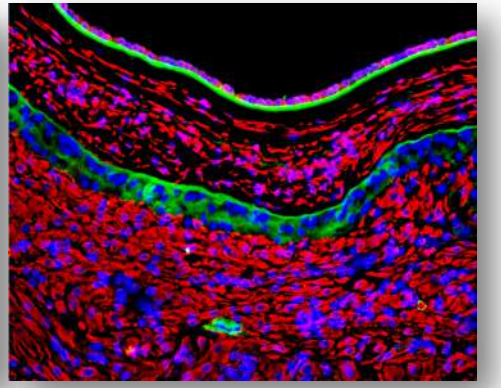

The CRYOTEK™ Method

- Patented and proprietary cryopreservation
- Ensures key active components of the Extracellular Matrix (ECM) are retained
- The **only** method that retains both:
  - The integrity of the tissue structure
  - The key active (ECM) components
- Safe and effective
  - Supported by over **300** peer-reviewed articles
  - Over **100,000** implanted
- Bio-Tissue Cryopreserved Amniotic Membrane is the **ONLY** AM granted wound healing indication by the FDA.

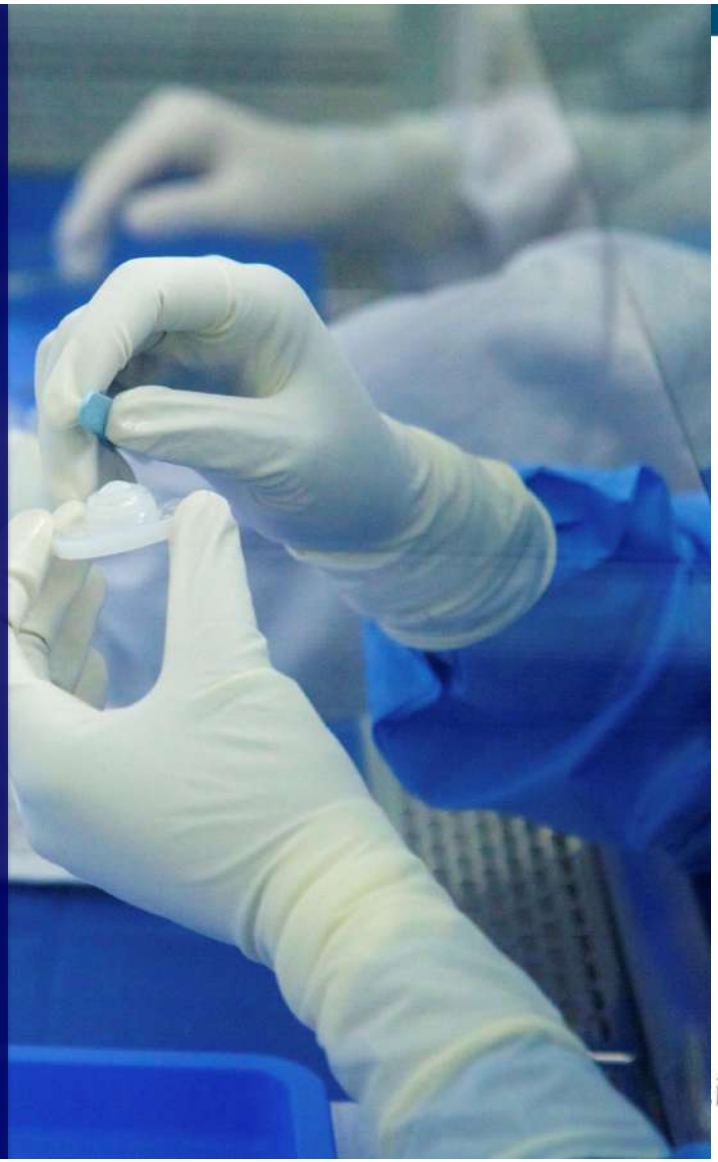

issue

Technology Highlights

Impressive regenerative **platform** that possesses natural growth factors and optimal scaffolding properties within a complex extracellular matrix that are:

- Anti-inflammatory
- Anti-scarring
- Anti-angiogenic

Therapeutic actions:

- Promotes Stem Cell Expansion
- Suppresses pain
- Promotes cellular migration
- Expedites recovery

issue

PROKERA®: BIOLOGIC CORNEAL BANDAGE

- PROKERA® utilizes the proprietary CryoTek™ cryopreservation process that maintains the active extracellular matrix of the amniotic membrane which uniquely allows for regenerative healing.
- PROKERA® is the only FDA-cleared therapeutic device that both reduces inflammation and promotes scar less healing
- PROKERA® can be used for a wide number of ocular surface diseases with severity ranging from mild, moderate, to severe

PROKERA®: Biologic Corneal Bandage
An Active Amniotic Membrane

PROKERA® | Slim

Mild to Moderate

- (Microbial, HSV)
- Recurrent Corneal Erosions
- Corneal Abrasions / Wounds

PROKERA®

Moderate to Severe

- Neurotrophic PED
- Severe Infectious Keratitis
- Post DSEK for Bullous Keratopathy
- Corneal Wounds

PROKERA® | PLUS

Severe

- Chemical Burns
- Stevens Johnson Syndrome
- Severe Corneal Ulcers
- Corneal Wounds

Excimer Phototherapeutic Keratectomy (PTK)

- Corneal Opacities
  - Scarring
  - Granular dystrophy
- Surface Irregularity
  - Saltzman nodules
- Surface Breakdown
  - Epithelial basement membrane dystrophy



PTK Procedure

- Removal of epithelium
- Manual debridement
- Polish with excimer

PRK

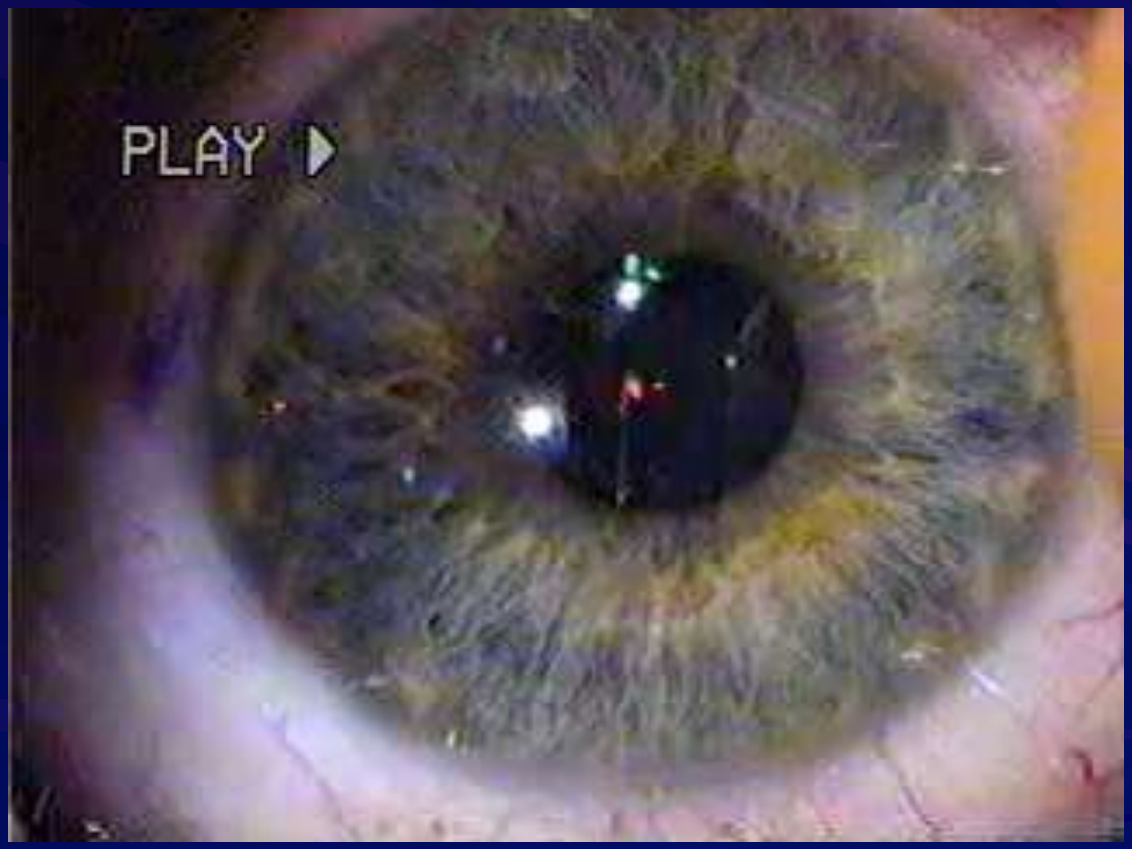

PTK

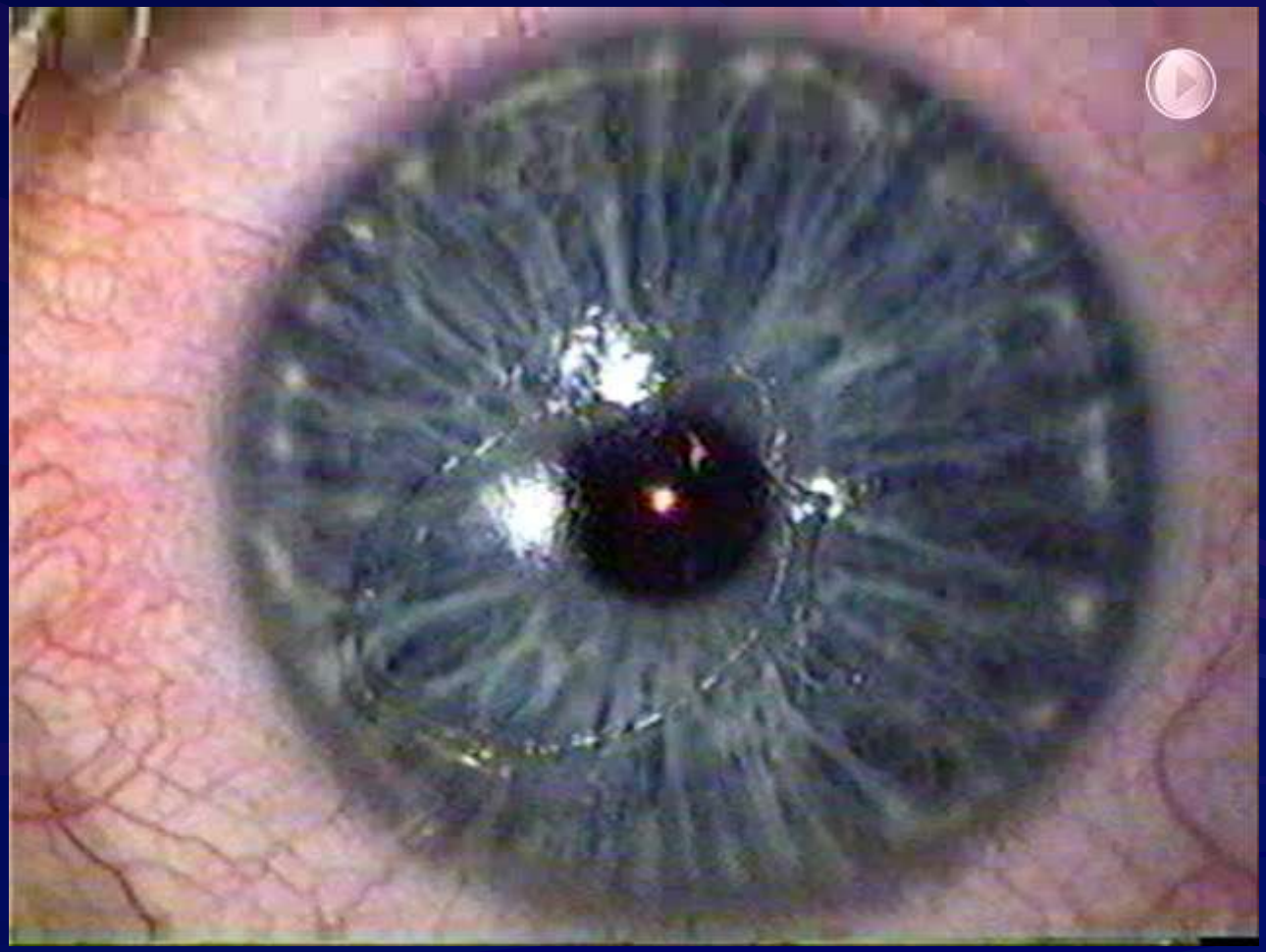

Post op Regimen

- Vigamox and Pred-Forte q2°
  - Until wound is closed
- Bandage contact lens (BCL)
- Vitamin C, 1000 mg/day x 1 month
- NP-artificial tears
- Sunglasses in any UV

Before & After

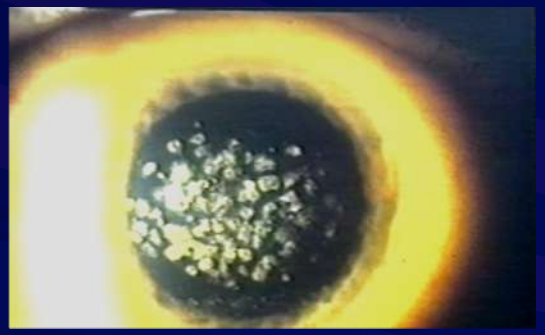

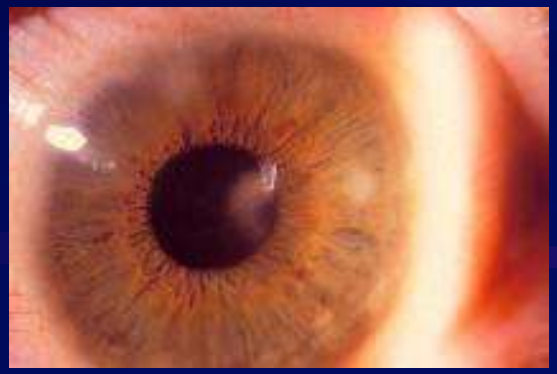

Case 5

84 year old woman

- Right eye red and painful
- Started about 10 days ago
- See photos for discussion

Diagnosis?
Treatment?

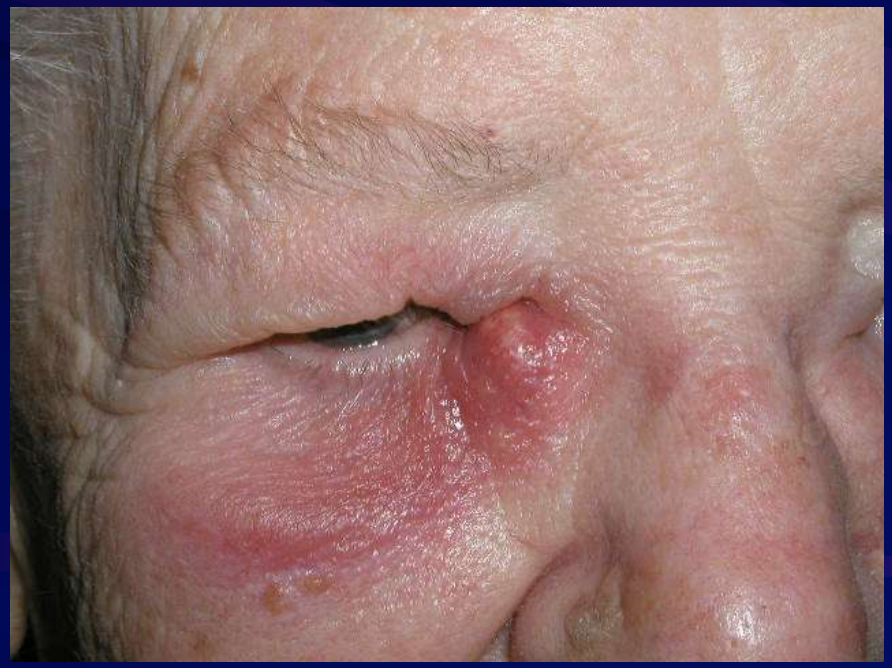

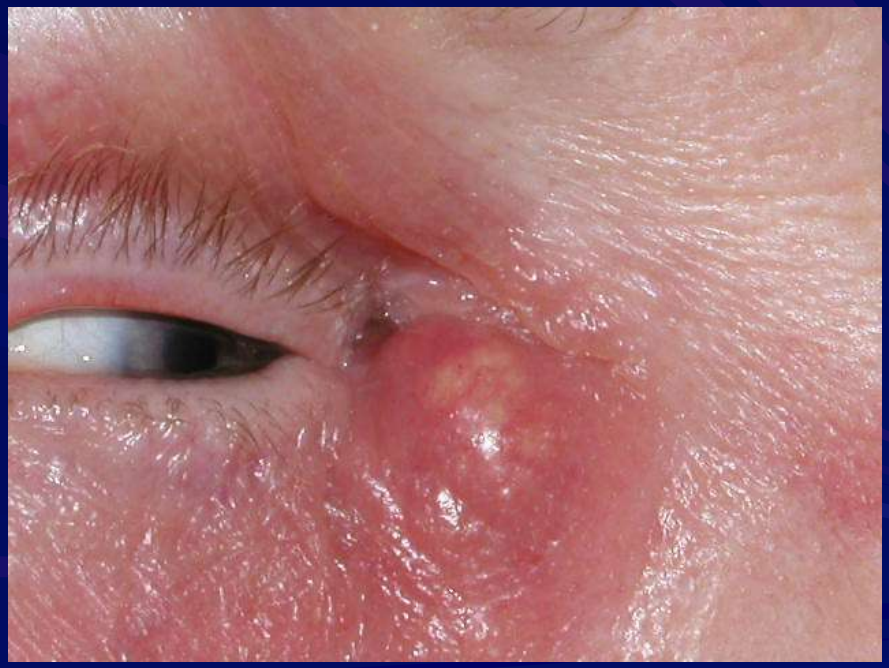

1 Week Later

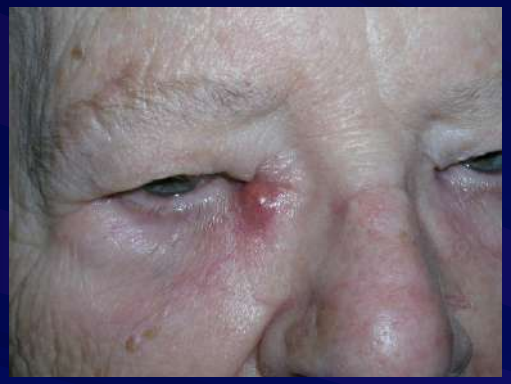

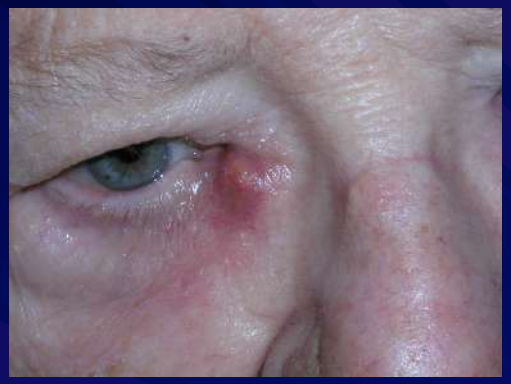

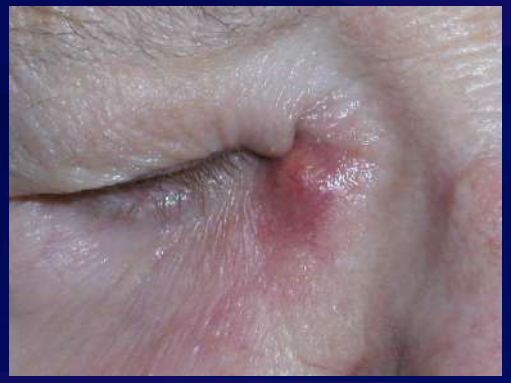

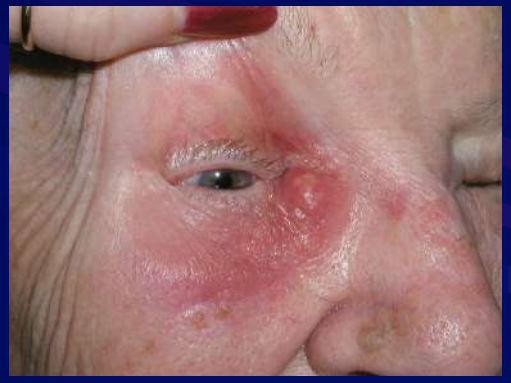

Treatment Plan?

Reminder 1 week ago

- Continue with topical and oral antibiotics
- Surgical consult for dacryocystorhinostomy (DCR)

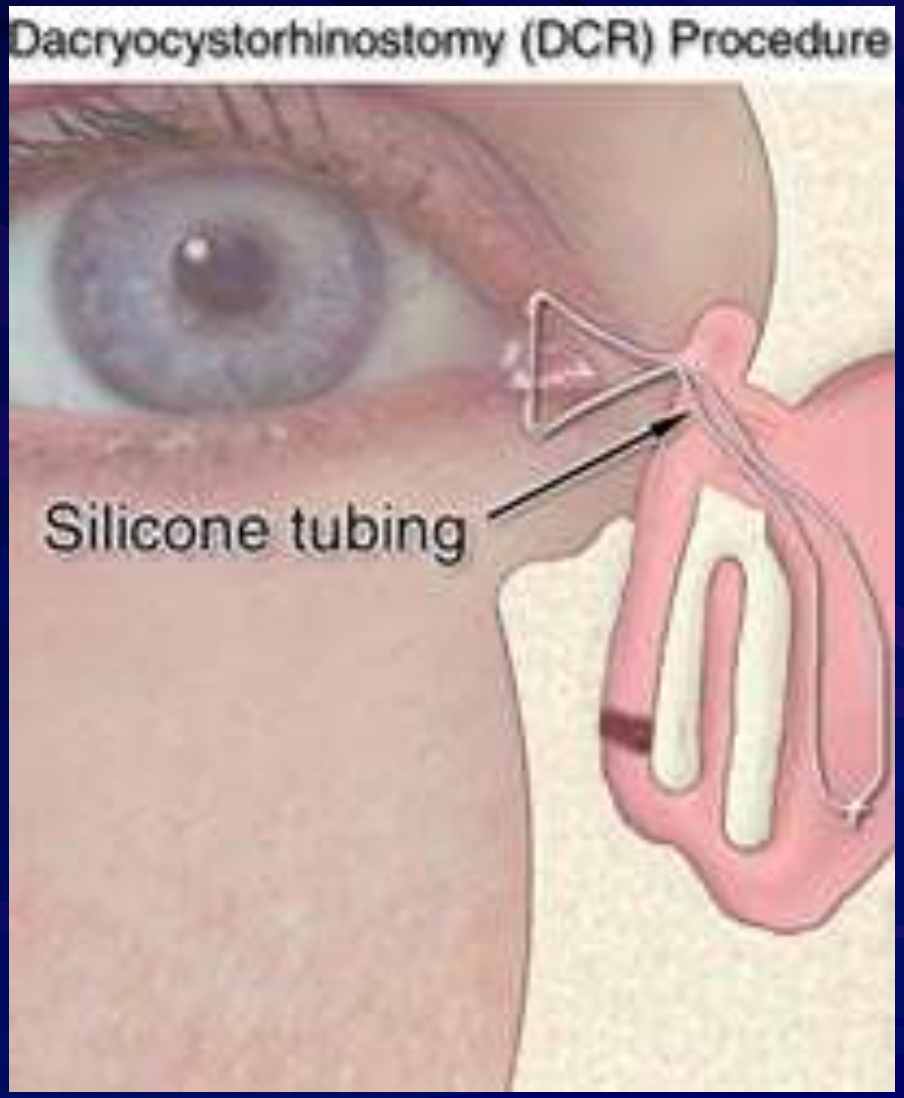
Dacryocystorhinostomy (DCR) Procedure
Silicone tubing

After Dacryocystorhinostomy (DCR)

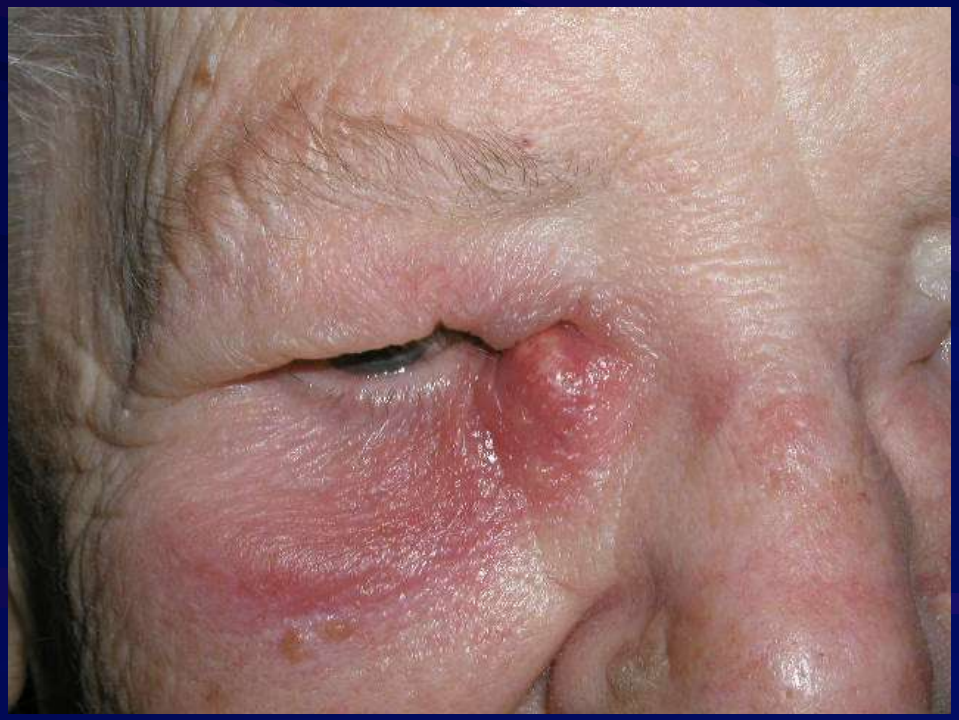

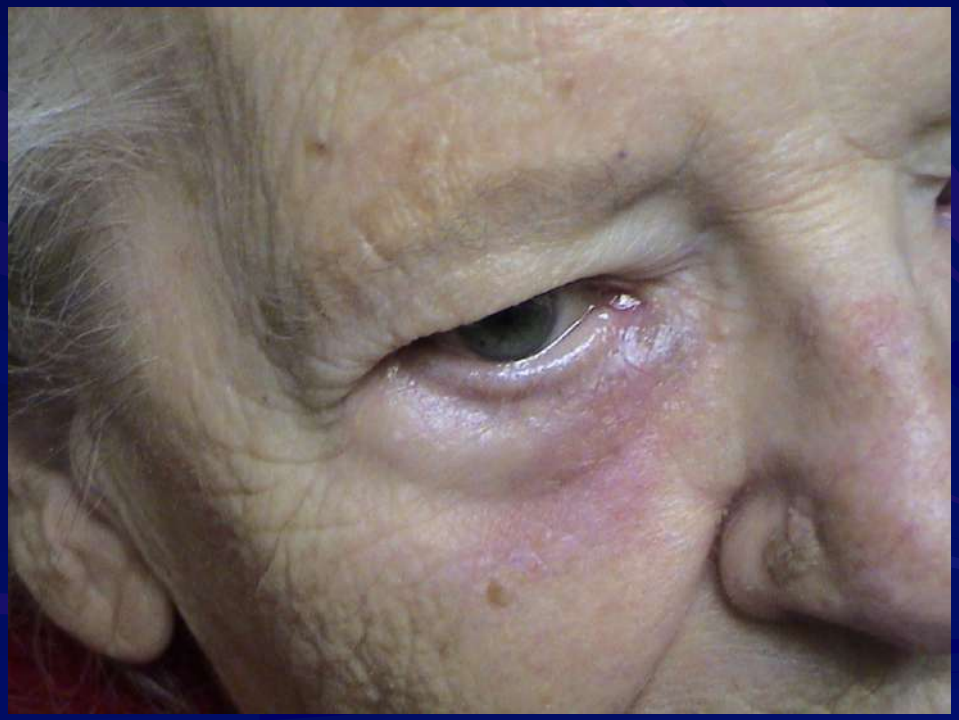

Tube Removal

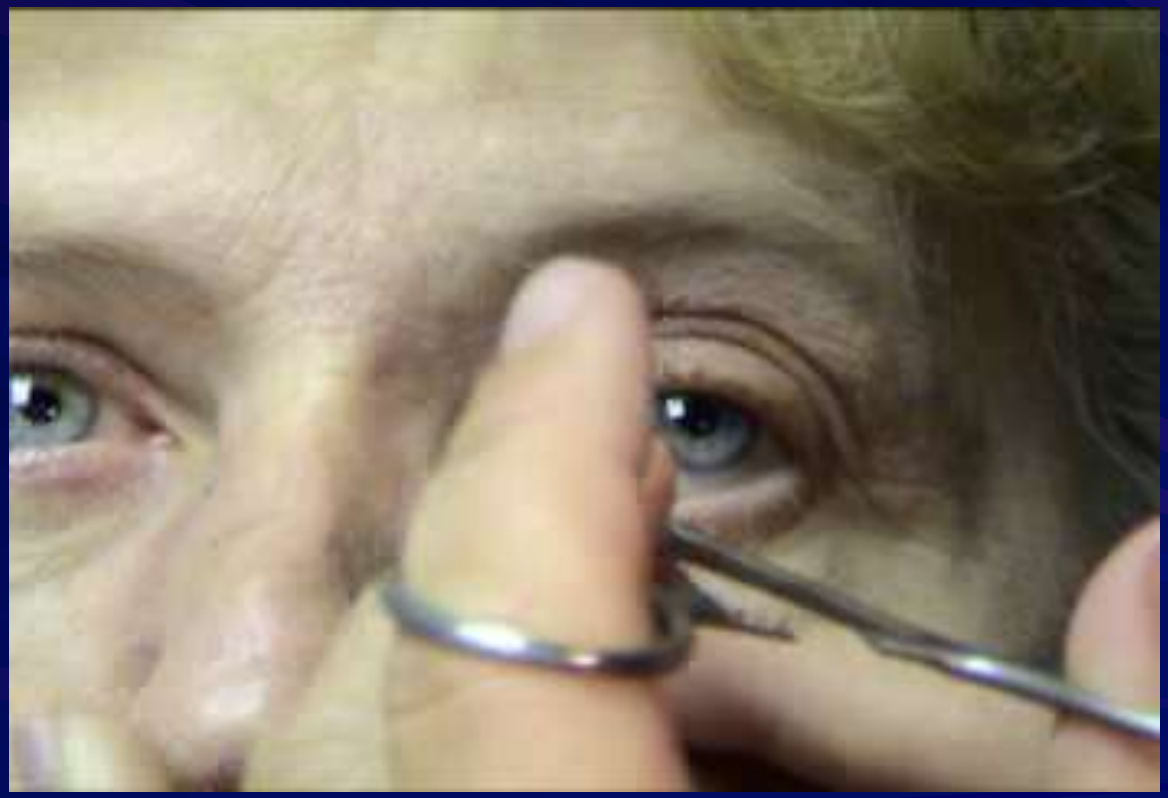

Case 6

35-year-old man

- Wants another opinion due to "hemorrhage on my right eye"
- Happened 3 days ago after vomiting
  - Claims food poisoning from chicken Caesar salad
  - Still feels a little nauseated
- Saw ophthalmologist 3 days ago, told he had a bruise on his eye and it should go away in 1-2 weeks

35-year-old man

- BVA 20/100 OD, 20/70 OS
  - Hx of amblyopia OD
  - Current Rx OD +5.50 OS +4.50
- Any concerns?
- Patient noticed blurry vision OS
  - Started 2 weeks ago
  - Did not mention because he is more concerned about the blood on his right eye
- Headaches for 2 weeks, decrease if patient stands up
- ROS: unremarkable
- Decide to dilate OU

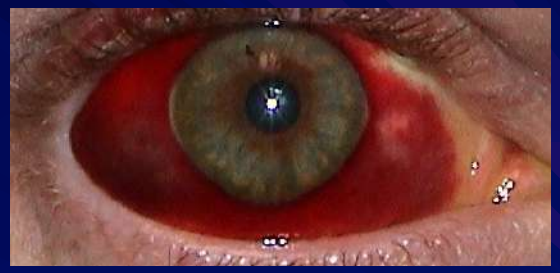

Retinal Findings

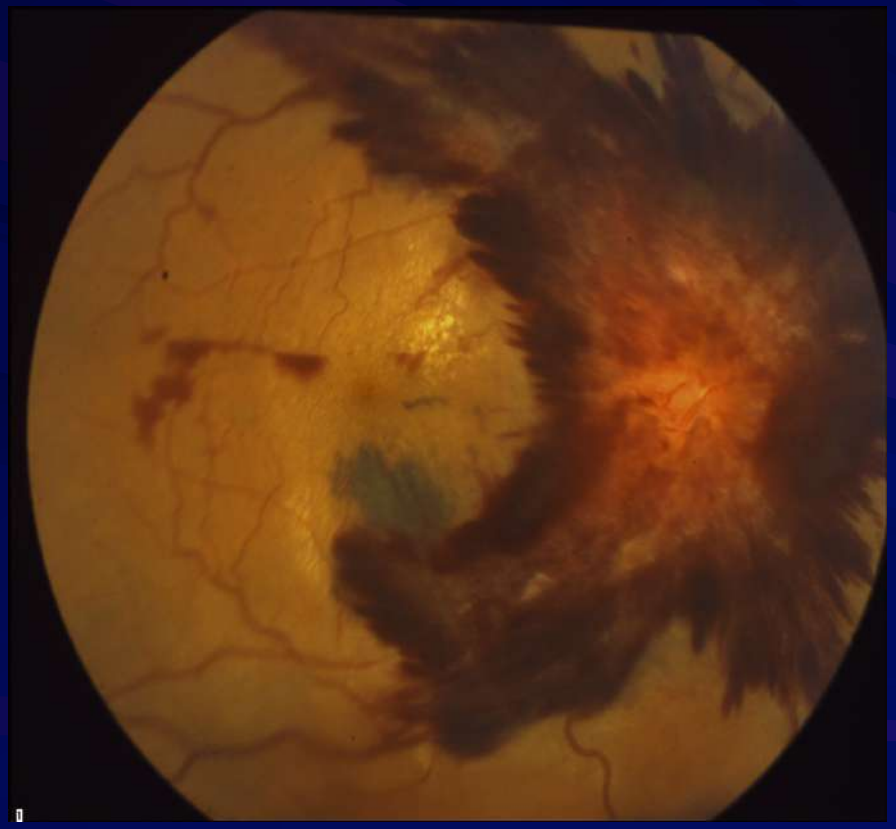

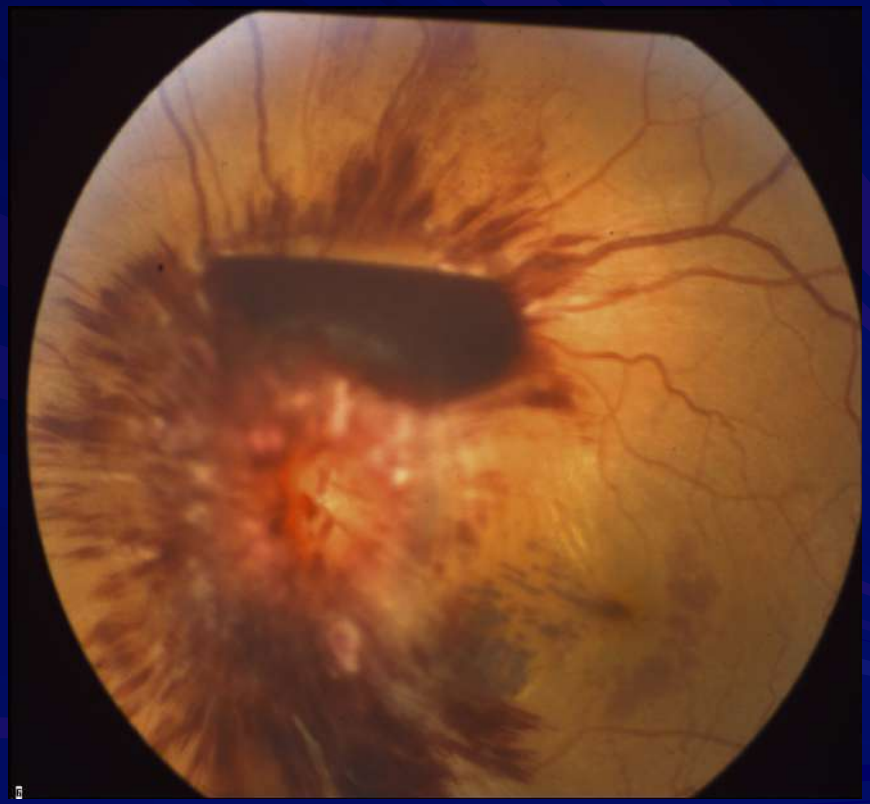

Differential Diagnosis

- Hypertensive retinopathy
- Blood dyscrasia
- Terson's syndrome
- Valsalva retinopathy
- Purtscher's retinopathy
- Shaken baby syndrome

Terson's Syndrome

- Terson's syndrome originally was defined by the occurrence of vitreous hemorrhage in association with subarachnoid hemorrhage
- Terson's syndrome now encompasses any intraocular hemorrhage associated with intracranial hemorrhage and elevated intracranial pressures
- Intraocular hemorrhage includes the development of subretinal, retinal, sub-hyaloidal, or vitreal blood
- The classic presentation is in the sub-hyaloidal space

Treatment

- Emergency referral to neurologist due to high suspicion of intracranial hemorrhage and elevated intracranial pressure
- Intracranial hemorrhage confirmed with MRI
- Patient later diagnosed with Hairy Cell Leukemia and cryptococcal meningitis

Case 7

8-year-old girl

- Mom noticed the left eyelid has become red and has pimples
- Started two days ago
- Slowly getting more pimples on the eyelid
- Globe not affected

Slit Lamp Evaluation

- Diagnosis
  - Herpes simplex blepharitis
- Treatment
  - 400 mg Acyclovir 5x/day
  - Call to pediatrician

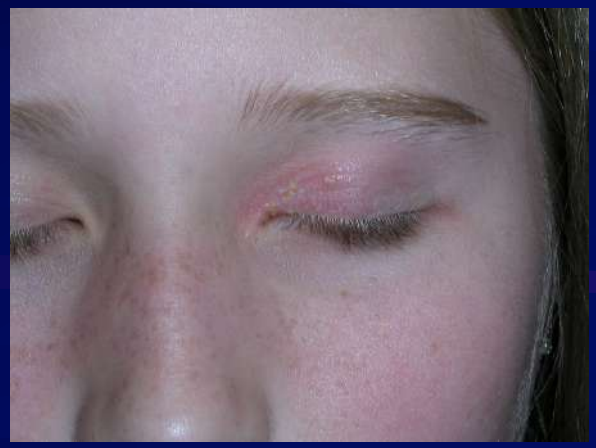

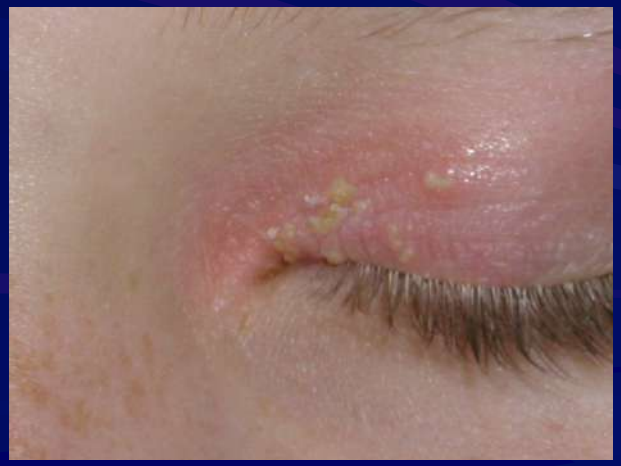

Case 8

58-year-old woman

- VA OD 20/200 OS 20/400
- Longstanding history of macular degeneration
- Anything suspicious here?
  - ?? Longstanding AMD in 58-year-old??
- History of cataract surgery OU
- Glasses Rx OD -1.00 OS -1.00

Axial length 29.85 mm

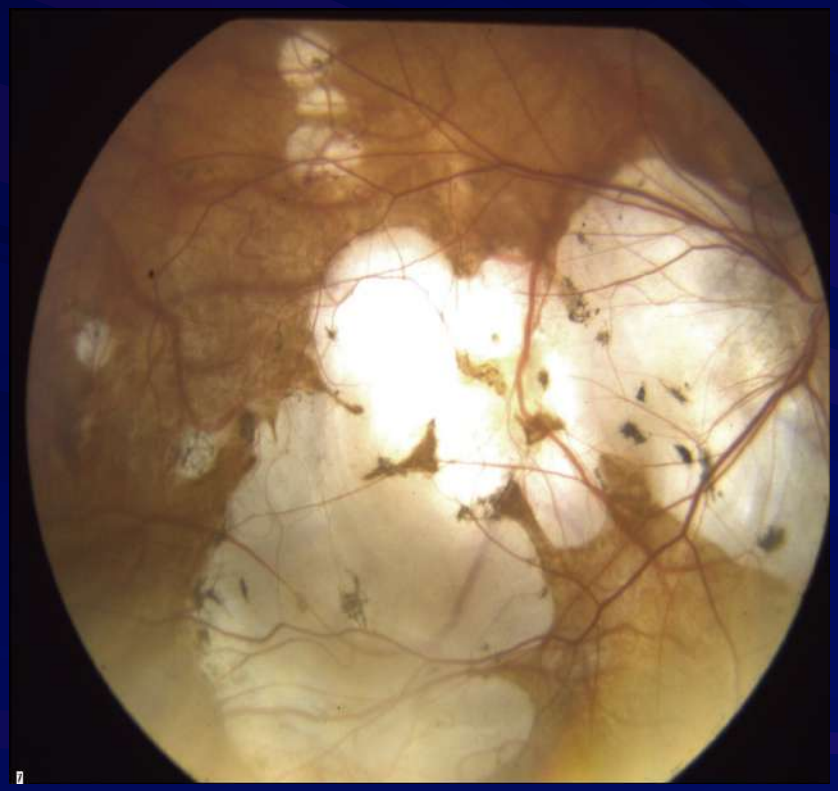

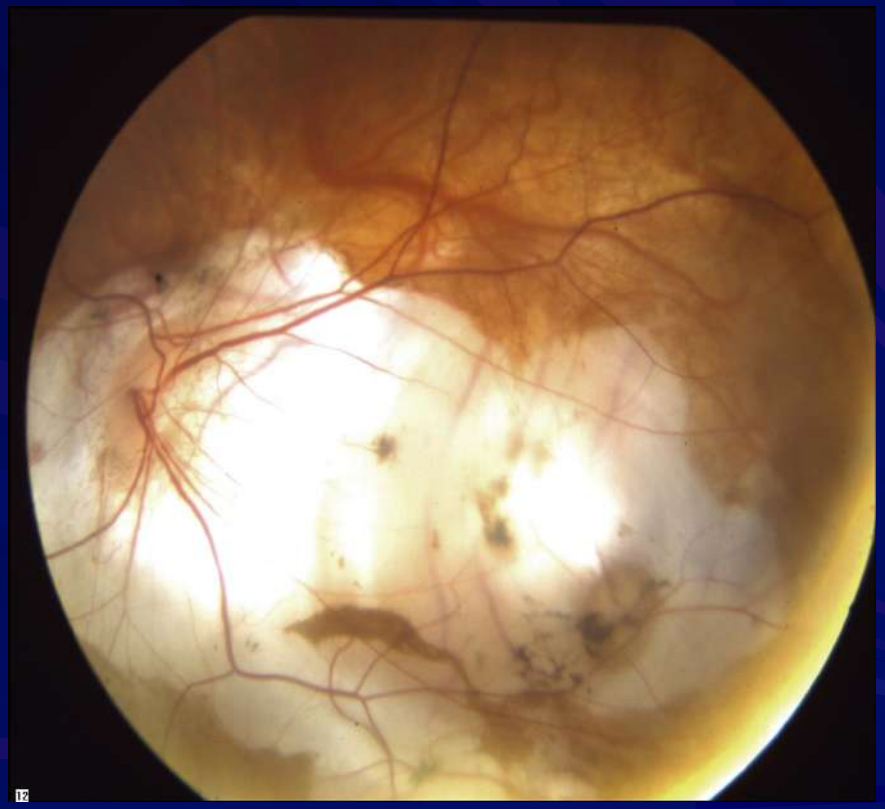

OD -18.00 OS -18.50 prior to cataract surgery

At what diopter value is a patient considered a degenerative or pathological myope?

Degenerative Myopia

- Differs from refractive myopia
  - There is an alteration of globe structure that is progressive
  - Primary alteration is a posterior elongation of eyeball as a result of progressive thinning of sclera
    - Posterior staphyloma

Degenerative Myopia

- Findings
  - Lacquer cracks
  - Posterior staphyloma
  - Fuch's spot
  - RPE and choroidal atrophy
  - Scleral crescents
  - Vessel straightening
  - Disc tilting
  - Peripheral retinal changes

Can be found in refractive and degenerative myopes

Conditions Associated With Degenerative Myopia

- Fetal Alcohol Syndrome
- Ocular albinism
- Down's Syndrome
- Low birth weight
- Infantile glaucoma
- Retinopathy of Prematurity
- Marfan's Syndrome

Treatment

- BVA with glasses/contact lenses
- Education regarding trauma and possible eye hazards
- Monitor for neovascularization and peripheral retinal changes
- Follow-up at least yearly

Which patient is at higher risk of retinal detachment?

Two patients are in your office
-8.00 D refractive myope
-14.00 D degenerative myope

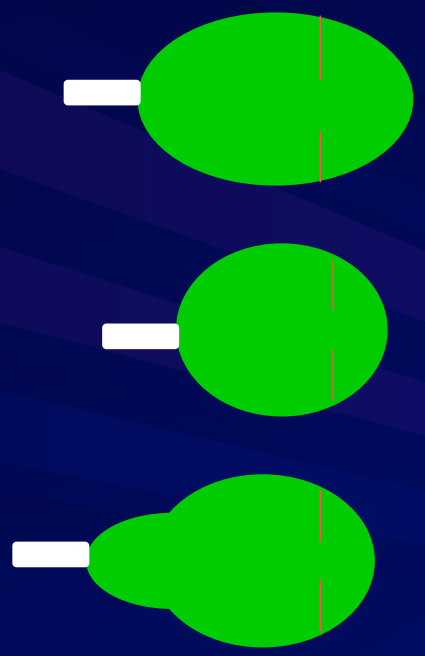

- Refractive myopia
  - Peripheral retina concerns
- Degenerative myopia
  - Posterior pole concerns

Clinical Pearl

- Refractive myopia
  - Peripheral retina is general concern
- Degenerative/Pathological myopia
  - Posterior pole is general concern
    - Posterior staphyloma

Peripheral Fundus Findings

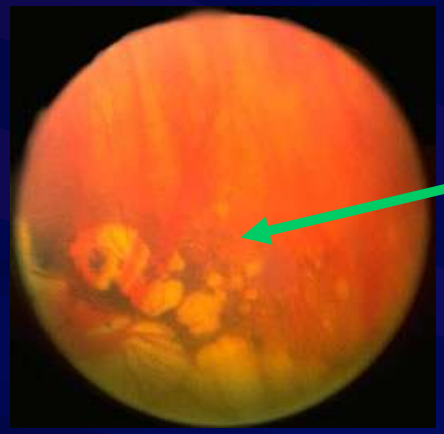

Pavingstone Degeneration

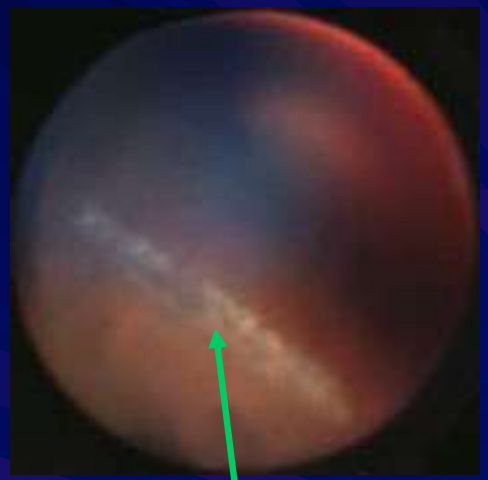

Lattice Degeneration

Pigmented Holes

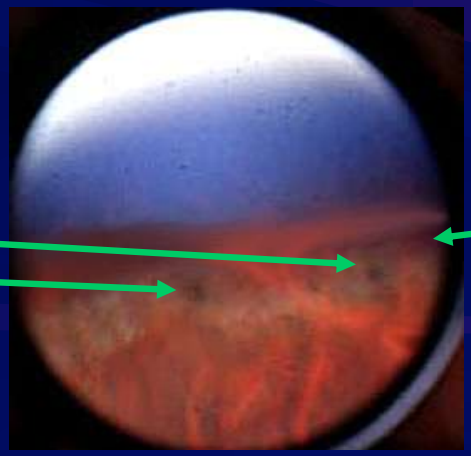

Case 9

88-year-old man
I see faces of friends that I have not seen for years, wheels of cars and at times pine trees

BVA
Count fingers at 2 feet OU

Current Correction
R plano
L -1.00 sphere

EOMS: full, unrestricted
CT: ortho D/N by Hirschberg

PERRL (-)APD
CF: central defect OU

Recommend psyche consult?

- Alert and Oriented x 3
  - Person
    - Knows who he is, who is with him
  - Place
    - Knows where he is, knows where he lives
  - Time
    - Knows what month, day, date and year

Diagnosis and Treatment?

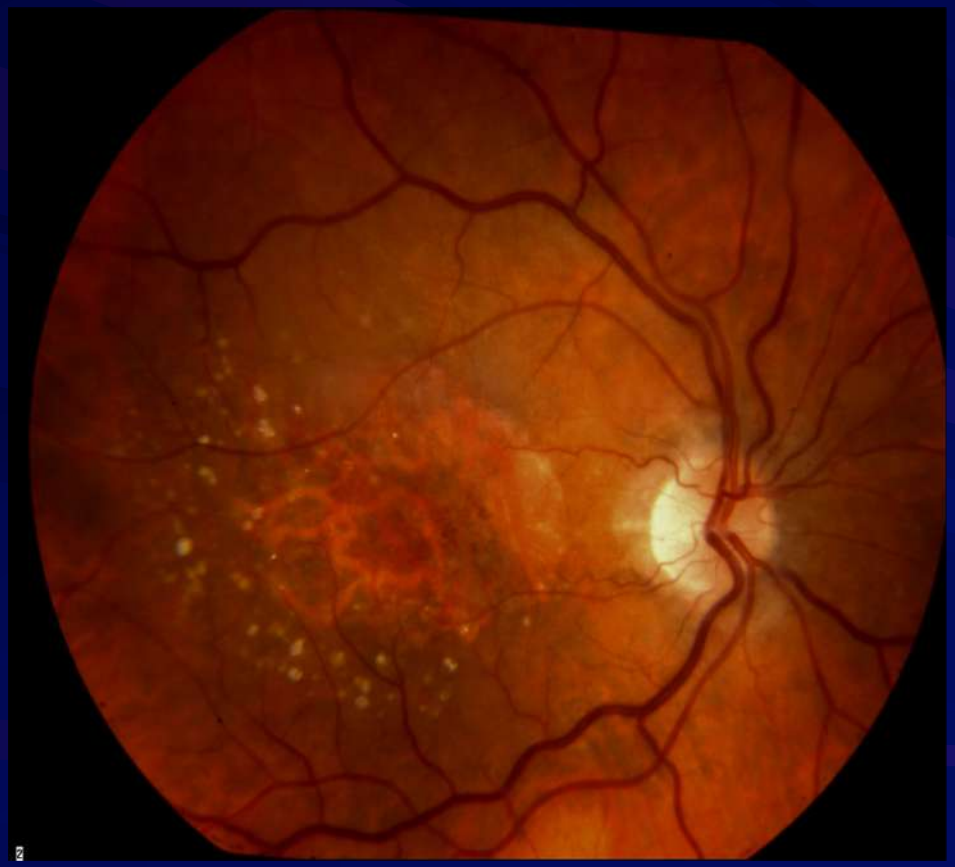

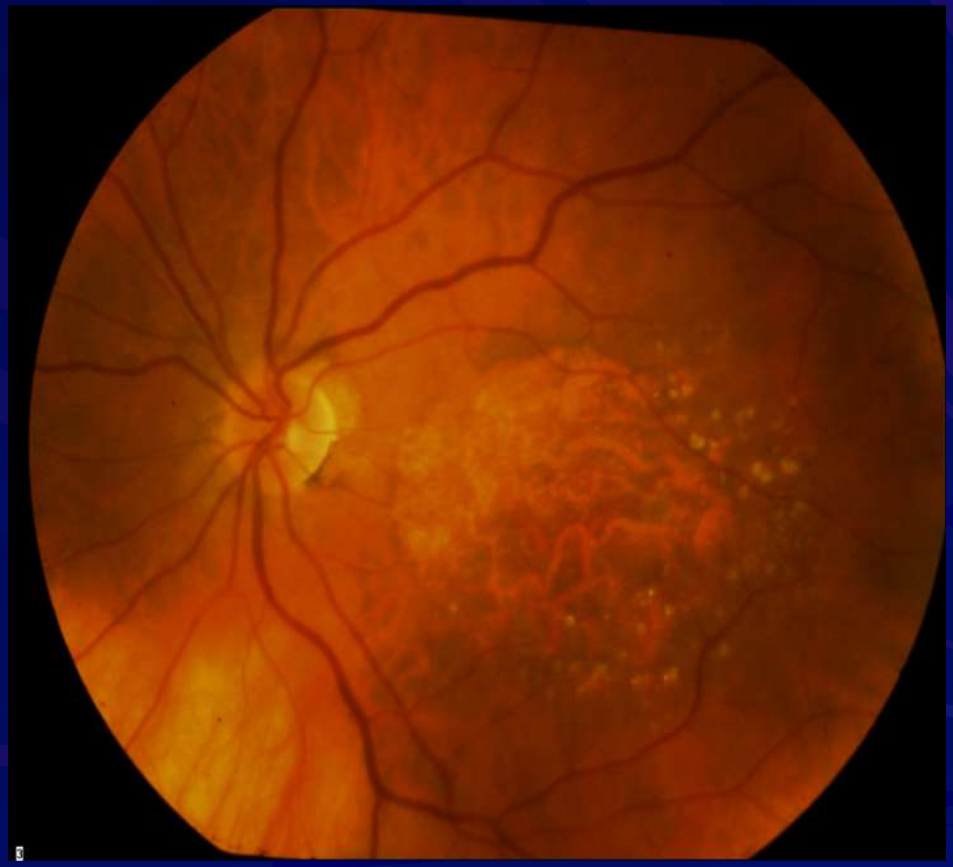

Charles Bonnet Syndrome

"Release Hallucination"

- Visual hallucinations
  - Irritative (brief)
    - Epilepsy
    - Migraine
  - Release (continuous)
    - Stroke
    - Sensory deprivation

Treatment

- Reassurance
  - That this is normal for patient with severe vision loss to experience hallucinations
- Clinical Pearl
  - Any patient 20/100 or worse in better eye
    - Ask the patient

Clinical Pearl
Is there a difference between
Geographic Atrophy and Disciform Scar

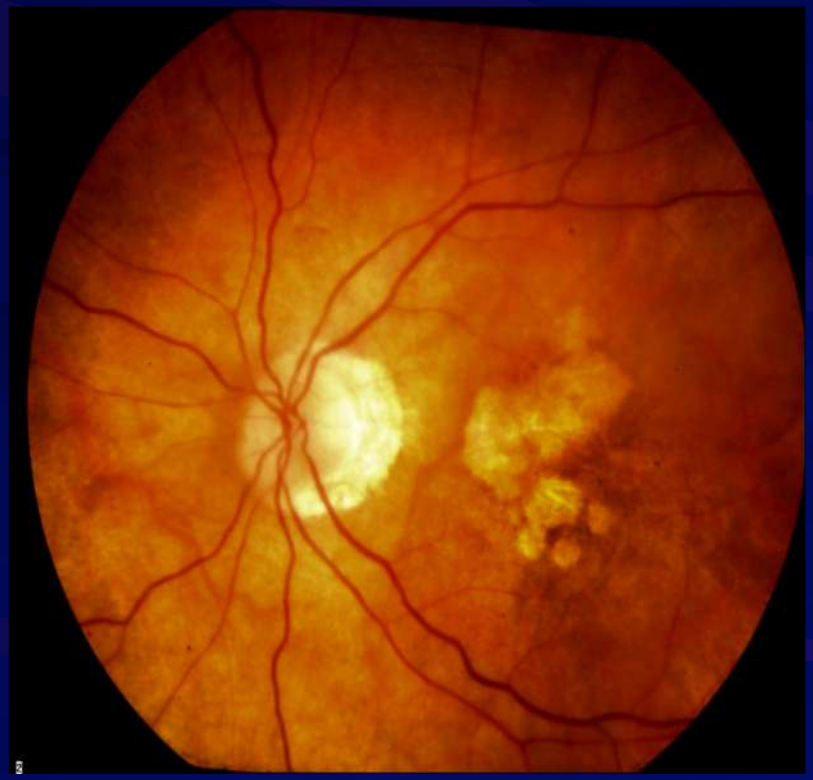

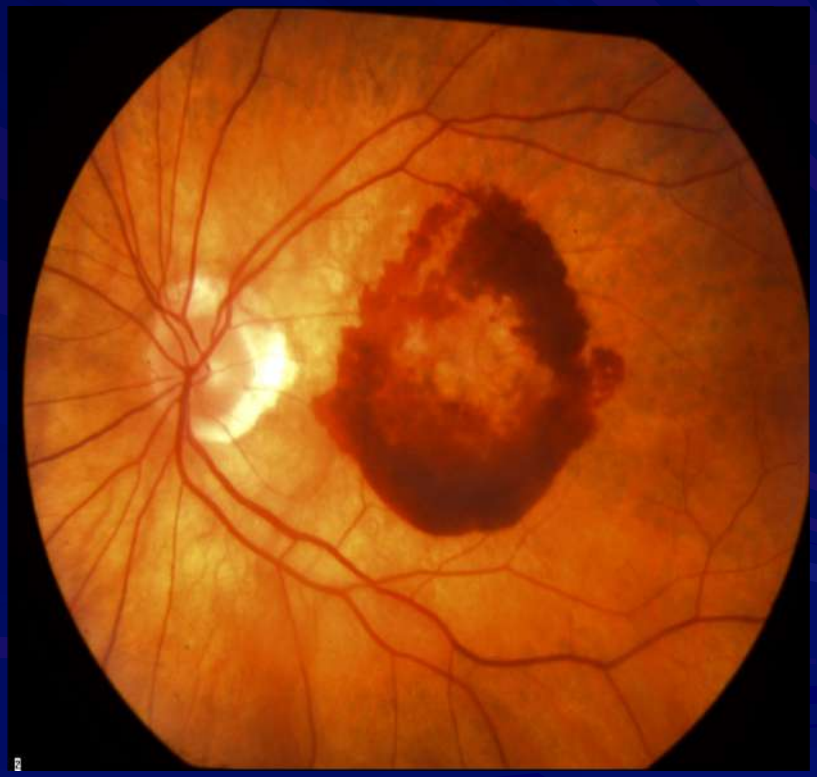

Thank You!
Questions!

Grand Rounds
Improving Eye Care and Outcomes for Patients

Greg A. Caldwell, OD, FAAO
Optometric Education Consultants
Sunday, March 5, 2023