Optometric Education Consultants

Anterior Segment Grand Rounds: Corneas, Cases, and Complexities

Joseph Sowka, OD, FAAO, Diplomate

DISCLOSURE:

- *Joseph Sowka, OD, in the past 24-months,* has been a Consultant/ Speaker Bureau/ Advisory Board member for B&L. Dr. Sowka has no direct financial interest in any of the diseases, products or instrumentation mentioned in this presentation. All relevant relationships have been mitigated. He is a co-owner of Optometric Education Consultants.

Optometric Education Consultants

The ideas, concepts, conclusions and perspectives presented herein reflect the opinions of the speaker; he has not been paid, coerced, extorted or otherwise influenced by any third party individual or entity to present information that conflicts with his professional viewpoints.

Case

- 21 YOWM plumber
- Calls in after hitting himself with "Blunt end of screwdriver"
  - "Fluid running down cheek"
  - Tylenol for pain
- Loose flap of skin
- Tried to manually remove

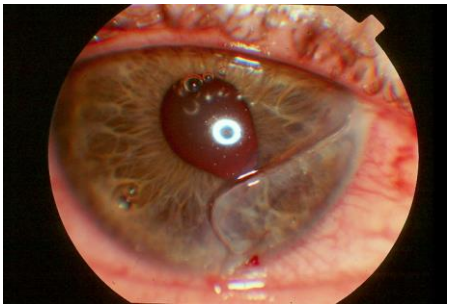

Optometric Education Consultants

What do you think?

CORNEAL LACERATION

- Excessive PAIN, decreased vision
- Deeper than abrasion; may be smaller, linear
- + Seidel's sign; additionally, may see hyphema, A/C rxn, flattened A/C (relative), air bubbles in A/C
- Iris prolapse possible
- IOP is low -- ***DO NOT perform tonometry***

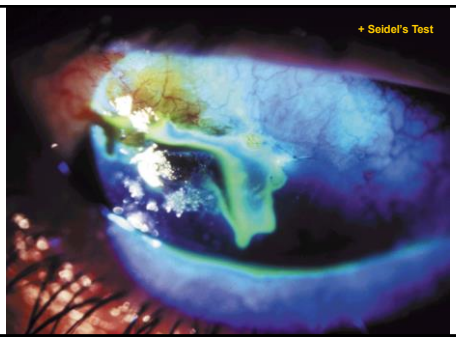

Sometimes it is Black and White… or Worse

- 55 YOBM with 'weed whacker abrasion'
  - 2 ODs
  - Shallow chamber; IOP < 5 mm; hypopyon
  - End Result?

Corneal Injury Pearls

- Perforations can self-seal
- High speed injury is a perforation until proven otherwise
  - DFE; B scan
  - Progressive vision loss
  - Inappropriate inflammation
    - You don't get hypopyon from a corneal abrasion
  - Shallow chamber
  - Hypotony
  - Instilling NaFL is *not* a Seidel's test

CORNEAL LACERATION:
Management

- Photodocument (if possible for clinicolegal purposes)
- MINIMAL manipulation of the globe
- Avoid topical medications
- Shield the eye but DO NOT PATCH
- N.P.O.
- Refer IMMEDIATELY for surgical repair

A sharp stick to the eye

- A 71-year-old man presented urgently
- He had been injured that morning.
- He had been pruning an areca palm tree when he bent down and caught the sharp end of a new shoot on his left eye.
- What next?

CASE: 20 Year Old White Female

- CC: Intermittent itching and irritation OU x 2 months
  - Worse after showers
  - Eyelids red and swollen all the time
  - Lid scrubs not helpful
- Medical Hx: non-contributory
- BVA 20/20 OD, OS

20 Year Old White Female

Continued…

- Significant erythema OU
- Thick crusting about lashes
- IOP normal OU
- Fundus unremarkable

20 Year Old White Female

- Can I get some more detail?

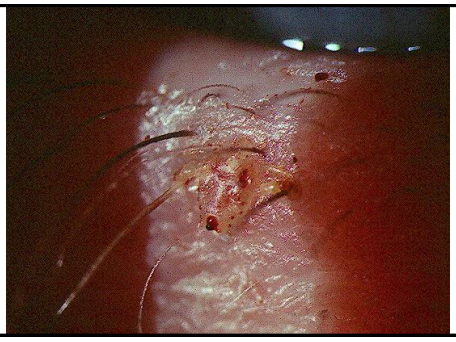

Crab Louse Infection

- **Pediculosis** refers to infestation by *Pediculus humanus corporis* (body) or *capitus* (head).
- **Phthiriasis** refers to eyelid infestation by *Phthirus pubis* (pubic louse).
  - Eyelid infestation is almost always Phthirus pubis.
- Phthirus organisms are 2 mm long with a broad-shaped, crab-like body
- Thick, clawed legs make it less Pediculus species

Crab Louse Infection

- Infest areas where the adjacent hairs are within its grasp (eyelashes, beard, chest, axillary region, pubic region).
  - Rarely do they infest the scalp.
- Ocular signs and symptoms:
  - visible organisms
  - reddish brown deposits (louse feces)
  - 2º blepharitis with preauricular adenopathy
  - follicular conjunctivitis
  - bilateral ocular itching and irritation

Crab Louse Infection: Treatment

- Pediculus organisms possess good mobility and can be passed from person to person by either close contact with an infested individual or by contact with contaminated bedding.
- Phthiriasis are slow moving organisms that cannot typically be passed unless cilia is brought into close proximity with infested cilia.

Crab Louse Infection: Treatment

- Forceps removal of all visible organisms and nits
  - Removed debris should be placed into an alcohol wipe and discarded
- Pediculocidal medicated shampoo
  - Lidane 1% (gamma benzene hexachloride)
  - Kwell®, Nix® or Rid®, which is a safe, effective, nonprescription pediculocide
    - **NOT** for ocular use

Crab Louse Infection: Treatment

- Topical therapy may include:
  - smothering lice & nits with petroleum jelly (or other bland ointment) X tid
  - 1% yellow mercuric oxide or 3% ammoniated mercuric oxide X bid
  - cholinesterase inhibitors (e.g. physostigmine)
- Typically, nits survive a single application of these agents.

Crab Louse Infection: Treatment

- Daily follow for 7 - 10 days
  - nits hatch q7-10 days
- Thoroughly wash all clothing and linens that may have been exposed.
- Patients should refrain from "interpersonal contact" until the disease is 100% resolved.
- Educate exposed partners to report for examination and evaluation.

"I'm Not Going Back in There!"

- OD-4 Student examines older male patient
- "I'm not going back in there. There are worms!"
- "I think that I am going to pass out"
- Nothing really to set up
- Social History: Recently returned from trip to Las Vegas

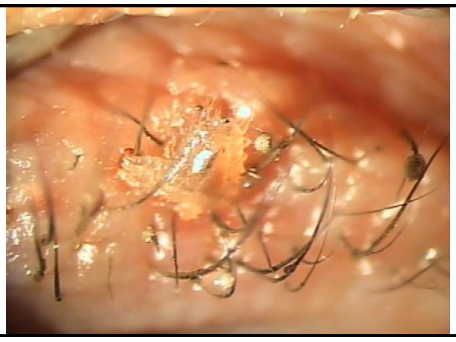

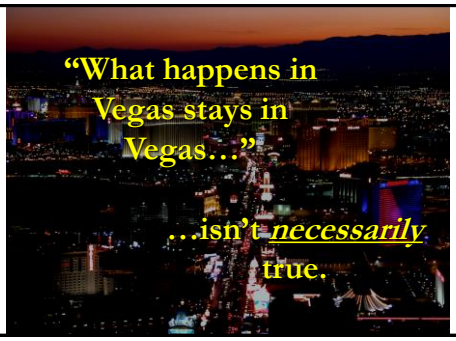

Ocular Demidicosis

- Anterior blepharitis caused by *Demodex* mites
- The typical patient is over 50 years of age
  - Increasing prevalence in the elderly population.
- Clinical symptoms of blepharitis—itching, burning, sandy or gritty feeling, heaviness of the lids or complaints of chronic redness are often present
  - Nearly half of those individuals who harbor Demodex remain asymptomatic.
- Classic sign associated with ocular demodicosis is collarettes
  - Scales that form clear casts around the lash root
  - Cylindrical dandruff

COLLARETTES ARE A PATHOGNOMONIC SIGN OF *DEMODEX* BLEPHARITIS

Collarettes, or cylindrical dandruff, are composed of mite waste products and eggs[1]

- Collarettes are translucent, solidified exudative excretions that form a cylindrical collar that cuffs around the base of the eyelash follicle[1-3]
- Collarettes are displaced along the shaft of the lash as it grows, and they are also displaced due to bacterial overgrowth[4]
- Collarettes are composed of regurgitated undigested mite waste combined with epithelial cells, keratin, mite eggs, and secreted proteases and lipases that cause irritation[3]
- **100%** of patients with collarettes have *Demodex* blepharitis[2,5]

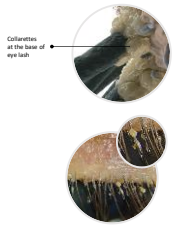

Image courtesy of Inder Paul Singh, MD, used with permission.[5]

1. Zhang AC et al. Ophthalmic Physiol Opt. 2020;40(4):489-510. 2. Gao YY et al. Invest Ophthalmol Vis Sci. 2009;50(9):3939-3946. 3. Fromstein SR et al. Clin Optom (Auckl). 2018;10:57-63.
4. Nichols K et al. Clinical and Experimental Optometry. 2021;104(3):289-294. 5. Karthikeyan R et al. Int J Ophthalmol. 2017;10(1):121-127. 6. Data on file image courtesy of Inder Paul Singh, MD. 2022.

Ocular Demidicosis

- Additional, nonspecific signs include red and swollen lid margins, trichiasis, eyelash disorganization, madarosis, meibomian gland dysfunction, blepharoconjunctivitis and blepharokeratitis.
  - Potential association between *Demodex* and pterygia and chalazia
- Commensal saprophyte, inhabiting the skin of the host and feeding on accumulated oil secretions and dead epithelial cells or parasitic, thriving in or on the host organism, offering no benefit and potentially causing harm?
  - Currently thought to be parasitic

Ocular Demidicosis

D. folliculorum

0.3-0.4 mm length
Colonizes the base of the lash follicle[1]

D. brevis

0.1 mm length
Colonizes the meibomian gland[1]

- *D. folliculorum* tends to cluster superficially around the lash root, while *D. brevis* burrows into the deeper pilosebaceous glands and meibomian glands.
- Cylindrical dandruff appears to result from epithelial hyperplasia and reactive hyperkeratinization around the base of the lashes, possibly due to microabrasions from the mite's (*D. folliculorum)* sharp claws and cutting mouth-parts
- D. brevis impacts the meibomian glands either by mechanical blockage of the duct, a granulomatous reaction to the mites as a foreign body or as a vector for other microbes that incite the host's innate immune response.
  - The end result is MGD with associated lipid tear deficiency.

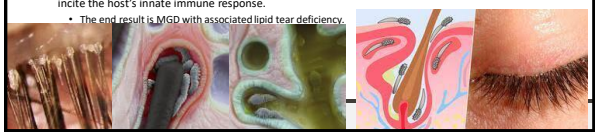

Ocular Demidicosis

- Because the eye is set back into the orbit, it does not lend itself to routine washing as readily as the rest of the structures of the face
  - Demodex seem to flourish in this environment.
  - Simple cleansing of the eyelids with baby shampoo or other surfactant cleaners has been effective but may be ineffective as a stand alone treatment modality
- Tea tree oil (TTO), naturally distilled from the leaves of the Melaleuca alternifolia plant, appears to be the most effective treatment at this time (new agents are coming)
  - 50% TTO in-office therapy, a 10% TTO home therapy, a 5% TTO ointment, commercially available TTO shampoo and Cliradex (terpinen-4-ol, Bio-Tissue).
    - Cliradex is typically prescribed once or twice daily for three to six weeks.

Ocular Demidicosis

- Microblepharoexfoliation (MBE) using the BlephEx device (BlephEx).
  - MBE ideal induction therapy for demodicosis by rapidly stripping away accumulated sebum, devitalized epithelial tissue, bacterial biofilm, cylindrical dandruff and even the more superficial mites themselves
- Lotilaner functions as a noncompetitive antagonist of mite and arachnid GABA-gated chloride channels
  - Directly paralyzes the mite nervous system through parasite-specific GABA inhibition, leading to death[1,2]
- Demodex mites are virtually impossible to view at the slit lamp due to their transparent nature, small size, aversion to bright light and tendency to remain buried within the lash follicle.
  - Pulling two or three lashes and viewing them under a high magnification microscope can offer confirming evidence of these organisms in many cases.
  - Lash rotation under the slit lamp can often help with the diagnosis. Rotating a lash in a circular fashion in the follicle can irritate the Demodex organisms and cause them, along with their debris, to evacuate the follicle, often making an acute buildup of debris visible.

"PATCHING IN THE EMERGENCY ROOM"

- A 19 YOBF develops a red, painful right eye while wearing contact lenses
- Goes to the emergency room where they patch her eye with gentamicin after trying to remove "white foreign body".
- Med Hx: (-); No meds; NKDA
- Acuity: PH 20/100 OD, 20/20 OS
- Conjunctival injection OD
- Cornea: epithelial excavation with dense stromal infiltration and purulent discharge

So, what do you think?

What do you want to do now?

~~Corneal Ulcer~~

Keratitis

- Infectious keratitis
  - Microbial keratitis
    - Fungal
    - Bacterial
      - *Pseudomonas, staph, strep*
    - Protozoan
- Non-infectious keratitis
  - Sterile keratitis
    - Marginal keratitis, infiltrative keratitis, peripheral keratitis, contact lens-related infiltrate, contact lens associated acute red eye (CLAARE)

Back to the Case

- Cultures obtained
- Initiated Vigamox Q1min x 5 Min in office, then Q1H while awake
- Scopolamine in office
- F/U 24 hours

Acuity: CF @ 3"
Hypopyon

- Vigamox hourly
- Add Pred forte Q1H
  - F/U 6 hours
  - Some improvement in comfort – no worsening of ulcer
  - Continue meds
- F/U 24 hours
  - Microbiology report positive for Pseudomonas
  - Susceptible to most antibiotics
  - Improvement in comfort and inflammation

- F/U 24 hours
- Greatly reduced inflammation
- Hypopyon resolved
- Cornea healing
- Final outcome 20/25 (with some surprises)

Bacterial Keratitis

- Corneal defense breakdown
- Pathogen induction
- Proliferation and toxin release
- Toxic (organism) and mechanical (stromal lysis) antigens
- Antigen/antibody reaction
- Inflammatory response with infiltration
- Phagocytosis
- Enzyme release and further stromal lysis
- Antigen neutralization (hopefully)
- Cicatrization- fibroblast proliferation and scar tissue
- Vision loss

Bacterial Keratitis

- Pain, photophobia, lacrimation
- Innocent bystanding tissue involved
- A/C reaction - possible hypopyon
- Corneal infiltrate with excavation
- Wide presentation depending upon organism
  - Pseudomonas very exaggerated

Bacterial Keratitis: Management

- Cultures
- Broad spectrum antibiosis
  - Fortified aminoglycosides and cephalosporins
  - Ciprofloxacin (Ciloxan): iigtt q15minx 6H; Q30
  - Ofloxacin (Ocuflox): q30min, BID at night
  - Moxifloxacin or gatifloxacin Q1H (not approved)
  - Iquix; Besafloxacin
    - Later generations (4th) have greater gram + coverage
- Cycloplegics
- Cold packs
- Corticosteroids

Shah VM, Tandon R, Satpathy G, et al. Randomized clinical study for comparative evaluation of fourth-generation fluoroquinolones with the combination of fortified antibiotics in the treatment of bacterial corneal ulcers. Cornea. 2010 Jul;29(7):751-7.


Randomized Clinical Study for Comparative Evaluation of Fourth-Generation Fluoroquinolones With the Combination of Fortified Antibiotics in the Treatment of Bacterial Corneal Ulcers

Conclusion:

The study failed to find a difference in the efficacy of monotherapy with 4th-generation fluoroquinolones in the treatment of bacterial corneal ulcers of 2–8 mm size when compared with combination therapy of fortified antibiotics.

Bacterial Keratitis: Use of Corticosteroids

But aren't they contraindicated?

- Role of immunosuppression
- When to use?
  - after bacteria suppressed
  - culture and sensitivity report
  - clinical stabilization
  - 24-48 hours best starting point

Blair J, Hodge W, Al-Ghamdi S, et al. Comparison of antibiotic-only and antibiotic-steroid combination treatment in corneal ulcer patients: double-blinded randomized clinical trial. Can J Ophthalmol. 2011 Feb;46(1):40-5.


Comparison of antibiotic-only and antibiotic-steroid combination treatment in corneal ulcer patients: double-blinded randomized clinical trial

- 30 eyes of 30 patients
- Culture-proven bacterial keratitis
- Randomized to either:
  - Gatifloxacin 0.3% alone OR
  - Gatifloxacin 0.3% + dexamethasone
- Primary outcome:
  - Ulcer size at 10 weeks (photographic measurement)
- Secondary outcomes:
  - Ulcer size at 10 weeks (clinician estimate by slit lamp)
  - Visual acuity
  - Time to healing

Outcomes:

1. By photo – no statistically significant difference
2. By clinician estimate – statistically significant difference favoring the antibiotic-steroid group

Table 3—Mean residual area (mm^2) by treatment group

	Baseline	Final	Difference	p value*
By photo				
Antibiotic-only	5.483	3.090	−1.919	0.56
Antibiotic + steroid	8.802	4.412	−4.388	
By slit lamp				
Antibiotic-only	4.596	3.712	−0.789	0.05
Antibiotic + steroid	8.302	4.263	−4.206	

*p values were calculated using the Kruskal–Wallis test.

Blair J, Hodge W, Al-Ghamdi S, et al. Comparison of antibiotic-only and antibiotic-steroid combination treatment in corneal ulcer patients: double-blinded randomized clinical trial. Can J Ophthalmol. 2011 Feb;46(1):40-5.

Secondary Outcomes:

- No statistically significant differences in final visual acuity or healing rate between the antibiotic group and the antibiotic-steroid group after 10 weeks
- Conclusions: This study suggests that the early addition of steroids to the antibiotic treatment of corneal ulcers does not seem to be harmful when employed in a closely monitored clinical setting.

Blair J, Hodge W, Al-Ghamdi S, et al. Comparison of antibiotic-only and antibiotic-steroid combination treatment in corneal ulcer patients: double-blinded randomized clinical trial. Can J Ophthalmol. 2011 Feb;46(1):40-5.

SCUT: Steroids for Corneal Ulcer Trial

- Multicenter, double-masked, placebo-controlled
- clinical trial
- 500 patients with culture-confirmed bacterial keratitis
  - all patients received topical moxifloxacin 0.5%
  - randomized to either topical prednisolone phosphate 1% or placebo
- Outcome measures: BCVA @ 3 months, time to complete reepithelialization, infiltrate/scar size and perforation.

Srinivasan M, Mascarenhas J, Rajaraman R, Corticosteroids for bacterial keratitis: the Steroids for Corneal Ulcers Trial (SCUT). Arch Ophthalmol. 2012 Feb;130(2):143-50

SCUT

- **Conclusions:** "We found no overall difference in 3-month BCVA and no safety concerns with adjunctive corticosteroid therapy for bacterial corneal ulcers."
- **Application to Clinical Practice: "**Adjunctive topical corticosteroid use does not improve 3-month vision in patients with bacterial corneal ulcers."

Shortcomings of SCUT

- Corticosteroid regimen was too conservative.
  - Prednisolone sodium phosphate 1% QID X 1 wk, then BID X 1 wk, then QD X 1 wk
  - Initiated 48 hours after moxifloxacin therapy
- Considerations were not made for subjective measures such as:
  - Patient comfort & QOL
  - Functional visual recovery time
- How quickly did vision improve in the steroid group vs. the placebo group?
  - *"At 3 weeks, corticosteroid treated patients had a 0.024 better logMAR acuity (approximately one-fourth of a line)…"*

Shortcomings of SCUT

- A *MINOR footnote:*
  - *"Corticosteroid treatment was associated with a benefit in visual acuity compared with placebo in the subgroups with the worst visual acuity and central ulcer location at baseline. These subgroup analyses suggest that patients with severe ulcers, who have the most to gain in terms of visual acuity, may benefit from the use of corticosteroids as adjunctive therapy."*

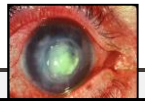

Microbiologic evaluation

- Traditional cultures (TC)
- In vivo confocal microscopy (IVCM)
- Polymerase chain reaction (PCR)
- Recent study comparing all 3 for microbial keratitis:
  - Traditional cultures were best for bacteria
  - IVCM outperformed PCR and TC for fungus
  - Both IVCM and PCR better than TC for acanthamoeba
    - Recommends multimodal approach

Hoffman et al. Eye (Lond) November 2022

Polymerase chain reaction (PCR)

- PCR allows for rapid and highly specific diagnosis of infectious diseases, including those caused by bacteria or viruses. PCR also permits identification of non-cultivatable or slow-growing microorganisms such as mycobacteria, anaerobic bacteria, or viruses from tissue culture assays and animal models.

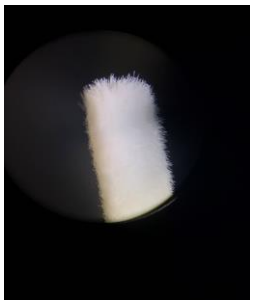





Polymerase chain reaction (PCR)

- PCR allows for rapid and highly specific diagnosis of infectious diseases, including those caused by bacteria or viruses. PCR also permits identification of non-cultivatable or slow-growing microorganisms such as mycobacteria, anaerobic bacteria, or viruses from tissue culture assays and animal models.
- Healthtrackrx.com (Dallas, Tx); 1.5-2 day turn around time
  - Bills patient/ insurance
  - Cost $125-$150
- *Procedure code: 65430 Scraping of Cornea, Diagnostic, For Smear and/or Culture*
  - $109.70

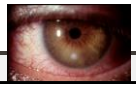

CASE

- 23 year old Asian male with bilateral redness & pain
  - thick sticky discharge, lids "glued shut" upon awakening; extreme discomfort & photophobia with blepharospasm
- Symptoms began several days ago, worsening steadily; OD affected first, then OS
- VA: 20/30 OD, 20/30 OS
- Conjunctival hyperemia with keratitis OU; (+) papillary hypertrophy OU; (+) AC rxn, no lymphadenopathy

Bacterial Keratoconjunctivitis

- Ocular defense system breakdown
- Antigen-antibody reaction
- Inflammatory response to bacteria and exotoxins
- Exotoxins alter corneal metabolism
  - Discharge is toxic to cornea
  - Epithelial breakdown and erosion
  - Punctate keratitis from mucopurulent discharge
    - Dead bacteria, white blood cells, exotoxins

Bacterial keratoconjunctivitis: Signs & Symptoms

- **Signs:**
  - conjunctival injection
    - inferior > superior
    - may extend to episclera
  - sticky, mucopurulent discharge
    - lids "glued shut", not "crusty"
    - eye may fill within minutes
  - tarsal papillae common
  - cornea may show punctate epithelial erosion
- **Symptoms:**
  - generalized ocular discomfort
  - photophobia
  - with corneal involvement may see:
    - significant pain or foreign body sensation
    - decreased acuity

Bacterial Keratoconjunctivitis

- Heavy loads or virulent organisms may be hard to eradicate without ocular damage
- Conjunctival infection can progress to corneal infection
- Nasolacrimal drainage
  - No lymphadenopathy unless hyperacute infection

Bacterial keratoconjunctivitis: Pathophysiology

- Invading bacteria and their exotoxins act as antigens, inducing an immune reaction with subsequent inflammation.
- Normally, the eye's natural defense mechanisms eradicate the invading pathogens; some bacteria are more virulent and conjunctival infection becomes manifest clinically.
- Most common organisms include:
  - *Staphylococcus aureus*
  - *Haemophilus influenzae*
  - *Streptococcus pneumoniae*
  - *Pseudomonas aeruginosa*

Bacterial keratoconjunctivitis: Management

- Culture and sensitivity testing?
  - usually time consuming and expensive; most clinicians begin treatment immediately
  - reserve for hyperacute or unresponsive presentations
- Broad spectrum antibiotics therapy
  - Fluoroquinolones represent the **BEST** option today.
    - Administration is Q2H to QID
    - WHAT ABOUT BACTERIAL **RESISTANCE**?
  - How about Polytrim, Tobrex, Erythromycin, etc…?
  - What about combination drugs (*Tobradex*® Zylet ®, or *Maxitrol*®)?

HYPERACUTE Bacterial conjunctivitis: Pathophysiology

- Hyperacute bacterial conjunctivitis presents with similar signs and symptoms, albeit much more severe.
  - Neisseria, corynebacterial
- History of recent sexual activity
  - History can become (unnecessarily) complicated
    - Partner or family in exam room
    - Patient understanding of risk behavior

Bacterial keratoconjunctivitis: Clinical Pearls

- ***Bacteria initiate an inflammatory reaction.***
- ***Antibiotics will eradicate bacteria, but will not address directly the inflammation. Eventually, the eye will return to normal, but this may need an anti-inflammatory.***
- ***Don't confuse lid CRUSTING with lid MATTING***
- ***Bacterial conjunctivitis is not common and is self-limiting. After 3 days, topical antibiosis does not affect outcome.***
- ***Treatment should be more aggressive in CL wearers because of the risk of Pseudomonas.***

Bacterial keratoconjunctivitis: Clinical Pearls

Remember that exotic lifestyles lead to exotic conjunctivises

HELP!!!

- 30 year-old white female presents as an emergency. Eyelid stuck shut
- POHX (+) Bilateral Lasik 6 months prior and using Alrex for dry eyes
- Profuse tearing and pain (level 8)

- Uncorrected VA 20/30 OD, LPP due to visual obstruction and a partial tarsorrhaphy
- **What do you do?**

A Stealthy Situation

- 47 year old White male
  - 13 years post-LASIK surgery; prior Rx -10.00 OU
- CC: decreasing vision OD X 18 months
  - Gradual "regression" in the right eye ONLY over the last 3-4 years
  - Reduced BVA OD from 20/15 to 20/70
  - Monocular diplopia OD
- Medical history unremarkable

Polling question 7

Additional testing

- Pupil testing – normal, without afferent defect
- Color vision testing – full & symmetrical
- Anterior segment biomicroscopy – normal
  - No corneal thinning or endothelial disease
  - Lenses graded as clear and symmetrical by several ECPs
- Corneal topography – normal
  - No irregular astigmatism
  - RGP lens with over-refraction – no improvement.
- Threshold perimetry – full OU
- OCT – normal macular architecture
- Fundus evaluation by retinal specialist – "perfect"
- MRI- deferred…for now

Refractive History (post-LASIK)

- 1998… Rx: OD -0.25 sph; 20/15. OS plano 20/15
- 2008… Rx: OD -0.75 sph; 20/25. OS -0.25 sph; 20/15
- 2009… Rx: OD -1.50 sph; 20/30. OS -0.25 sph; 20/15
- 2010… Rx: OD -3.00 sph; 20/50. OS -0.25 sph; 20/15
- 2011… Rx: OD -5.00 sph; 20/70. OS -0.25 sph; 20/15

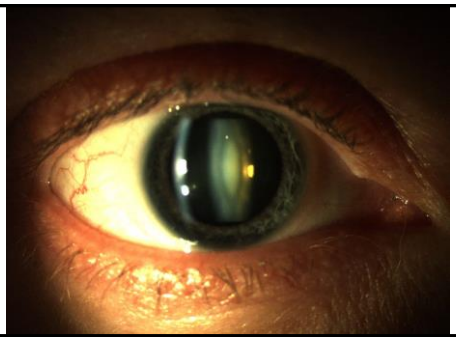

Now I am going to break HIPPA privacy and tell you who the patient is…

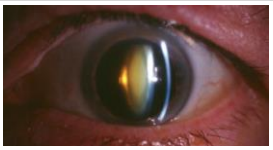

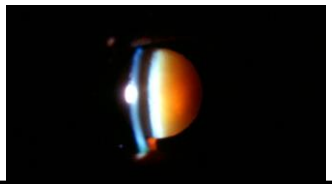

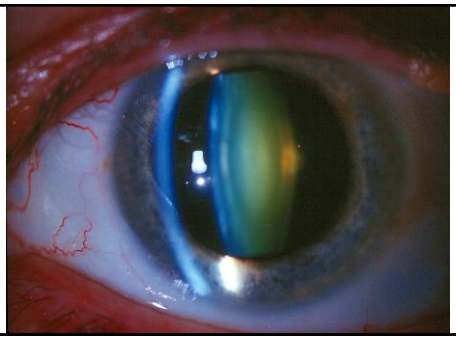

"Milky" Nuclear Sclerosis

- A.K.A. "white" NS or nuclear opalescence
- Delineates a unique type of cataract
  - Not often described in the literature as a distinct clinical entity
- Specific and unusual properties:
  - Dramatic myopic shift
  - Significant visual impairment
  - Unobstructed view of the fundus, but differing refractive indices can produce a "bowing" effect of the slit beam

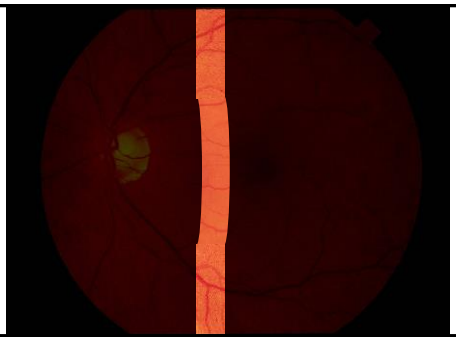

Case Continued

- Patient initially refuses to accept diagnosis
  - Eventually acknowledges cataract as possible cause
- Undergoes phaco with SV IOL
- VA 20/20 six hours after surgery
- VA 20/15 uncorrected
- Pt now accepts cataract as diagnosis

So what did we learn…?

- Not all cataracts are created equal.
- The "view in = view out" rule does not apply with milky NS.
- Be suspicious of extreme refractive shifts in older patients:
  - Hyperopic? Think retrobulbar mass.
  - Myopic? Think NS.
  - Fluctuating? Think diabetes.
- Cases commonly diagnosed by neuro-ophthalmologist
- Remember the M's
  - Myopic
  - Male
  - Middle-aged
  - Myopic shift
  - Milky NS

Not a BRITE Idea

- 59-year-old man
- Red, painful, photophobic left eye- 10 days duration.
- Past hx: Cosmetic eye whitening procedure 5 years previous
- Dental work- removal of two decayed teeth
  - Spread of infection?
  - Topical polytrim- no inmprovement
- 20/40 OD and finger counting OS
- OS profound deep injection
- Grade 3 cell and flare reaction, stromal corneal edema, endothelial keratic precipitates, near complete posterior synechiae, dense nuclear cataract, IOP 18 mm Hg OD and 34 mm Hg OS, temporal conjunctival and scleral thinning, calcific plaque. No fundus view.

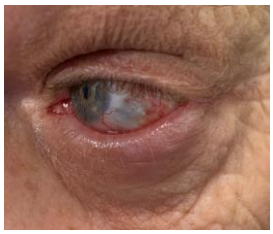

- Anterior scleritis OS
- Topical difluprednate 0.05% QID, atropine 1% BID, Combigan BID, and oral ibuprofen 800 mg QID PO.
- His medical history was significant only for diabetes and no suggestion of autoimmune or rheumatologic diseases. He was referred for medical evaluation with a rheumatologist to search for a potential underlying cause.
  - Never went

- I-Brite™ (conjunctivoplasty) is designed to remove sun-damaged tissue
- Involves both the surgical removal of conjunctiva and resection of tenon's capsule with application of Mitomycin C. Also can involve avastin. I-Brite developed by Beverly Hills Ophthalmologist
  - Now calls it WhiterEyes®
  - Also Cosmetic Eye Whitening™, performed commercially in South Korea
- One review of 1713 patients undergoing cosmetic whitening procedures noted an overall complication rate of 83%, of which 55.6% were considered severe. These severe complications included fibrovascular conjunctival tissue proliferation, scleral thinning, scleral thinning with calcified plaques, intraocular pressure elevation, diplopia, and recurrence of hyperemic conjunctiva.

Lee S, Go J, Rhiu S, Stulting RD, et al. Cosmetic regional conjunctivectomy with postoperative mitomycin C application with or without bevacizumab injection. Am J Ophthalmol. 2013 Sep;156(3):616-22.

- 231 patients undergoing cosmetic eye whitening, 4 patients developed necrotizing scleritis.
  - Average time was 51 months
  - All had unilateral findings.
  - No underlying systemic autoimmunity or infectious etiology found.
  - Due to large area treated with MMC, necrotizing scleritis more extensive and severe
- 48 patients undergoing procedure, 92% had complications.
  - Chronic conjunctival defects, scleral thinning with or without calcified plaques, fibrovascular conjunctival adhesion at the muscle insertion site, chronic dysfunctional tear syndrome, avascular zones, abnormal vessel growth, lymphangiectasis, adhesions of Tenon capsule and the conjunctiva at the extraocular muscle insertion site, extraocular muscle fiber exposure, and diplopia

Ji YW, Park SY, Jung JW, et al. Necrotizing Scleritis After Cosmetic Conjunctivectomy With Mitomycin C. Am J Ophthalmol. 2018 Oct;194:72-81.
Rhiu S, Shim J, Kim EK, Chung SK, Lee JS, Lee JB, Seo KY. Complications of cosmetic wide conjunctivectomy combined with postsurgical mitomycin C application. Cornea. 2012 Mar;31(3):245-52.

The Case of The Found Dinosaur

- 63 YOM c/o veiling over OD for past 2 days; VA 20/40
- Hx of lasered retinal tear- always worried about RD
- Hx cataract removal with YAG capsulotomy 15 years earlier
- Initial inspection reveals opacification behind IOL
  - But what about that YAG history?
- Grade 2 anterior chamber reaction
- IOP 32 mm OD, 15 mm OS

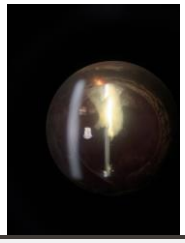

Phacoanaphylactic Uveitis/ Retained Lens Fragment

- Inflammatory secondary glaucoma usually due to antigenic lens materials inadvertently left in the eye.
- Autoimmunity to lens antigens, which may be left in anterior chamber following procedure.
- Occurs as a severe uveitis following cataract extraction- may be confused with endophthalmitis.
- In post-surgical cases, there will be either lens cortex or nucleus material (which may not be readily observable) that was not completely removed during the operation. When this happens, it is termed, "retained lens fragment". Should penetrating lens trauma be the inciting factor, then the term lens particle glaucoma is used.

Phacoanaphylactic Uveitis/ Retained Lens Fragment

- Retained lens fragments may hide between IOL and posterior capsule and be protected until later.
- Initiates an open angle glaucoma without pupil block
- Nuclear lens fragments are much more likely than cortical fragments to induce this response.
- Initial inclination to increase/use steroids
  - Rarely effective in providing a cure. Short term only
  - Aqueous suppressants can be used but the material should be removed
  - Pt was placed on topical steroids and Combigan until the fragment was YAGed

The Non-Healing Abrasion:

- 30 YOWM
- Painful, red left eye x 2 weeks;
- Treated previously for "corneal abrasion"
  - Gentamicin gtt and ung with patching QHS by PCP
  - Minimal epitheliopathy
- Treated subsequently with Voltaren, debridement, bandage lens, Tobradex, E-mycin ung
  - Enjoyed Tobradex

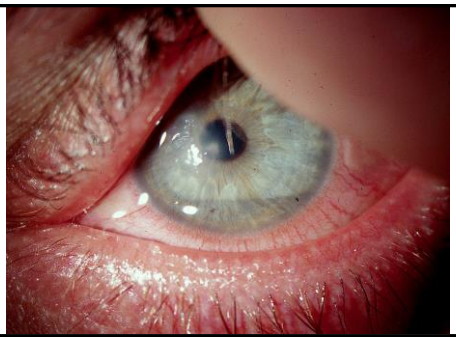

SO…

WHAT'S THE DIAGNOSIS?

Herpes Simplex Disciform Keratitis: Signs and Symptoms

- Discrete disc shaped areas of focal stromal edema
- Stromal infiltration
- Central or peripheral
- Epithelium intact

- Pain
- Photophobia
- Lacrimation
- Vision loss
- Avascular

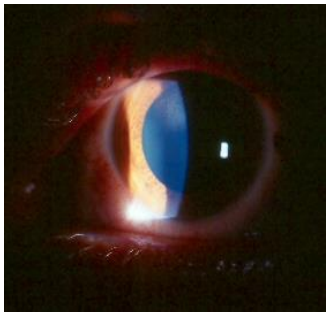

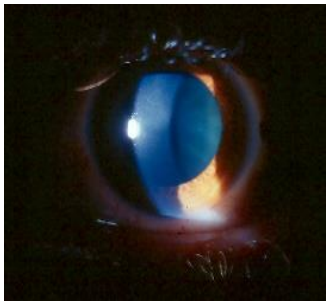

Herpetic Disciform Keratitis

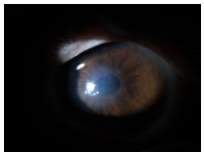

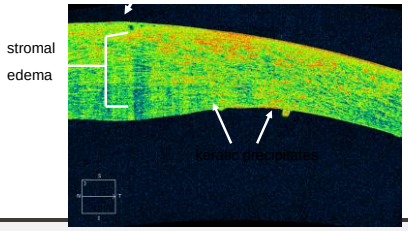

OCT Progression

Date		Corneal Thickness
Sept. 21		900µm
Sept 24	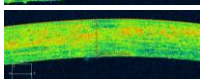	564µm
Oct 12		540µm

Herpes Simplex Stromal Disease: Disciform Keratitis

- Discrete disc shaped areas of focal stromal edema
- Central or peripheral
- Typically mild, epithelium intact, avascular

Herpes Simplex Disciform Keratitis

- Delayed hypersensitivity reaction to HSV
  - No active virus present
- Self limiting- manage conservatively
  - Cycloplegia & lubrication
- topical steroids
  - Lowest concentration to quell disease
- Prophylactic topical antivirals if steroids are used (more than BID)
- Oral antivirals not helpful

Herpetic Eye Disease Study Phase 1

- HEDS-SKN (Not on Steroid Treatment)
- HEDS-SKS (On Steroid Treatment)
- HEDS-IRT (Iridocyclitis receiving Steroids)

HEDS-SKN

- **PURPOSE** was to evaluate the efficacy of topical corticosteroids in the treatment of herpes simplex stromal keratitis in conjunction with topical trifluridine
- **RESULTS:** Patients receiving prednisolone phosphate drops in conjunction with topical trifluridine had faster resolution of their stromal keratitis and fewer treatment failures

HEDS-SKS

- **PURPOSE** was to evaluate the efficacy of oral acyclovir in the treatment of herpes simplex stromal keratitis in patients receiving concomitant topical cortical steroids and trifluridine
- **RESULTS:** The was **NO** apparent benefit with the addition of oral acyclovir to the treatment regimen of a topical corticosteroid and topical anti-viral for the treatment of herpetic stromal keratitis

HEDS-IRT

- **PURPOSE** was to evaluate the efficacy of oral acyclovir in the treatment of herpes simplex iridocyclitis in conjunction with treatment with topical corticosteroids and trifluridine
- **RESULTS:** The trial arm was discontinued due to poor patient recruitment, **HOWEVER**, the trending data suggested a benefit in adding oral acyclovir to the treatment of HSV iridocyclitis in patients who received topical corticosteroids and trifluridine prophylaxis

HEDS – Phase II

- HEDS-EKT (Epithelial Keratitis Trial)
- HEDS-APT (Acyclovir Prevention Trial)
- HEDS-RFS (Recurrence Factor Study)

HEDS-EKT

- **PURPOSE** was to determine whether early treatment of herpes simplex corneal ulcerations with oral acyclovir would prevent progression to the blinding complications of stromal keratitis and iridocyclitis
- **RESULTS** demonstrated that there was **NO** benefit from the addition of oral acyclovir to the treatment with topical trifluridine in prevention of the development of stromal keratitis or iritis.

HEDS-APT

- **PURPOSE** was to determine the efficacy of low dose oral acyclovir in prevention of recurrent HSV eye infection in patients with previous episodes of herpetic eye disease
- **RESULT** demonstrated that acyclovir taken 400mg BID PO reduced by **41%** the probability that any form of herpetic eye disease would return in patients who had the infection in previous years.

HEDS-RFS

- **PURPOSE** is to determine the role of external factors such as UV light or corneal trauma and behavioral factors such as life stress on the induction of ocular recurrences of HSV
- **RESULTS** have **not** been published to date

Summary

- Herpetic Epithelial Keratitis – **NO** Steroid
- Stromal Keratitis – Topical Steroid
  - **Beware of Epithelial Breakthrough**
- Epithelial and Stromal Keratitis – Oral Acyclovir **NO** Benefit
- Prevention of Recurrences – Oral Acyclovir **IS** a Benefit
- Herpetic Iridocyclitis – Oral Acyclovir may be beneficial
  - **Beware of Iris Atrophy and Elevated IOP**

Case

- A 45 year old female presents with a swollen eyelid and a history of "possibly being scratched by a child during play".
- She self-medicates with OTC antibiotic ointment and it gets worse.

So, what do you think?

What do you want to do now?

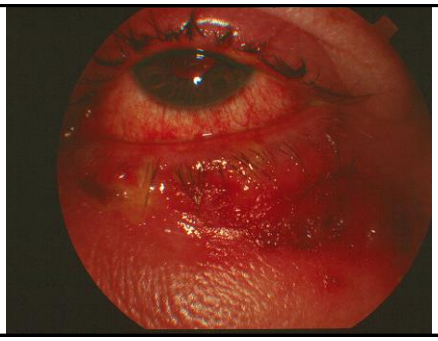

So, what do you think?

What do you want to do now?

Herpes Simplex Blepharitis

- Encountered primarily in children, may occur in adults
- Pain, tenderness
- Lacrimation
- Follicles
- Preauricular lymphadenopathy

Herpes Simplex Blepharitis

- Primary ocular infection in children
  - Blepharitis or blepharoconjunctivitis
- Recurrence typically is dendritic keratitis
- Recurrent blepharitis can occur
- Trigger factors
  - Fever, emotional stress, menstruation, solar exposure

Herpes Simplex Blepharitis

- No specific treatment: self limiting
- Drying agents
- Topical prophylactic antibiotic ointment
- Topical, oral antivirals advocated by some for severe cases. Viroptic essential if cornea involved. Prophylactic unnecessary
- Topical corticosteroids?
  - Predispose to corneal outbreak?