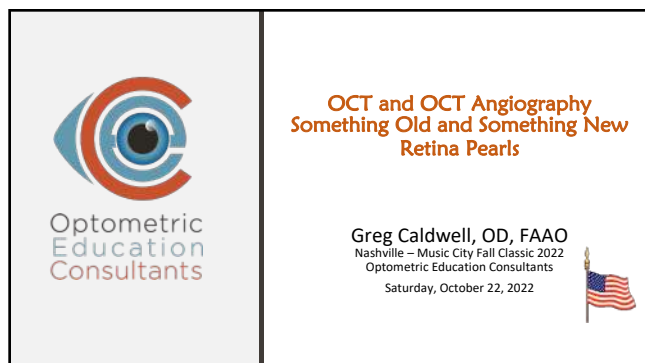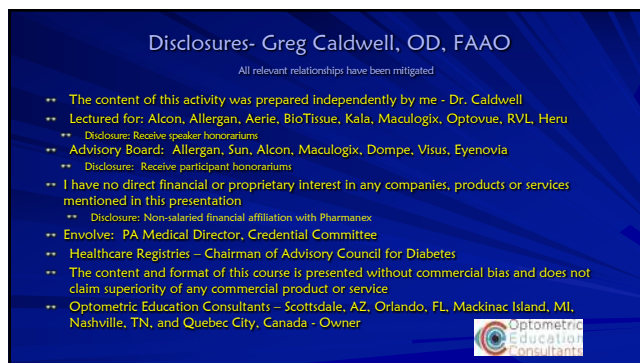

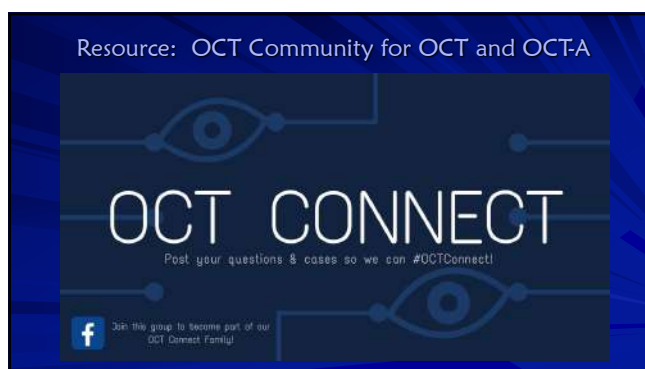



1



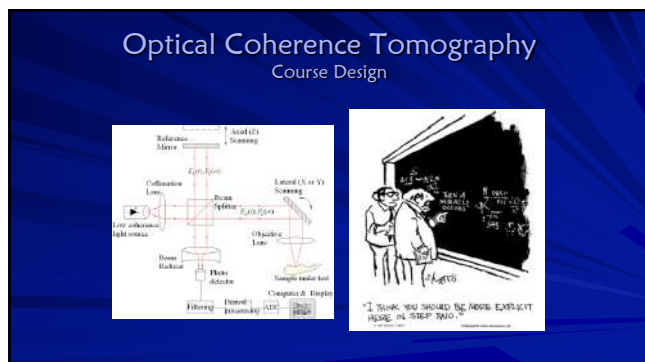
2



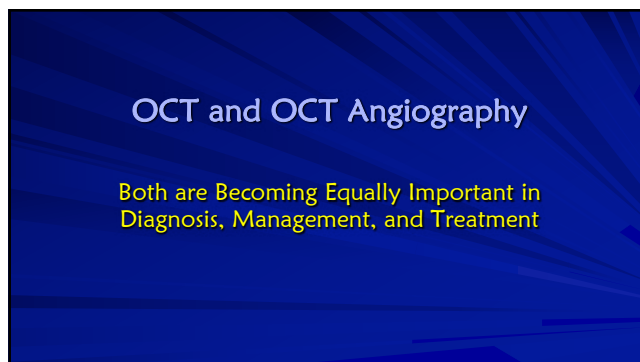
5



6



7



8

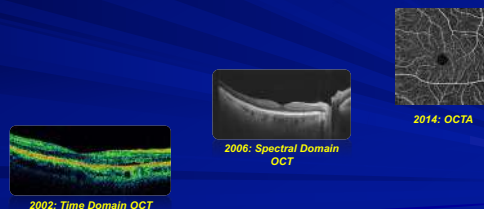Optical Coherence Tomography

- ~ OCT is an optical signal acquisition and processing method
- ~ Time domain OCT
 - * 15-16 microns of resolution
 - * Stratus (Zeiss)
- ~ Spectral domain (SD-OCT) or Fourier domain OCT
 - * Spatially encoded frequency domain OCT (SEFD-OCT)
 - * 5-6 microns of resolution
 - ~ Able to see photoreceptor morphology (inner/outer segments)
 - * 50 times faster than time domain
- ~ Swept source OCT
 - * Time encoded frequency domain OCT
 - * 1 micron of resolution
- ~ Future of OCT: intraoperative imaging, blood flow and oxygenation measurements
- ~ May have the possibility to assess retinal pathology like a pathologist

9

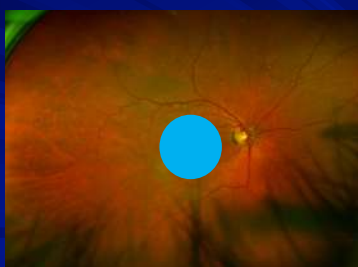
OCT Angiography: the Next Chapter in Posterior Imaging

- ~ Images retinal microvasculature without dye injection
- ~ Displays structure and function from a single imaging system



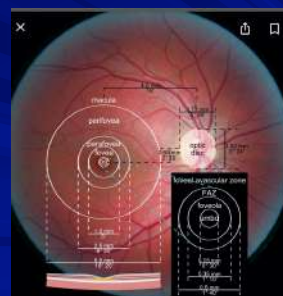10

Where is the macula?



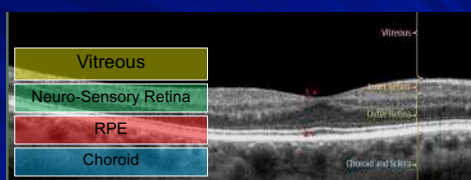
11

How large is the macula?

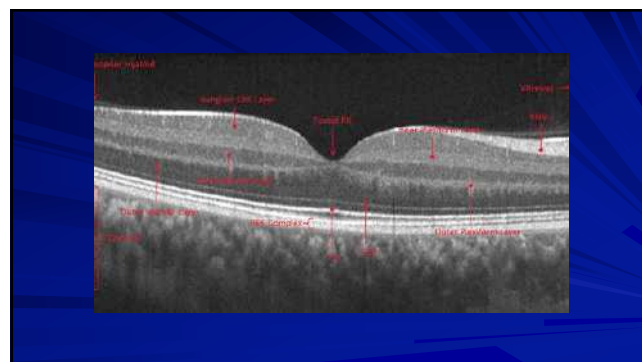


12

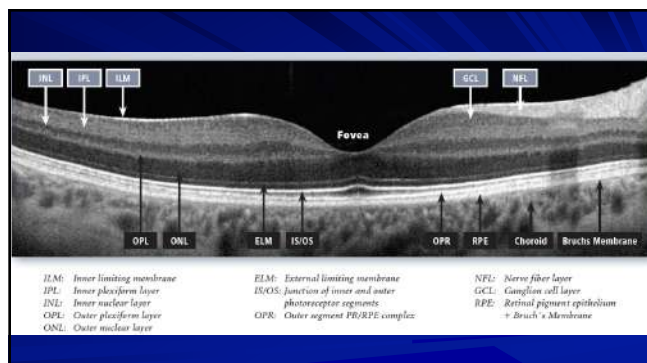
4 Basic Categories: Diseases of the....



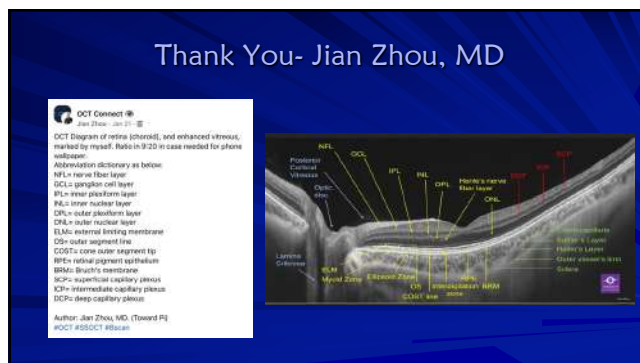13



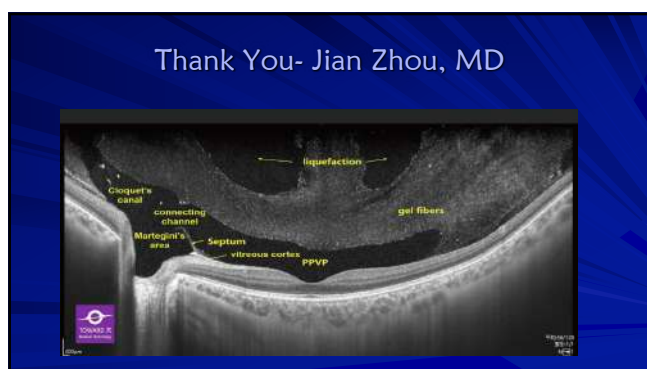14



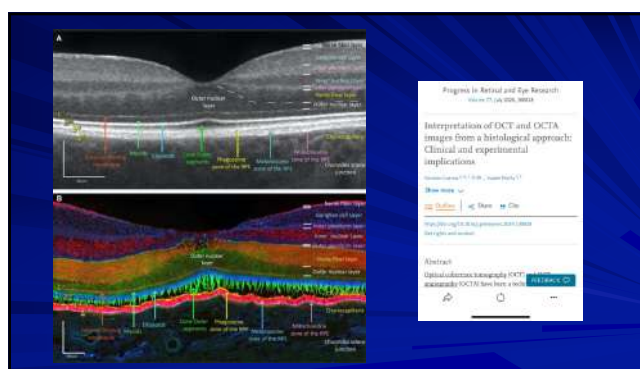
15



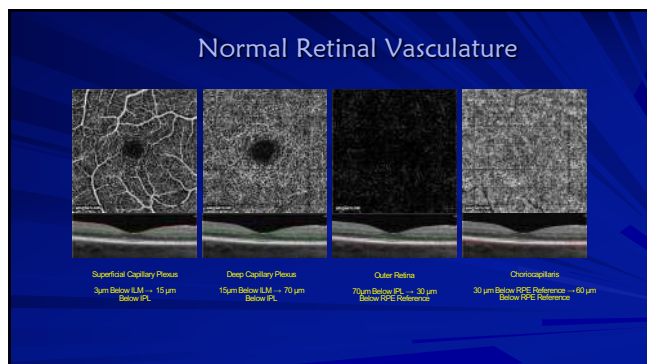
16



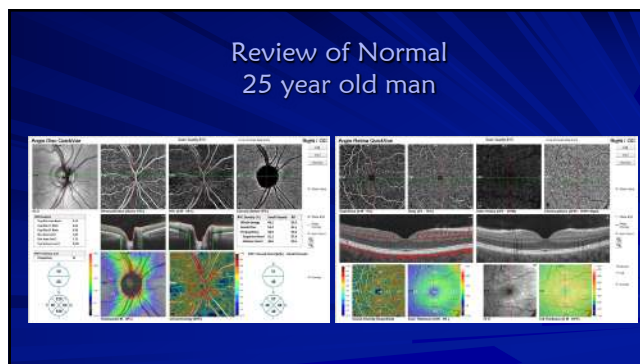
17



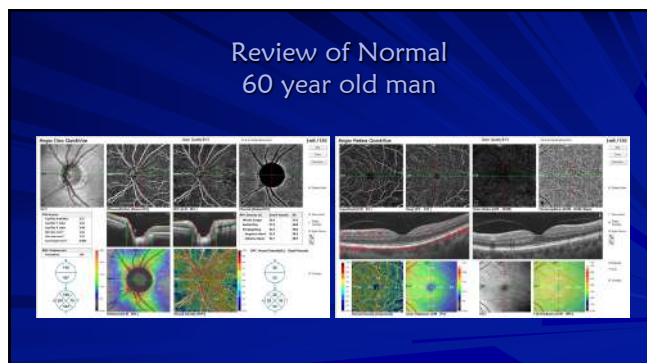
18



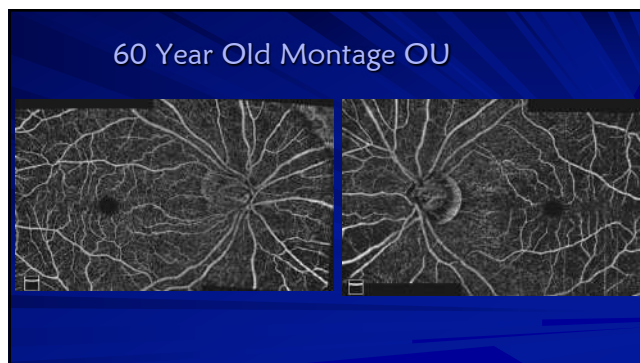
19



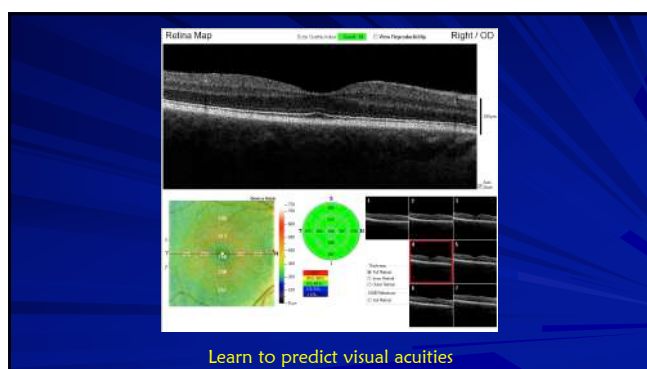
20



21



22

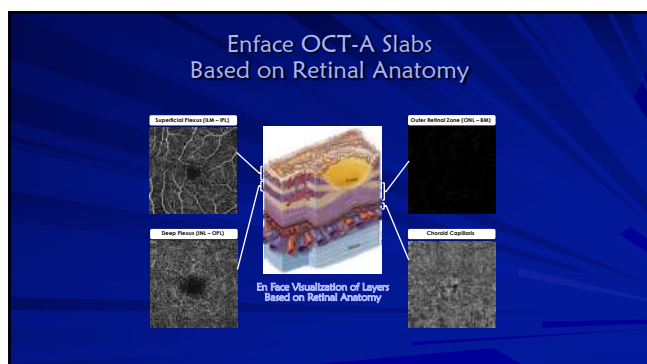


23

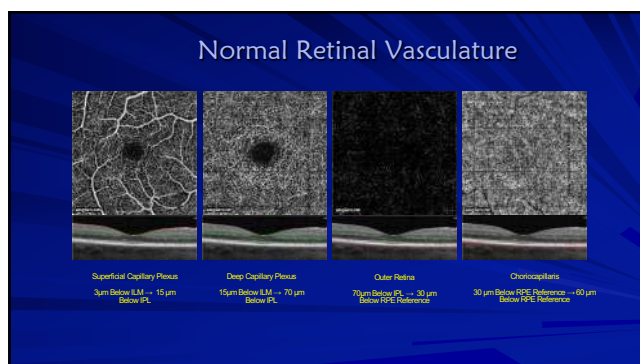
OCT Angiography
 A New Approach to Protecting Vision

- ▶ Non-invasive visualization of individual layers of retinal vasculature
- ▶ Pathology not obscured by fluorescein staining or pooling
- ▶ Image acquisition requires less time than a dye-based procedure
- ▶ Reduced patient burden allows more frequent imaging to better follow disease progression and treatment response

24



25



26

27

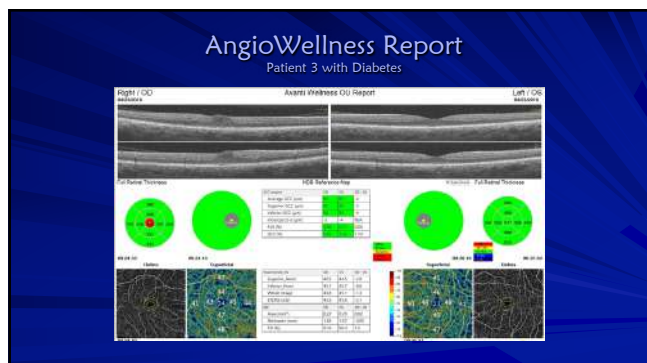
28

29

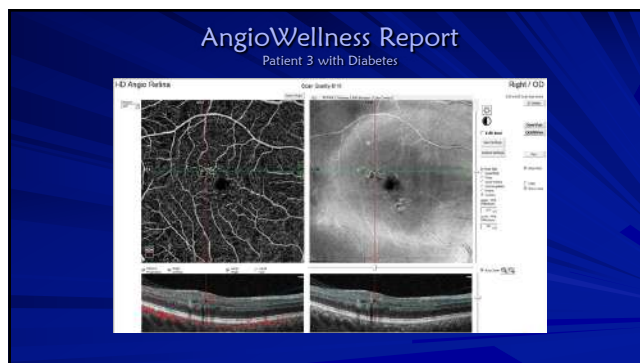
30

31

32



33

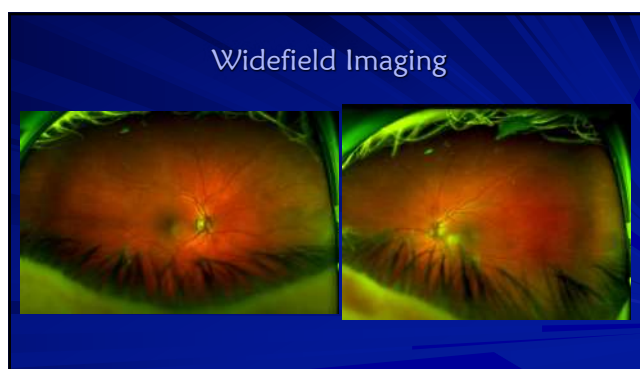

34

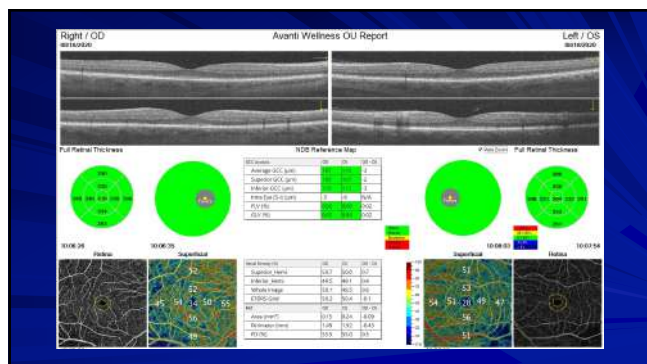
58-year-old man with diabetes

- ~ New patient to the practice
- ~ BS: unsure, last HbA1c unsure
- ~ DM meds: metformin, glyburide, Invokana
- ~ Vision 20/20
- ~ Anterior segment: normal

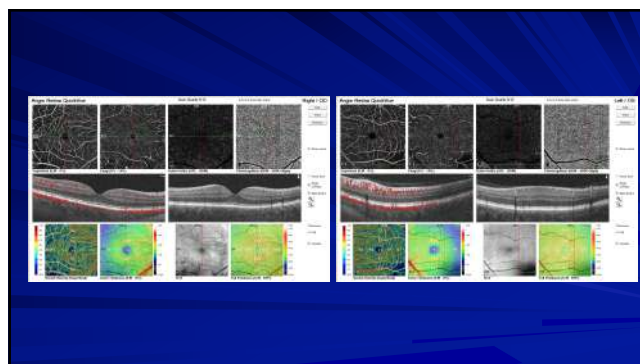
35



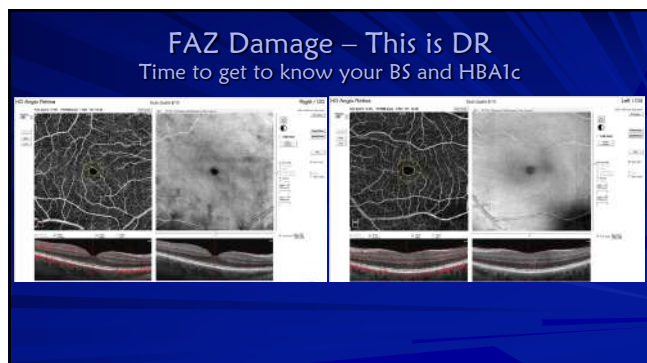36



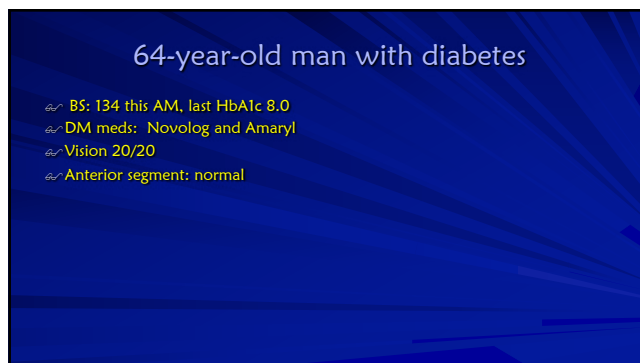
37



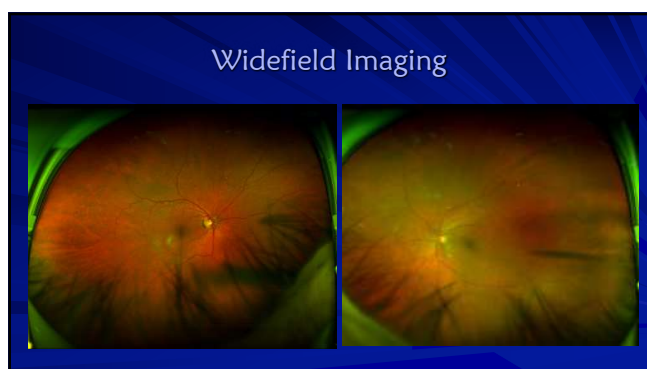
38



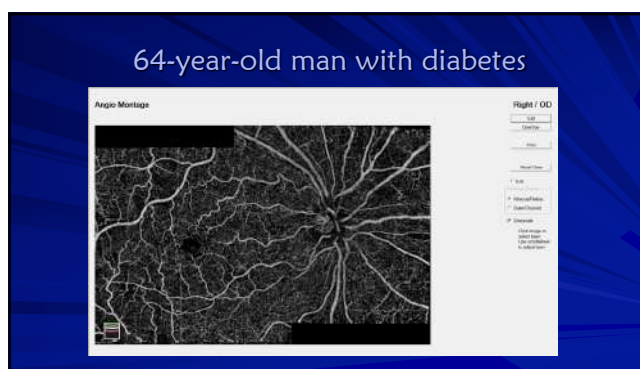39



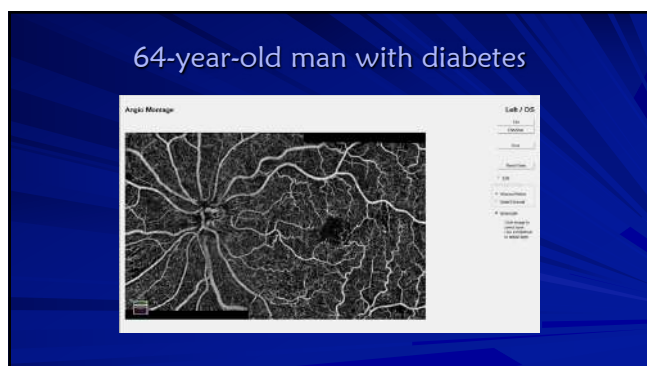
40



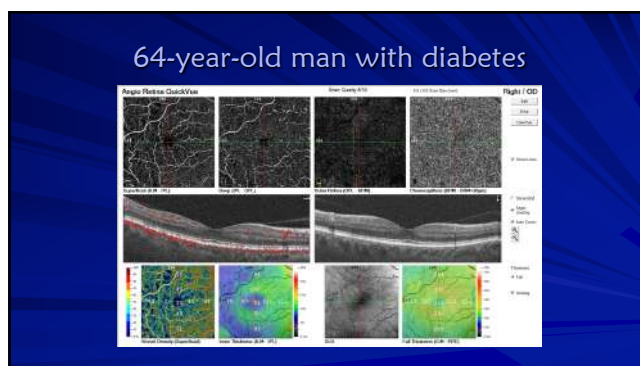
41



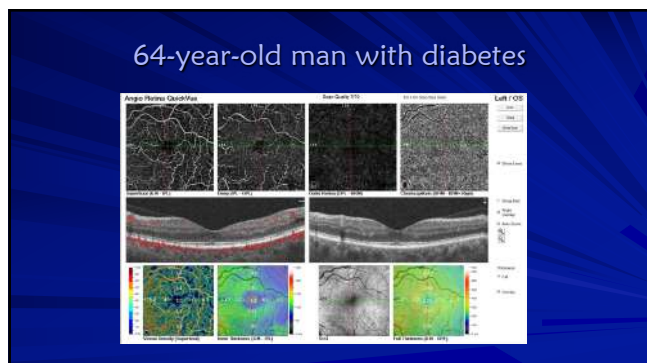
42



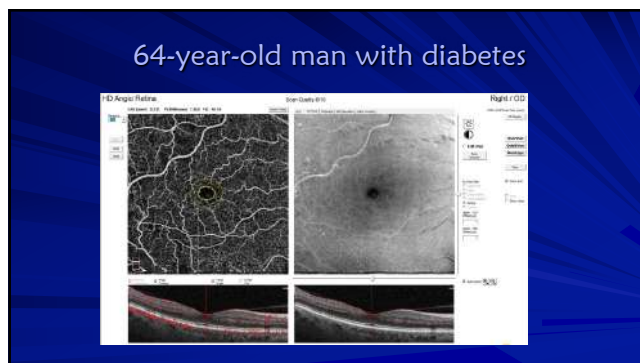43



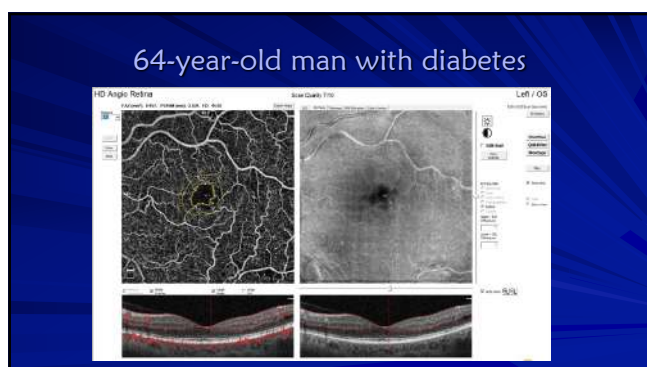44



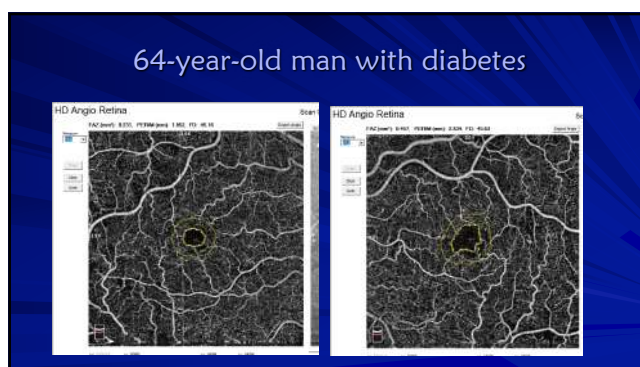
45



46



47



48

OCT and OCT-A

- ~ Treatment?
- ~ Certainly useful, beneficial, essential, and important in following the patient with diabetes
- ~ Improved HbA1c

49

AMD

50

Optometrists and All Eye Care Professionals Responsibility

- ~ Rethink our responsibility related AMD diagnosis and management
- ~ Commit to that we will do better in
 - * Early detection
 - * Treatment
- ~ Know, execute, and employ current clinically appropriate Practice Guidelines
 - * Those that preserve vision
 - * Don't wait until vision has been lost
- ~ Closely monitor and treat the early detected disease
 - * If progresses to advanced AMD, better opportunity to save vision

51

Instruments for AMD – fragmented care

- ~ Slit lamp/DFE
- ~ Camera
- ~ OCT
- ~ OCT Angiography
- ~ Dark adaption
- ~ PHP
- ~ Macula pigment eval – Scanner
- ~ Genetic testing

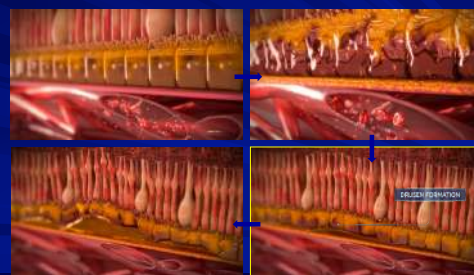
52

Beckmann Committee Classification of AMD

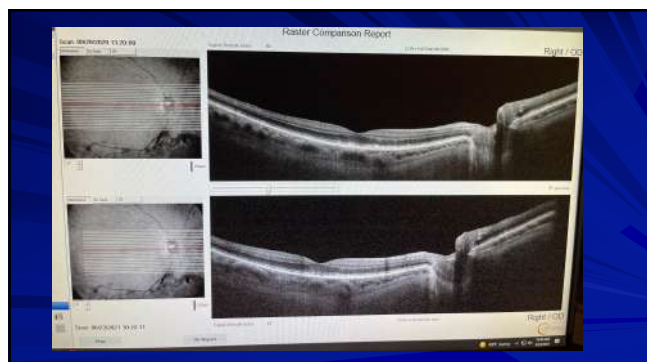- ~ Based on presence of lesions within 2 DD of fovea in either eye
 - * No AMD
 - None or few small drusen, < 63 microns
 - No AMD pigmentary abnormalities
 - * Early AMD
 - Medium drusen, > 63 – <125 microns
 - No AMD pigmentary changes
 - * Intermediate AMD
 - 1 large drusen, > 125 microns
 - Any AMD pigmentary changes
 - * Advanced AMD
 - Any geographic atrophy
 - Choroidal neovascularization (CNV)

53

AMD is a Disease Process that Starts Below the Surface

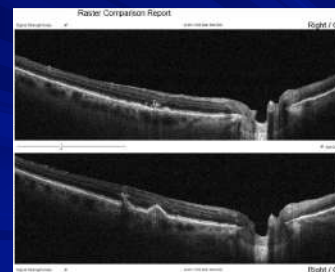


54



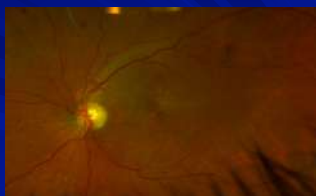
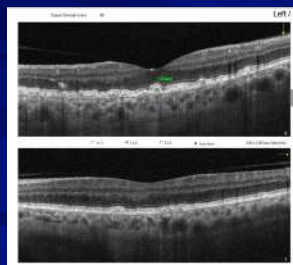
55

April 27, 2021 – January 26, 2022 (9 months)



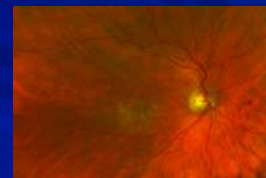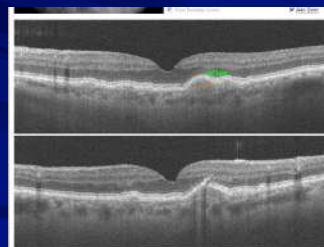
56

Measure the Drusen with Your OCT



57

Measure the Drusen with Your OCT



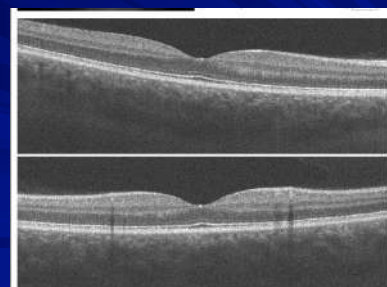
58

OCT in AMD

- ~ Need spectral domain to follow intermediate or worse AMD
- ~ Able to identify OCT predictors of progression
- ~ Especially in identifying OCT predictors of progression
 - * Hyper-reflective foci
 - * Reticular pseudodrusen
 - * Nascent geographic atrophy
 - * Sub-RPE hyper-reflective columns
 - * Drusen substructures
 - * Drusen load and regression

59

Hypo versus Hyper Reflectance



60

Can We Learn From These Pictures?



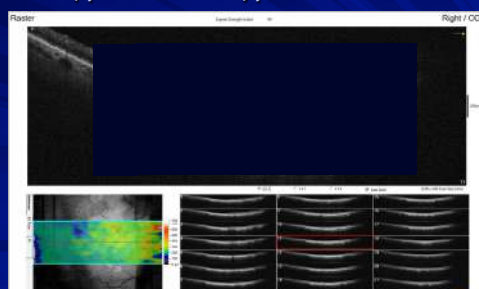
61

Can We Learn From These Pictures?



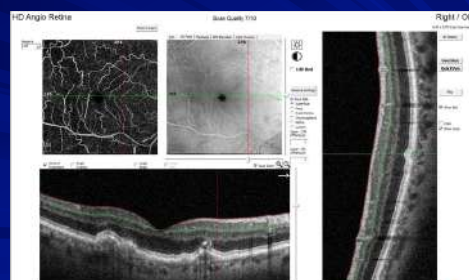
62

Hypo versus Hyper Reflectance



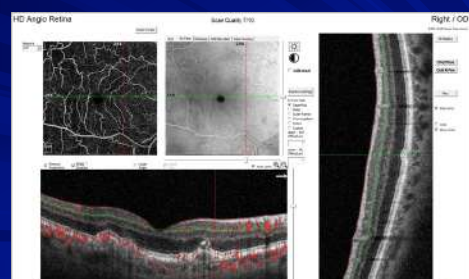
63

Case 1 - OCT Predictors of Progression



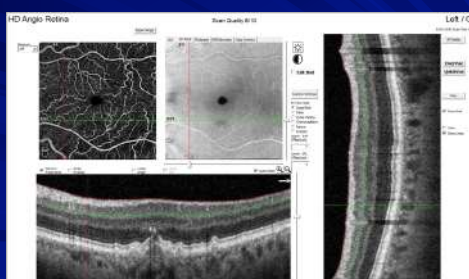
64

Case 1 - OCT Predictors of Progression



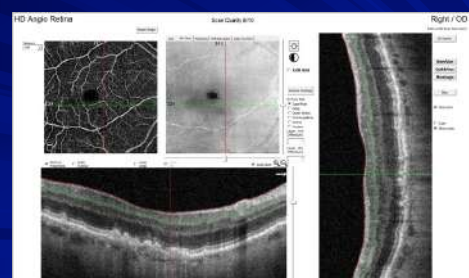
65

Case 1 - OCT Predictors of Progression



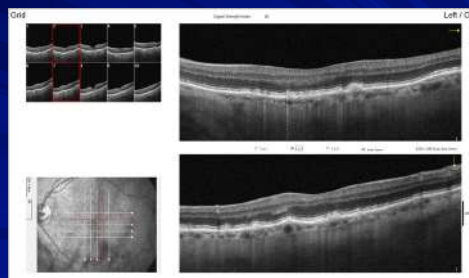
66

Case 2 - OCT Predictors of Progression



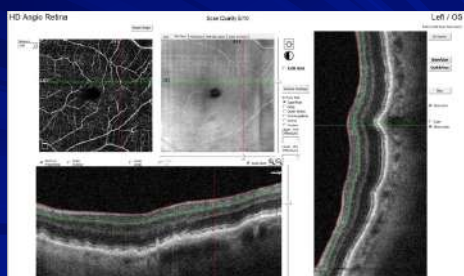
67

Case 2 - OCT Predictors of Progression



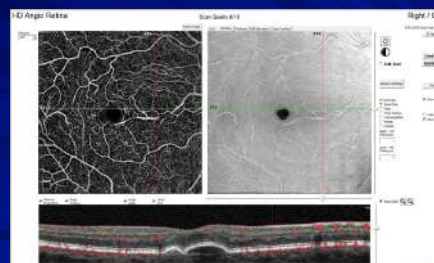
68

Case 2 - OCT Predictors of Progression



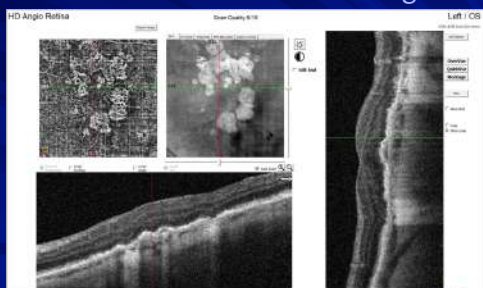
69

Case 3 - OCT Predictors of Progression



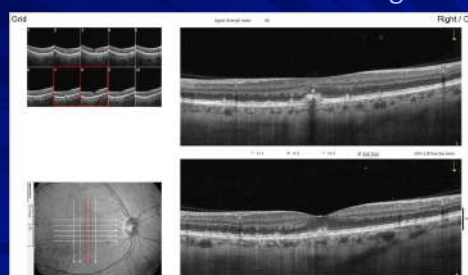
70

Case 4 - OCT Predictors of Progression



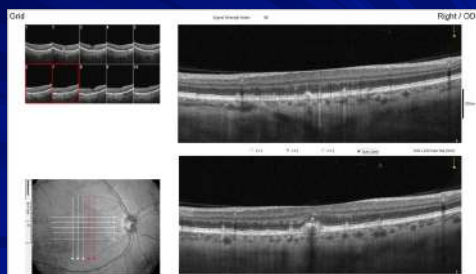71

Case 5 - OCT Predictors of Progression



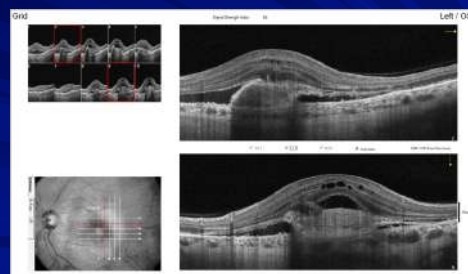
72

Case 5 - OCT Predictors of Progression



73

Case 5 - OCT Predictors of Progression



74

OCT Angiography in AMD Structure Test

- ~ Able to identify occult or classic CNV before they leak
- ~ Non-invasive technique
- ~ Subclinical CNV or "Occult non-exudative CNV"
- ★ Risk of exudation at 12 months is 15.2 times greater compared to eyes without subclinical CNV

75

Type 1 "Occult" CNV

~ CNV

- ▶ New vessels develop in the choroid
- ▶ New vessels located below RPE and above Bruch's membrane

76

Type 1 "Occult" CNV

- ~ New vessels develop in the choroid
- ~ New vessels located **BELOW RPE** and **ABOVE** Bruch's membrane

RPE
 Bruch's Membrane
 Choroid

77

CNV?

72 y/o Hispanic male
 20/30
 History of "Dry AMD"

78

Multimodal imaging and OCTA

VAGUE???

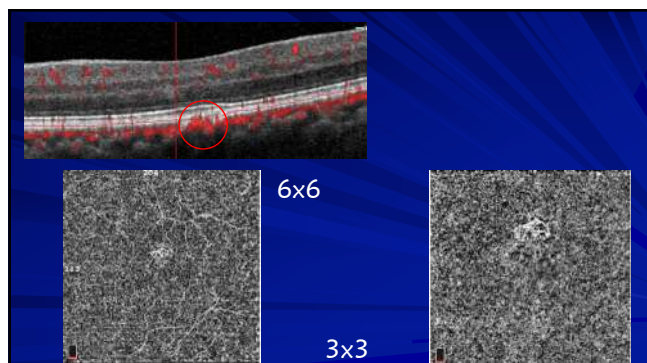
VAGUE???

Vascularized Non-vascularized

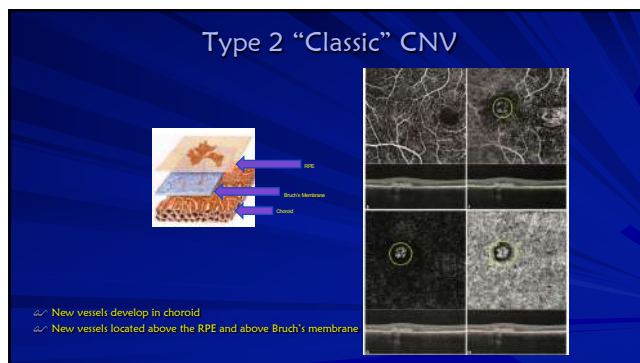
79

And the not so obvious ones...

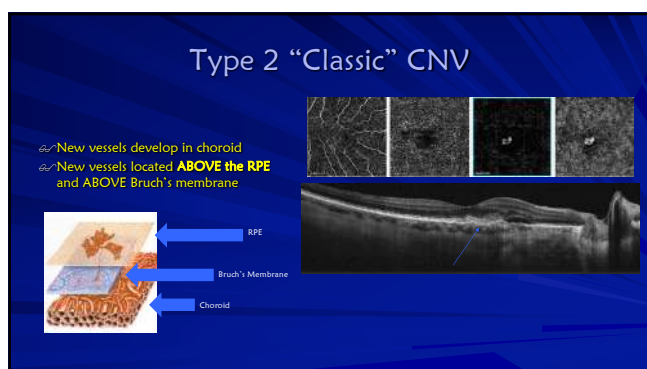
80



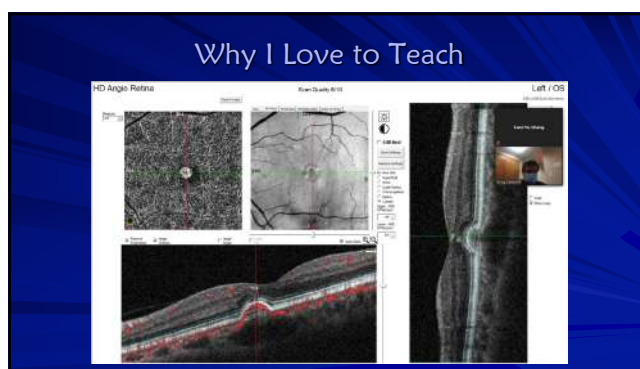
81



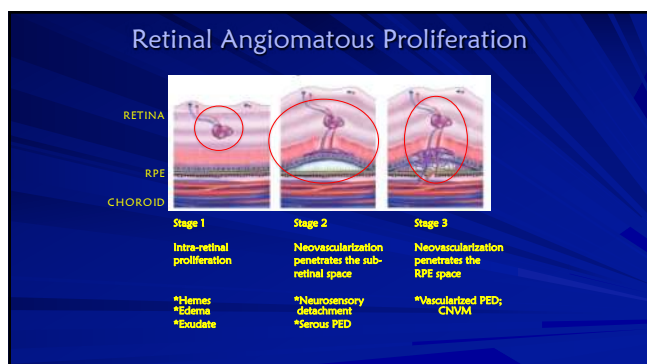
82



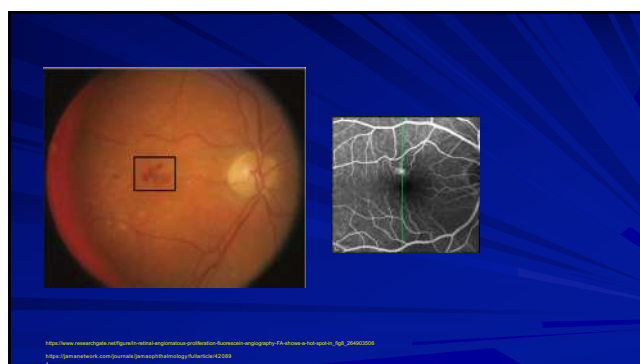
83



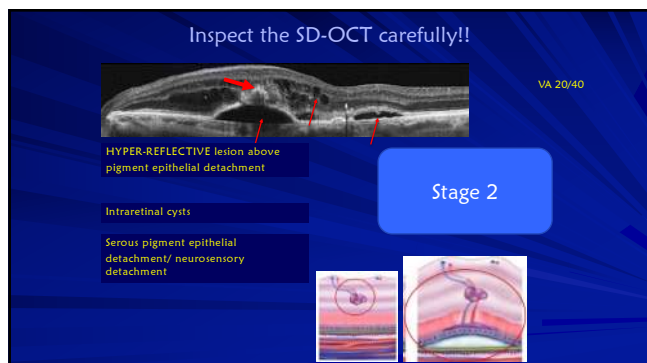
84



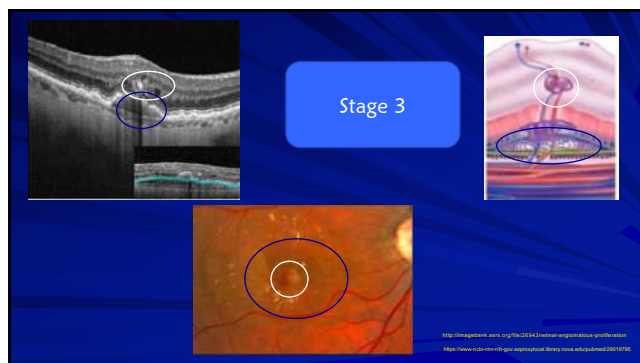
85



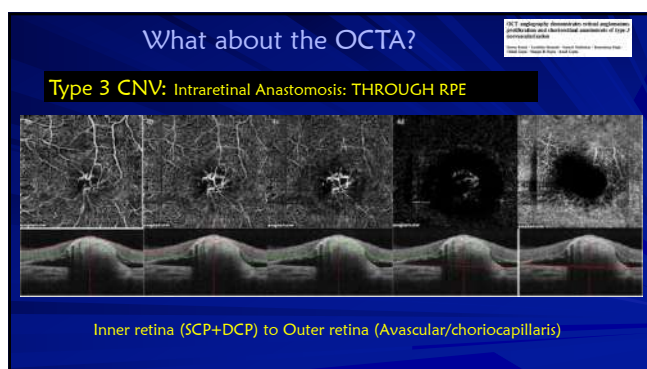
86



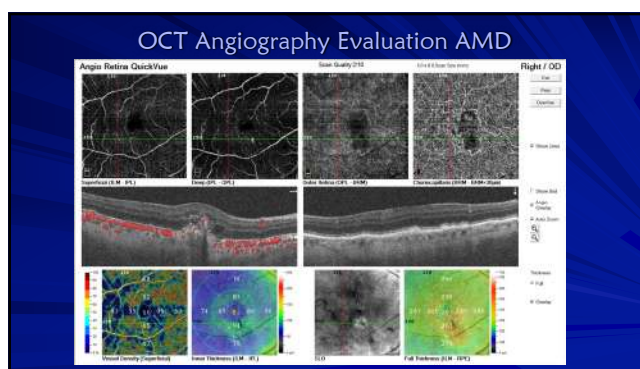
87



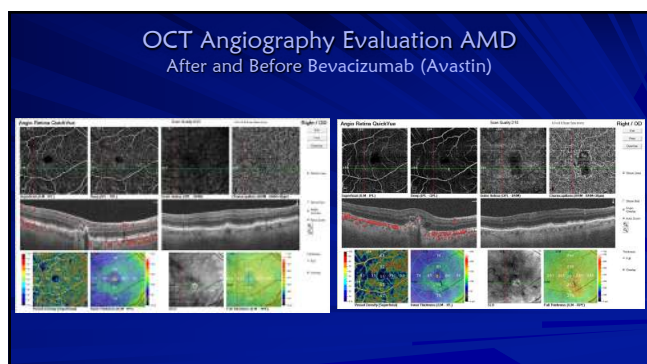
88



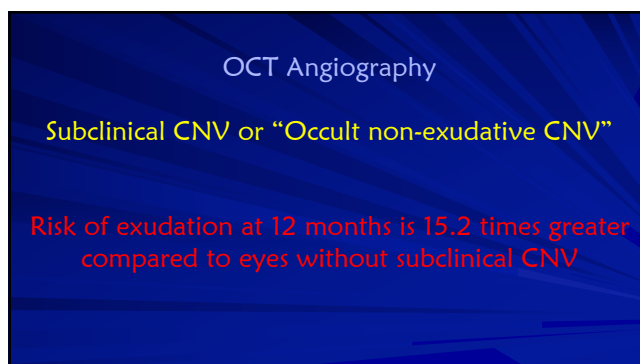
89



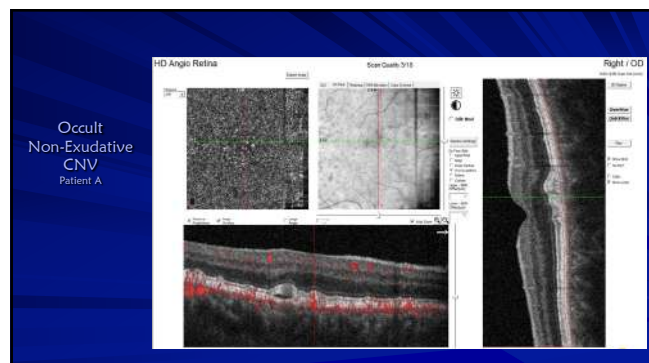
90



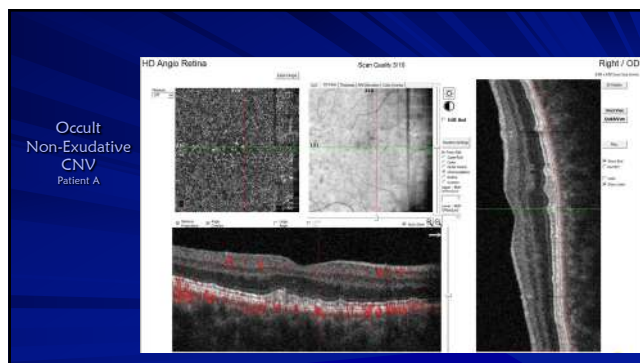
91



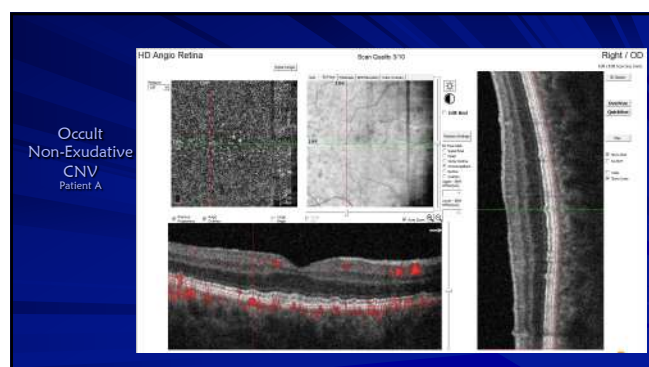
92



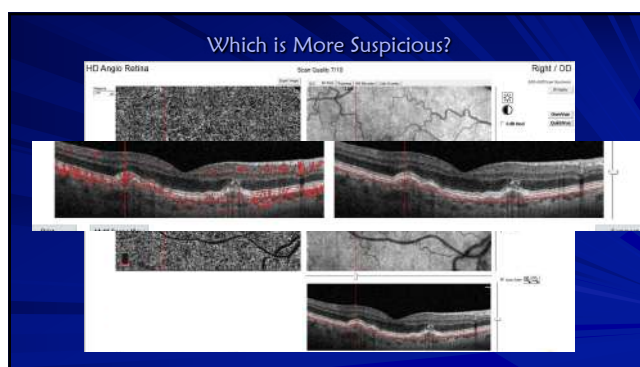
93



94



95



96

Treatments for AMD

Early detection and meaningful treatments with significant value, do not cure, but have been shown to slow or halt progression. Not limited to early stages but all stages of AMD

- ★ Prescribe smoking cessation programs
 - Smoking and AMD
 - Depletes serum antioxidants
 - Decreases pigmentary density
 - Increases risk to advanced AMD
- ★ Lifestyle changes
 - Diet
 - Exercise
- ★ Systemic disease management
 - Cardiovascular disease, DM, obesity, high cholesterol

97

Treatment for AMD

Nutritional supplements

- ★ Sub-clinical/sub-structural or early disease
 - Controversy flourishes
 - No definitive guideline exists
 - Despite consensus evidence suggests using supplements
- ★ Intermediate - advance disease
 - No controversy on advocating for supplements
- ★ AREDS 1
 - Contains Beta-carotene and no lutein or zeaxanthin, no longer recommended
 - Investigated early AMD, no statistically significant benefit
- ★ AREDS 2
 - Recommended for intermediate and advanced AMD, study protocol
- ★ The Practical Guide for the Treatment of AMD - 3 primary options
 - Macular pigment supplement
 - Carotenoids: lutein, zeaxanthin, meso-zeaxanthin
 - Carotenoids, antioxidants, zinc, and vitamins C & E
 - AREDS 2
 - Carotenoid macular supplement in subclinical and early AMD, Carotenoid and antioxidant is intermediate and AMD that is progressing

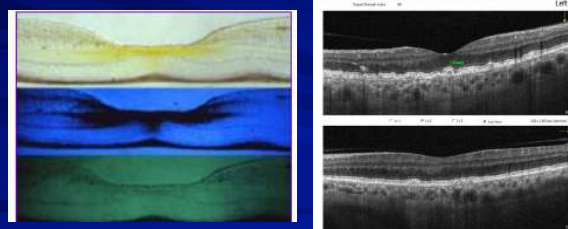
98

Treatment for AMD

- ✧ Retinal light protection
 - ★ Sun exposure
- ✧ Closer follow up
 - ★ 12 months is currently accepted as being too long to defect progression
 - ★ 6 months or sooner based on risk of CNV
- ✧ Low vision and rehabilitation consultation

99

Macular Pigment



100

Macular Pigment

Imaging lutein and zeaxanthin in the human retina with confocal resonance Raman microscopy

Binling Li¹*, Evan W. Savage², Gregory T. Regnier¹, Anura Senanayake¹, Archibald Rangarajoff¹, Bo Yan Chang¹,
Unja Shi¹, Joanne M. Frederick¹, and Paul S. Bernstein^{1,2}

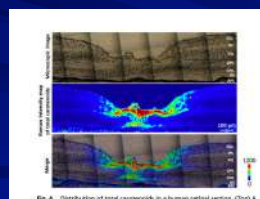
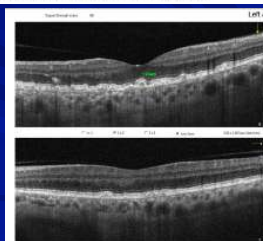
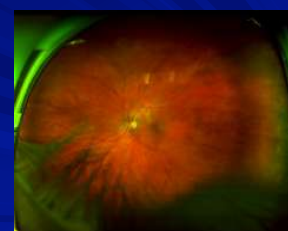
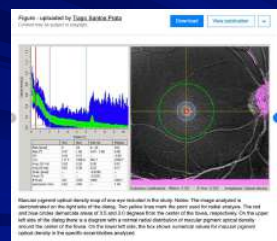


Fig. 4. Distribution of total carotenoids in a human retinal section. (Top) A.

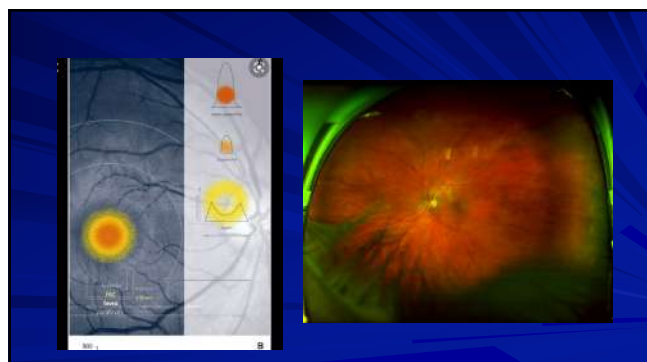


101

Macular Pigment and the Retina



102



103

Macular Pigment

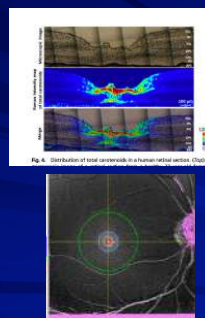
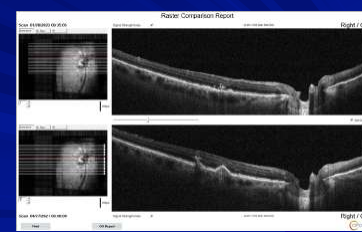




Fig. 8. Distribution of total caryocoids in a human retinal section. Cytoc



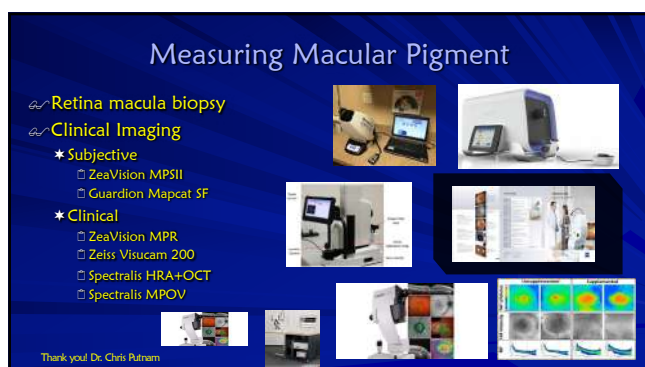
104



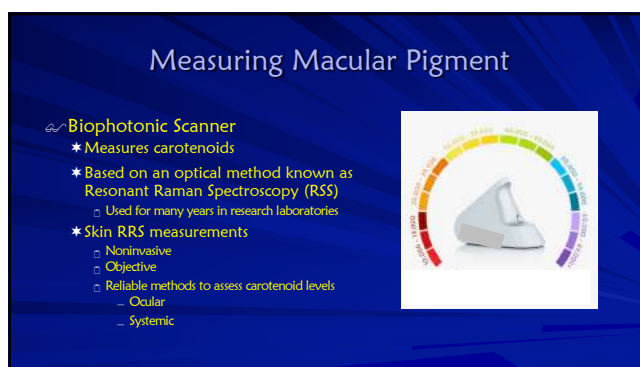
105



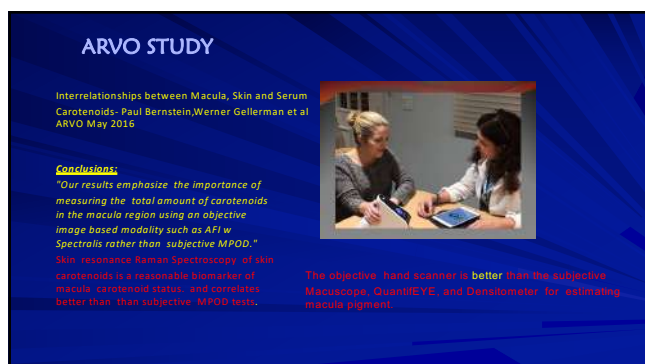
106



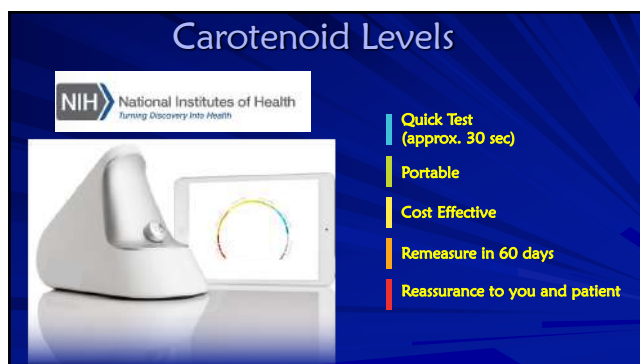
107



108

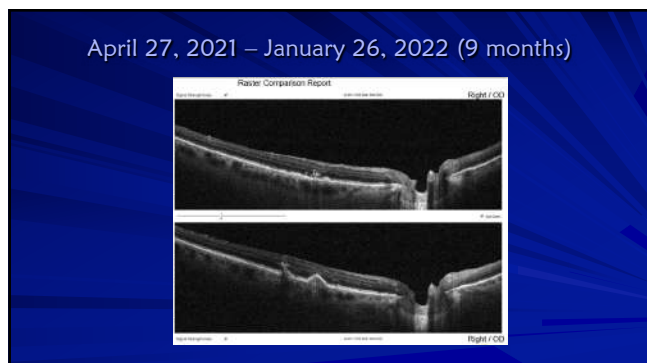

109





110

113114



117

 <p>Optometric Education Consultants</p>	<p>Questions? Thank You!</p> <p>OCT and OCT Angiography Something Old and Something New Retina Pearls</p> <p>Greg Caldwell, OD, FAAO Nashville – Music City Fall Classic 2022 Optometric Education Consultants Saturday, October 22, 2022</p> 
--	---

118