What if?... The Pupil Showed This

- **Andrew G. Lee, MD**
- Professor of Ophthalmology, Neurology and Neurosurgery, Weill Cornell Medical College
- Chair, Department of Ophthalmology, Houston Methodist Hospital, Houston, TX
- Adjunct Professor, University of Iowa Hospitals & Clinics, Iowa City, Iowa, Baylor COM, UTMB, UTMDACC

Weill Cornell Medical College

1

We have no financial disclosures relevant to this presentation

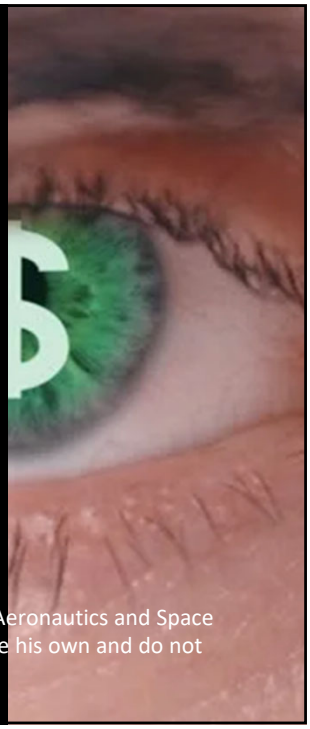

*Dr. Lee works as a consultant for the United States Department of Justice (DOJ), the National Aeronautics and Space Administration (NASA), and the National Football League (NFL) but the views expressed here are his own and do not represent those of these organizations or the United States government.

2

What are we really covering?

- Anatomy
- Neurotransmitters
- Autonomic nervous system

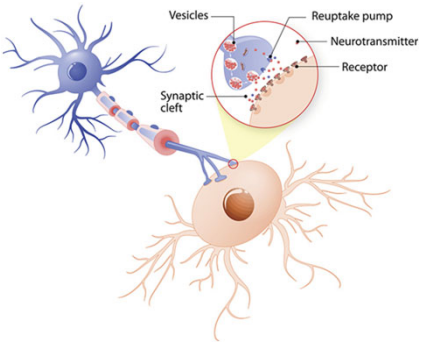

https://qbi.uq.edu.au/files/27919/what-are-neurotransmitters-QBI.jpg

3

Goal:
you should be able to

- Describe the autonomic nervous system (ANS)
  - Sympathetic nervous system (SNS)
  - Parasympathetic nervous system (PNS)

https://www.iblindness.org/wp/wp-content/uploads/2015/08/fight-or-flight.jpg
https://img.buzzfeed.com/buzzfeed-static/static/enhanced/web04/2012/2/1/16/enhanced-buzz-18881-1328131142-75.jpg

4

Goal:
you should be able to

- Give an overview of the pupil pathway
  - Differentiate Afferent from Efferent pathways

http://newlifepathways.net/images/image004.jpg

https://contemplativepathways.files.wordpress.com/2012/08/cornwalls-glendurgan_1280x.jpg

5

Goal: You should be able to

Describe how location and local structures directs your differential diagnosis

List several causes of a "perilous pupil" tailored to the findings and location

6

Perils by location look at local structures

- **VITAMIN**
  - Vascular: aneurysm, malformation
  - Infectious: Syphilis, TB
  - Tumor: anything taking up space
  - Anatomic: variation from the norm
  - Metabolic: Thyroid
  - Inflammatory: Sarcoid
  - Neoplastic: primary or metastatic

7

To understand neural pathways, simplify…

- Stimulus (light) is received by the retina
- Retina transmits message to brain by neurons
  - "Relay station" between neurons is a synapse
- Afferent neurons: eye to brain
- Efferent pathway: brain to end organ
  - Iris sphincter
  - Extra-ocular muscles



8

Afferent, Efferent: 2 different pathways

Afferent disease cau

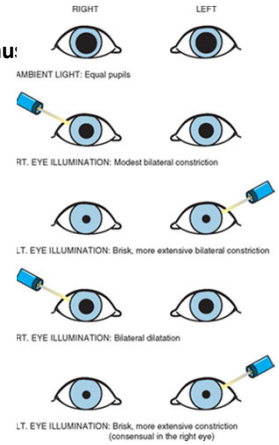

Efferent disease causes anisocoria

http://clinicalgate.com/wp-content/uploads/2015/04/B9780323033541500808_gr13.jpg
https://vcahospitals.com/-/media/vca/images/lifelearn-images/anisocoria-in-cats-1.ashx?la=en&hash=7B633870616962F7E1016251E58B5971

9

If you find afferent and efferent, the patient has TWO lesions

- Repeat your pupil exam



https://d2v9y0dukr6mq2.cloudfront.net/video/thumbnail/bOFlXnz/pupil-reaction-test-with-light_sgilxio4__F0000.png

10

Afferent system = APD

- Remember the Chiasm
- Prechiasmal
  - Ipsilateral
- Post-chiasmal APD
  - Contralateral
  - 53% of fibers cross

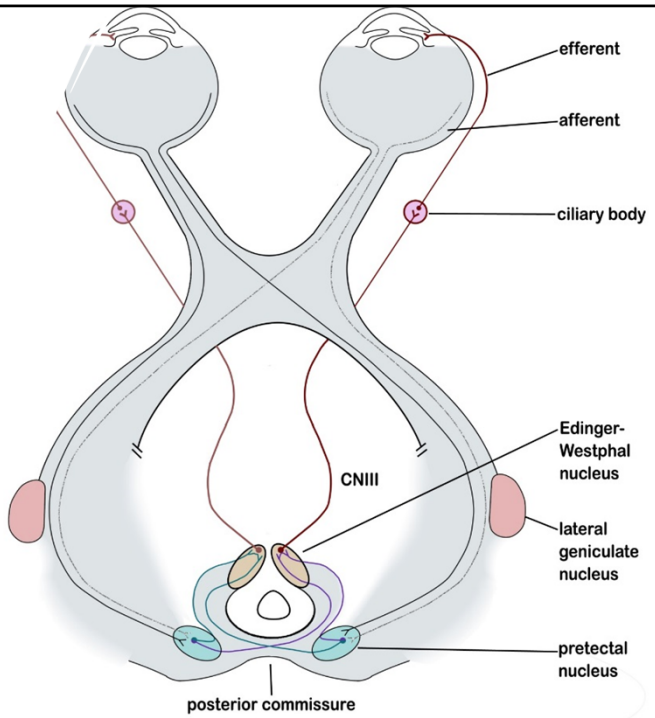

11

Two types of Afferent fibers

- Vision fibers
- Pupil fibers

http://arts.brighton.ac.uk/__data/assets/image/0009/6201/yinyang-1a.jpg

12

Afferents

Vision fibers

Synapse: lateral geniculate nucleus (LGN)

Pupil fibers

Bypass the LGN without synapse

Synapse first in midbrain (pretectal nucleus)

Synapse again bilaterally

- Edinger-Westphal nuclei; CNIII
- Neuron between these synapses: interneuron

http://kidsblogs.nationalgeographic.com/globalbros/images/skipping-stones-at-avalanche-lake.jpg

13

After the interneuron: Efferent fibers

- **Bilateral** post-synaptic fibers return to **both** eyes
  - Same impulse sent to both pupils
    - Explains the equal **direct** and **consensual** response
- Neural impulse causes pupil response

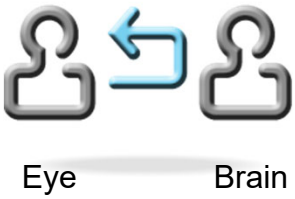

14

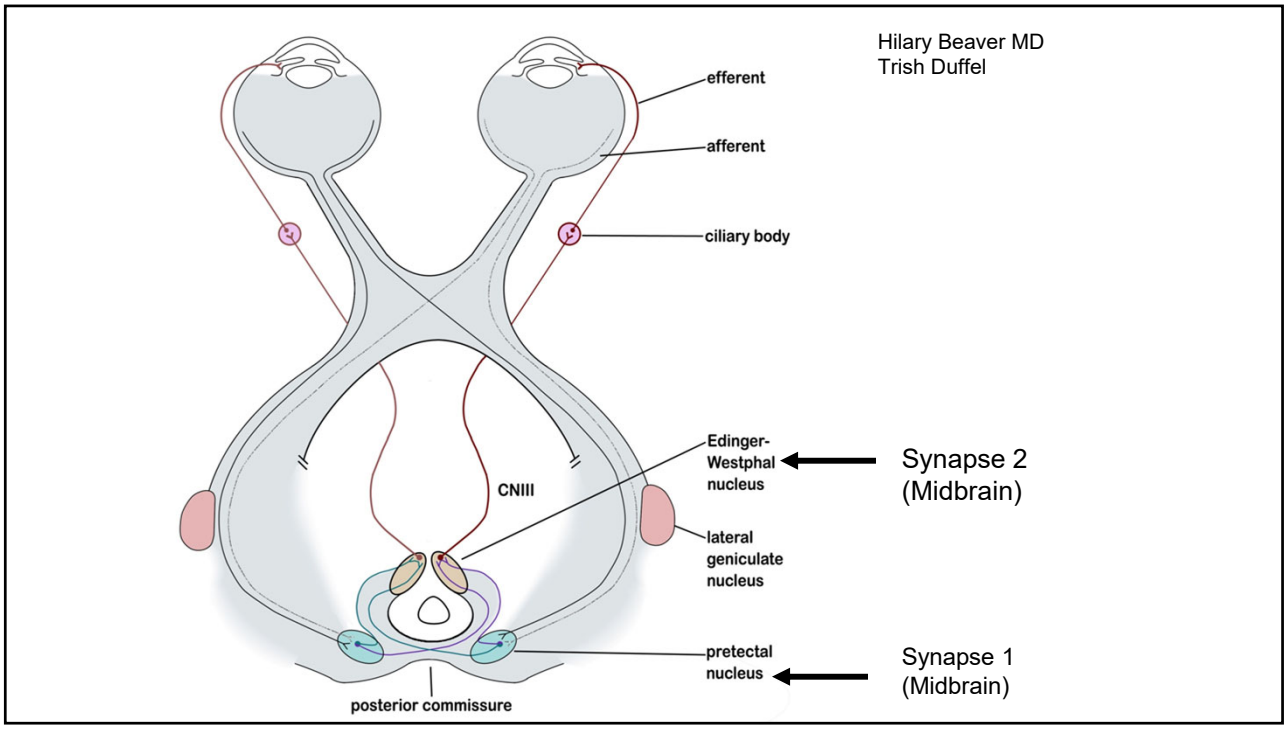

15

Afferent disease: sites for pupil perils

- Interruption of impulse from retina to midbrain
- Damage causes afferent pupillary defect (APD)
  - Large retinal lesion
  - Lesion of optic nerves, optic tracts
  - Lesion of isolated pupil fibers all the way to midbrain
- May retain good vision or have vision loss
- RAPD not covered in PERRLA!
  - You must test for and document relative afferent pupillary defect (RAPD)

16

	5mm	3mm	No	
P<	D(ark)	L(ight)		APD
	5mm	3mm	No	

17

Afferent pupil perils: Lesions of the optic nerve

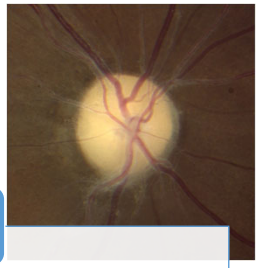

Large retinal lesion

- Macula

Optic nerve disease

- Tumor: Optic nerve glioma or meningioma
- Demyelinating disease
  - Multiple sclerosis
- Ischemia
  - Giant cell arteritis

http://inredchrome.com/wp-content/uploads/2012/04/saltatory.jpg
http://qman-consulting.com/wp-content/uploads/2012/07/PVC-Insulated-Copper-Wire.jpg

18

Pupil perils: nerve compression

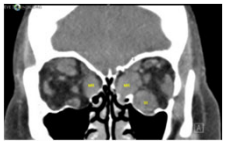

- Orbital disease
  - Graves disease
  - Tumors
- Brain tumors: malignant or benign
  - Meningioma
    - Frontal, olfactory groove, sphenoid ridge
    - Foster-Kennedy Syndrome
  - Pituitary (apoplexy, tumor)

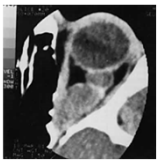

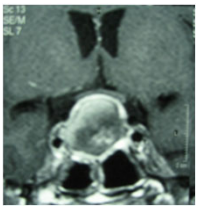

http://webeye.ophth.uiowa.edu/eyeforum/atlas/pages/Thyroid-Eye/fig2-TED-LRG.jpg
http://www.oculist.net/downaton502/prof/ebook/duanes/graphics/figures/v2/0240/010f.jpg

Courtesy of AG Lee, MD

19

Pupil perils: Inflammatory/ infectious involvement to chiasm

- Sarcoidosis

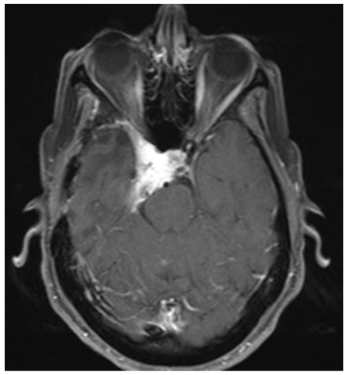

Courtesy of AG Lee, MD

20

The forgotten afferents

- Optic tracts, Midbrain

21

The forgotten afferents

- Optic tracts
  - 53% pupil fibers cross (vs 47% = 6% difference)
  - Unequal crossing = unequal tract innervation
    - 53% Tract lesion causes contralateral APD
  - Post chiasmal lesion
    - If Visual defect, then homonymous hemianopsia

Trac
t

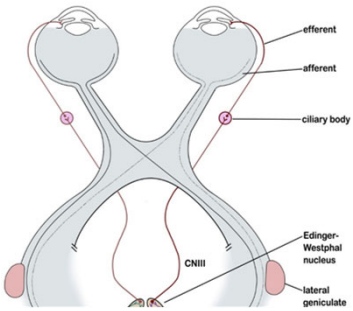

22

The most forgotten pretectal afferents

- Lesion as far back as the midbrain
  - Pupil fibers don't synapse until midbrain
    - Presynaptic damage causes APD
  - Pupil fibers have separated from vision fibers
    - Bypass the LGN
    - Therefore no associated vision loss

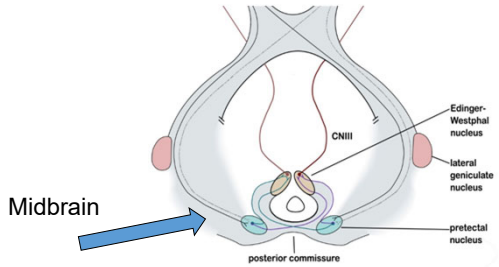

23

Afferent pupillary defect anywhere along afferent pathway

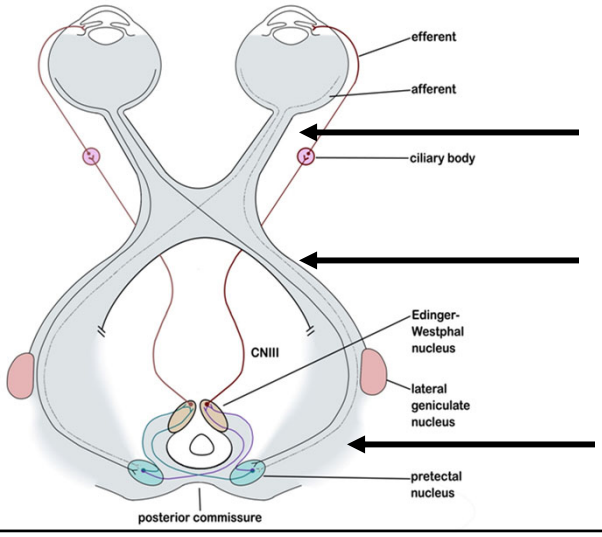

Optic nerve lesion causes ipsilateral APD and vision loss

Optic tract lesion causes contralateral APD and Homonymous hemianopsia

Midbrain lesions cause APD without vision loss

24

Enough with the Afferents

- On to the Efferents!

http://davidlwilliams.org.uk/wp-content/uploads/2011/08/Barn-owl-anisocoria-in-light.jpg

25

Efferent disease

- Iris innervated by Autonomic Nervous System
  - Constrictor muscle
    - Parasympathetic fibers: midbrain to pupil
  - Dilator muscle
    - Sympathetics, covered later
- Present with anisocoria
- Patients have good vision, intact retinas and normal optic nerves (no RAPD)

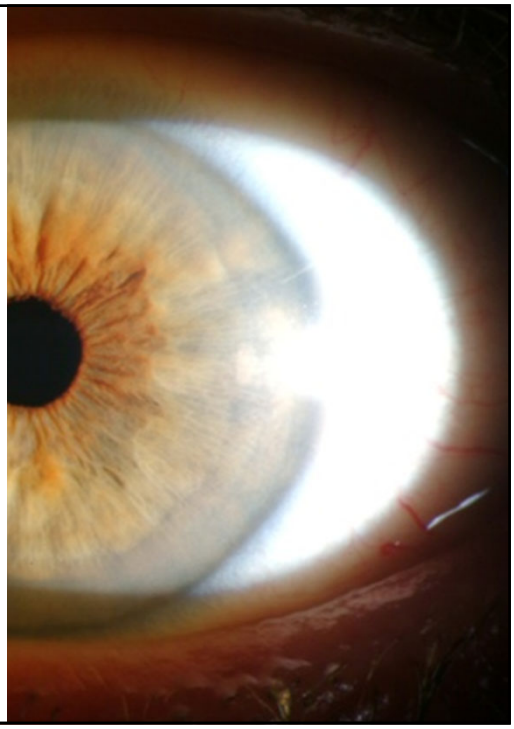

26

Efferent pupillary defect = anisocoria

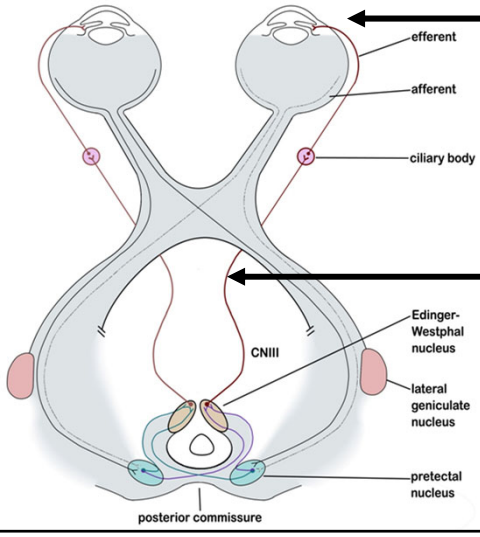

Iris damage: Trauma, HZV, siderosis

Adies tonic pupil

CN III: compression, ischemia

27

Pupil path is autonomic nervous system

Autonomics are automatic

- You don't have to think for them to function
- Autonomic nervous system works while you don't

Components

- Sympathetic nervous system (SNS)
- Parasympathetic nervous system (PNS)

Balance of power within each system

- Activation (stimulation)
- Suppression (inhibition)

28

Components of the ANS

- Sympathetic nervous system
  - Neurotransmitter: epinephrine, norepinephrine
  - Ex.: Fight or flight response
  - Increased heart rate and blood pressure
  - “Wide eyed with fright”- opens pupil and lid
- Parasympathetic nervous system
  - Neurotransmitter: acetylcholine
  - Ex.: Digestion
  - Pupil constriction

29

Neurotransmitter

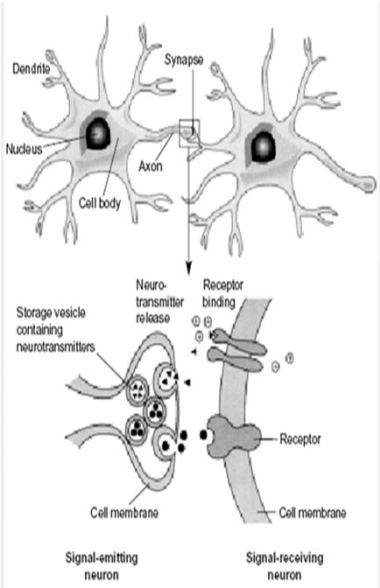

- Chemical released at synapse
- Passes the excitation from one nerve to another nerve or muscle
- Runners passing baton

pubs.niaaa.nih.gov

30

Parasympathetics constrict pupil

- Sphincter muscle
  - Contraction constricts pupil
  - Purse string effect
- PNS defect = dilated pupil

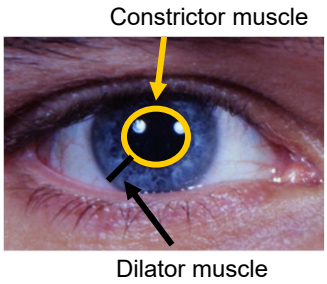

31

Sympathetics dilate pupil

- Dilator muscle- like spokes on wheel
  - Contraction dilates pupil
- SNS defect = small pupil

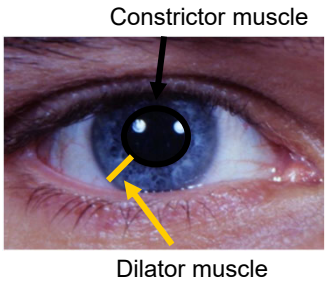

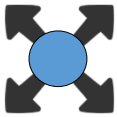

32

Pupil pharmacology

- Drugs act to stimulate or inhibit receptors
- Ex: dilating drops
  - Sympathetic: stimulator
    - Stimulates dilator contraction
    - Neosynephrine 2.5-10%
  - Parasympathetic: inhibitor
    - Paralyze sphincter contraction
    - Tropicamide 0.5-1%, cyclopentolate, atropine, homatropine, scopolamine

33

Applied science: Locate lesion using anisocoria

- Pinpoint which neuron by pharmacologic testing

34

Localize anisocoria by pupil responses: 3 choices

- ***Asymmetry equal in light and dark***
- Asymmetry greater in dark
  - One pupil cannot dilate
- Asymmetry greater in light
  - One pupil cannot contract

35

Asymmetry equal in light and dark

- Physiologic or simple anisocoria
- 20% of normal people
- Benign, variable by day
- Example
  - Dark: 5 mm OD, 4 mm OS
  - Light: 4 mm OD, 3 mm OS

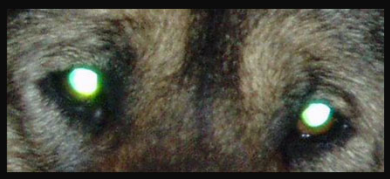

36

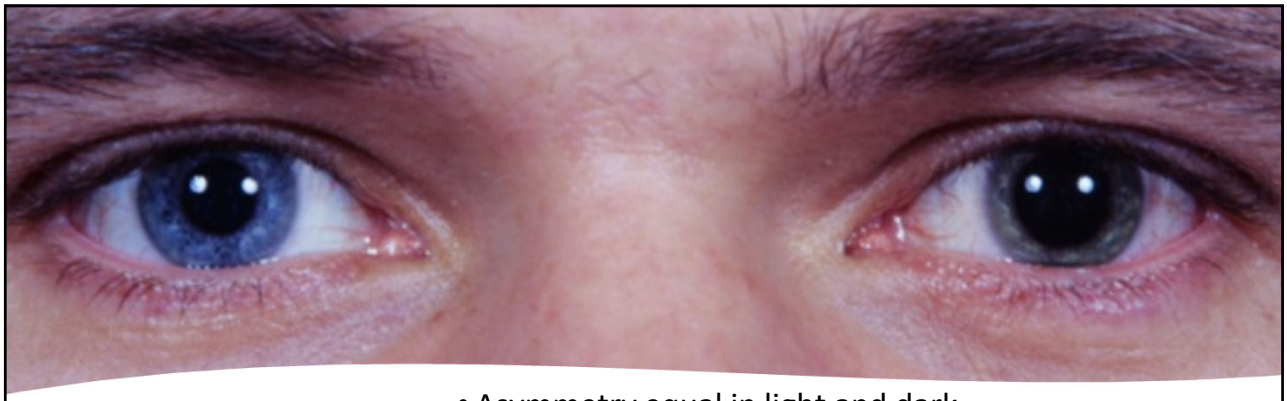

Patient presents with anisocoria: Localize by the pupil responses

- Asymmetry equal in light and dark
  - Physiologic or simple anisocoria
- ***Asymmetry greater in dark***
  - ***Pupil cannot dilate***
- Asymmetry greater in light

37

Asymmetry greater in dark: the little pupil is abnormal

- Pupil cannot dilate
  - Dilator not being stimulated (SNS problem)
  - Most marked immediately after lights out
    - Dilation lag

38

SNS does more then just pupils

- Elevates lid (Mueller's muscle)
- Dilates pupil
- Facial sweating

- Loss of these function = Horner syndrome
  - Ptosis, miosis, anhydrosis

http://4.bp.blogspot.com/-M-gG_XiF814/TzFbBPfYFjI/AAAAAAAAAnc/Axthh-it6N8/s1600/Horners_syndrome.jpg

39

Don't forget upside down ptosis

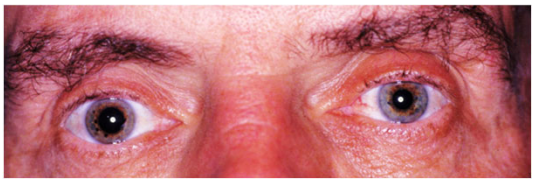

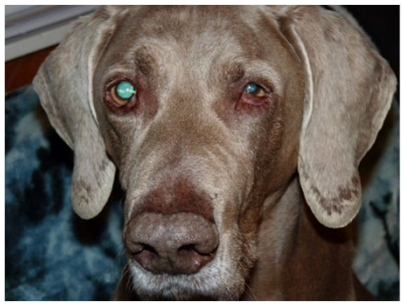

http://4.bp.blogspot.com/-z018HQn3YQI/T-57SodM-2I/AAAAAAAAFRI/iZrlLlHT7qk/s1600/P1190013.JPG

https://o.quizlet.com/i/ZdKCArUaD_mwJ7el0E8vEA_m.jpg

40

41

- First order neuron
  - Hypothalmus, runs down spinal column
  - Synapse in C7-T2 cord
- Second order neuron
  - Leaves spine, ascend outside spine
  - Over lung apex
  - Synapse near jaw
    - Superior cervical ganglion
- Third order neuron
  - Within wall of carotid into skull

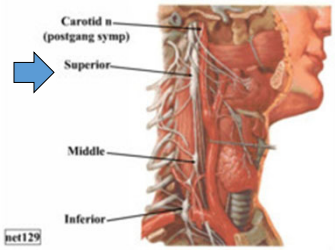

https://o.quizlet.com/F.oiYbWeAxIIlwTgqNUP2g_m.jpg

42

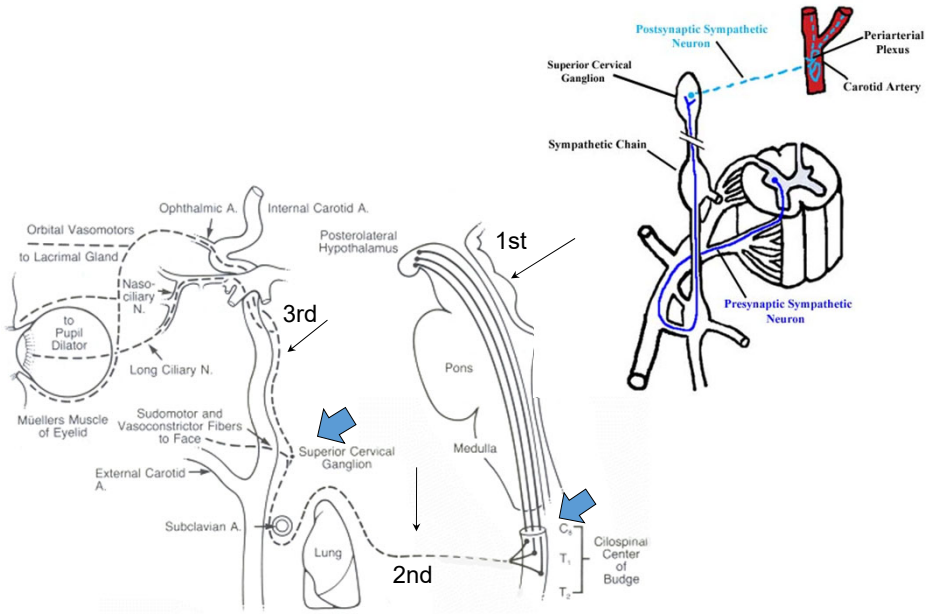

www.ncbi.nlm.nih.gov

http://anatomy.med.umich.edu/modules/intro_autonomics_2_module/Files/symp_head.jpg

43

Sympathetic third order neuron

- External carotid- **sweat glands** of lower face
- Internal carotid- Into skull
  - Cavernous sinus- rides CN VI then CN III
  - In orbit on ciliary nerves
    - **Pupil dilator muscle**
  - On ophthalmic artery branches
    - **Muller's muscle (lid)**
    - **Lower eyelid retractors**
    - **Frontal sweat glands**

44

Horner syndrome

Issue: where is the lesion

1st, 2nd, 3rd order neuron?

Location, location, location

Indicates likely differential diagnosis

45

Traditional (multistep) Horner test Step one

- Do not touch or drop the eye!
  - Makes subsequent testing unreliable
- **Cocaine 10%** (Compounding pharmacy)
  - Prevents synaptic reuptake of norepinephrine
    - Iris dilator muscle
  - Excess norepinephrine floods iris dilator receptors
    - Normal pupil dilates
    - ***If SNS not functioning, no baseline release of norepinephrine so no dilation = Horner syndrome
    - Postcocaine anisocoria > 1mm is Horner

46

Traditional : Step two

- Go home- you've had step one, which makes further same day testing unreliable
- **Hydroxyamphetamine 1%** (Compounding pharmacy)
  - Stimulates intact nerve to release norepinephrine
  - Released norepinephrine stimulates dilator muscle
    - Pupil dilates
  - If pupil dilates, then 3rd order nerve is intact
    - Thus 3rd order not the problem
    - Therefore is a 1st or 2nd order lesion

47

New kid on the block: apraclonidine (Iopidine)

- Iris receptors
  - Alpha 1: dilates
  - Alpha 2: constricts
- Apraclonidine primarily alpha-2 agonist
  - Constricts normal pupils (glare post lasik)
  - Weak alpha-1 activity
- But….Horner syndrome
  - Denervation supersensitivity after 5-7 day

48

Denervation supersensitivity

- Apraclonidine normally alpha-2 agonist
  - Constricts normal pupil
- Horner: denervation supersensitivity (α-1)
  - Small pupil dilates (alpha-1)
  - Ptotic lid elevates (alpha-1)
- Reversal of anisocoria
  - Easy to obtain drop
  - Easy to read result

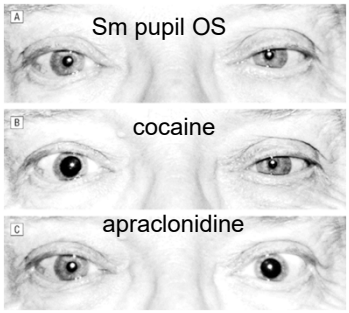

Ocular Effects of Apraclonidine in Horner Syndrome
Jose Morales, MD; Sandra M. Brown, MD; Aziz S. Abdul-Rahim, MD; Craig E. Crosson, PhD
Arch Ophthalmol. 2000;118(7):951-954. doi:10-1001/pubs.Ophthalmol.-ISSN-0003-9950-118-7-ecs90240

49

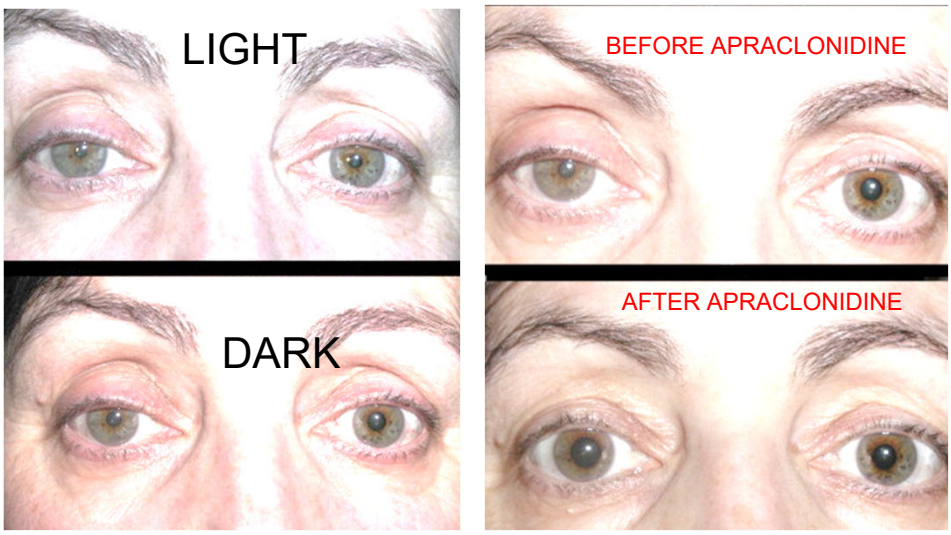

Apraclonidine test (inferior image) confirmed suspected diagnosis of Horner syndrome.*González Martín-Moro et al. Horner Syndrome, a New Complication. J Oral Maxillofac Surg 2009.*

50

SNS summary

- All you can prove pharmacologically
  - It is/not Horner syndrome
  - It is/not last nerve in the sympathetic pathway

51

30 year old WF presents with 4 months of anisocoria

No PMH, no headache, no neck surgery

6 years s/p bike accident "clothslined"

Seen in ER, arm x-ray and exam (–)

2 years later: left arm, dorsal hand pain, arm "cold"

- Saw chiropractor- resolved

Was noted to have anisocoria

52

- Room light (far fixation)
- Light OD
- Dark + 5 seconds
- Dark + 10 seconds
- Dark + 15 seconds

53

1 hour after cocaine 10%

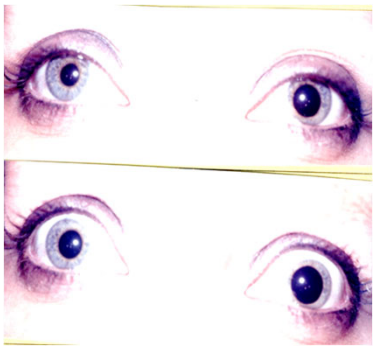

- Room light
- Dark room
- Mild ptosis, miosis, dilation lag, poor response to cocaine = Horner syndrome

54

Hydroxyamphetamine 1%

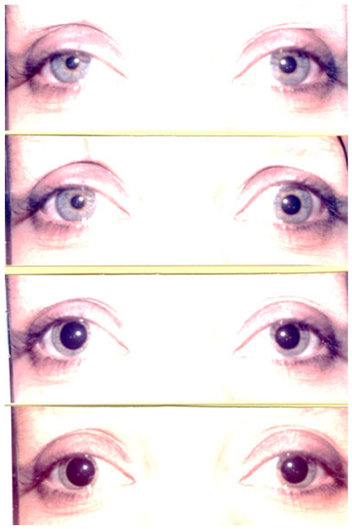

- Room light
- Dark room

(45 minutes after HA1%)

- Room light
- Dark room

- DX: Preganglionic Horner (brachial plexus trauma)

55

How to remember the sympathetics?

- People like stimulation
  - Cocaine and amphetamine thus drugs of abuse
  - Stimulation dilates pupil (wide eyed with fright)
- Cocaine is a stimulant and will dilate pupils
  - Inhibits reuptake of neurotransmitter
  - Sympathetic pathway must be intact
- Amphetamine forces release of neurotransmitter **if** third order neuron is intact

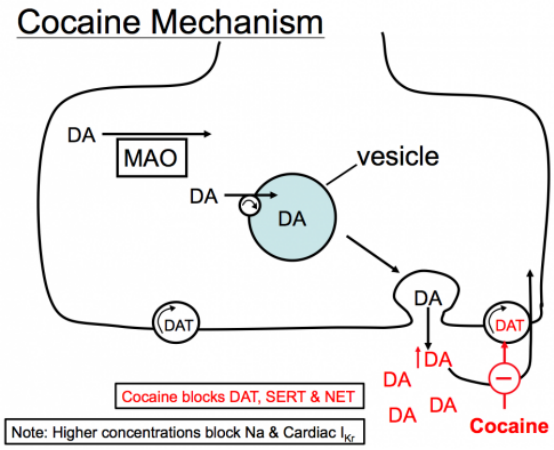

56

Where is the "Peril" ?
3rd order neuron lesion

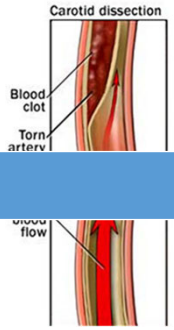

Carotid artery damage

- Dissection (splitting apart)
  - Blood within wall
- Post traumatic
  - Roller coaster, whiplash, chiropractic manipulation
- Stroke risk: Carotid occlusion or clot

Post surgical

- Neck dissection, endarterectomy

Cavernous sinus tumor

http://www.pyroenergen.com/articles13/images/carotid-artery-dissection.jpg

57

Preganglionic "Perils"?

- 2nd order neuron lesion
  - Apical lung cancer (Pancoast tumor)
    - Beware Horner in smokers!
  - Metastasis- Sentinel nodes in neck
  - Chest lesion: aortic aneurysms, brachial plexus syndrome, surgery
- 1st order neuron lesion
  - Brain and spinal cord- stroke, tumor, disc dx
  - Rarely isolated as is tight space

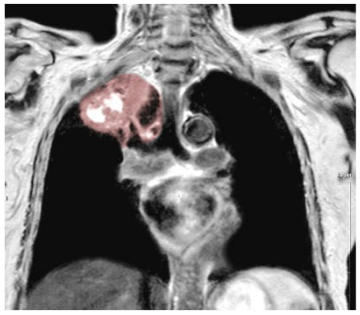

https://moffitt.org/media/4633/bc_pancoast_mr.jpg

58

Infant with Horner syndrome

- Congenital lesion along the sympathetic chain
  - Birth trauma to brachial plexus
  - Associated with iris heterochromia
  - **Neuroblastoma**
    - Malignant but treatable childhood tumor
    - "Baby gram"- MRI scan of the sympathetic chain
    - Chest lesion

http://image.slidesharecdn.com/hornerfonts3-130619193933-phpapp02/95/horner-syndrome-15-638.jpg?cb=1371672820

59

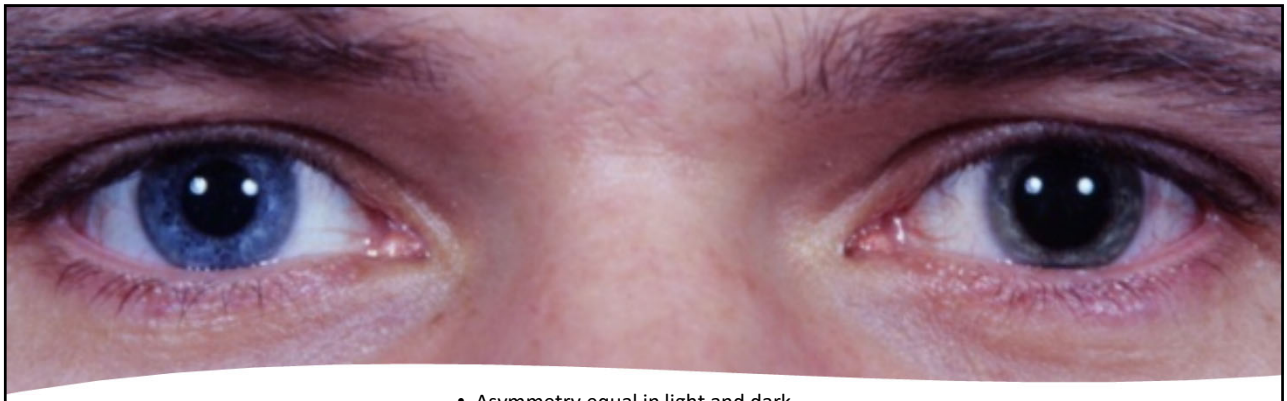

Patient presents with anisocoria: Localize by the pupil responses

- Asymmetry equal in light and dark
  - Physiologic or simple anisocoria
- Asymmetry greater in dark
  - Sympathetic N.S. defect
- ***Asymmetry greater in light***
  - ***Pupil cannot constrict***

60

Anisocoria greater in light; Problem is the dilated pupil

- Pupil can't constrict- big pupil abnormal
  - Sphincter muscle not getting stimulated
    - Nerve defect: parasympathetic pathway
  - Iris muscle damage: slit lamp exam
- Differential diagnosis
  - Pupil involved CN III lesion
  - Adie's tonic pupil
  - Pharmacologic dilation

www.usbg.gov/your-visit/October12007.cfm

61

Parasympathetic pathway

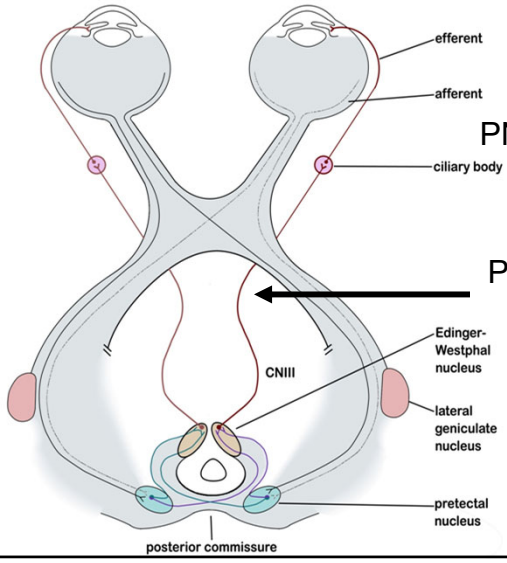

PNS synapse in ciliary ganglion

PNS ride on Cranial Nerve III

Parasympathetic fibers originate in dorsal midbrain
Edinger-Westphal (EW) complex (CN III)

62

PNS lesion: CN III lesion

- Ride on Cranial Nerve III
  - Ride on **top** of third nerve
  - Nerve travels **below** posterior communicating artery
    - Circle of Willis

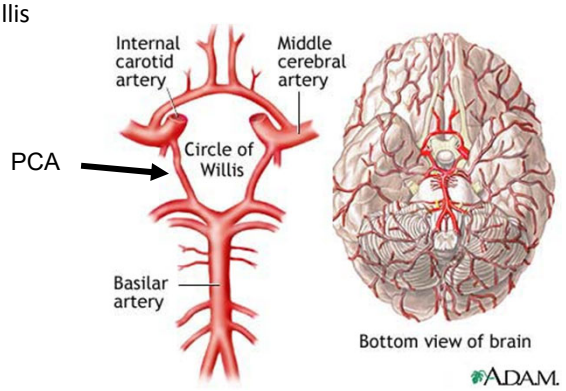

http://www.nlm.nih.gov/medlineplus/ency/imagepages/18009.htm

63

CN III "perils"

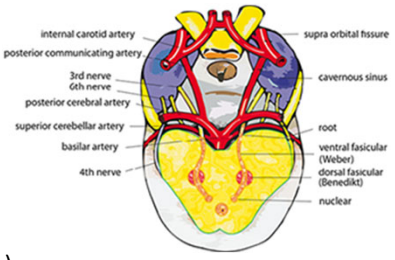

- PNS Ride on top Cranial Nerve III
  - Under posterior communicating artery (PCA)
    - Aneurysm of the PCA compresses the top of CN III and PNS
  - Enter cavernous sinus
    - Tumor, vascular, inflammatory, or infectious disease
  - Enter orbit on inferior division CN III
    - Tumor, inflammatory or infectious disease

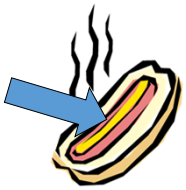

- Synapse in ciliary ganglion in orbit

- Ride on inferior oblique division of CN III
  - Innervates pupil sphincter

http://www.cmej.org.za/index.php/cmej/article/viewFile/2686/2905/15666

64

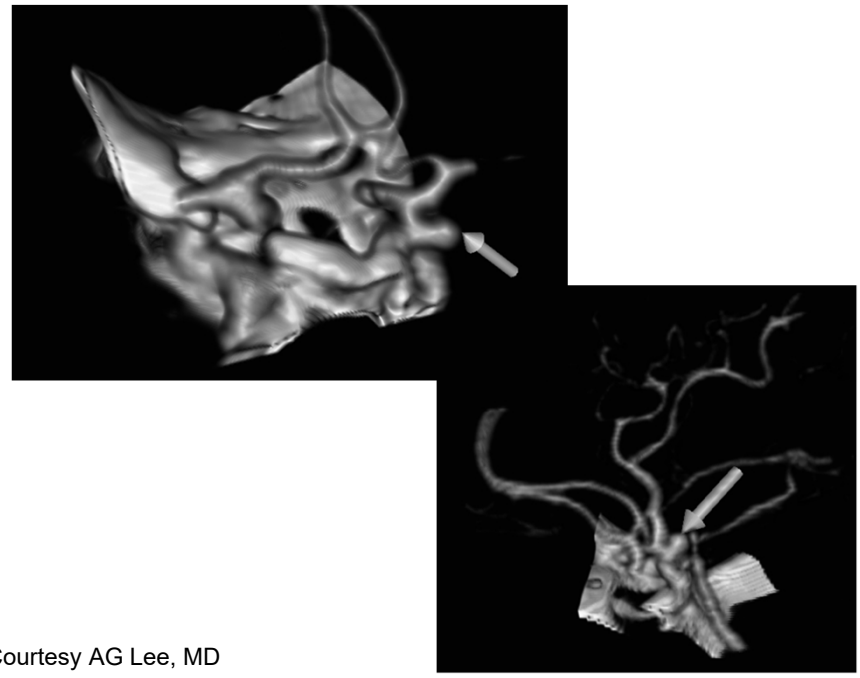

Courtesy AG Lee, MD

65

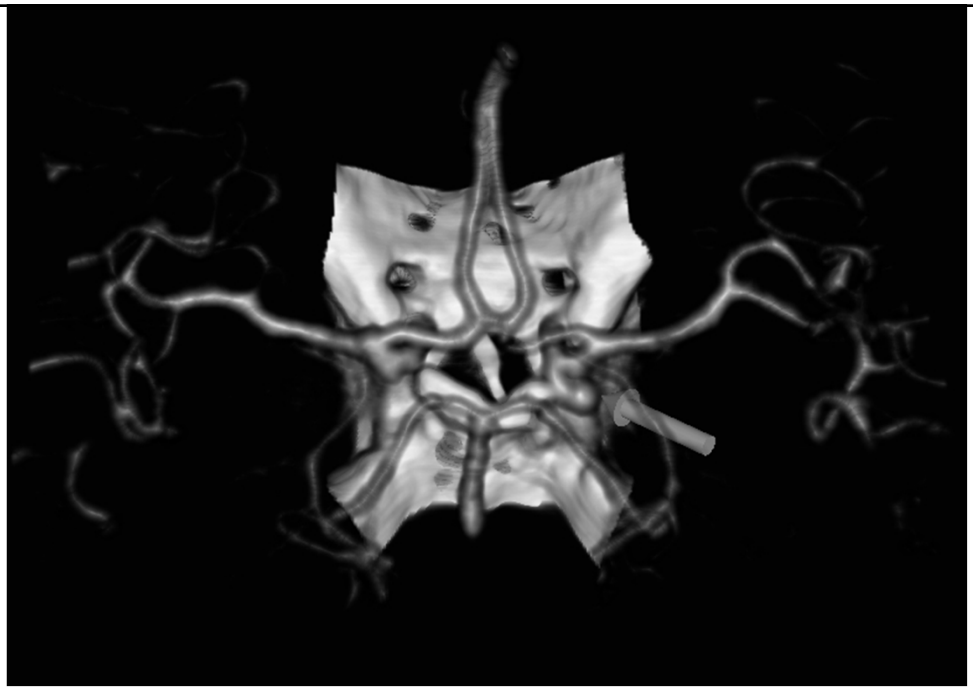

66

Unilateral dilated pupil: Is it a CN III palsy?

- Ptosis: Partial or complete
  - Need to lift the lid for drops?
    - Stop and reassess
- Exotropia: Partial or complete
  - Cannot adduct, elevate, depress
  - Lateral rectus (CN VI) unopposed

https://themilwaukeedrum.files.wordpress.com/2012/07/down-and-out.jpg

67

Motility deficit of CN III palsy

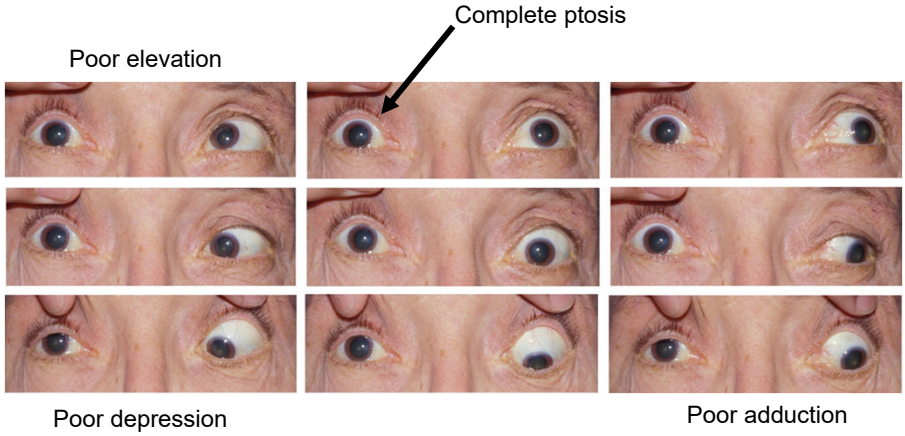

CN III post pharmacological dilation
This patient also has CN VI palsy

68

So what?

- Aneurysm of PCA compresses pupil fibers
- Associated with third nerve findings
  - May be partial CN III, partial pupil
- Pupil is key to diagnosis
  - Alternative diagnosis if pupil sparing, complete CN III (ischemic)
- Expanding PCA aneurysm ruptures
  - 50% mortality
  - 50% severe neurologic damage

69

Your role

- If you need to lift the lid to instill drops, Stop!
- Note pupil findings with abnormal motility
- **The** issue in diagnosing a dilated pupil
  - Is this a pupil involved third nerve palsy???
- Life or death encounter

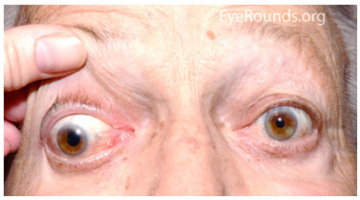

70

Pupil involved CN III

- MRI/CTA- emergent
- Arteriogram
  - 1% risk of morbidity and mortality
- Neuroradiology/neurosurgery consult
  - Coiling/clipping of aneurysm

Courtesy of AG Lee, MD

71

Relax: more benign causes of pupil dilation

- **Adie's tonic pupil**
  - **Ciliary body**
- Pharmacologic dilation
- Iris muscle damage

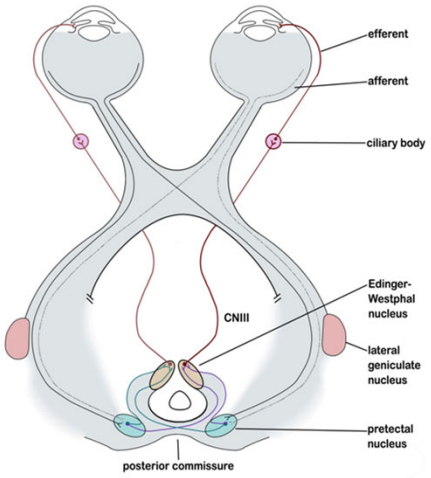

72

Adie's tonic pupil

- PNS lesion at the ciliary ganglion
  - Post viral, young female predominance
  - 4% bilateral
- Segmental iris de-innervation
  - Parts of sphincter contract, iris writhes
  - Vermiform movements
- Light-near dissociation
- Iris supersensitivity to neurotransmitter
  - Acetylcholine receptors

73

Look for vermiform movements

- Infared pupilometry: segmental transillumination defects of the pupil sphincter

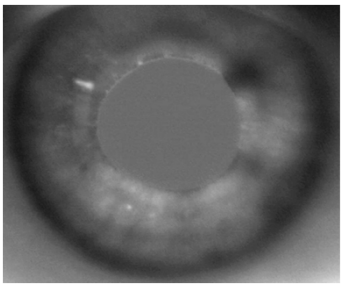

Pilocarpine 0.1%

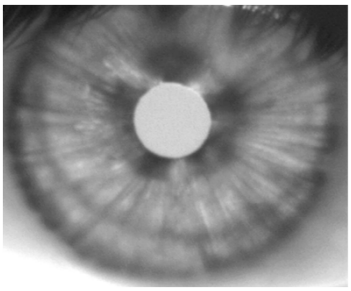

Courtesy of AG Lee, MD

74

Is the pupil supersensitive

- Has this been there a long time?
- Pilocarpine 1/8% (1/10%)
  - Normal pupil won't react
  - Adie's pupil will constrict

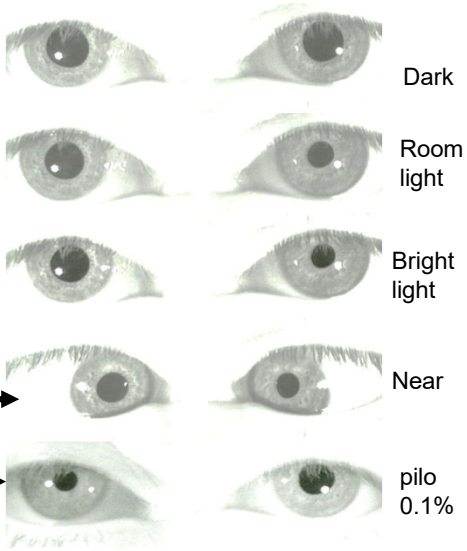

Near response greater then light

Supersensitivity to dilute pilocarpine

Courtesy of AG Lee, MD

75

Other causes: Isolated dilated pupil

- Pharmacologic
  - Inadvertent contamination
    - Scopolamine patch
    - Naturally occurring alkaloids
      - Jimson weed
      - Angels trumpet
    - Contralateral alpha agonist for glaucoma (Alphagan, Iopidine)
  - Intentional dilation
    - Non-organic disease

76

Is the pupil pharmacologically dilated (had no response to pilo 1/8%)

- Pilocarpine 1%
  - Normal pupil constricts
  - Pharmacologically dilated pupil will not
- Clue:extreme dilation, suspect pharmacologic

77

Iris causes

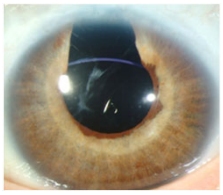

- Trauma
  - Sphincter rupture- pupil irregular
  - Acute post-traumatic mydriasis
  - Surgical: retinal laser, post cataract surgery
- Inflammation
  - Posterior synechiae
  - Iris atrophy
    - Herpetic eye disease
      - Simplex
      - Zoster

Traumatic mydriasis OS

78

Afferent summary

- Afferent disease: APD
  - Impulse blocked from retina to midbrain
  - May have vision loss
    - Ipsilateral loss: large retinal lesion, optic nerve
    - Homonymous hemianopsia: optic tracts- LGN
  - May have good vision
    - Even with lesions listed above
    - Lesions posterior to LGN
  - Not covered in PERRLA!
    - Must test for afferent pupillary defect (APD)

79

Efferent summary: anisocoria

- Physiologic anisocoria
  - Pupil asymmetry equal in light and dark
- Sympathetic lesion (Horner syndrome)
  - Asymmetry greater in dark
  - Anisocoria > 1 mm after cocaine 10%
  - 3rd order neuron (postganglionic) damage
    - No dilation with hydroxyamphetamine 1%
  - Beware with trauma, vasculopathic, or smokers
  - Congenital- evaluate for neuroblastoma

80

Parasympathetic summary

- Ptosis: Stop!
  - No drops or tonometry
  - If you must lift lid- reassess
- Third nerve palsy
  - Look carefully for partial palsy
  - Dilating aneurysms are at risk for rupture

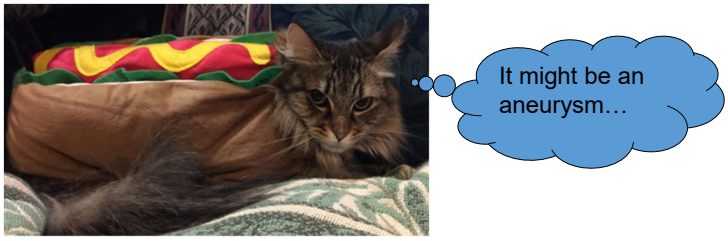

81

Parasympathetics, continued

- Adie's tonic pupil
  - Young women, post viral
  - Vermiform movements
  - 1/8 % pilocarpine supersensitivity
- Parasympathetic mimics
  - Pupil damage: trauma, surgery, inflammation
  - Pharmacologic (prove with pilocarpine 1%)
    - Accidental
    - Intentional

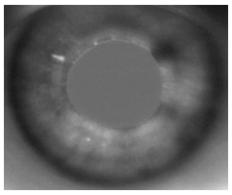

82

Overview: Pupil cases

Some things you don't know about things you know well: RAPD (afferent pathway) and Anisocoria (efferent pathway)

Relative afferent pupillary defect and light near dissociation of pupils

Anisocoria

- Small pupil
- Big pupil

Third nerve palsy, Horner syndrome, Adie tonic pupil, pharmacologic dilation

83

Relative afferent pupillary defect (RAPD) OD: Which side is the lesion?

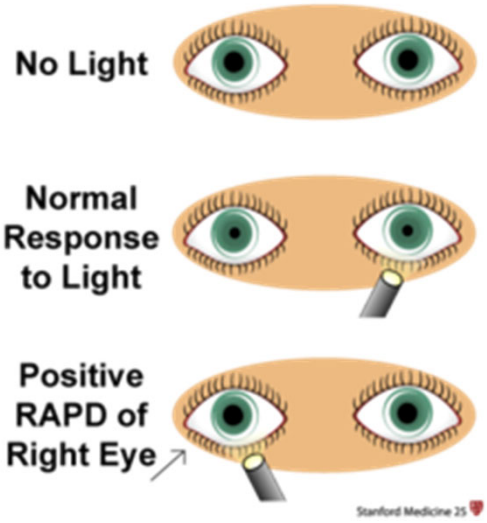

84

Relative afferent pupillary defect (RAPD) OD: Which pupil dilates with an RAPD OD?

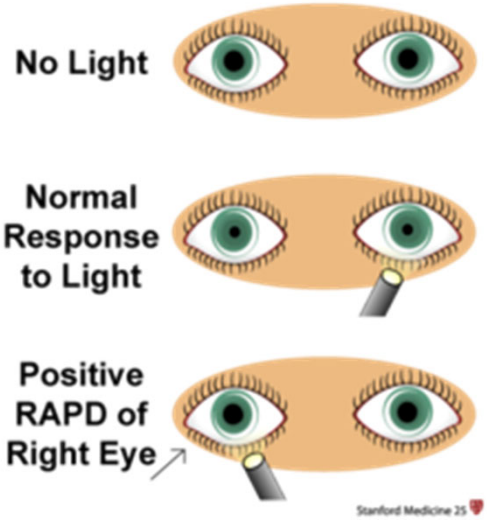

85

How do we check RAPD in an ipsilateral pupil involved third nerve palsy?

https://www.atlasophthalmology.net/photo.jsf?node=5830&locale=en

86

Panel questions

- What would you ask?
- What would you do on exam?
- What tests or imaging would you do and when?
- Should you admit to hospital?
- What would make you admit?
- What is the treatment and prognosis?

87

Both pupils

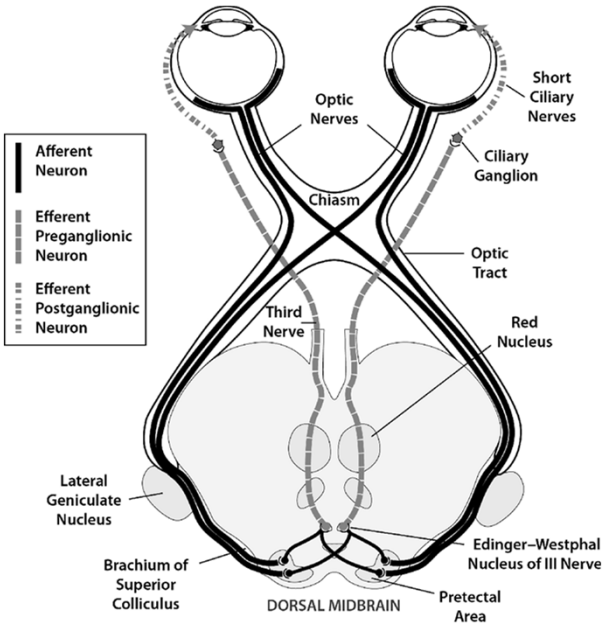

https://www.cambridge.org/core/books/abs/neurologic-differential-diagnosis/pupil-dilation/ED4F21F059F6CB01FEF4645A5EBD470B

88

Bilateral light near dissociation

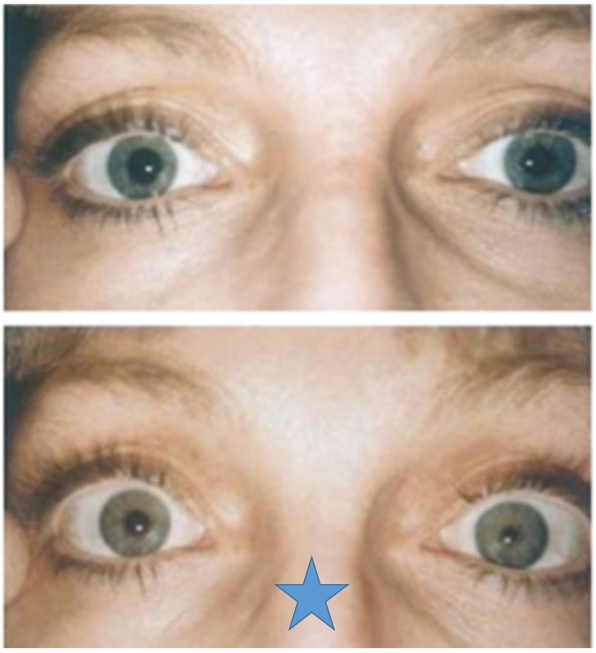

89

Panel questions

- What would you ask?
- What would you do on exam?
- What tests or imaging would you do and when?
- Should you admit to hospital?
- What would make you admit?
- What is the treatment and prognosis?

90

Bilateral light near dissociation

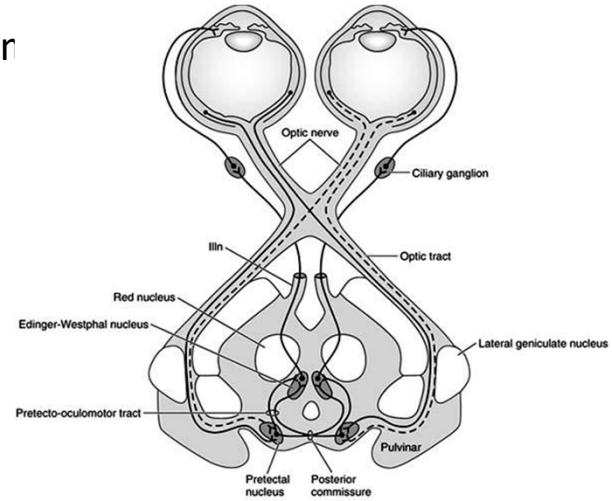

https://www.cambridge.org/core/books/abs/neurologic-differential-diagnosis/pupil-dilation/ED4F21E059F6CB01FEF4645A5EBD470B

91

“PERRLA” ≠ NORMAL

92

Panel questions

- What would you ask?
- What would you do on exam?
- What tests or imaging would you do and when?
- Should you admit to hospital?
- What would make you admit?
- What is the treatment and prognosis?

93

Apraclonidine test (inferior image) confirmed suspected diagnosis of Horner syndrome.*González Martín-Moro et al. Horner Syndrome, a New Complication. J Oral Maxillofac Surg 2009.*

94

Oculosympathetic (Horner pathway)

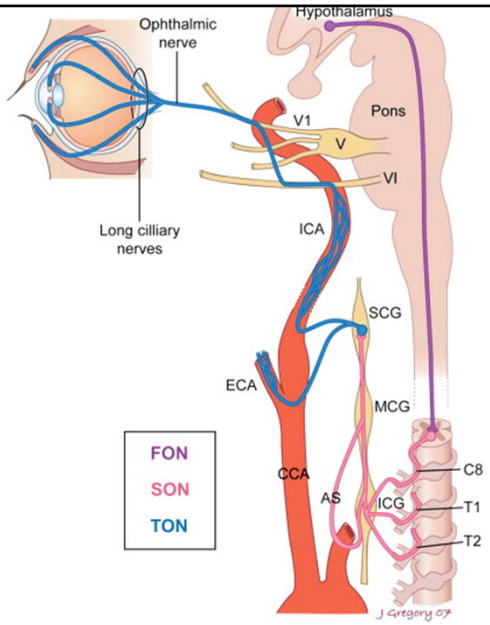

https://radiologykey.com/horners-syndrome-clinical-and-radiographic-evaluation/

95

The JAMA Network

Sent for levator dehiscence OS

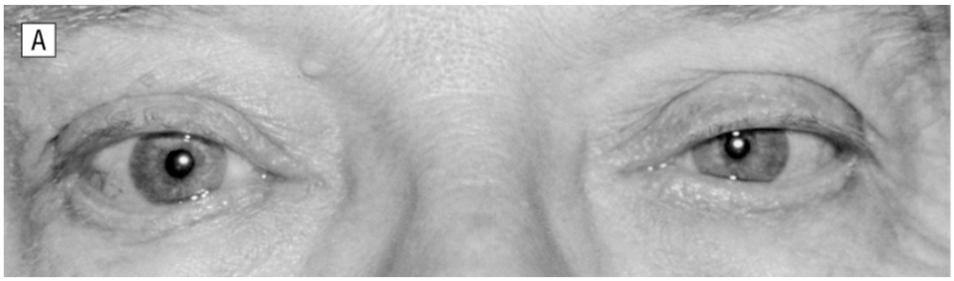

96

The JAMA Network

From: Rfxcu#Hihfw#:#Dsuiforqlqh#q#Kruqhu#Wqgurph

Arch Ophthalmol. 2000;118(7):951-954. doi:10-1001/pubs.Ophthalmol.-ISSN-0003-9950-118-7-ecs90240

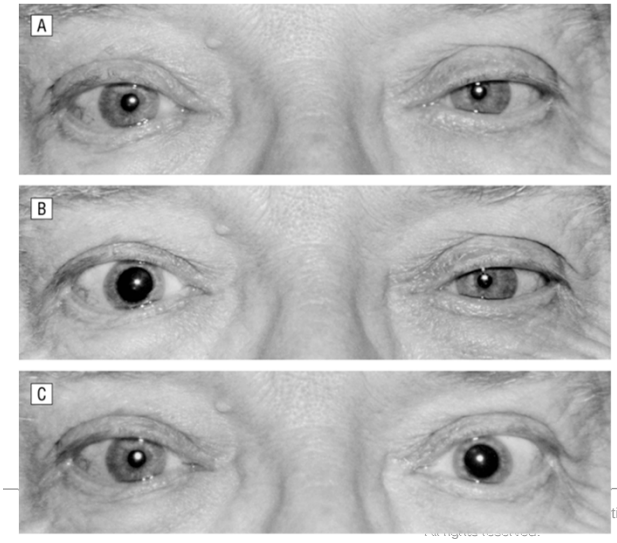

A. Baseline

A. Cocaine

C. Apraclonidine

97

Bilateral small to pinpoint without tonic near OU

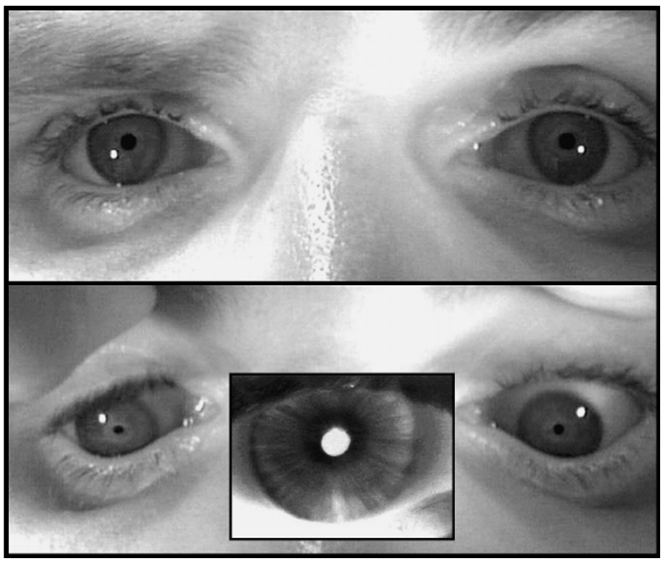

98

Panel questions

- What would you ask?
- What would you do on exam?
- What tests or imaging would you do and when?
- Should you admit to hospital?
- What would make you admit?
- What is the treatment and prognosis?

99

Pilocarpine 1/10% and pilocarpine 1% do not constrict pupil

http://mmcneuro.wordpress.com/2013/02/

100

Panel questions

- What would you ask?
- What would you do on exam?
- What tests or imaging would you do and when?
- Should you admit to hospital?
- What would make you admit?
- What is the treatment and prognosis?

101

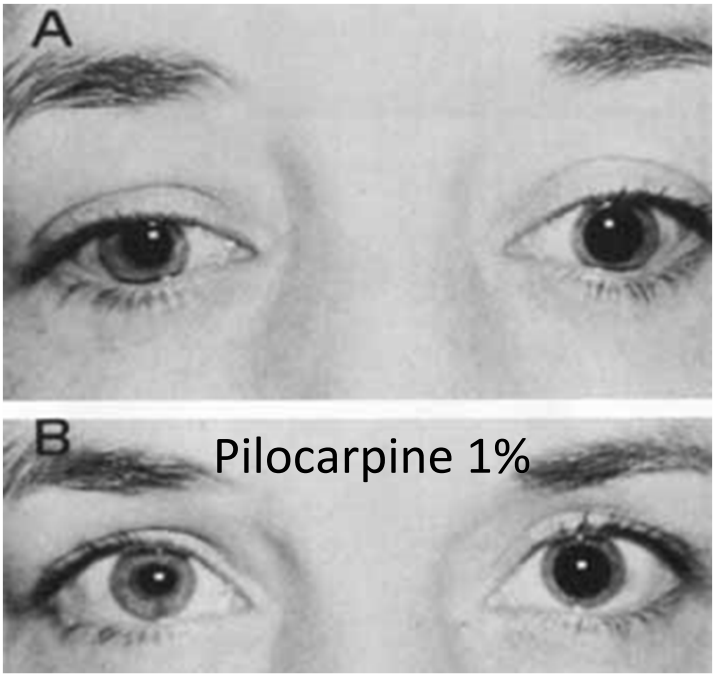

102

What if….

103

Panel questions

- What would you ask?
- What would you do on exam?
- What tests or imaging would you do and when?
- Should you admit to hospital?
- What would make you admit?
- What is the treatment and prognosis?

104

What if….

105

Panel questions

- What would you ask?
- What would you do on exam?
- What tests or imaging would you do and when?
- Should you admit to hospital?
- What would make you admit?
- What is the treatment and prognosis?

106

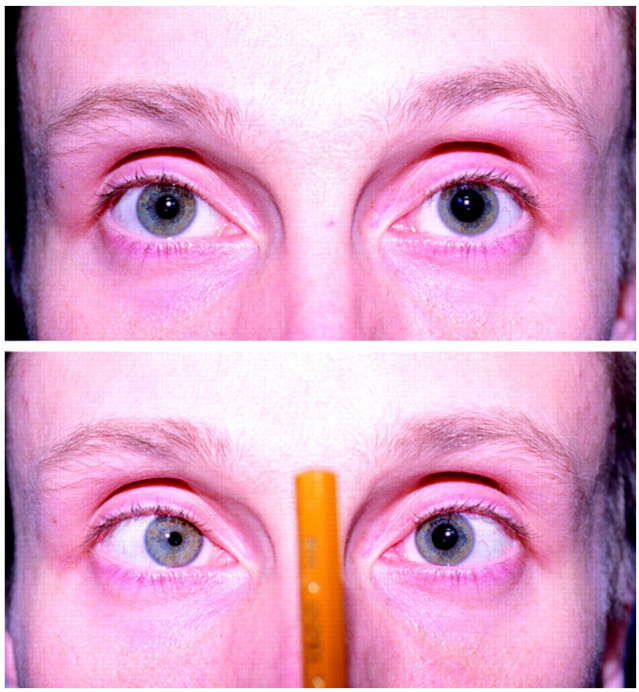

107

Panel questions

- What would you ask?
- What would you do on exam?
- What tests or imaging would you do and when?
- Should you admit to hospital?
- What would make you admit?
- What is the treatment and prognosis?

108

What if….

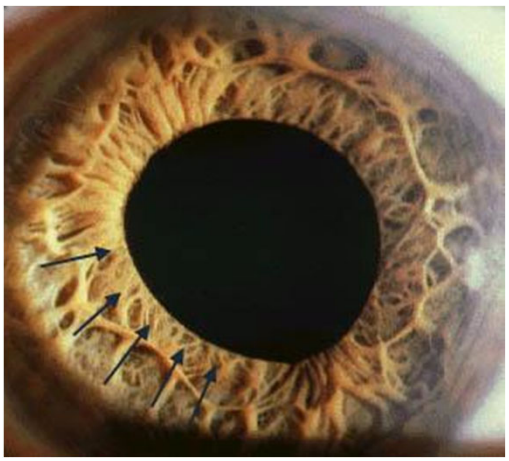

109

Panel questions

- What would you ask?
- What would you do on exam?
- What tests or imaging would you do and when?
- Should you admit to hospital?
- What would make you admit?
- What is the treatment and prognosis?

110

What if….



111

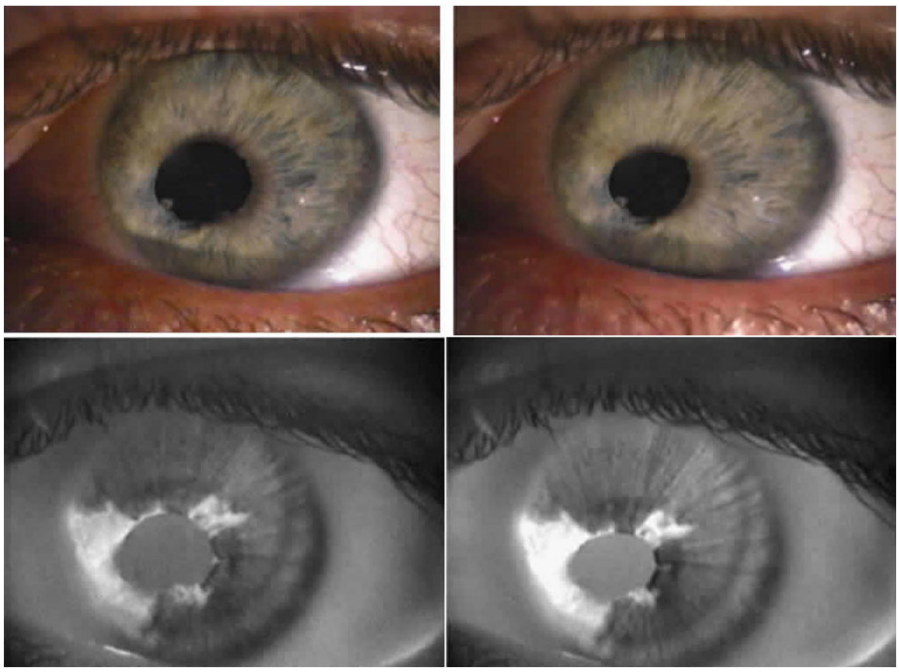

112

Panel questions

- What would you ask?
- What would you do on exam?
- What tests or imaging would you do and when?
- Should you admit to hospital?
- What would make you admit?
- What is the treatment and prognosis?

113

What if…

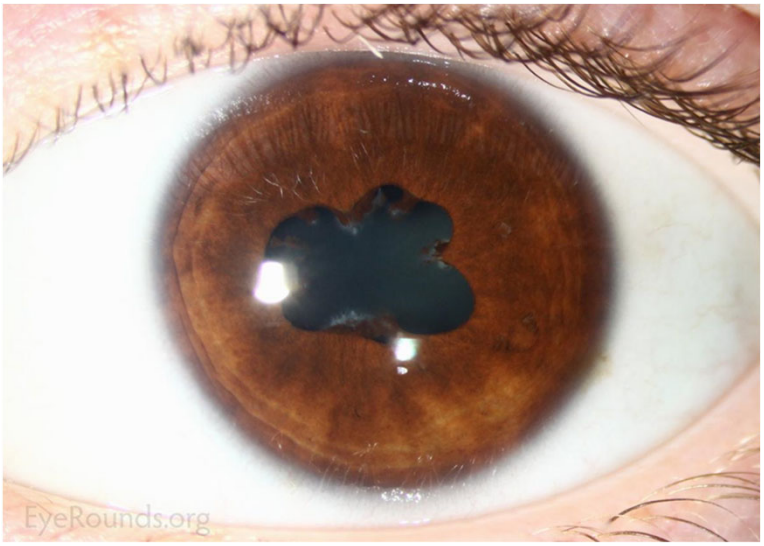

114

Panel questions

- What would you ask?
- What would you do on exam?
- What tests or imaging would you do and when?
- Should you admit to hospital?
- What would make you admit?
- What is the treatment and prognosis?

115

Different days

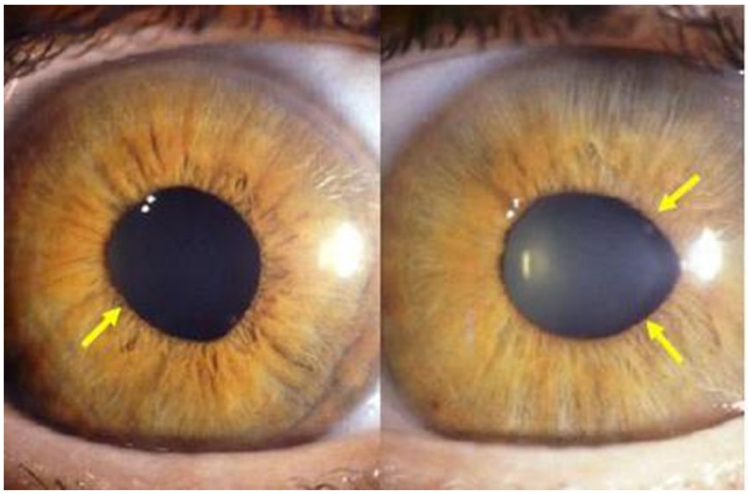

116

Panel questions

- What would you ask?
- What would you do on exam?
- What tests or imaging would you do and when?
- Should you admit to hospital?
- What would make you admit?
- What is the treatment and prognosis?

117

What if….

118

What if it was non-traumatic and there was a family history of scalloped pupil and amyloid?

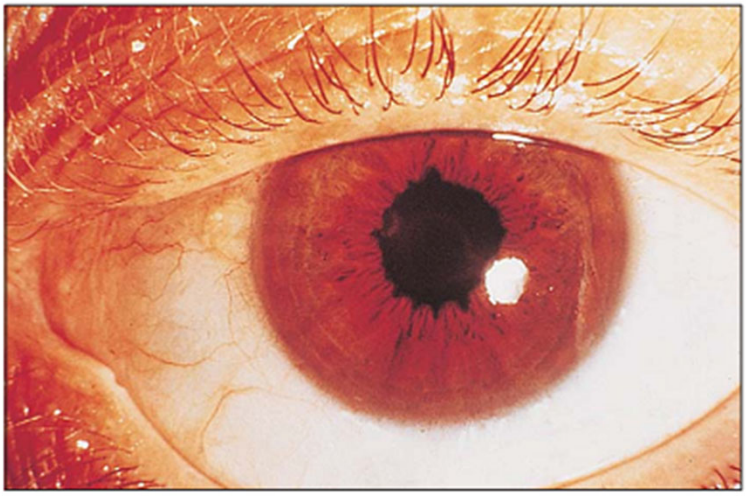

119

Panel questions

- What would you ask?
- What would you do on exam?
- What tests or imaging would you do and when?
- Should you admit to hospital?
- What would make you admit?
- What is the treatment and prognosis?

120

Summary: Pupil cases with Prem and Andy

Some things you don't know about things you know well: RAPD (afferent pathway) and Anisocoria (efferent pathway)

Relative afferent pupillary defect and light near dissociation of pupils

Anisocoria

- Small pupil
- Big pupil

Third nerve palsy, Horner syndrome, Adie tonic pupil, pharmacologic dilation

121

Summary: Pupil cases

Some things you don't know about things you know well: RAPD (afferent pathway) and Anisocoria (efferent pathway)

Relative afferent pupillary defect and light near dissociation of pupils

Anisocoria

- Small pupil
- Big pupil

Third nerve palsy, Horner syndrome, Adie tonic pupil, pharmacologic dilation

122

Thanks for your time & attention

Weill Cornell Medical College

123