

Optometric
Education
Consultants

Carotenoid Levels in Ocular Disease and Systemic Health

Greg Caldwell, OD, FAAO

Mackinac Island
Optometric Education Consultants
Saturday, August 27, 2022



Disclosures- Greg Caldwell, OD, FAAO

All relevant relationships have been mitigated

- The content of this activity was prepared independently by me - Dr. Caldwell
- Lectured for: Alcon, Allergan, Aerie, BioTissue, Kala, Maculogix, Optovue, RVL, Heru
 - Disclosure: Receive speaker honorariums
- Advisory Board: Allergan, Sun, Alcon, Maculogix, Dompe, Visus, Eyenovia
 - Disclosure: Receive participant honorariums
- I have no direct financial or proprietary interest in any companies, products or services mentioned in this presentation
 - Disclosure: Non-salaried financial affiliation with Pharmanex
- Involve: PA Medical Director, Credential Committee
- Healthcare Registries – Chairman of Advisory Council for Diabetes
- The content and format of this course is presented without commercial bias and does not claim superiority of any commercial product or service
- Optometric Education Consultants – Scottsdale, AZ, Orlando, FL, Mackinac Island, MI, Nashville, TN, and Quebec City, Canada - Owner



Thank You for This Opportunity



Agenda

Thanks for the Opportunity

- 🕒 My ocular disease focus to prevention
- 🕒 Ocular diseases from oxidative stress
- 🕒 Evidence based medicine proves antioxidant intervention
- 🕒 Measuring carotenoids
- 🕒 Phospholipid bilayer membrane – damage and protection
- 🕒 Partial versus total supplementation
 - ★ Inner and outer retina
 - ★ Ocular supplements or full body

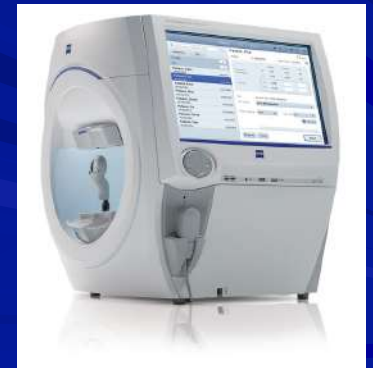Ocular Disease Career

- 👁️ OCT - Spectral domain
- 👁️ OCT Angiography
- 👁️ Visual Fields
- 👁️ AMD, glaucoma, retinal degenerations, diabetic retinopathy
- 👁️ Dark Adaptation

- 👁️ Focusing on structure and function loss or damage

- 👁️ Patients asking what about supplements
 - ★ Reading about it on internet
- 👁️ Promised I would do my due diligence

- 👁️ Ocular disease optometrist to an Integrative Optometrist



Patients Are Expecting

🔗 Early detection

🔗 Wellness

🔗 Prevention

Question?

👁 Who in here would consider themselves as an integrative optometrist?

👁 Who has done or recommended?

- ★ Supplements, vitamins, AREDS2
- ★ Omegas, EPA, DHA
- ★ Vital tears – ASED
- ★ Regener-Eyes
- ★ Amniotic membranes
- ★ CBD
- ★ Probiotics

Allopathic vs Integrative Medicine

- ☞ “Allopathic medicine” is a term used for modern or mainstream medicine
 - ★ Conventional medicine, mainstream medicine, Western medicine, biomedicine
 - ★ Treating conditions and symptoms with its “opposite”
 - ★ Health system in which medical doctors, nurses, pharmacists, and other healthcare professionals are licensed to practice and treat symptoms and diseases
 - ★ Using medication, surgery, radiation, therapies, and procedures
- ☞ Complementary and integrative medicine are commonly used along with mainstream medicine
 - ★ Homeopathy, naturopathy, chiropractic care, Chinese medicine
- ☞ Allopathic or modern medical schools have recently added more study and information on how food and nutrition can help prevent and treat disease
 - ★ More education is being offered on integrative approaches and potential interactions with mainstream medicine

Medical Practices

👓 Allopathic medicine

- ★ Western medicine

👓 Alternative “homeopathic”

👓 Functional

- ★ Medicine of why, treat the cause

👓 Integrative medicine

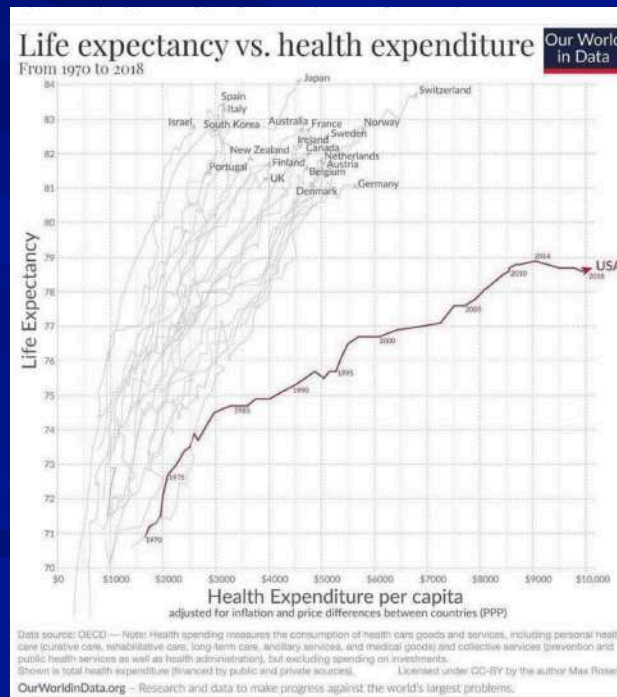
- ★ Complementary medicine - Eastern complimenting Western

What is integrative medicine?

The practice of integrative medicine refers to the **blending of conventional and evidence-based natural and complementary medicines and/or therapies with lifestyle interventions** to deliver holistic, patient-centred care.

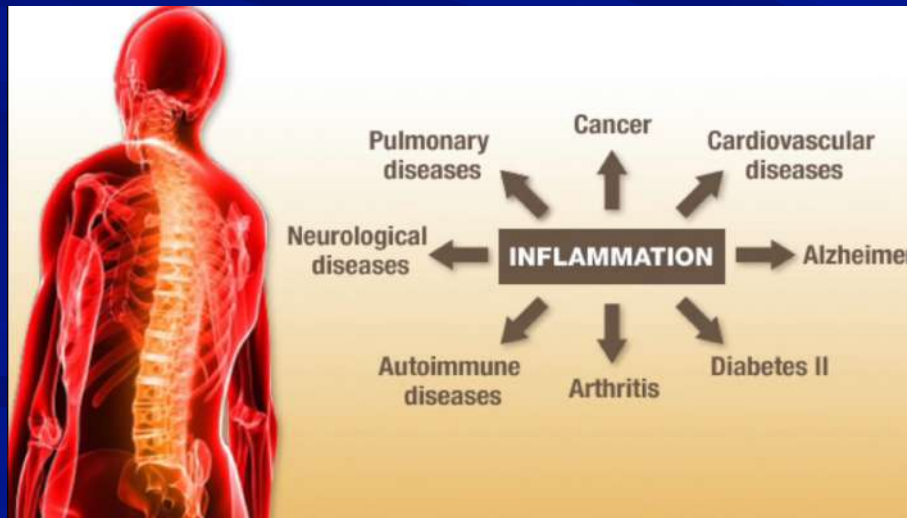
Chronic and Low-Grade Inflammation

Science has proven that chronic, low-grade inflammation can turn into a silent killer that contributes to cardiovascular disease, cancer, type 2 diabetes, diabetic retinopathy, cataracts, macular degeneration, and many other conditions



Chronic and Low-Grade Inflammation

Like cancers and other slow-burn diseases, identifying these conditions early can make the difference between full recovery or a dramatically reduced quality of life or even death (vision loss or blindness)



“Choose Your Parents Wisely”

👓 This just isn't as true as it's used to be

👓 Lifetime health

- ★ 8% genetics “Picking your parents wisely”

- 📋 DNA in our nucleus

- Can't be influenced

- ★ 92% epigenetics

- 📋 Lifestyle choices = we can influence

- 📋 Turn on/off gene expression

Biomarker

- ✍ Test that has meaning
- ✍ Biological molecule found in blood, other body fluids, or tissues that is a sign of a normal or abnormal process, or of a condition or disease.
- ✍ A biomarker may be used to see how well the body responds to a treatment for a disease or condition
- ✍ Blood pressure, blood work, heart rate, genetic testing, IOP

Predictive Biomarker

- Used to identify individuals who are more likely to respond to exposure to a particular medical product or environmental agent
- The response could be a symptomatic benefit, improved survival, or an adverse effect
- A value that we can guide therapy around
 - ★ HbA1c
 - ★ C-Reactive Protein
 - ★ Plasma Homocysteine
 - ★ Vitamin D (25-HydroxyD)
 - ★ Omega 3 index
 - ★ Carotenoid

Measure?



Annual Review of Nutrition
Ocular Carotenoid Status in Health and Disease

Lydia Sauer, Binxing Li, and Paul S. Bernstein
Department of Ophthalmology and Visual Sciences, John A. Moran Eye Center, University of Utah, Salt Lake City, Utah 84152, USA; email: lydia.sauer@hsc.utah.edu, Binxing.Li@hsc.utah.edu, paul.bernstein@hsc.utah.edu

Click on Tools to go to PDF

ANNUAL REVIEWS CONNECT

www.annualreviews.org

- Download figures
- Navigate cited references
- Keyword search
- Explore related articles
- Share via email or social media

Annu. Rev. Nutr. 2019.39:95-120. Downloaded from www.annualreviews.org. Access provided by Dartmouth College - Main Library on 01/12/21. For personal use only.

Annu. Rev. Nutr. 2019.39:95-120
First published as a Review in Advance on May 15, 2019
The Annual Review of Nutrition is online at nut.annualreviews.org
https://doi.org/10.1146/annurev-nutr-082018-124555
Copyright © 2019 by Annual Reviews. All rights reserved.

Keywords
macular pigment, macular carotenoids, carotenoid supplementation, ocular nutrition, retinal imaging

Abstract
Retinal carotenoids are dietary nutrients that uniquely protect the eye from light damage and various retinal pathologies. Their antioxidative properties protect the eye from many retinal diseases, such as age-related macular degeneration. As many retinal diseases are accompanied by low carotenoid levels, accurate noninvasive assessment of carotenoid status can help ophthalmologists identify the patients most likely to benefit from carotenoid supplementation. This review focuses on the different methods available to assess carotenoid status and highlights disease-related changes and potential nutritional interventions.

91

ASSESSMENT OF CAROTENOIDS

Impact of Carotenoid Assessment

Because carotenoids appear to play a key role in retinal diseases, intensive research has resulted in a variety of innovative carotenoid assessment techniques. The breadth of possibilities for assessing retinal carotenoids is often confusing because methodologies, units of measurement, and the presentation of results vary widely. Accurate readings of carotenoid status are important in order to correctly advise individuals with regards to supplementation. Furthermore, in diseases such as macular telangiectasia type 2 (MacTel), the assessment of carotenoids may be crucial to the diagnosis, as reduced MP levels as well as abnormal distributions are among the first signs of the disease. Therefore, the measurement of carotenoids can impact clinical practice, and the evaluation of MP may eventually become an integral part of comprehensive ophthalmological care. The following sections describe and aim to give an organized overview of different MP assessment techniques.

A large variety of methods are used to assess carotenoid status in humans, most of which are focused on the eye, but carotenoids can also be measured in tissue outside of the eye, such as the skin, blood, and the brain. Measurements of ocular carotenoids can be distinguished between subjective (psychophysical) and objective (optical) methods used to assess the amount of MP. In subjective methods, a direct answer from the patient is required, whereas objective measurement methods typically require just enough cooperation to generate an image (73).

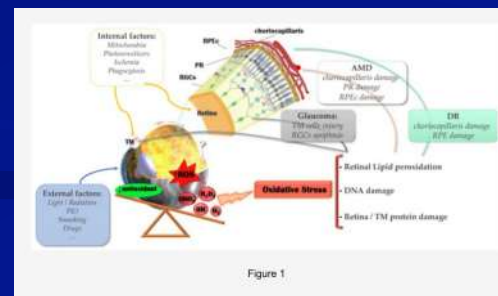
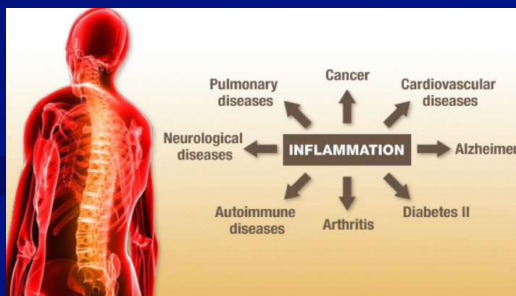
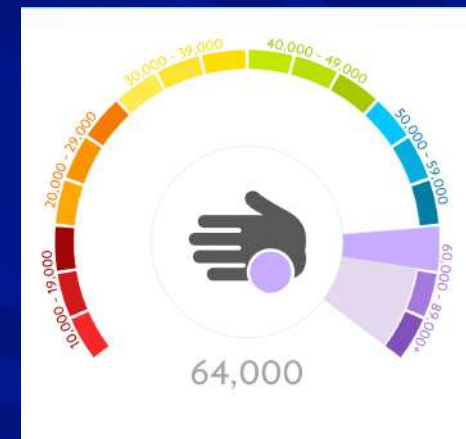
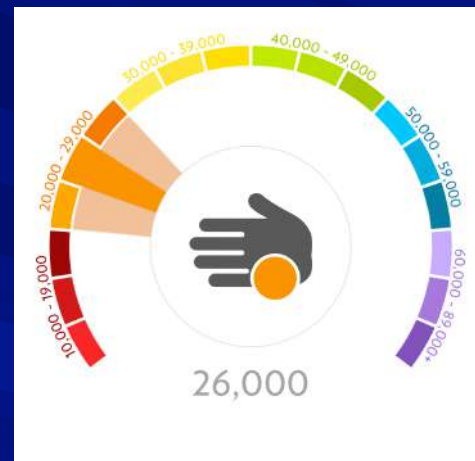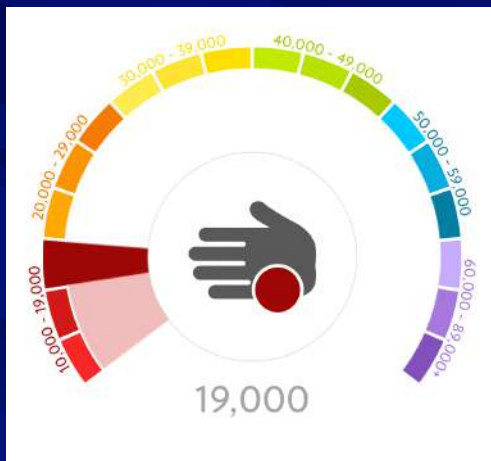
Carotenoids in Tissues Other Than the Eye

Carotenoids can be assessed noninvasively in the skin and by high-performance liquid chromatography (HPLC) of blood and tissue samples. It has been shown that RRS measurements of skin carotenoids show strong correlations ($r = 0.7$ to 0.9) with carotenoids in biopsies of human skin

www.annualreviews.org • Ocular Carotenoid Status in Health and Disease 103

(57, 96). Skin RRS and reflectometry are particularly useful to assess the carotenoid status of children, with skin carotenoid levels strongly associated with fruit and vegetable intake (123). Using HPLC, the carotenoid status in the plasma can also be assessed (77, 104), and higher L levels in the serum of patients have been associated with higher visual function. Similarly, carotenoid assessment in brain tissue suggests that higher carotenoid levels might be beneficial for overall cognitive performance (65, 74).

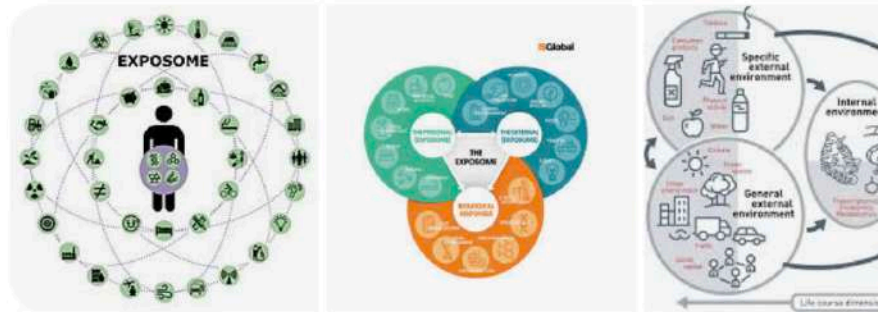
Chronic and Low-Grade Inflammation



DNA Sciences

- 🔗 Genomics = all of our genes
- 🔗 Genetics = individual genes
- 🔗 Epigenetics – the study of how our cells control gene activity without changing the DNA
 - ★ Internal and external environments

Exposome



The exposome can be defined as **the measure of all the exposures of an individual in a lifetime and how those exposures relate to health**. An individual's exposure begins before birth and includes insults from environmental and occupational sources. Understanding how exposures from our environment, diet, lifestyle, etc.

 <https://www.cdc.gov/niosh/topics>

Exposome and Exposomics - NIOSH
Workplace Safety and Health Topic - CDC

Google Search Definition

visiblegenomics.slingsr.io

2 of 3

PATIENT'S RISK OF ED AMD

LOW

CONTRIBUTION TO RISK RESULTS
The AMD Lifetime Risk is calculated based upon the patient's genetics, ocular findings, demographic and behavior status. The table below lists the patient's individual factors contributing to their individual risk.

RISK FACTORS

PATIENT FACTOR MEASURED	LOWER RISK	MODERATE RISK	HIGHER RISK	PATIENT RESULTS
AMD Grading	0-2 Factors	3 Factors	4 Factors	LOWER
Genetic Markers	Low	Moderate	High	LOWER
Race	Non-White	-	White	HIGHER
Smoking Status	Never	Past	Current	LOWER
BMI Score	<25	25-29	≥30	HIGHER
Gender	Male	-	Female	LOWER
Age (years)	55-64	65-74	≥75	LOWER

Electronically signed by: George Nils, M.D., Ph.D. Date Signed: 11/01/2021 Order ID: 9-1221 Patient ID: P-1192 Page 1 of 2

AMD LIFETIME RISK REPORT
age related macular degeneration

RISK FACTORS

GENE	SNPS	ALLELE	RISK	PATIENT RESULTS
ARMS2/HTRA1 (HTRA Serine Peptidase 1)	rs10490924	GG	Lower Risk (Reference)	X
		GT	Moderate Risk	
		TT	Higher Risk	
		TT	Highly Protective	
CFH (Complement Factor H)	rs121913059	CT	Moderately Protective	X
		CC	Higher Risk (Reference)	
		CT	Lower Risk (Reference)	
		TT	Moderate Risk	
C3 (Complement Component 3)	rs2230199	AA	Highly Protective	X
		GA	Moderately Protective	
		GG	Higher Risk (Reference)	
		GG	Lower Risk (Reference)	

Electronically signed by: George Nils, M.D., Ph.D. Date Signed: 11/01/2021 Order ID: 9-1221 Patient ID: P-1192 Page 2 of 3

visiblegenomics.slingsr.io

CURRENT AGE: 80 RISK OF ADVANCED AMD

PATIENT'S PROBABILITY OF ADVANCED AMD

HIGH

2 YEARS 18%
5 YEARS 49%
10 YEARS 90%
20 YEARS 100%
30 YEARS 100%

PROBABILITY OF ADVANCED AMD (%)

YEARS

Electronically signed by: George Nils, M.D., Ph.D. Date Signed: 11/26/2021 Order ID: 9-1380 Patient ID: P-1191 Page 1 of 3

AMD PROGRESSION REPORT
age related macular degeneration

RISK FACTORS

PATIENT FACTOR MEASURED	LOWER RISK	MODERATE RISK	HIGHER RISK	PATIENT RESULTS
AMD Grading	0-2 Factors	3 Factors	4 Factors	MODERATE
Genetic Markers	Low	Moderate	High	HIGHER
Race	Non-White	-	White	HIGHER
Smoking Status	Never	Past	Current	MODERATE
BMI Score	<25	25-29	≥30	HIGHER
Gender	Male	-	Female	LOWER
Age (years)	55-64	65-74	≥75	HIGHER

Electronically signed by: George Nils, M.D., Ph.D. Date Signed: 11/26/2021 Order ID: 9-1380 Patient ID: P-1191 Page 2 of 3

visiblegenomics.slingsr.io

2 of 3

PATIENT'S RISK OF ED AMD

MODERATE

CONTRIBUTION TO RISK RESULTS
The AMD Lifetime Risk is calculated based upon the patient's genetics, ocular findings, demographic and behavior status. The table below lists the patient's individual factors contributing to their individual risk.

RISK FACTORS

PATIENT FACTOR MEASURED	LOWER RISK	MODERATE RISK	HIGHER RISK	PATIENT RESULTS
AMD Grading	0-2 Factors	3 Factors	4 Factors	LOWER
Genetic Markers	Low	Moderate	High	MODERATE
Race	Non-White	-	White	HIGHER
Smoking Status	Never	Past	Current	LOWER
BMI Score	<25	25-29	≥30	LOWER
Gender	Male	-	Female	HIGHER
Age (years)	55-64	65-74	≥75	LOWER

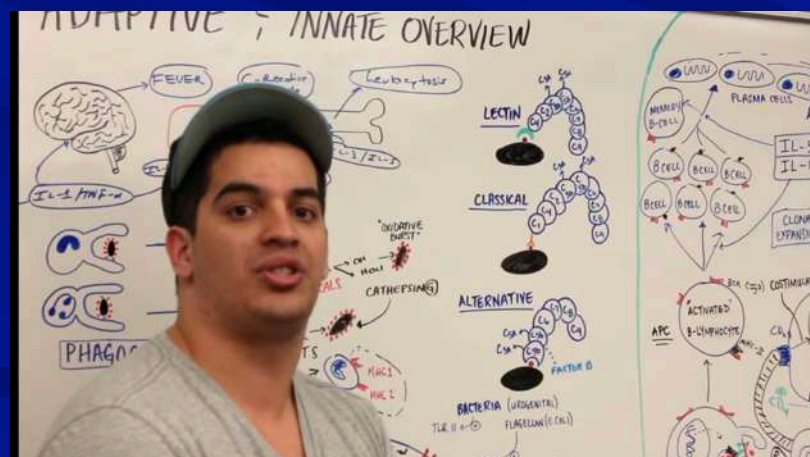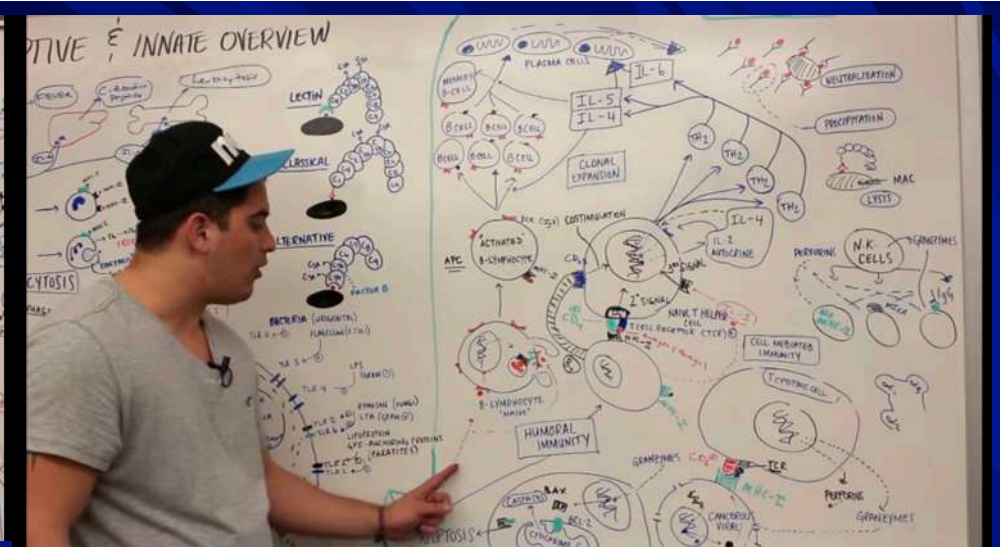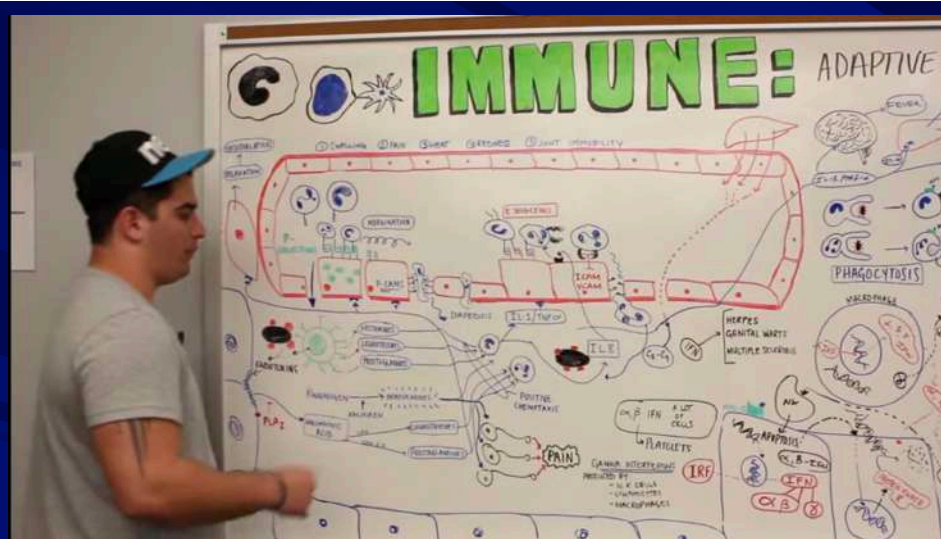
Electronically signed by: George Nils, M.D., Ph.D. Date Signed: 11/24/2021 Order ID: 9-1221 Patient ID: P-1191 Page 1 of 2

AMD LIFETIME RISK REPORT
age related macular degeneration

RISK FACTORS

GENE	SNPS	ALLELE	RISK	PATIENT RESULTS
ARMS2/HTRA1 (HTRA Serine Peptidase 1)	rs10490924	GG	Lower Risk (Reference)	X
		GT	Moderate Risk	
		TT	Higher Risk	
		TT	Highly Protective	
CFH (Complement Factor H)	rs121913059	CT	Moderately Protective	X
		CC	Higher Risk (Reference)	
		CT	Lower Risk (Reference)	
		TT	Moderate Risk	
C3 (Complement Component 3)	rs2230199	AA	Highly Protective	X
		GA	Moderately Protective	
		GG	Higher Risk (Reference)	
		GG	Lower Risk (Reference)	

Electronically signed by: George Nils, M.D., Ph.D. Date Signed: 11/24/2021 Order ID: 9-1221 Patient ID: P-1191 Page 2 of 3



Ninja Nerd Science
YouTube



Randomized Controlled Trial

Treatment response to antioxidants and zinc based on CFH and ARMS2 genetic risk allele number in the Age-Related Eye Disease Study

Carl C Awh et al. Ophthalmology. 2015 Jan.

Show details



Full text links



Cite



Abstract

Objective: To evaluate the impact of complement factor H (CFH) and age-related maculopathy susceptibility 2 (ARMS2) risk alleles on the observed response to components of the Age-Related Eye Disease Study (AREDS) formulation.

Design: Genetic and statistical subgroup analysis of a randomized, prospective clinical trial.

Participants: White patients from the AREDS with category 3 or 4 age-related macular degeneration (AMD) with available DNA (n = 989).

Results: Patients with 2 CFH risk alleles and no ARMS2 risk alleles progressed more with zinc-containing treatment compared with placebo, with a hazard ratio (HR) of 3.07 (P = 0.0196) for zinc and 2.73 (P = 0.0418) for AREDS formulation (AF). Seven-year treatment-specific progression rates were: placebo, 17.0%; zinc, 43.2% (P = 0.023); and AF, 40.2% (P = 0.039). Patients with 0 or 1 CFH risk alleles and 1 or 2 ARMS2 risk alleles benefited from zinc-containing treatment compared with placebo, with an HR of 0.514 for zinc (P = 0.012) and 0.569 for AF (P = 0.0254). Seven-year treatment-specific AMD progression rates were as follows: placebo, 43.3%; zinc, 25.2% (P = 0.020); and AF, 27.3% (P = 0.011). Zinc and AF treatment each interacted statistically with these 2 genotype groups under a Cox model, with P values of 0.000999 and 0.00366, respectively. For patients with 0 or 1 CFH risk alleles and no ARMS2 risk alleles, neither zinc-containing treatment altered progression compared with placebo, but treatment with antioxidants decreased progression (HR, 0.380; P = 0.034). Seven-year progression with placebo was 22.6% and with antioxidants was 9.17% (P = 0.033). For patients with 2 CFH risk alleles and 1 or 2 ARMS2 risk alleles, no treatment was better than placebo (48.4%).

Conclusions: The benefit of the AREDS formulation seems the result of a favorable response by patients in only 1 genotype group, balanced by neutral or unfavorable responses in 3 genotype groups.

pubmed.ncbi.nlm.nih.gov

RESEARCH ARTICLE | OPEN ACCESS



CFH and ARMS2 genetic risk determines progression to neovascular age-related macular degeneration after antioxidant and zinc supplementation

Demetrios G. Vavvas, Kent W. Small, Carl C. Awh, and Rafal Kusztal. [Authors Info & Affiliations](#)

January 8, 2018 | 115 (4) E696-E704
<https://doi.org/10.1073/pnas.1718059115>



Genetic Polymorphisms of CFH and ARMS2 Do Not Predict Response to Antioxidants and Zinc in Patients with Age-Related Macular Degeneration

Independent Statistical Evaluations of Data from the Age-Related Eye Disease Study

Miklos J. Aul, MD,^{1,2} Fan Li, MD,^{1,2} Ying Wang, PhD,^{1,2} Andrew S. Allen, PhD,^{1,2} Erik A. Baggett, PhD,^{1,2} Andrew J. Valler, PhD

Purpose: Considerable controversy has existed in recent years regarding whether genotyping should be part of standard care for patients with age-related macular degeneration (AMD) who are being considered for treatment with antioxidants and zinc. We aimed to determine whether genotype predicts response to supplements in AMD.

Design: Three separate statistical teams reanalyzed data derived from the Age-Related Eye Disease Study (AREDS), receiving data provided by the AREDS investigators and, separately, data from investigators reporting findings that extend the use of genotyping.

Participants: The population of interest was AREDS participants with AMD worse than category 1 and genotyping data available. Data from the 2 groups overlap extensively with respect to measurements made; the largest common set involved 879 participants for whom the same CFH and ARMS2 single nucleotide polymorphisms were measured by both groups.

Methods: Each team took a separate but complementary approach. One team focused on data concordance between conflicting studies. A second team focused on replicating the key claims of an interaction between genotype and treatment. The third team took a linear model approach in attempting to find baseline predictors of treatment response.

Main Outcome Measures: Progression to advanced AMD.

Results: The first team aimed to support the initial claim of genotype-treatment interaction. Although we found evidence that high-risk patients had more to gain from treatment, we were unable to replicate any genotype-treatment interactions after adjusting for multiple testing. We tested 3 genotype claims on an independent set of data, with negative results. Even if we assumed that interactions in fact did exist, we did not find evidence to support the claim that supplementation leads to a large increase in the rate of advanced AMD in some genotype subgroups.

Conclusions: Patients who meet criteria for supplements to prevent AMD progression should be offered zinc and antioxidants without consideration of genotype. Ophthalmology 2018;125:391-397 © 2017 by the American Academy of Ophthalmology

Supplemental material available at www.aaojournal.org

The Age-Related Eye Disease Study (AREDS) was a large, multicenter, double-blind, randomized trial to determine whether high-dose antioxidants, zinc, or their combination could reduce the risk of progression of age-related macular degeneration (AMD) in older patients. Excluding patients in AREDS category 1, for whom the crude rate was less than 1%, the combination of data and antioxidants was found to reduce the rate of progression to

advanced AMD (odds ratio, 0.48; 95% confidence interval [CI], 0.40-0.57; P = 0.002). The publication of the trial results led to rapid changes in practice, with at-risk patients routinely prescribed the zinc and antioxidant combination used in the trial.

In 2010, Klein et al¹ published a pharmacogenetics study regarding the effect of antioxidant and zinc on AMD in AREDS. They found that patients with

© 2017 by the American Academy of Ophthalmology. Published by Elsevier Inc.

0886-6266/18/125391-07\$36.00/0
DOI:10.1016/j.ophtha.2017.09.018

Complement factor H in AMD: Bridging genetic associations and pathobiology

Christopher B. Toomey ^{a, b, 1} ... Catherine Bowes Rickman ^{a, b}  

Show more 


 Outline  Share  Cite

<https://doi.org/10.1016/j.preteyeres.2017.09.001>

[Get rights and content](#)

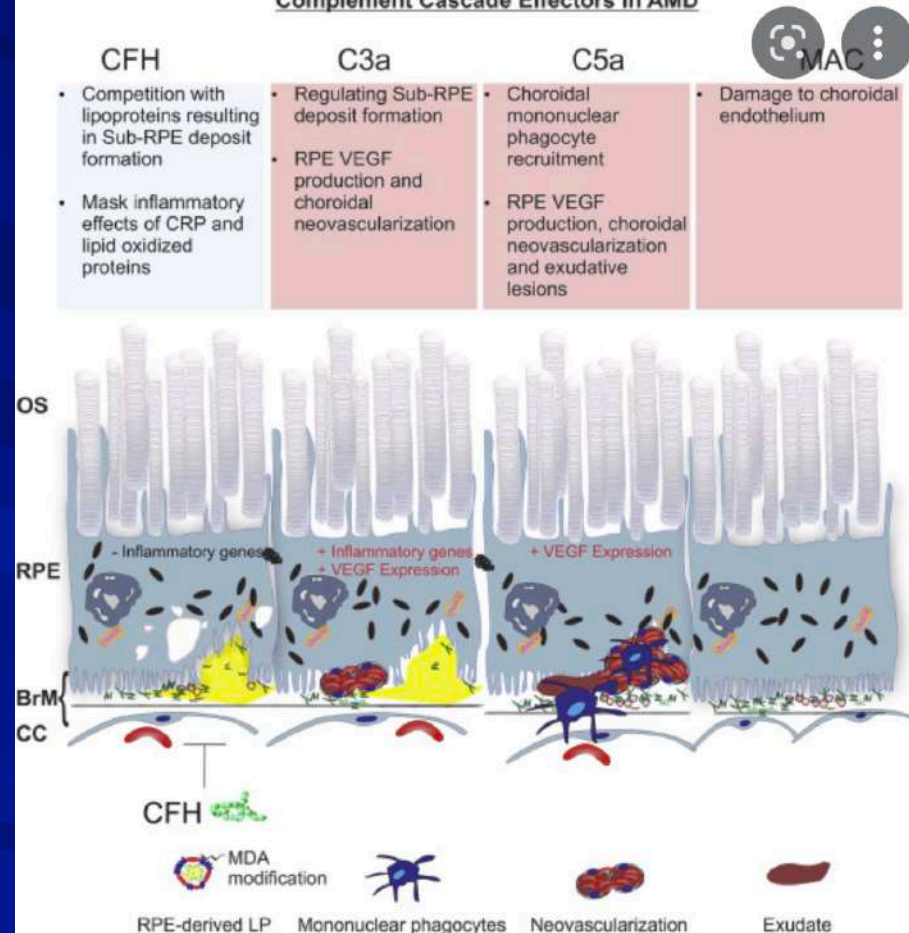
Abstract

Age-Related Macular Degeneration (AMD) is a complex multifactorial disease characterized in its early stages by lipoprotein accumulations in Bruch's Membrane (BrM), seen on fundoscopic exam as drusen, and in its late forms by neovascularization ("wet") or geographic atrophy of the Retinal Pigmented Epithelial (RPE) cell layer ("dry"). Genetic studies have strongly supported a relationship between the alternative complement cascade, in particular the common H402 variant in Complement Factor H (CFH) and development of AMD. However, the functional significance of the CFH Y402H polymorphism remains elusive. In this

FEEDBACK 

 sciencedirect.com

Complement Cascade Effectors in AMD



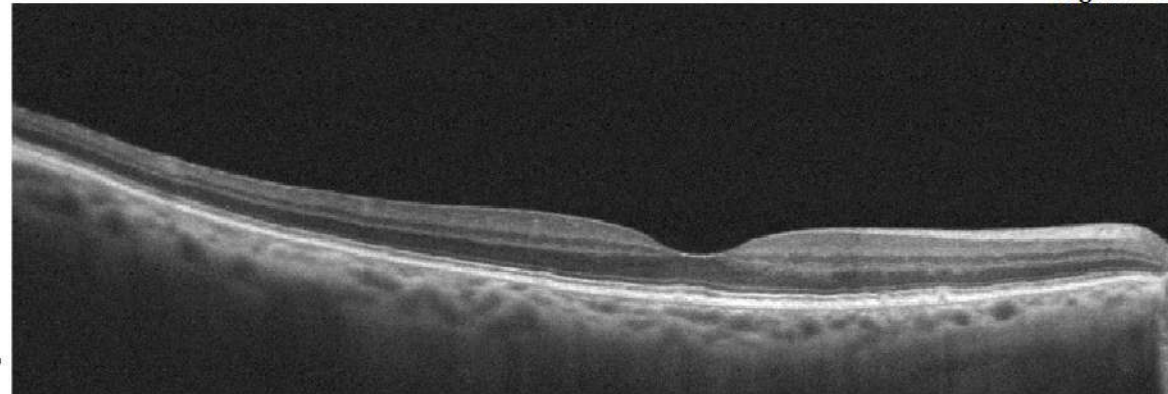
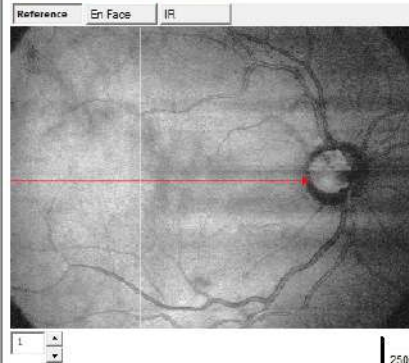
Cross Line Comparison Report

Scan 04/05/2021 14:33:33

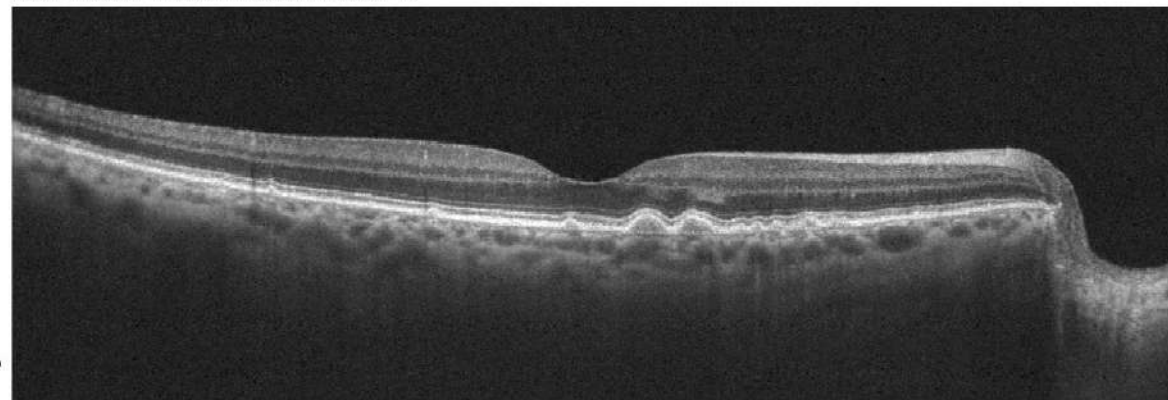
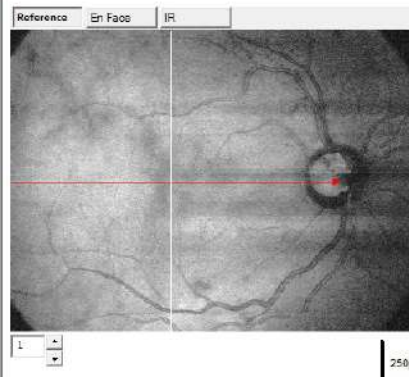
Signal Strength Index 58

10.00 Scan Size (mm)

Right / OD



☒ Auto Zoom



Scan 09/21/2020 10:40:42

Signal Strength Index 59

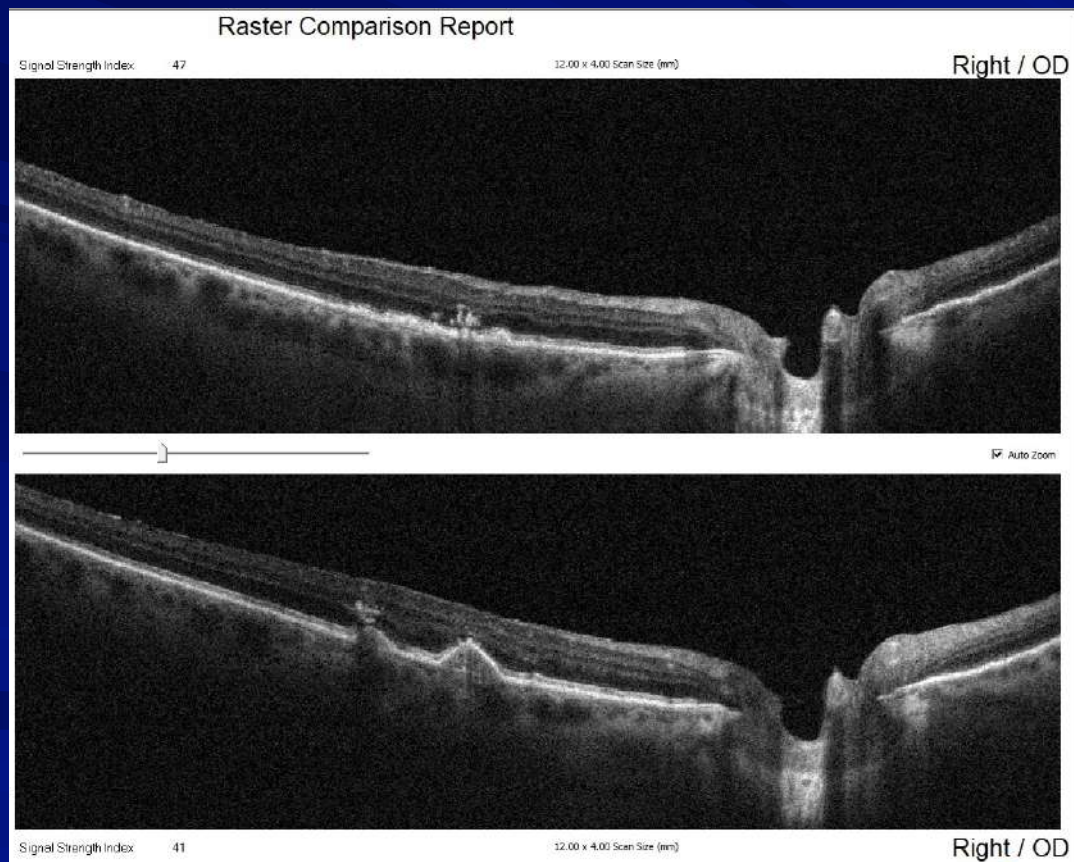
10.00 Scan Size (mm)

Right / OD

Print

OU Report

April 27, 2021 – January 26, 2022 (9 months)

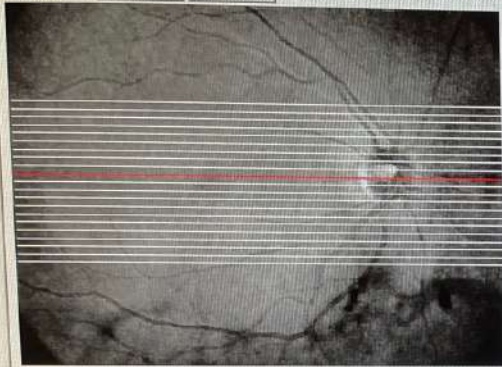


Melanie Clemmons, OD
May 20, 2022 AACO Nashville

Raster Comparison Report

Scan 09/29/2020 13:20:09

Reference En Face IR



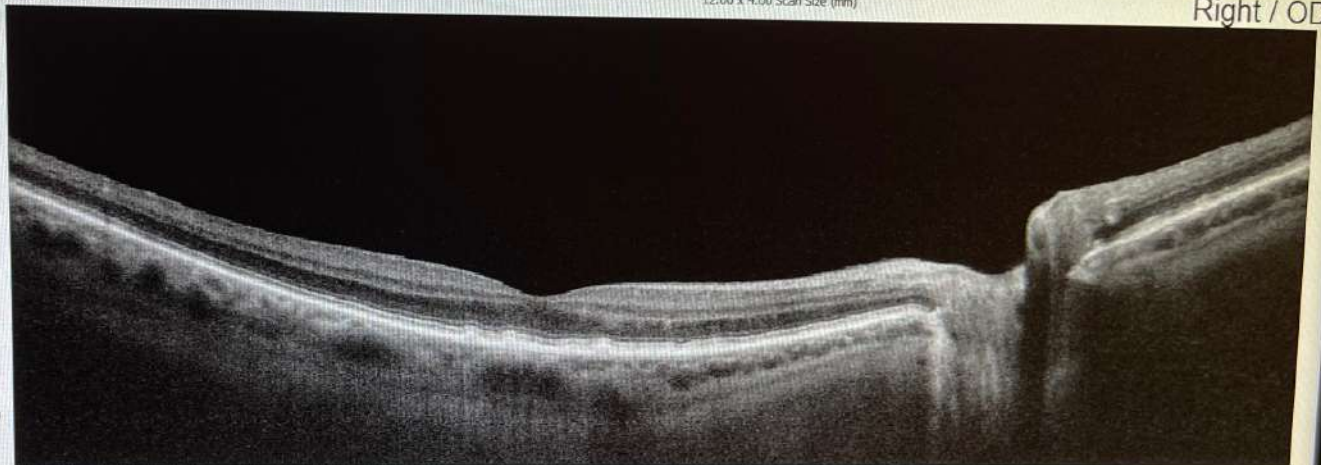10

250µm

Signal Strength Index 55

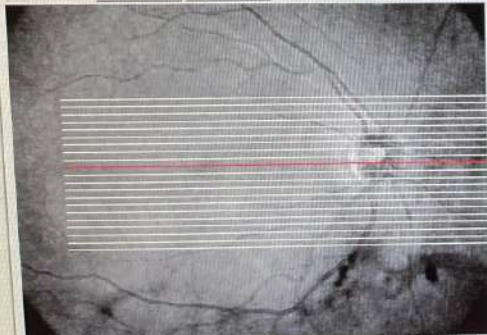
12.00 x 4.00 Scan Size (mm)

Right / OD



Auto Zoom

Reference En Face IR



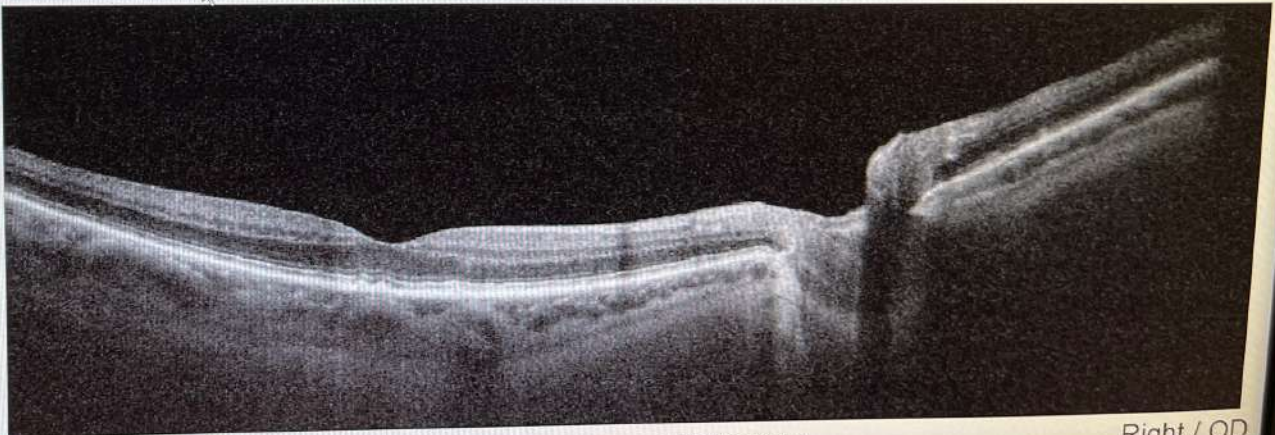10

250µm

Signal Strength Index 43

12.00 x 4.00 Scan Size (mm)

Right / OD



CRTVue

Scan 06/23/2021 10:22:11

Print

OU Report

49°F Sunny 10:46 AM 6/23/2021

Key Tenants of Aging, Performance and Vitality



Oxidative Stress / Inflammation



Hormonal Balance



Stress Hormones



Glucose / Insulin Regulation



GUT integrity and microbiome diversity



Immune Balance



Environmental Exposure/Burden



Individuality

Credit to: James LaValle, RPh, CCN

Inflamm-aging

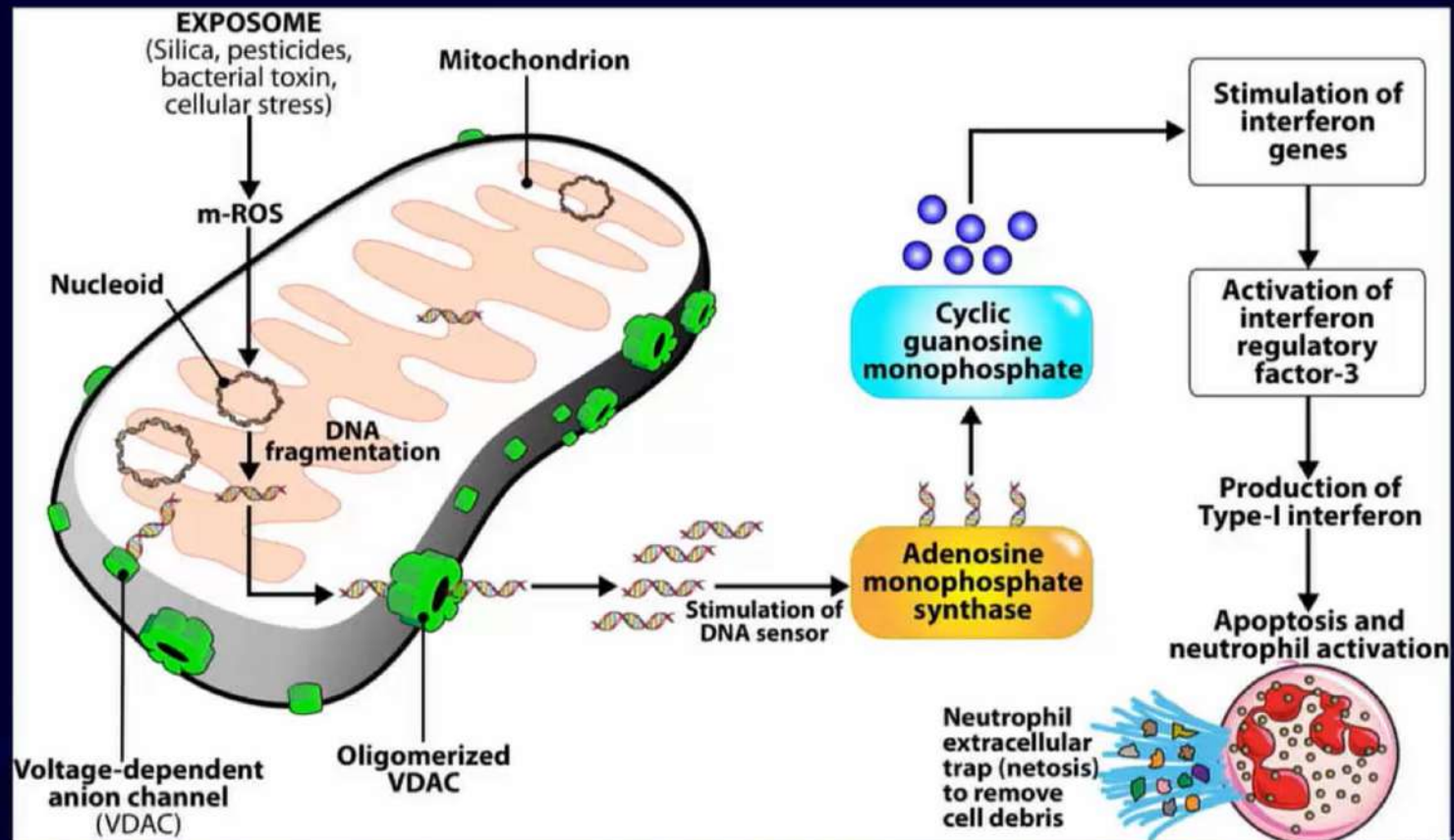
One of the consequences of failing mitochondria due to aging, beyond mtROS, is the release of mtDNA. Plasma levels of mtDNA increase gradually after the fifth decade of life, correlating with elevated levels of pro-inflammatory cytokines (i.e., TNF- α , IL-6, RANTES, and IL-1ra)

These data indicate that mtDNA may promote the production of pro-inflammatory cytokines in aging. Because cell stress, senescence and death are a part of the pathophysiology of aging designing new therapeutic strategies against circulating mtDNA, or other mtDAMPs, or their cognate receptors (e.g., TLRs or FPR1) may be a viable strategy to approaching IA and its associated conditions.



Credit to: Elroy Vojdani, MD -

Dead Batteries: The Role of Mitochondrial Dysfunction in Immunological Decline -
Emerging Diagnostic Tools and Nutraceutical Interventions



Mitochondrial exposure to exposomes or endogenous stress by fragmentation of DNA and its release into the cytosol induce inflammation and Autoimmunity. Modified from Crow MK, *Science*, 2019, 366(6472): 1445-1446

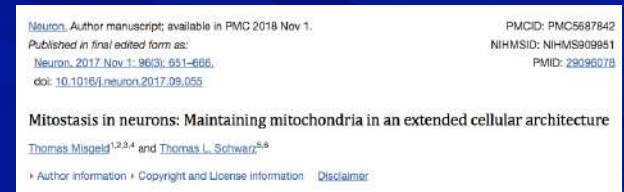Credit to: Elroy Vojdani, MD -

Dead Batteries: The Role of Mitochondrial Dysfunction in Immunological Decline - Emerging Diagnostic Tools and Nutraceutical Interventions

Fun Facts I Have Learned About the Mitochondria

- 👁 Mitochondria produce energy from organic matter
- 👁 Live about 100 days
- 👁 They produce 90% of energy in the body
- 👁 In return they product 90% of the free radicals
- 👁 When they become dysfunction when get many clinical consequences
- 👁 Mitochondria are very sensitive to reactive oxygen and need antioxidant support
- 👁 Mitochondria are one of cellular organelles
 - ★ Electron transport chain – uses co-enzyme 10, and many other micronutrients
 - ★ Brain cell has 1-2 million/single neuron
 - ★ Heart cell has 5,000/cell
 - ★ Liver cell has 1000-2000/cell
 - ★ Photoreceptors 498/cell
 - ★ RPE cells >700/cell

The ellipsoid contains a densely-packed array of mostly elongated mitochondria arranged broadly parallel to the long axis of the photoreceptor. The cell contained **498 individual mitochondria**



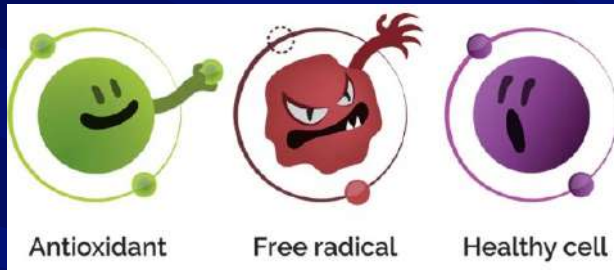Question

Do you agree that free radical formation is a progressive process that leads to cell damage or death?

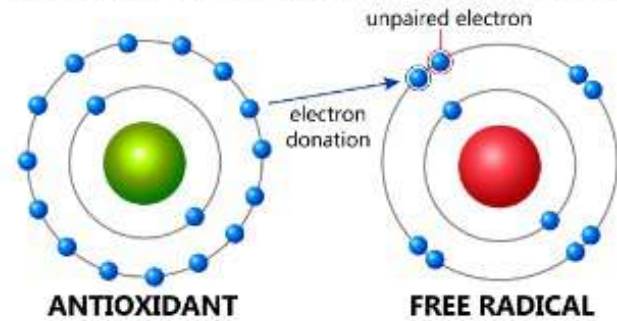
★ Yes

★ No

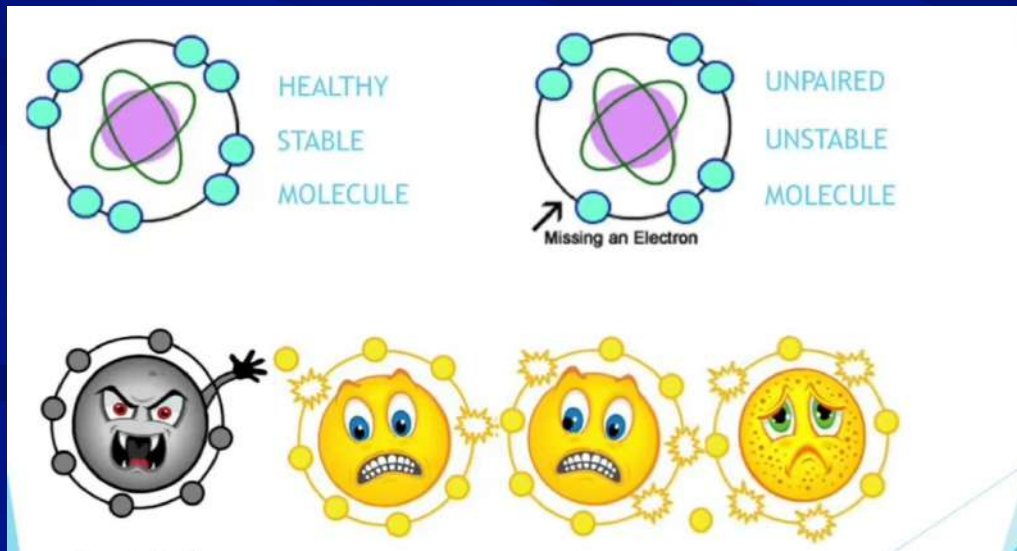
Free Radicals and Antioxidants



How antioxidants reduce free radicals

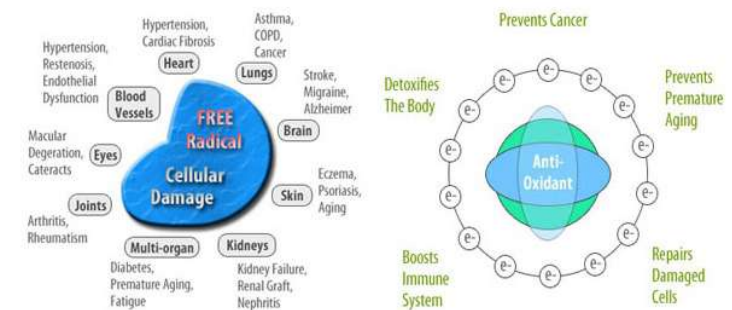
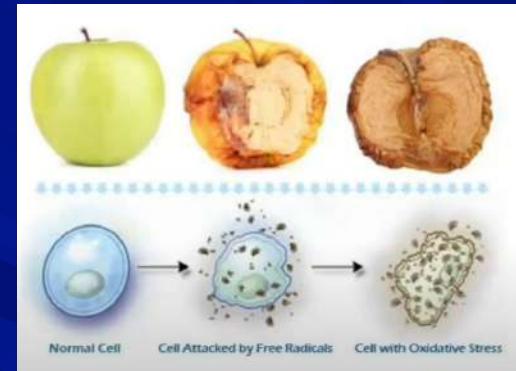


chemically reactive unpaired electron + electron donation:
stable electron pair is formed, free radical is neutralised



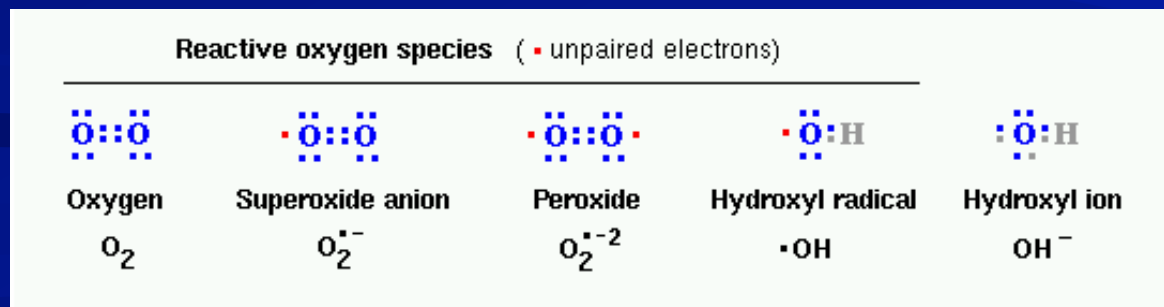
Oxidative Stress

- Small percentage of oxygen is not completely reduced
 - Accumulation of free radicals
 - Oxidative damage
 - Oxidative stress
 - Considered the starting of several diseases
 - Responsible for epigenetic alterations
 - Mitochondria – vulnerable
- Not going to make this apple new again
- ★ Prevention is the one of the best medicines

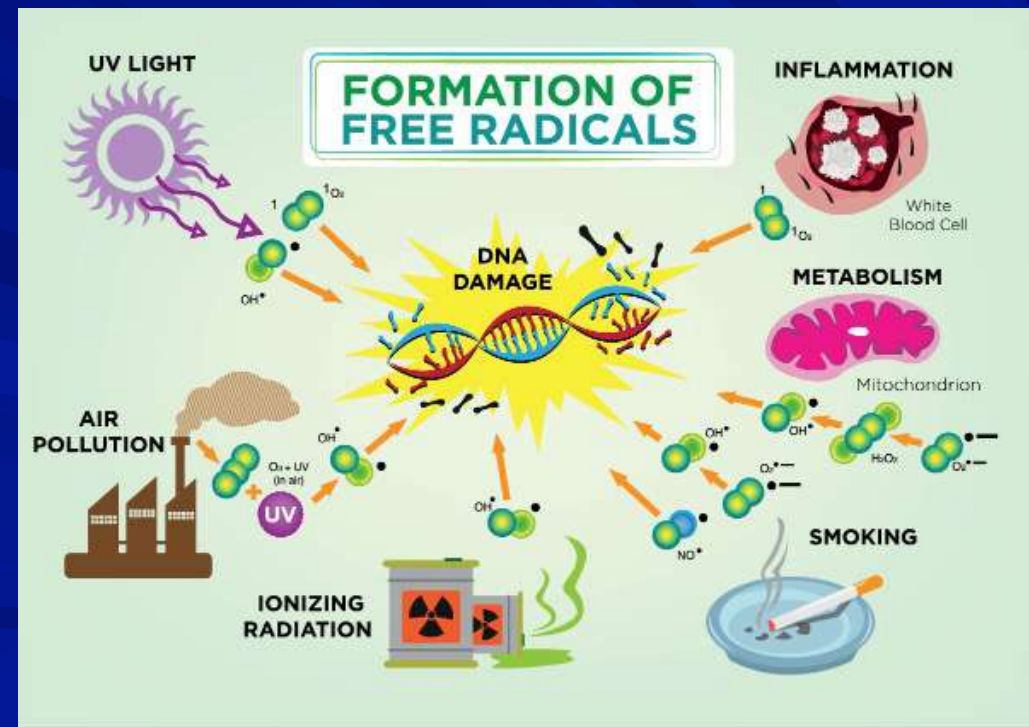
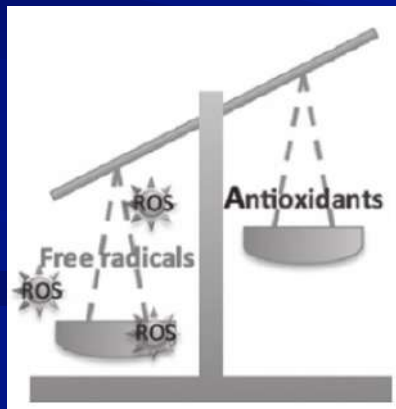
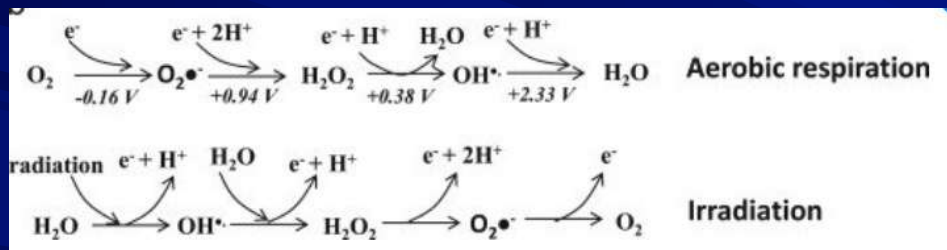


Free Radicals

- During metabolism the O_2 molecule splits and energy is released
 - ★ Endogenous free radical formation
- Regain stability the free single oxygen atom (oxygen free radical) seeks and steals electrons from other molecules
 - ★ Superoxide anion – will accept one electron
 - ★ Peroxide – will accept two electrons
- These molecules can be proteins, lipids, and DNA
 - ★ Proteins (enzymes) – kinases, phosphatases, and transcription factors



Endogenous and Exogenous Free Radial Formation



Oh no

- ⌘ Increasing exogenous free radicals
- ⌘ Less antioxidant protection in our diet
- ⌘ More bad and less good



Is an orange of the 1950's equivalent to 21 of today's oranges?

An orange from the 1950's was full of vitamin A, precious for our sight and our immune defenses. To attain the same amounts today, you would have to consume 21 of them. Onions and potatoes no longer contain any trace of it. The iron content in meat? Divided by 2. Calcium in broccoli? Divided by 4. To ingest the vitamin C contained in an apple from yesteryear, you would have to eat 100 today.

The Equalizer



October 23, 2021





October 23, 2021

M Lounge



Nutritional Antioxidants

Exogenous antioxidants

- ★ Tocopherols (E), ascorbic acid (C), carotenoids, ubiquinone, and polyphenols

Well know antioxidants

- ★ Vitamin C, E, Beta-carotene, lutein, zeathanin, selenium, quercetin, and resveratrol

Mechanisms of action;

- ★ Neutralize free radicals
- ★ Repair oxidized membranes
- ★ Decrease reactive oxygen species
- ★ Neutral reactive oxygen species

Endogenous and Exogenous Antioxidants

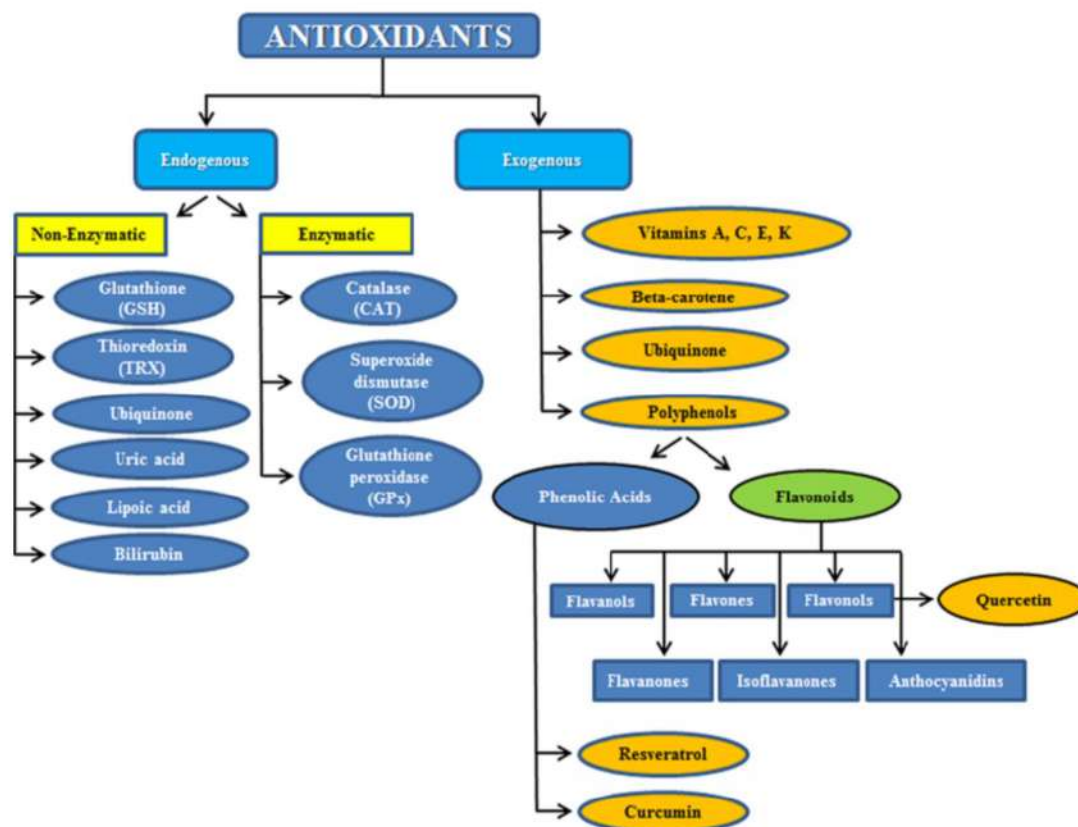
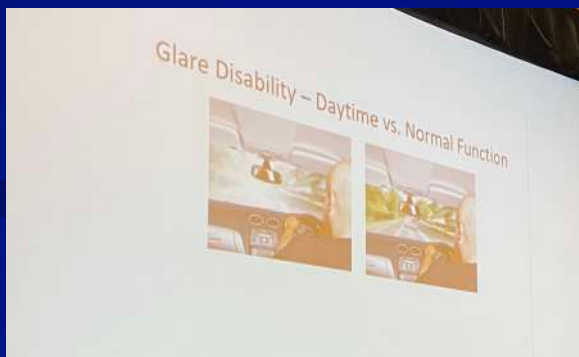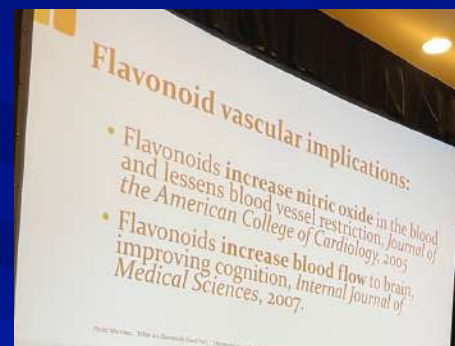



Figure 1: Subdivision between endogenous and exogenous antioxidants.

Carotenoids

- 👓 Why do hear so much about carotenoids
- 👓 Melonie Clemmons, OD May 20, 2022 AACO Nashville



Carotenoids

Organic pigments produced by plants, algae, and bacteria

Cannot be synthesized by the human body

- ★ Hydrophobic compounds

- ☐ Important for the phospholipid bilayer

600 in nature – 50 human food chain – 15-20 human blood stream

Macular carotenoids (L and Z) – highest concentration found in the human body

- ★ Diet derived

- ★ Henle fibers – between the inner and outer plexiform layers

- ★ Sequester or absorb blue light

Question

Do you measure carotenoid levels in your office?

★ Yes

★ No

Measure?



Annual Review of Nutrition
Ocular Carotenoid Status in Health and Disease

Lydia Sauer, Binxing Li, and Paul S. Bernstein
Department of Ophthalmology and Visual Sciences, John A. Moran Eye Center,
University of Utah, Salt Lake City, Utah 84143, USA; email: lydia.sauer@hsc.utah.edu,
Binxing.Li@hsc.utah.edu, paul.bernstein@hsc.utah.edu

ANNUAL REVIEWS CONNECT
www.annualreviews.org

- Download figures
- Navigate cited references
- Keyword search
- Explore related articles
- Share via email or social media

Annu. Rev. Nutr. 2019.39:95-120.
First published as a Review in Advance on May 15, 2019.
The Annual Review of Nutrition is online at nut.annualreviews.org.
https://doi.org/10.1146/annurev-nutr-082018-124555
Copyright © 2019 by Annual Reviews.
All rights reserved.

Keywords
macular pigment, macular carotenoids, carotenoid supplementation, ocular nutrition, retinal imaging

Abstract
Retinal carotenoids are dietary nutrients that uniquely protect the eye from light damage and various retinal pathologies. Their antioxidative properties protect the eye from many retinal diseases, such as age-related macular degeneration. As many retinal diseases are accompanied by low carotenoid levels, accurate noninvasive assessment of carotenoid status can help ophthalmologists identify the patients most likely to benefit from carotenoid supplementation. This review focuses on the different methods available to assess carotenoid status and highlights disease-related changes and potential nutritional interventions.

ASSESSMENT OF CAROTENOIDS

Impact of Carotenoid Assessment

Because carotenoids appear to play a key role in retinal diseases, intensive research has resulted in a variety of innovative carotenoid assessment techniques. The breadth of possibilities for assessing retinal carotenoids is often confusing because methodologies, units of measurement, and the presentation of results vary widely. Accurate readings of carotenoid status are important in order to correctly advise individuals with regards to supplementation. Furthermore, in diseases such as macular telangiectasia type 2 (MacTel), the assessment of carotenoids may be crucial to the diagnosis, as reduced MP levels as well as abnormal distributions are among the first signs of the disease. Therefore, the measurement of carotenoids can impact clinical practice, and the evaluation of MP may eventually become an integral part of comprehensive ophthalmological care. The following sections describe and aim to give an organized overview of different MP assessment techniques.

A large variety of methods are used to assess carotenoid status in humans, most of which are focused on the eye, but carotenoids can also be measured in tissue outside of the eye, such as the skin, blood, and the brain. Measurements of ocular carotenoids can be distinguished between subjective (psychophysical) and objective (optical) methods used to assess the amount of MP. In subjective methods, a direct answer from the patient is required, whereas objective measurement methods typically require just enough cooperation to generate an image (73).

Carotenoids in Tissues Other Than the Eye

Carotenoids can be assessed noninvasively in the skin and by high-performance liquid chromatography (HPLC) of blood and tissue samples. It has been shown that RRS measurements of skin carotenoids show strong correlations ($r = 0.7$ to 0.9) with carotenoids in biopsies of human skin

(57, 96). Skin RRS and reflectometry are particularly useful to assess the carotenoid status of children, with skin carotenoid levels strongly associated with fruit and vegetable intake (123). Using HPLC, the carotenoid status in the plasma can also be assessed (77, 104), and higher L levels in the serum of patients have been associated with higher visual function. Similarly, carotenoid assessment in brain tissue suggests that higher carotenoid levels might be beneficial for overall cognitive performance (65, 74).

Significance of Carotenoids

High blood levels of the carotenoid alpha-carotene may reduce the risk of dying from cardiovascular disease (CVD), cancer, and all other causes by up to 39 percent. Results from a 14 year study.

Source: Archives of Internal Medicine
Published online ahead of print, doi: 10.1001/archinte.
"Serum a-Carotene Concentrations and Risk of Death: Results from the Atherosclerosis Risk in
Examination Survey Follow-up Study"
Authors: C. Li, E.S. Ford, G. Zhao, L.S. Balluz, W.L.

elderly: results of

AREDS 2: Higher dietary intake of lutein/zeaxanthin was independently associated with decreased risk of having neovascular AMD, geographic atrophy, and large or extensive drusen.

Arch Ophthalmol. 200

Levels of carotenoids may increase risk of persistent HPV infection

Institute-Surveillance,
case-control

Total plasma carotenoids and risk of coronary heart disease: a prospective study.
British Journal of Nutrition

Plasma carotenoid levels and cognitive performance in an elderly population: results of the EVA Study.

Akbaraly NT¹, Faure H, Gourlet V, Favier A, Berr C.

Epidemiology
study 1-3
Am J Clin Nutr

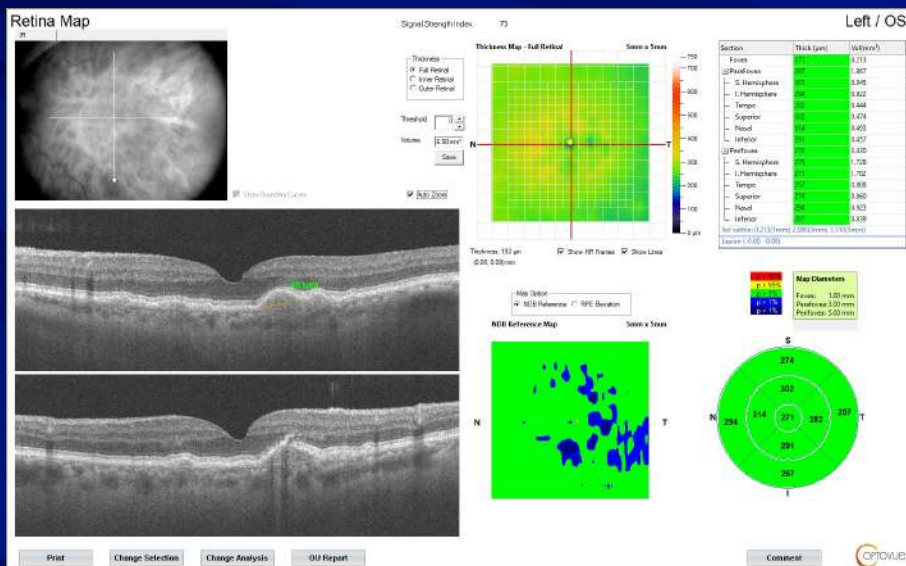
Search term

Oxidative stress in rheumatoid arthritis patients: relationship with carotenoid intake and antioxidant activity.

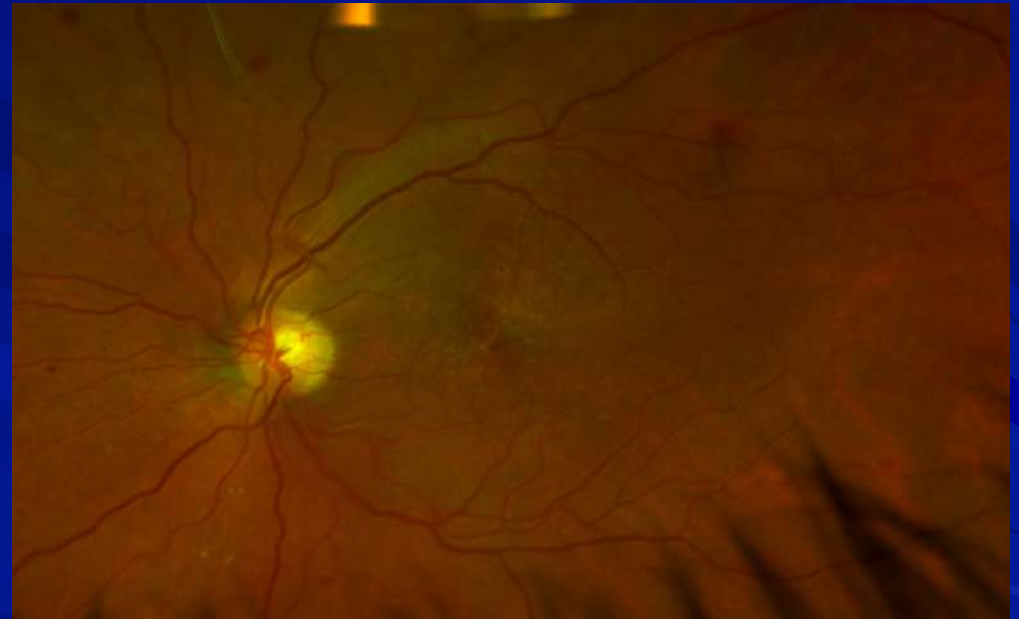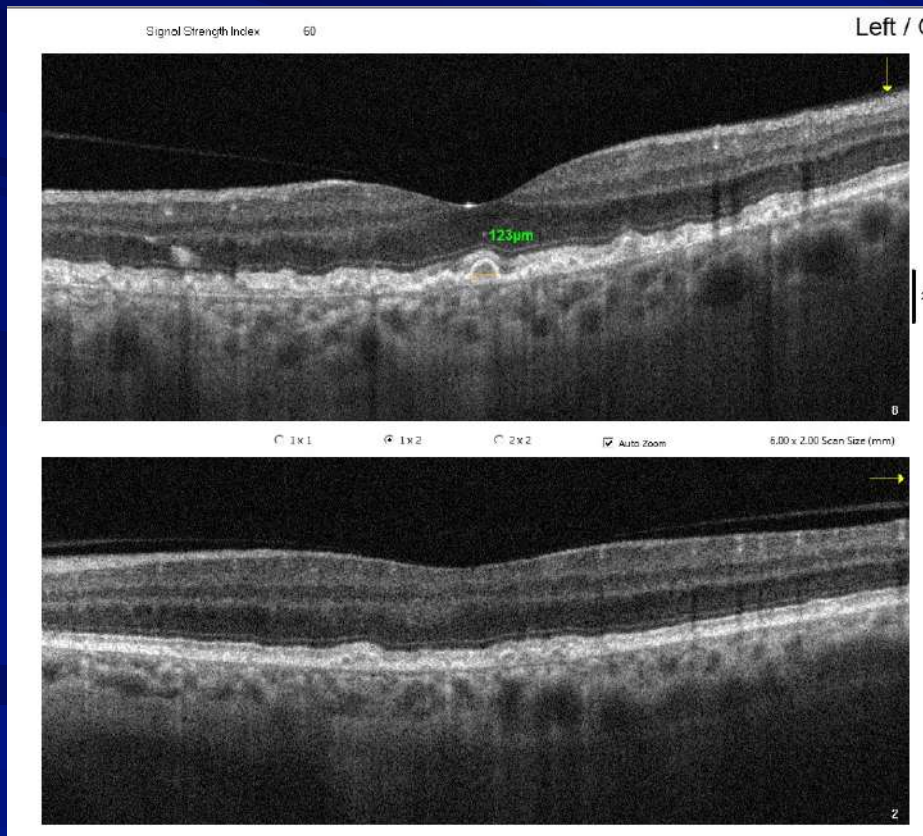Veselinovic M, et al. [Show all](#)

Mol Cell Biochem. 2014 Jun;391(1-2):225-32. doi: 10.1007/s11010-014-2006-6. Epub 2014 Mar 9.

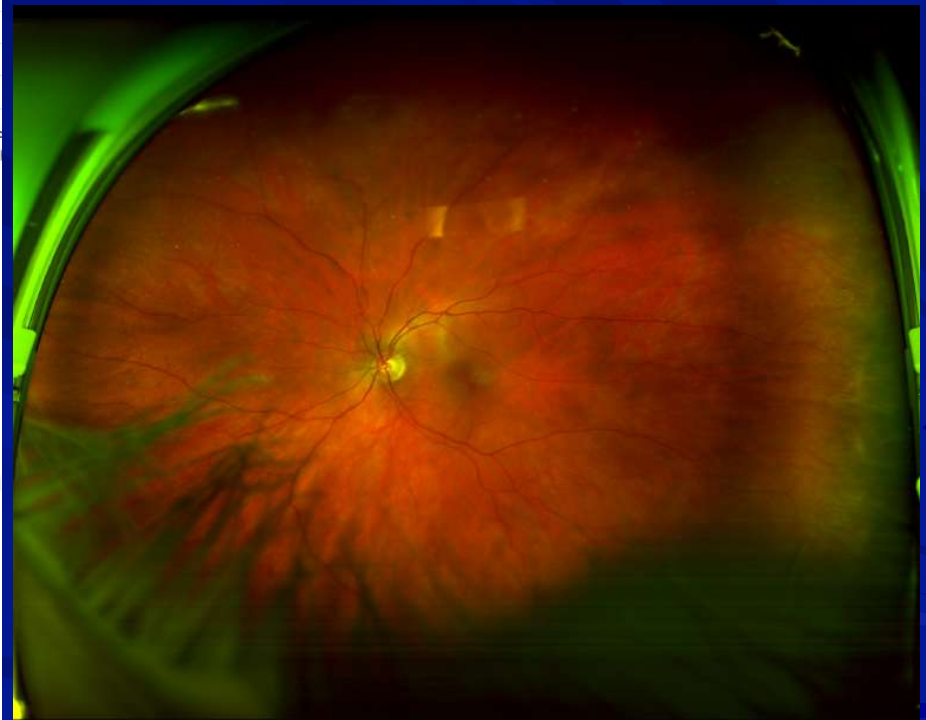
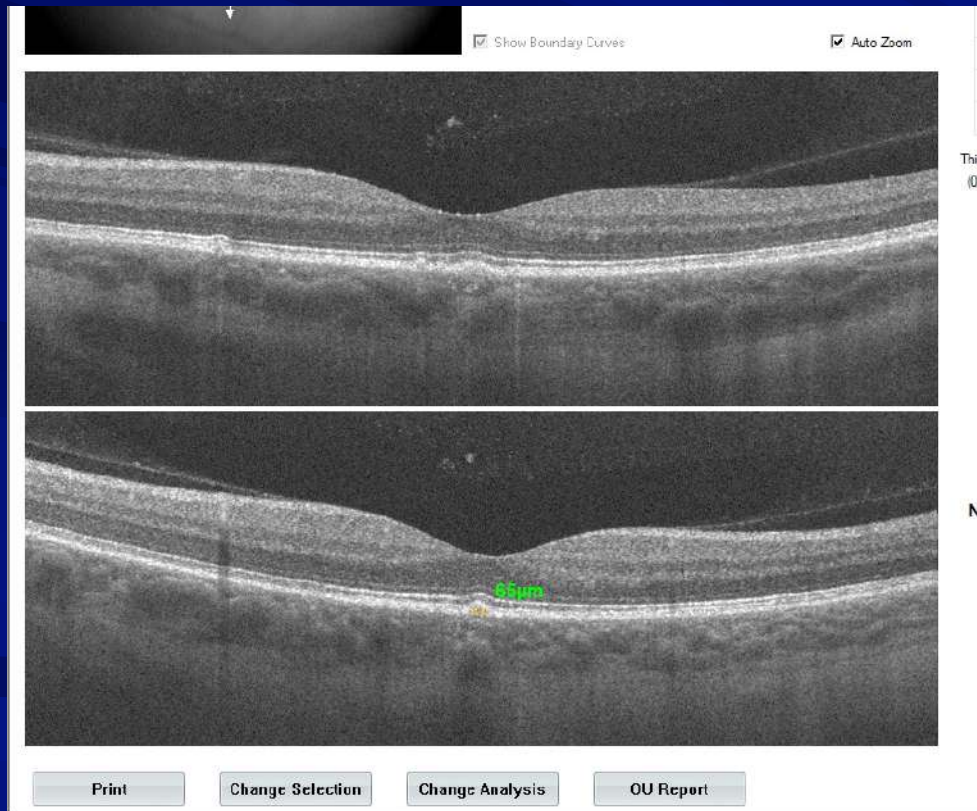
Oxidative Stress with Your OCT



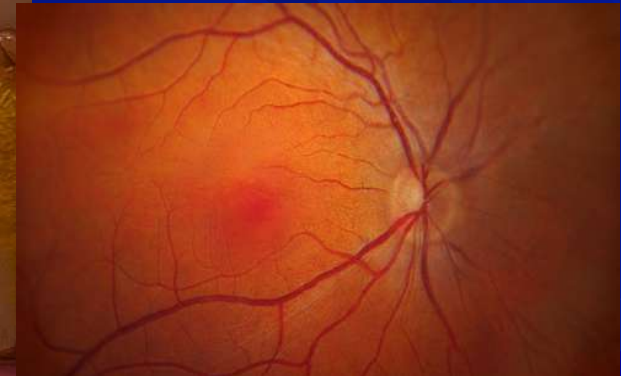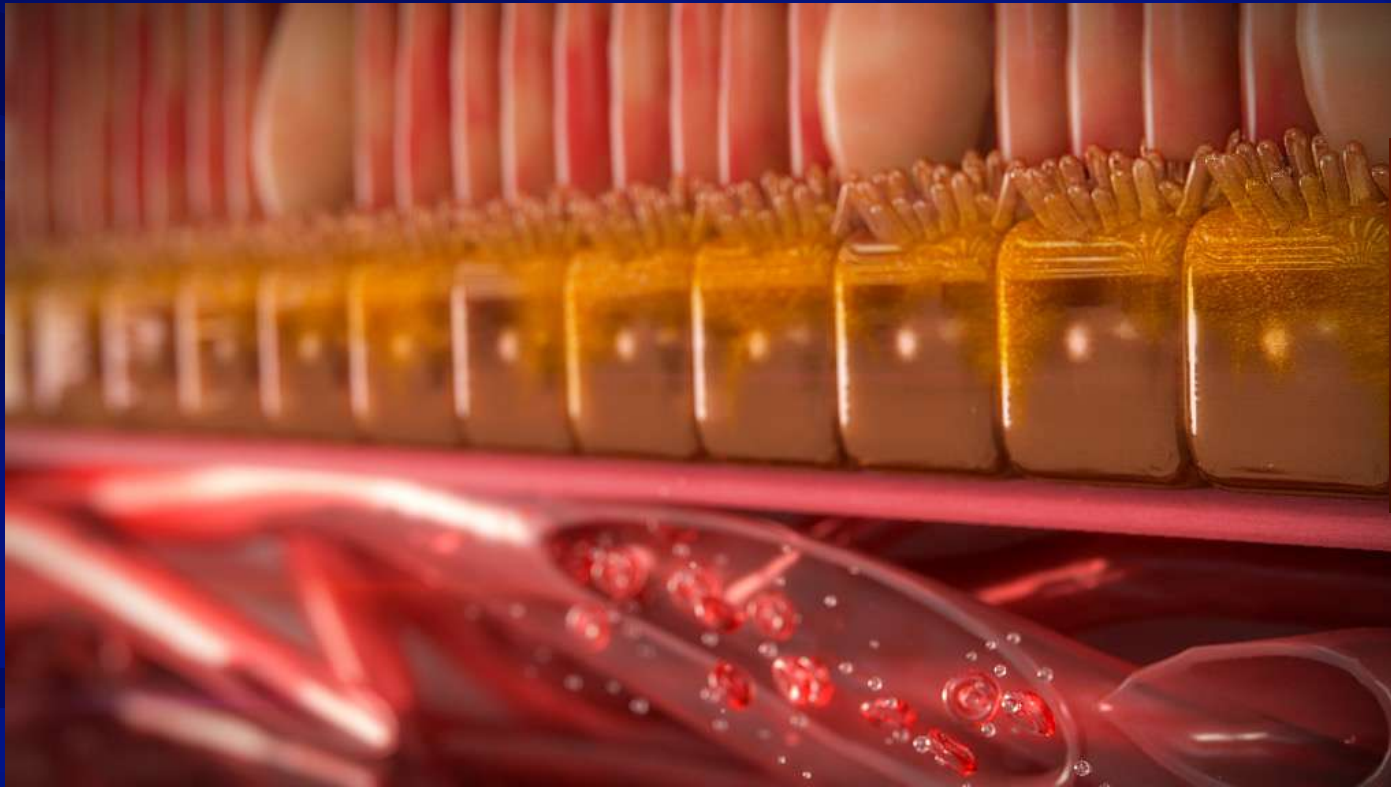
Oxidative Stress with Your OCT



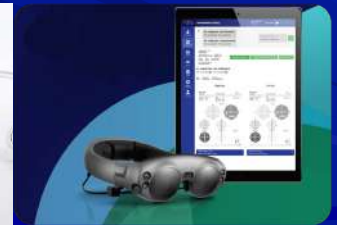
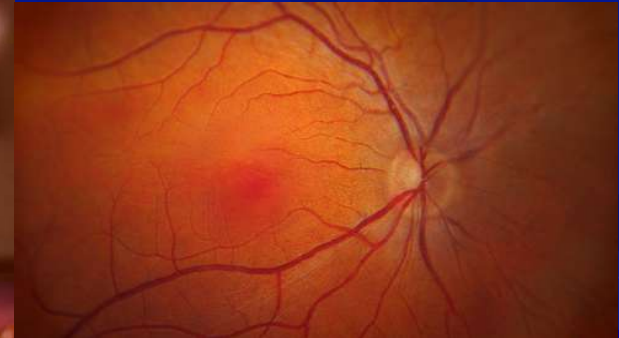Oxidative Stress with Your OCT



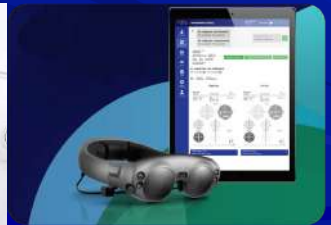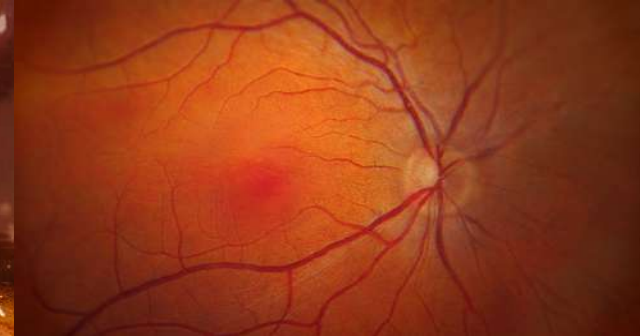Healthy choriocapillaris, Bruch's, RPE, and Photoreceptors



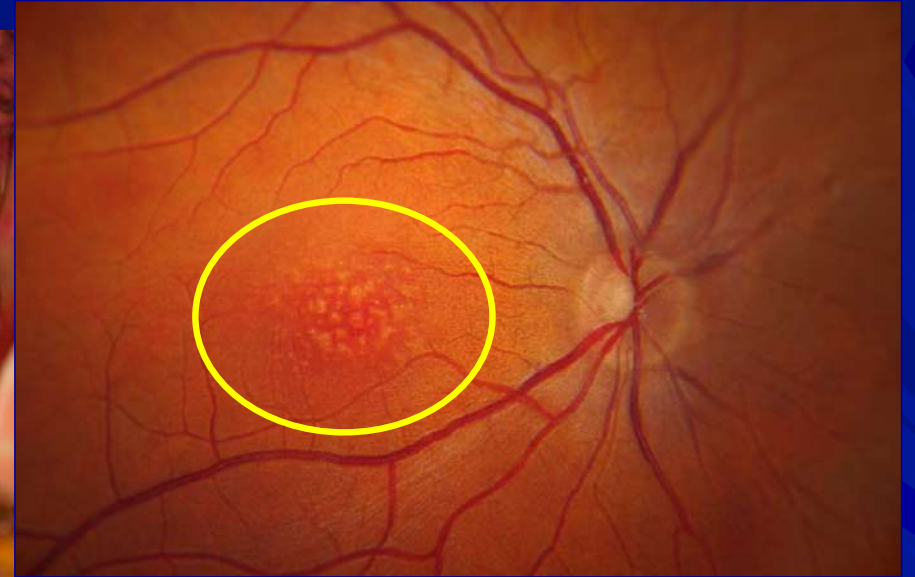
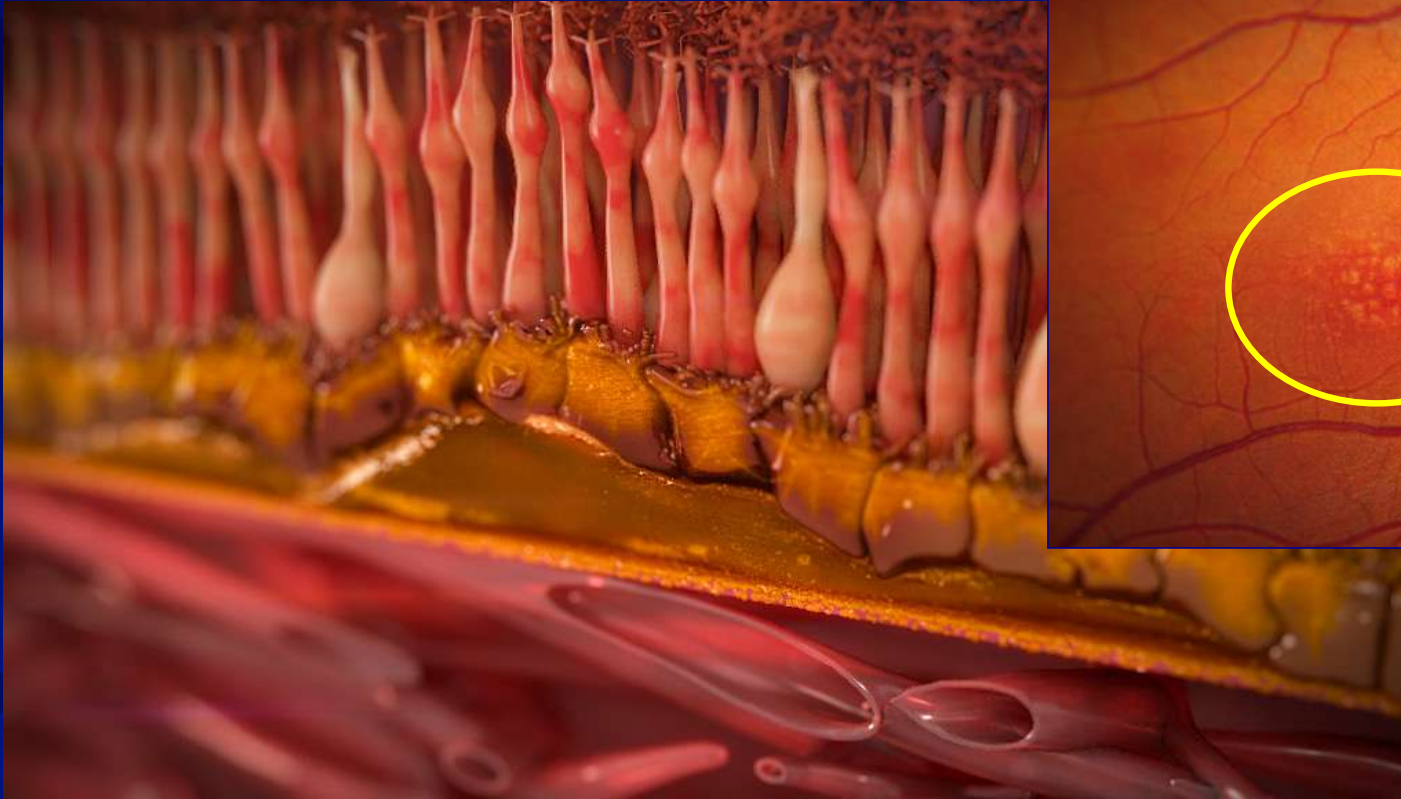
Cholesterol barrier deposited along Bruch's and RPE



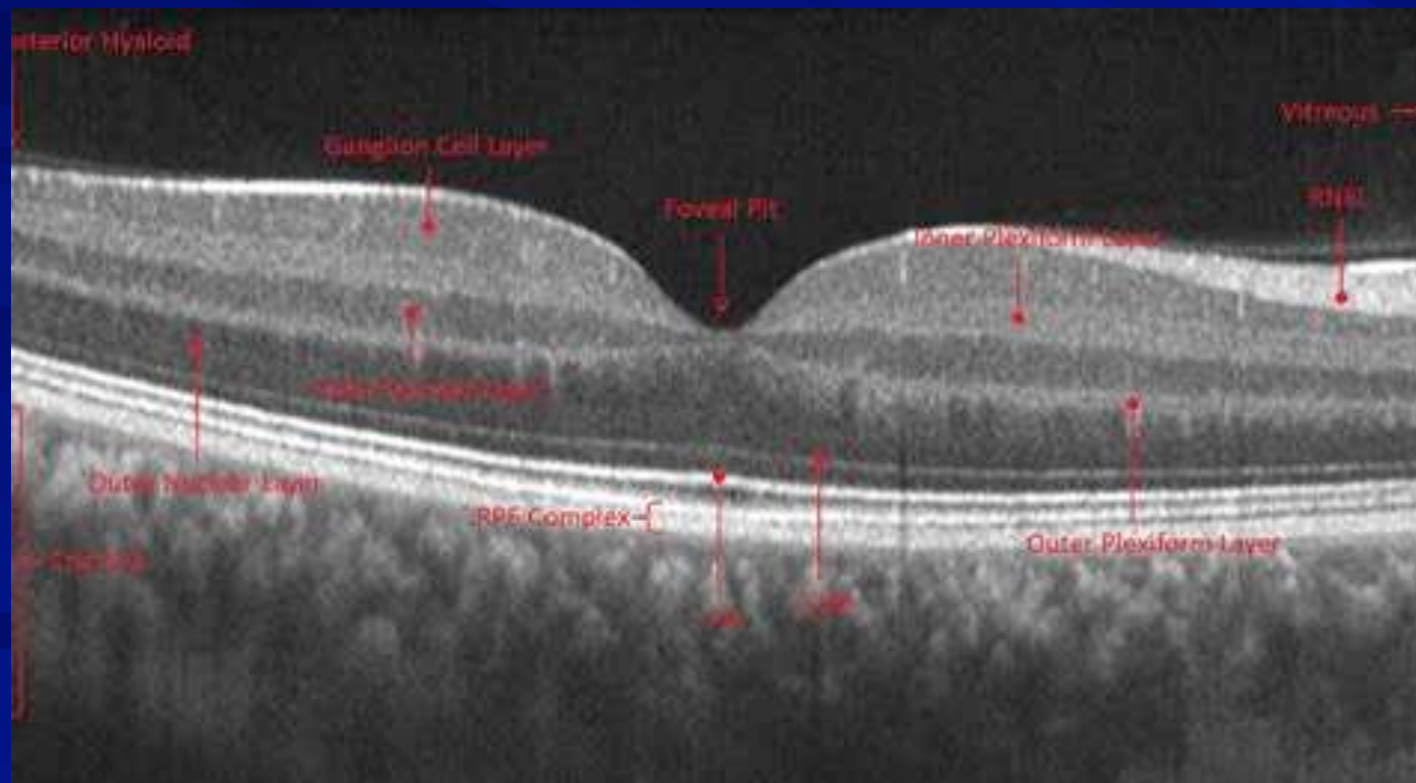
RPE Secretes even more cholesterol and degenerates

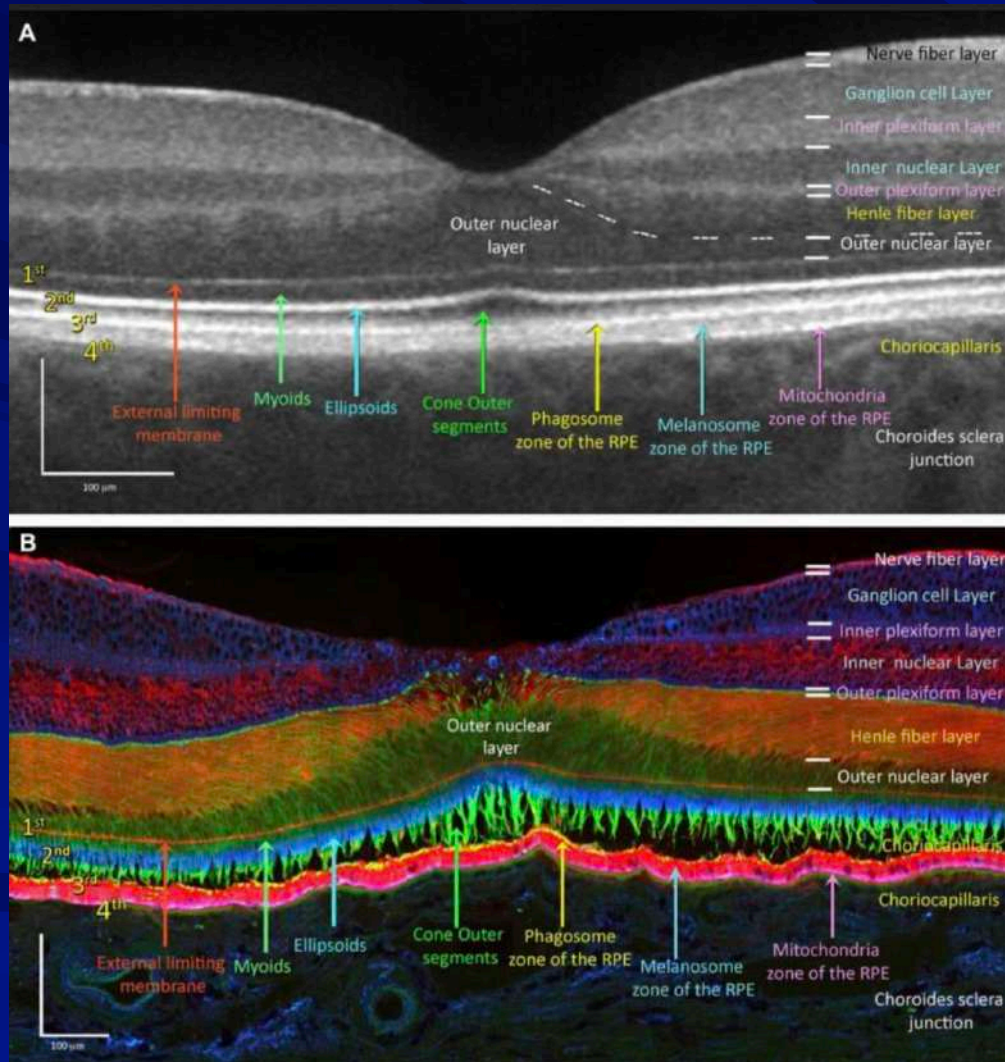


Finally, visibly evident drusen on fundus evaluation



The ellipsoid zone (EZ) is considered to be formed mainly by mitochondria within the ellipsoid layer of the outer portion of the inner segments of the photoreceptors. However, it was previously known as the junction between the photoreceptor IS/OS).





Progress in Retinal and Eye Research

Volume 77, July 2020, 100828

Interpretation of OCT and OCTA images from a histological approach: Clinical and experimental implications

Nicolás Cuenca ^{a, b, 1} ... Isabel Pinilla ^{f, 1}

Show more

Outline | Share | Cite

<https://doi.org/10.1016/j.preteyeres.2019.100828>

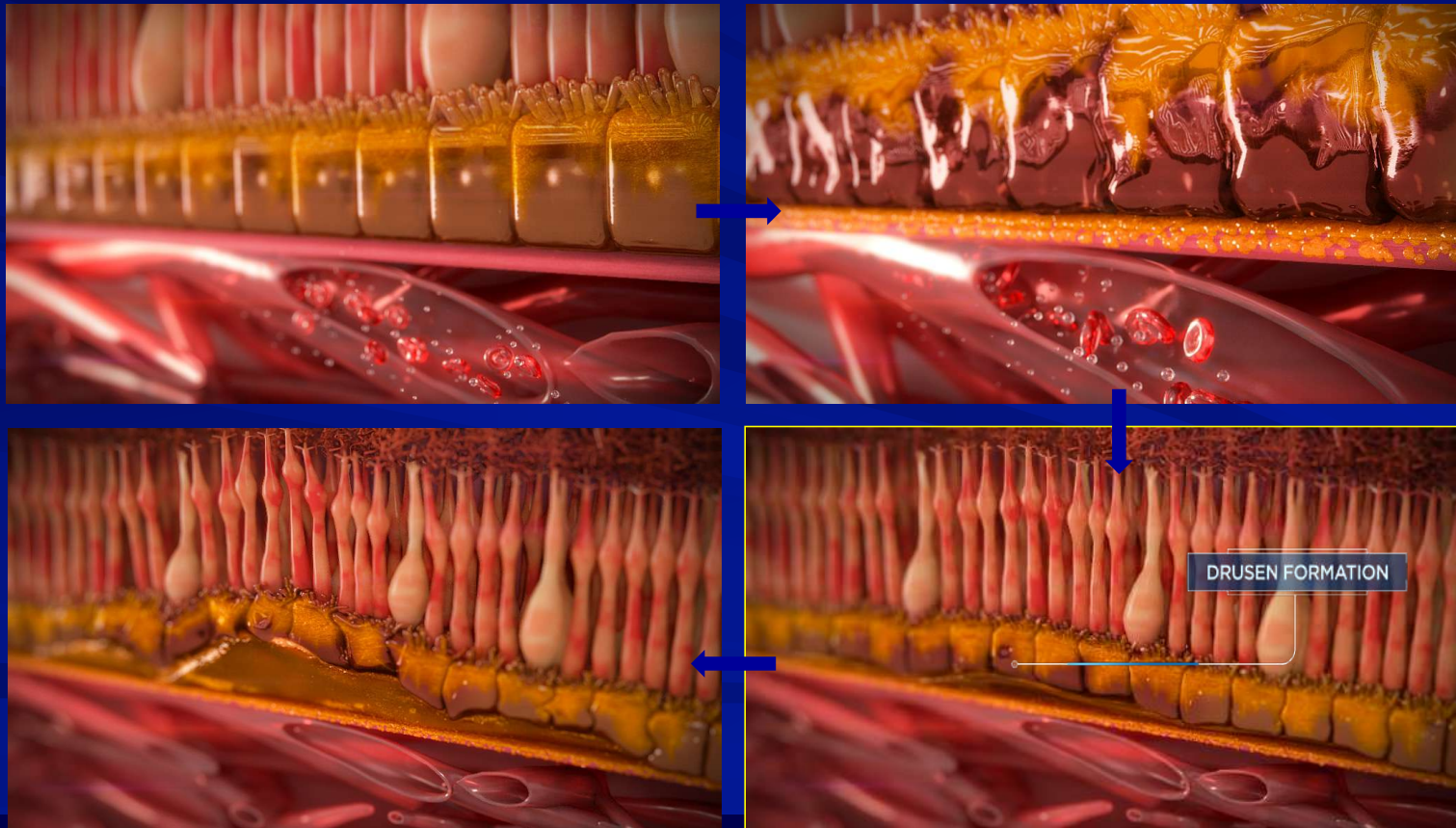
Get rights and content

Abstract

Optical coherence tomography (OCT) and OCT angiography (OCTA) have been a techn

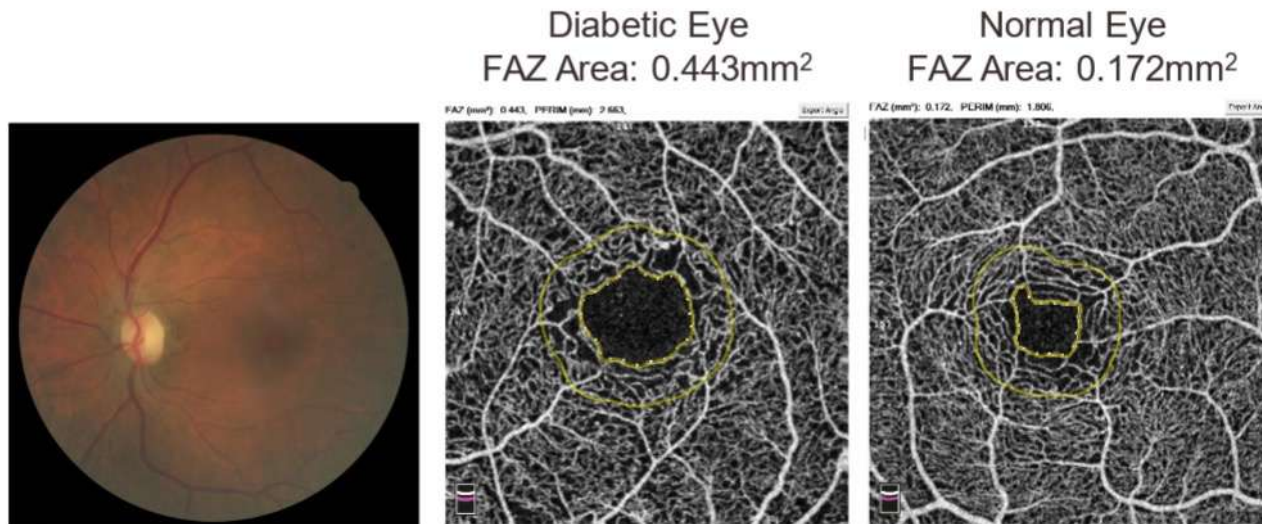
FEEDBACK

AMD is a Disease Process that Starts Below the Surface



Identify Early Vascular Changes in Diabetic Eyes

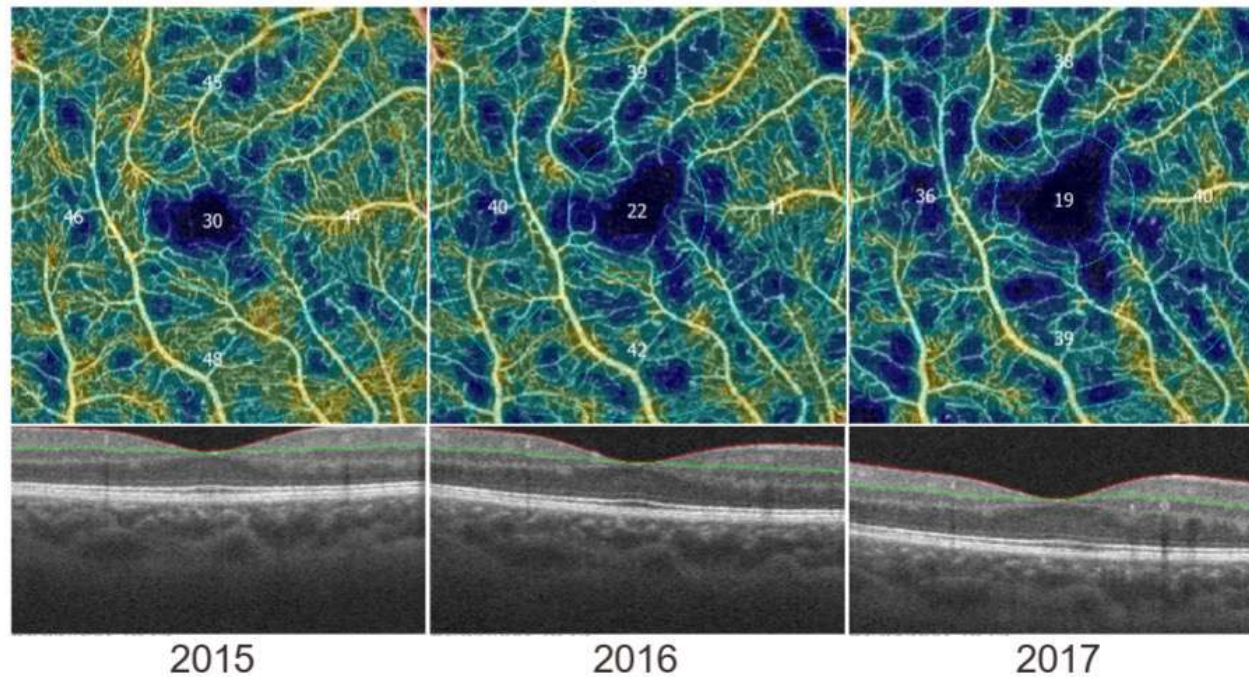
Patients with DM have a larger FAZ than healthy eyes.³



3. Di, G., Weihong, Y., Xiao, Z. et al. Graefes Arch Clin Exp Ophthalmology (2016) 254: 873. <https://doi.org/10.1007/s00417-015-3143-7>
Images courtesy of Julie Rodman, OD, FAAO

Assess Disease Progression with Multiscan View

Vessel Density Decreases Significantly with Disease Severity⁴



4. Nesper PL, Roberts PK, Onishi AC, et al. Quantifying Microvascular Abnormalities With Increasing Severity of Diabetic Retinopathy Using Optical Coherence Tomography Angiography. *Investigative Ophthalmology & Visual Science*. 2017;58(6):BIO307-BIO315. doi:10.1167/iov.17-21787.

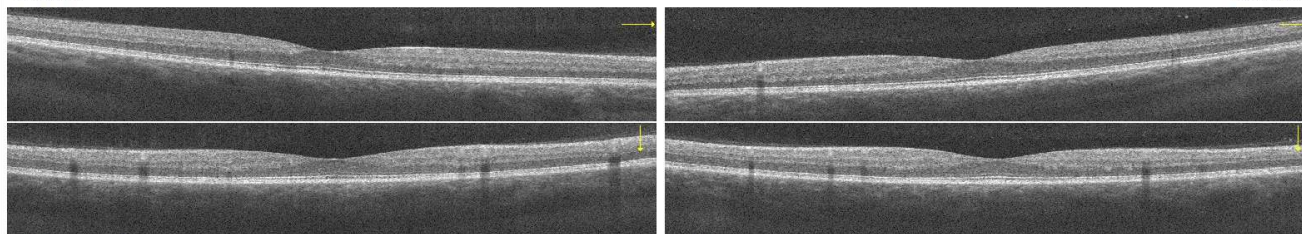
AngioWellness Report

Patient with Diabetes

Right / OD
12/19/2018

Avanti Wellness OU Report

Left / OS
12/19/2018

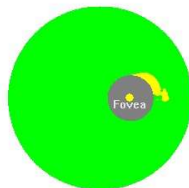
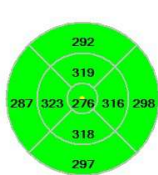
Full Retinal Thickness

NDB Reference Map

Auto Zoom

Full Retinal Thickness

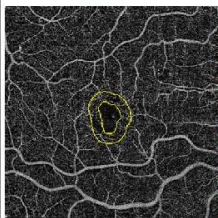


15:29:35

Retina

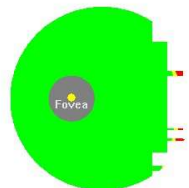
15:29:44

Superficial



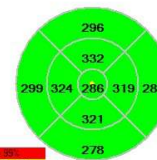15:29:11

GCC Analysis	OD	OS	OD - OS
Average GCC (μm)	96	96	0
Superior GCC (μm)	93	95	-2
Inferior GCC (μm)	100	97	3
Intra Eye (S-I) (μm)	-7	-2	N/A
FLV (%)	0.76	0.42	0.34
GLV (%)	1.60	3.03	-1.43



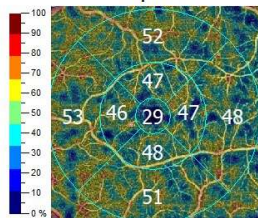
15:31:52

Superficial



15:31:42

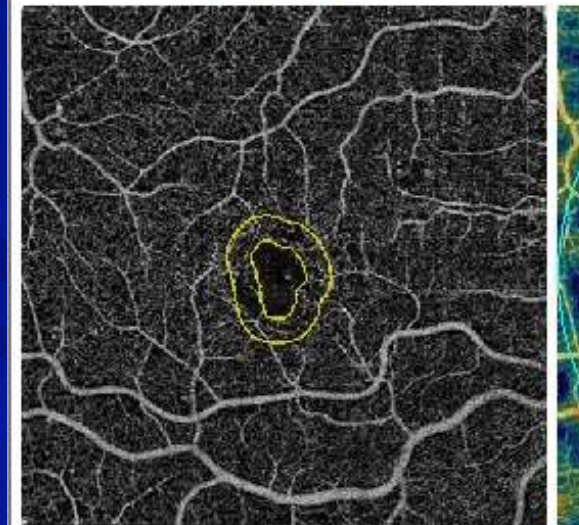
Retina



15:31:16

Vessel Density (%)	OD	OS	OD - OS
Superior_Hemi	48.4	49.3	-0.9
Inferior_Hemi	47.4	49.4	-2.0
Whole Image	47.9	49.4	-1.5
ETDRS Grid	47.4	49.4	-2.0
FAZ	OD	OS	OD - OS
Area (mm ²)	0.35	0.20	0.15
Perimeter (mm)	2.44	1.90	0.54
FD (%)	48.8	49.7	-0.9

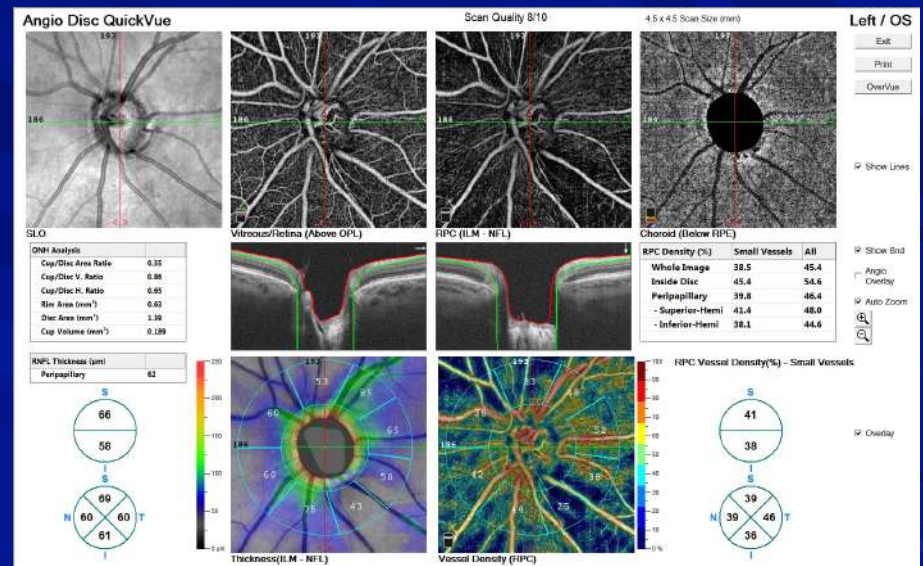
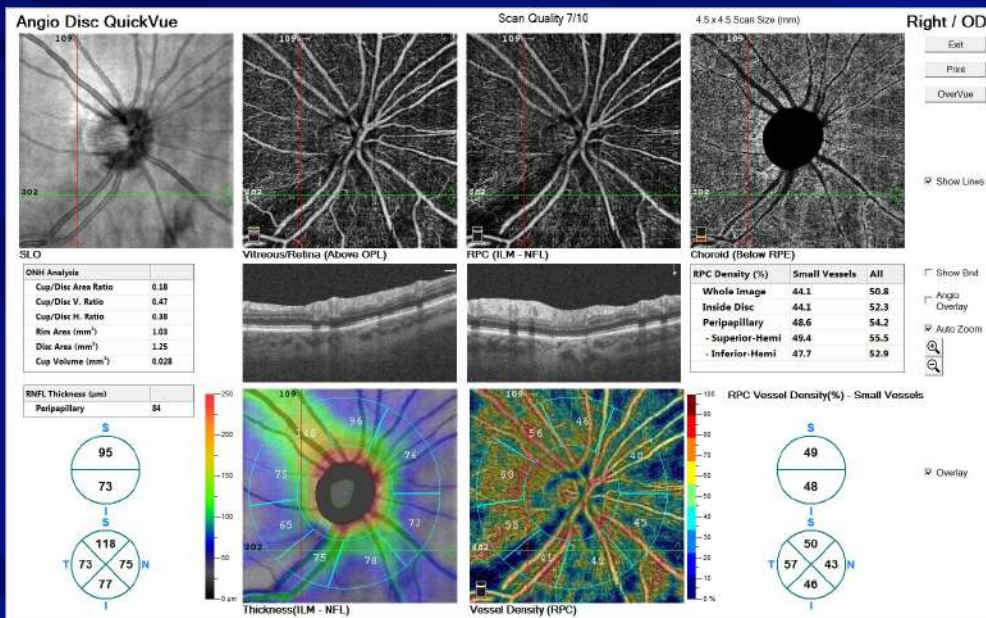
Retina



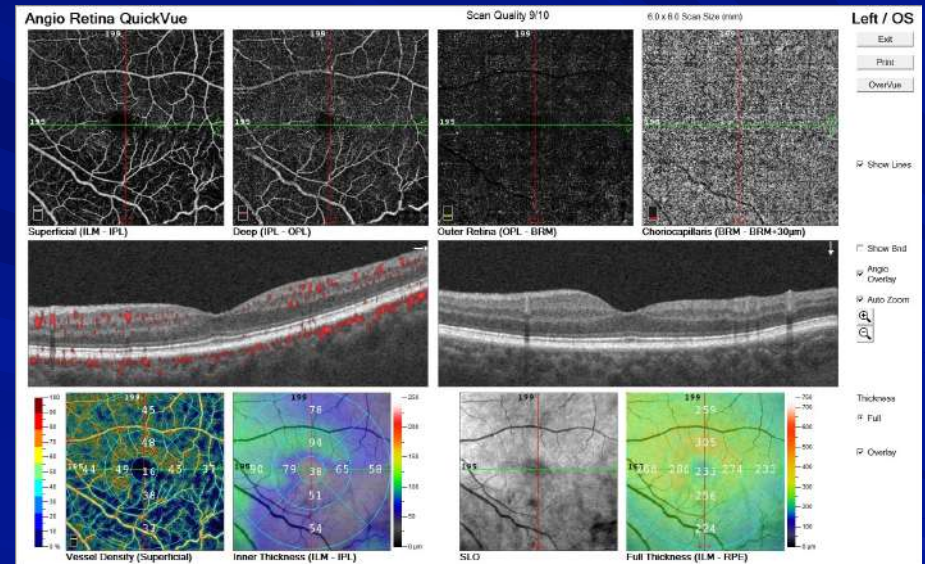
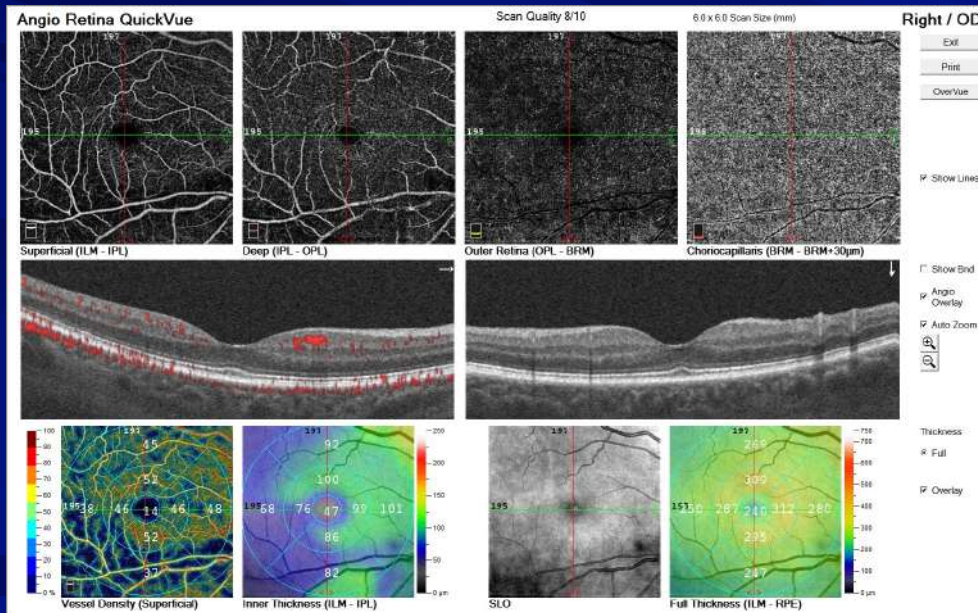
15:29:11

Print

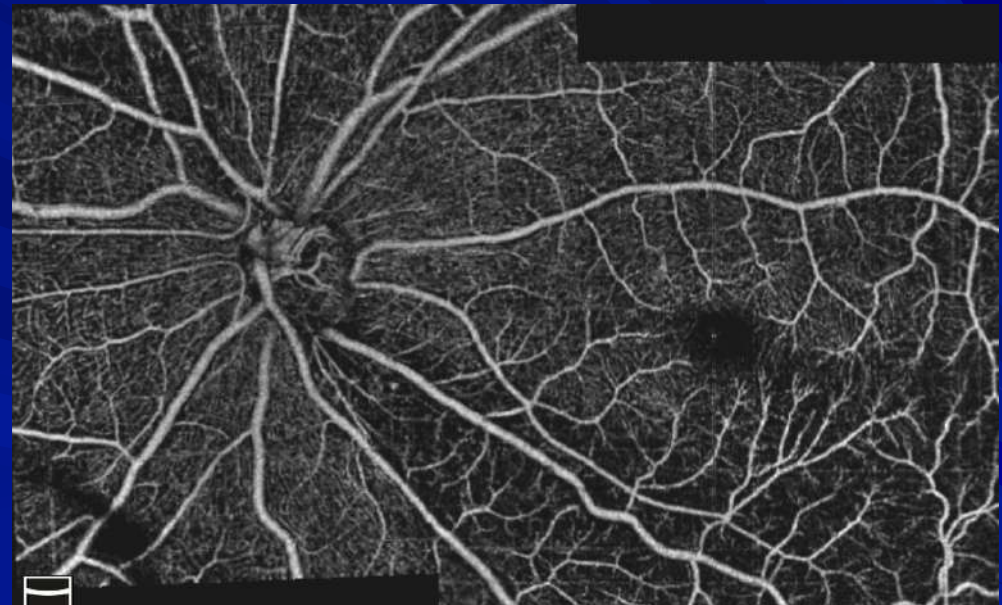
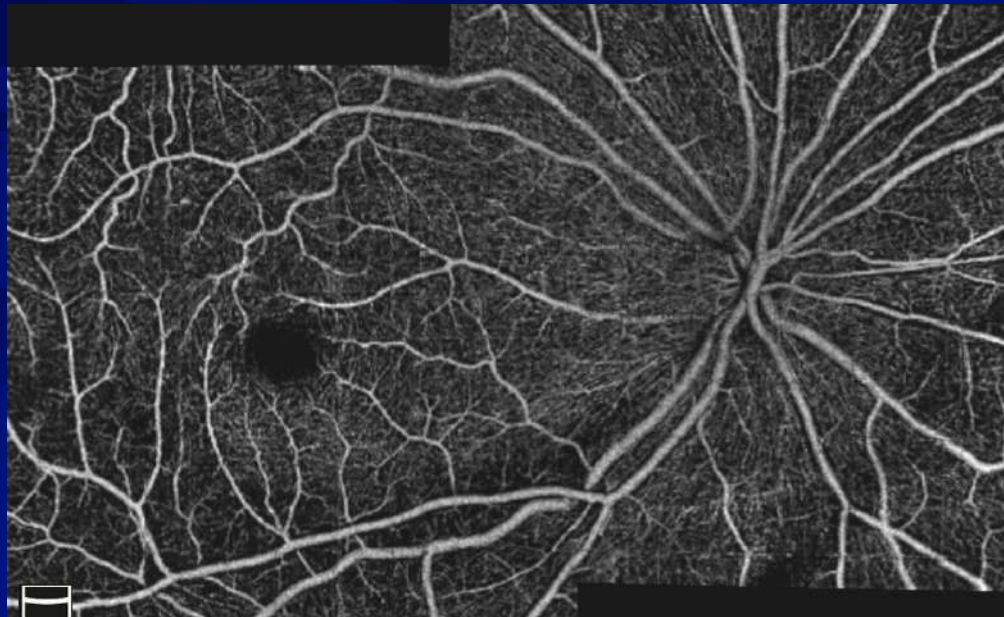Angiography and AngioAnalytics of Disc



Angiography and AngioAnalytics of Retina



Montage OU



Randomized Controlled Trial > Br J Ophthalmol. 2016 Feb;100(2):227-34.

doi: 10.1136/bjophthalmol-2014-306534. Epub 2015 Jun 18.

The Diabetes Visual Function Supplement Study (DiVFuSS)

A Paul Chous¹, Stuart P Richer², Jeffrey D Gerson³, Renu A Kowluru⁴

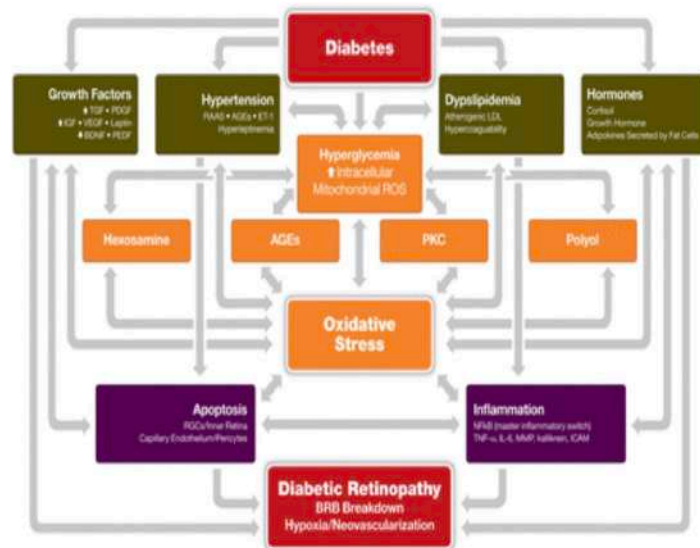
Affiliations + expand

PMID: 26089210 PMCID: PMC4752618 DOI: 10.1136/bjophthalmol-2014-306534

[Free PMC article](#)

PATHWAYS CONTRIBUTING TO DIABETIC RETINOPATHY

USED WITH PERMISSION
A. PAUL CHOUS, MD, PhD



DiVFuSS Constituents	Mitigates DR in animal models	Blocks capillary cell apoptosis	Improves retinal capillary fragility	Reduces VEGF	Reduces oxidative stress	Reduces AGE activity	Reduces Polyol activity	Reduces PKC activity	Reduces NF-κB
Alpha-Lipoic Acid	*		*	*	*				*
Berberine	*	*				*	*	*	*
Vitamins C/E	*				*		*		*
Curcumin	*			*	*	*			*
Vitamin D3	*			*					
DHA/EPA	*	*			*				
Grape Seed Extract	*	*			*	*			
Resveratrol	*	*			*				
Green Tea Extract	*			*					
N-Acetyl Cysteine	*			*	*				
CoQ10					*				
Zinc	*								
Pycnogenol	*		*		*				*
Lutein/Zeaxanthin	*			*	*				*

DiVFuSS Constituents	Improves visual function in humans	Reduces retinal edema in humans	Improves endothelial dysfunction in humans	Improves retinal blood flow in humans	Reduces HbA1c in humans	Improves Dyslipidemia in humans	Reduces blood pressure in humans	Reduces DPN symptoms in humans
Alpha-Lipoic Acid			*	*				*
Berberine			*			*		*
Vitamins C/E			*	*		*		
Curcumin	*	*	*	*				
Vitamin D3					*	*	*	
DHA/EPA			*				*	
Grape Seed Extract								
Resveratrol			*		*			
Green Tea Extract			*			*	*	
N-Acetyl Cysteine								
CoQ10			*					
Zinc						*		
Pycnogenol	*	*		*	*	*	*	*
Lutein/Zeaxanthin	*	*						

Note: Suggested improvements marked by * include published evidence in animal and/or cell models, except as specifically noted, but do not reflect grading of that evidence.

Download figure

Review > [Nutrients](#). 2019 Apr 2;11(4):771. doi: 10.3390/nu11040771.

Nutraceuticals for the Treatment of Diabetic Retinopathy

Maria Grazia Rossino ¹, Giovanni Casini ² ³

Affiliations + expand

PMID: 30987058 PMCID: [PMC6520779](#) DOI: [10.3390/nu11040771](#)

[Free PMC article](#)

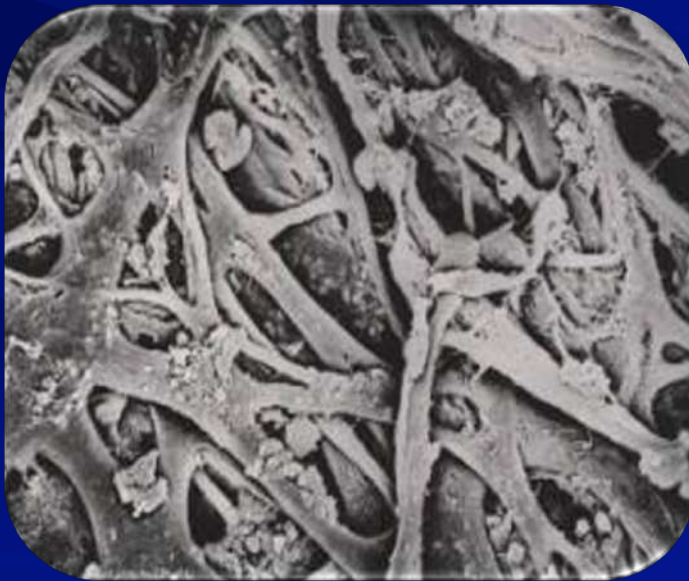Abstract

Diabetic retinopathy (DR) is one of the most common complications of diabetes mellitus and is characterized by degeneration of retinal neurons and neoangiogenesis, causing a severe threat to vision. Nowadays, the principal treatment options for DR are laser photocoagulation, vitreoretinal surgery, or intravitreal injection of drugs targeting vascular endothelial growth factor. However, these treatments only act at advanced stages of DR, have short term efficacy, and cause side effects. Treatment with nutraceuticals (foods providing medical or health benefits) at early stages of DR may represent a reasonable alternative to act upstream of the disease, preventing its progression. In particular, in vitro and in vivo studies have revealed that a variety of nutraceuticals have significant antioxidant and anti-inflammatory properties that may inhibit the early diabetes-driven molecular mechanisms that induce DR, reducing both the neural and vascular damage typical of DR. Although most studies are limited to animal models and there is the problem of low bioavailability for many nutraceuticals, the use of these compounds may represent a natural alternative method to standard DR treatments.

Keywords: carotenoids; flavonoids; inflammation; microvascular lesions; neoangiogenesis; oxidative stress; polyphenols; retina; saponins.

Disease at the TM is responsible for elevated IOP in glaucoma^{1,2}

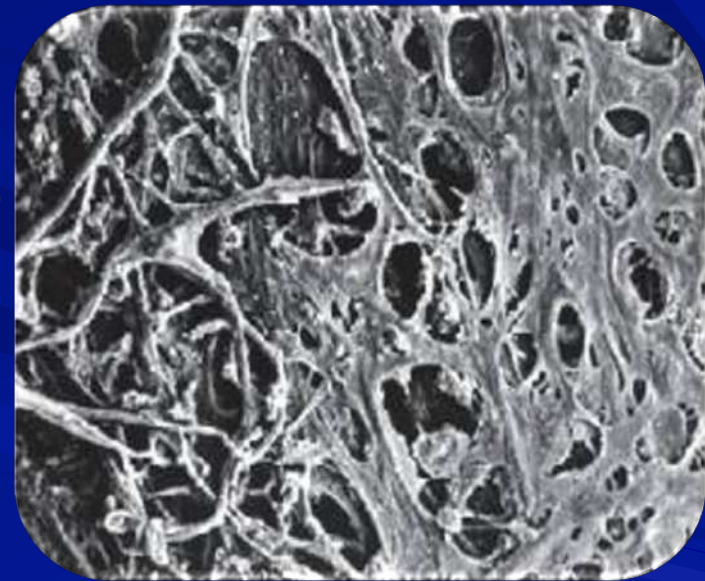
Healthy TM
Normal IOP



Cellular Damage
(eg, Oxidative Stress)



POAG TM Stiffness
Elevated IOP



Scanning electron microscopy (2000x) was used to examine human TM under physiological conditions and in patients with POAG.²

POAG, primary open-angle glaucoma; TM, trabecular meshwork.

1. He et al. *Invest Ophthalmol Vis Sci.* 2008;49:1447.

2. Saccà et al. *J Cell Physiol.* 2015;230:510.

Glaucoma

PERSPECTIVES ON GLAUCOMA

Antioxidants enhance ocular perfusion in Open Angle Glaucoma

Harris A, et al. Acta Ophthalmol. 2018;doi:10.1111/aos.13530.

“In agreement with previous findings, our results indicate that the supplementation of certain antioxidants may increase blood supply to the orbit and within retinal capillary beds following 4 weeks administration,” the authors wrote. “Our data suggest [oral antioxidant supplementation](#) may decrease vascular resistance over a longer period of time than previous trials investigated.”



Sissy D. Johns · 2nd

1w · 🌐

The development of atherosclerotic plaque, or atheroma, involves a multistep process:

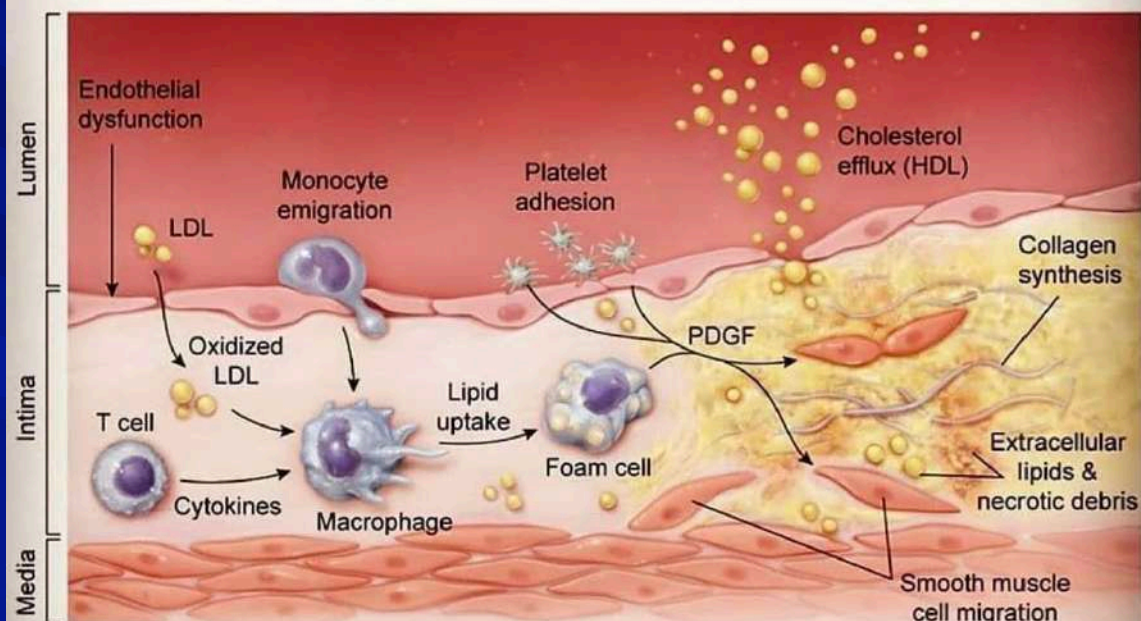
Initially, factors including hyperlipidemia, hypertension, hyperglycemia, and smoking trigger endothelial injury and/or dysfunction. This leads to increased vascular permeability, enhanced leukocyte adhesion, and a higher propensity for thrombosis.

Lipoproteins (ie, LDL and oxidized LDL) enter the arterial wall intima and begin to accumulate. Monocytes adhere to the endothelial wall and enter into the intima as well; these cells transform into macrophages and engulf lipid particles to become foam cells. Platelets adhere to the abnormal endothelium and become activated.

Growth factors, namely platelet-derived growth factor (PDGF), are released from platelets, activated macrophages, and endothelial cells. This triggers smooth muscle cell (SMC) recruitment from the media and proliferation in the intima.

See less

Formation of atheroma



PDGF = platelet-derived growth factor.

Treatments for AMD

🕒 Early detection and meaningful treatments with significant value, do not cure, but have been shown to slow or halt progression. Not limited to early stages but all stages of AMD

- ★ Prescribe smoking cessation programs

- 📋 Smoking and AMD

- Depletes serum antioxidants
 - Decreases pigmentary density
 - Increases risk to advanced AMD

- ★ Lifestyle changes

- 📋 Diet

- 📋 Exercise

- ★ Systemic disease management

- 📋 Cardiovascular disease, DM, obesity, high cholesterol

Treatment for AMD

Nutritional supplements

- ★ Sub-clinical/sub-structural or early disease
 - ☐ Controversy flourishes
 - No definitive guideline exists
 - Despite consensus evidence suggests using supplements
- ★ Intermediate – advance disease
 - ☐ No controversy on advocating for supplements
- ★ AREDS 1
 - ☐ Contains Beta-carotene and no lutein or zeaxanthin, no longer recommended
 - ☐ Investigated early AMD, no statistically significant benefit
- ★ AREDS 2
 - ☐ Recommended for intermediate and advanced AMD, study protocol
- ★ The Practical Guide for the Treatment of AMD - 3 primary options
 - ☐ Macular pigment supplement
 - Carotenoids: lutein, zeaxanthin, meso-zeaxanthin
 - ☐ Carotenoids, antioxidants, zinc, and vitamins C & E
 - AREDS 2
 - ☐ Carotenoid macular supplement in subclinical and early AMD. Carotenoid and antioxidant is intermediate and AMD that is progressing

Measuring Macular Pigment

👁️ Retina macula biopsy

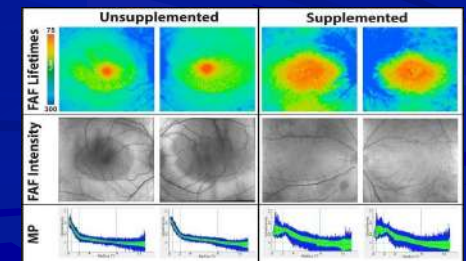
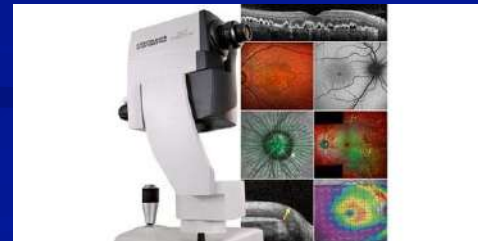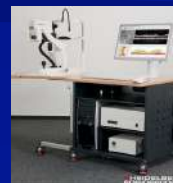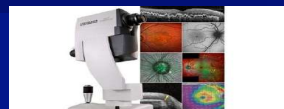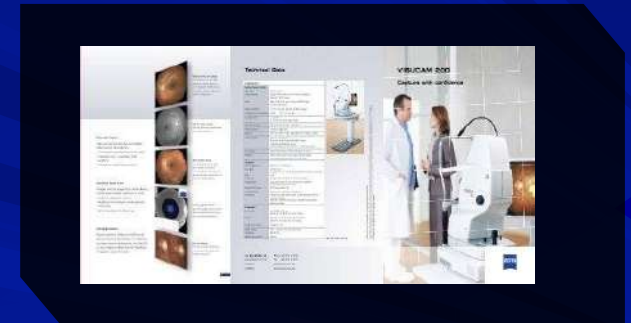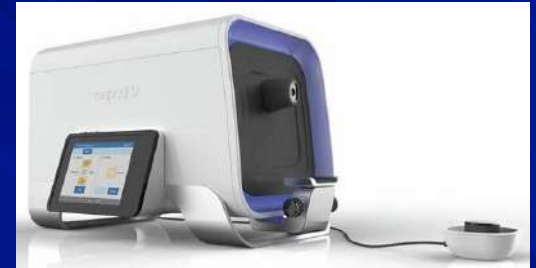👁️ Clinical Imaging

★ Subjective

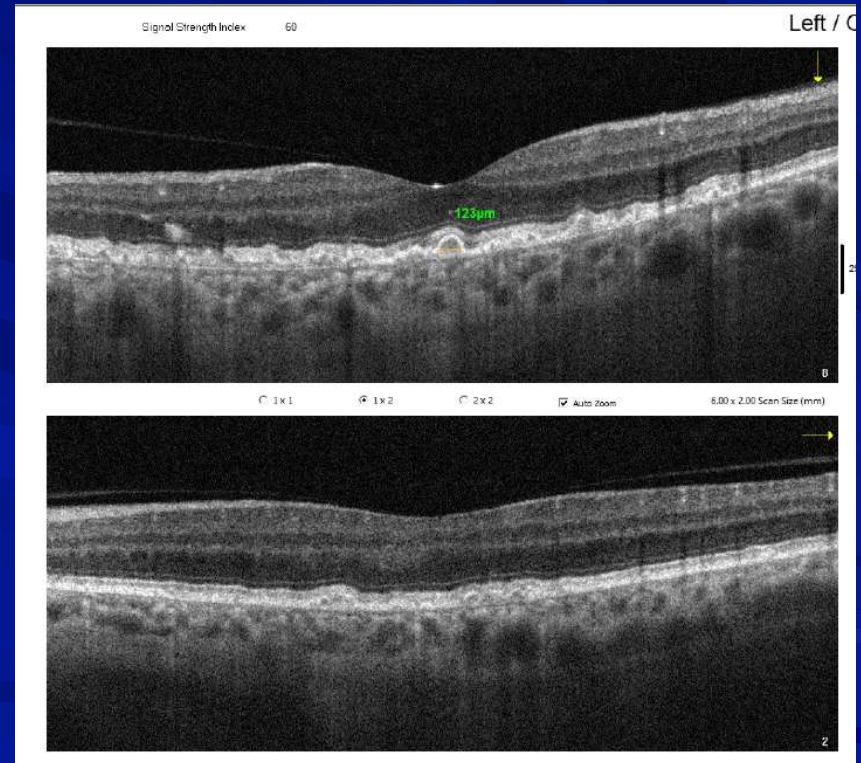

- 📋 ZeaVision MPSII
- 📋 Guardion Mapcat SF

★ Clinical

- 📋 ZeaVision MPR
- 📋 Zeiss Visucam 200
- 📋 Spectralis HRA+OCT
- 📋 Spectralis MPOV



Macular Pigment



Macular Pigment

Imaging lutein and zeaxanthin in the human retina with confocal resonance Raman microscopy

Binxing Li^a, Evan W. George^a, Gregory T. Rognon^a, Aruna Gorusupudi^a, Arunkumar Ranganathan^a, Fu-Yen Chang^a, Linjia Shi^a, Jeanne M. Frederick^a, and Paul S. Bernstein^{a,1}

^aDepartment of Ophthalmology and Visual Sciences, Moran Eye Center, University of Utah School of Medicine, Salt Lake City, UT 84132

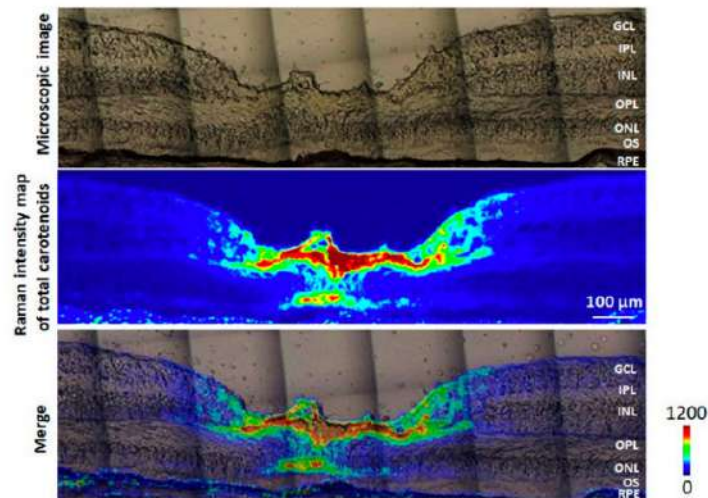
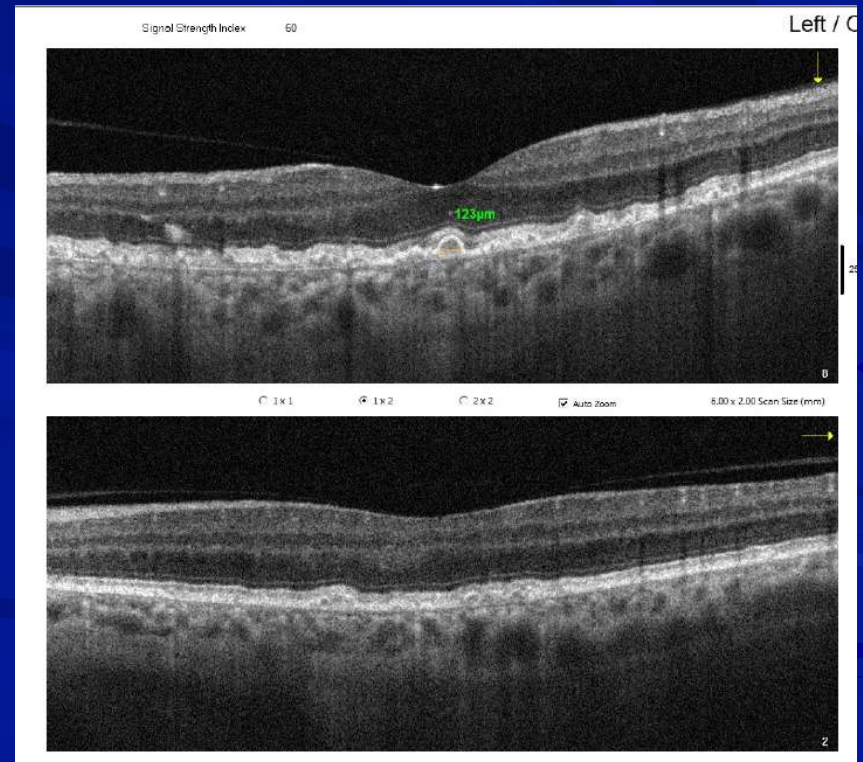


Fig. 4. Distribution of total carotenoids in a human retinal section. (Top) A



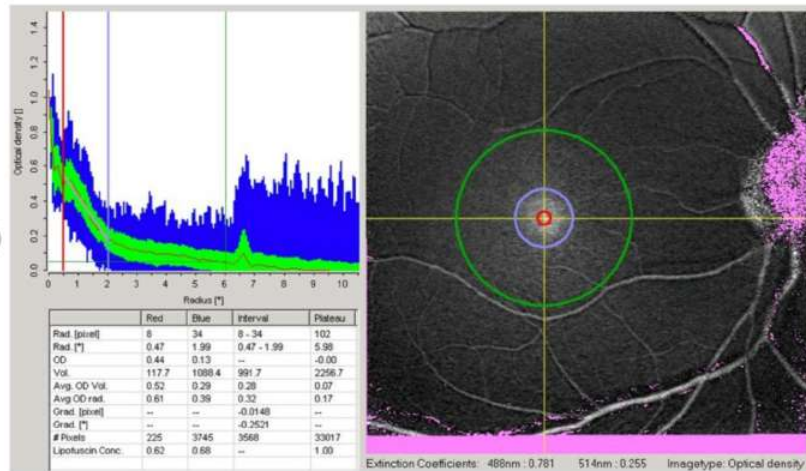
Macular Pigment and the Retina

Figure - uploaded by [Tiago Santos Prata](#)

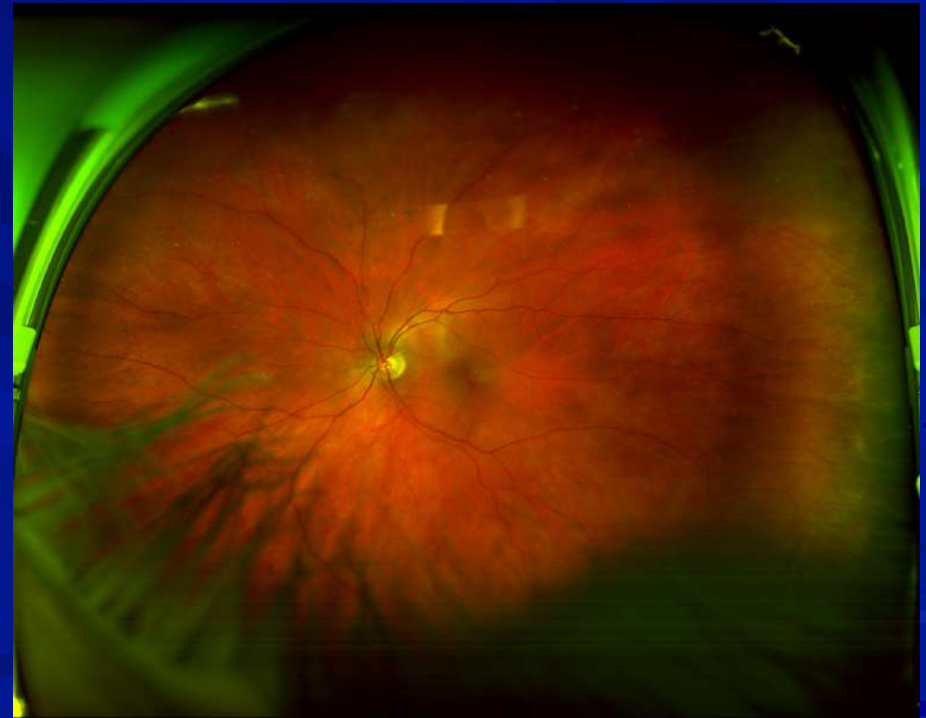
Content may be subject to copyright.

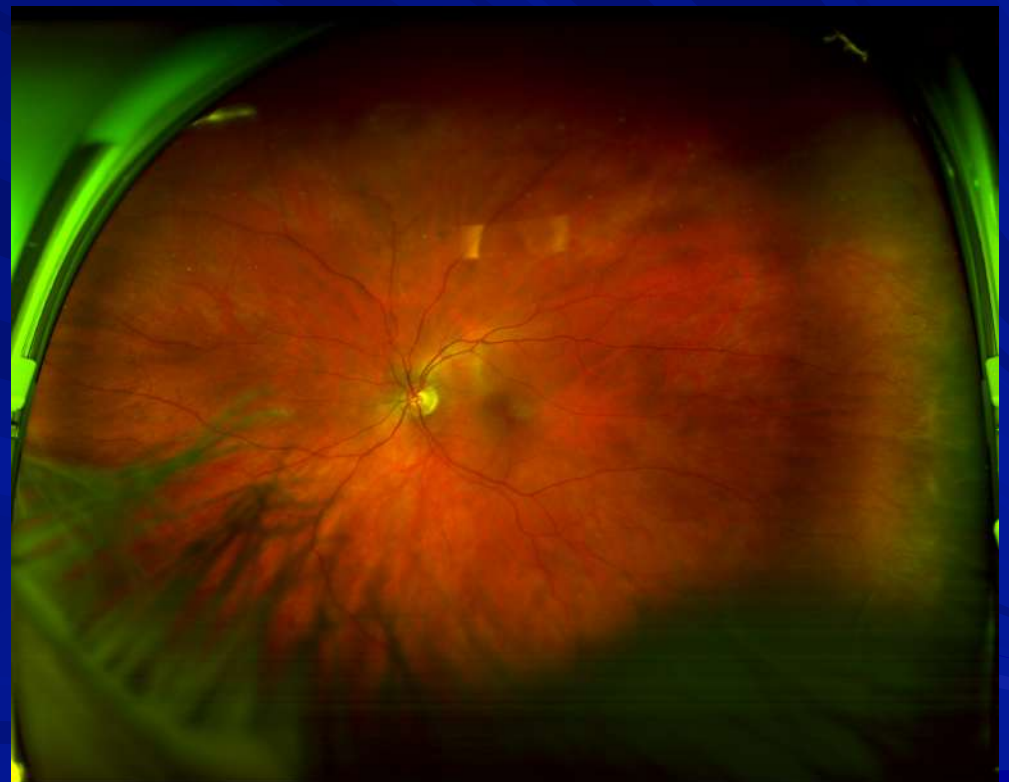
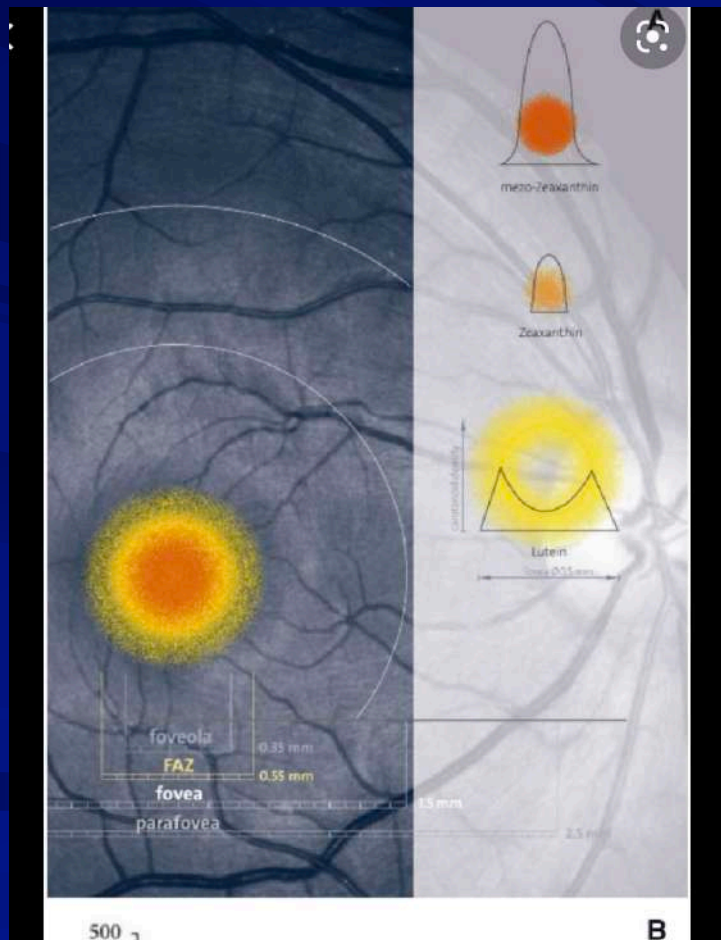
[Download](#)

[View publication](#)



Macular pigment optical density map of one eye included in the study. Notes: The image analyzed is demonstrated on the right side of the dialog. Two yellow lines mark the point used for radial analysis. The red and blue circles demarcate areas of 0.5 and 2.0 degrees from the center of the fovea, respectively. On the upper left side of the dialog there is a diagram with a normal radial distribution of macular pigment optical density around the center of the fovea. On the lower left side, the box shows numerical values for macular pigment optical density in the specific eccentricities analyzed.





Macular Pigment

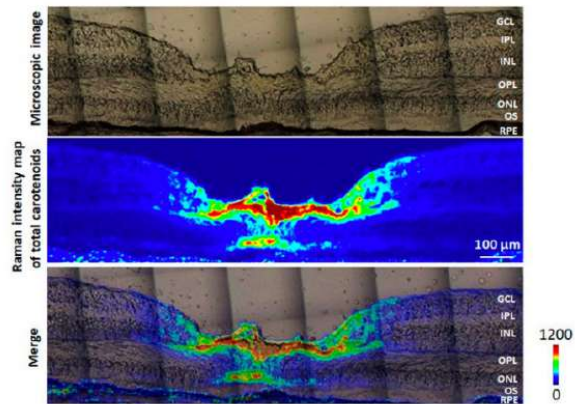
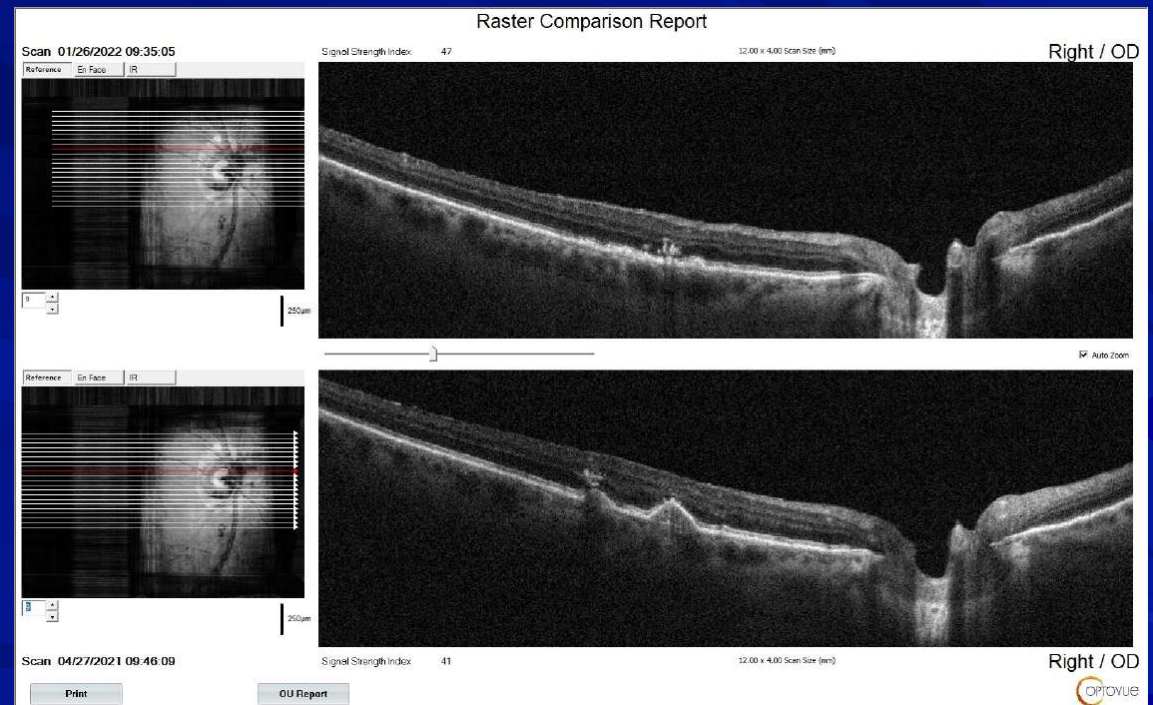
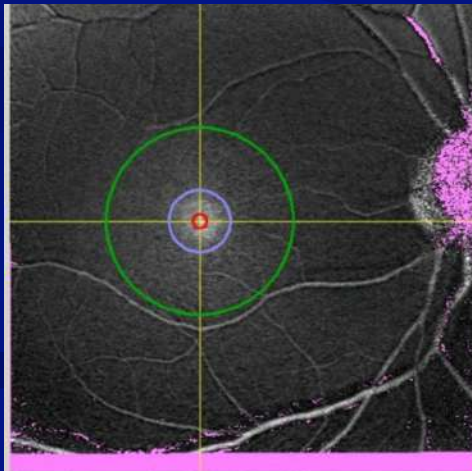


Fig. 4. Distribution of total carotenoids in a human retinal section. (Top) A microscopic image of a retinal section from a healthy 77-year-old female.



When it cold outside what are good for your feet and head?



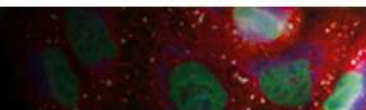Question

👁 Do you recommend resveratrol and quercetin antioxidants when treating ocular/retinal conditions?

★ Yes

★ No

Why Are We Only Treating Half the Retina?



Oxid Med Cell Longev. 2019; 2019: 9783429.

PMCID: PMC6390265

Published online 2019 Feb 12. doi: [10.1155/2019/9783429](https://doi.org/10.1155/2019/9783429)

PMID: [30891116](https://pubmed.ncbi.nlm.nih.gov/30891116/)

Health Benefits of Polyphenols and Carotenoids in Age-Related Eye Diseases

Simona Bungau,¹ Mohamed M. Abdel-Daim,^{2,3} Delia Mirela Tit,¹ Esraa Ghanem,⁴ Shimpei Sato,³ Maiko Maruyama-Inoue,³ Shin Yamane,³ and Kazuaki Kadonosono³

► Author information ► Article notes ► Copyright and License information [Disclaimer](#)

This article has been [cited by](#) other articles in PMC.

Abstract

Go to:

Oxidative stress and inflammation play a critical role in the initiation and progression of age-related ocular abnormalities as cataract, glaucoma, diabetic retinopathy, and macular degeneration. Therefore, phytochemicals with proven antioxidant and anti-inflammatory activities, such as carotenoids and polyphenols, could be of benefit in these diseases. We searched PubMed and Web of Science databases for original studies investigating the benefits of different carotenoids and polyphenols in age-related ophthalmic diseases. Our results showed that several polyphenols (such as anthocyanins, *Ginkgo biloba*, quercetin, and resveratrol) and carotenoids (such as lutein, zeaxanthin, and mezoanthin) have shown significant preventive and therapeutic benefits against the aforementioned conditions. The involved mechanisms in these findings include mitigating the production of reactive oxygen species, inhibiting the tumor necrosis factor- α and vascular endothelial growth factor pathways, suppressing p53-dependent apoptosis, and suppressing the production of inflammatory markers, such as interleukin- (IL-) 8, IL-6, IL-1 α , and endothelial leucocyte adhesion molecule-1. Consumption of products containing these phytochemicals may be protective against these diseases; however, adequate human data are lacking. This review discusses the role and mechanisms of polyphenols and carotenoids and their possible synergistic effects on the prevention and treatment of age-related eye diseases that are induced or augmented by oxidative stress and inflammation.

Carotenoids and Polyphenols

www.oncotarget.com

Oncotarget, 2018, Vol. 9, (No. 24), pp: 17181-17198

Review

Oxidative stress: role of physical exercise and antioxidant nutraceuticals in adulthood and aging

Carolina Simioni¹, Giorgio Zauli¹, Alberto M. Martelli², Marco Vitale^{3,4}, Gianni Sacchetti⁵, Arianna Gonelli¹ and Luca M. Neri¹

¹Department of Morphology, Surgery and Experimental Medicine, University of Ferrara, Ferrara, Italy

²Department of Biomedical and Neuromotor Sciences, University of Bologna, Bologna, Italy

³Department of Medicine and Surgery, University of Parma, Parma, Italy

⁴CoreLab, Azienda Ospedaliero-Universitaria di Parma, Parma, Italy

⁵Department of Life Sciences and Biotechnology, Pharmaceutical Biology Laboratory, University of Ferrara, Ferrara, Italy

Correspondence to: Luca M. Neri, email: luca.neri@unife.it

Keywords: exercise training; nutraceuticals; flavonoids intake; aging; antioxidant supplementation

Received: January 26, 2018

Accepted: March 08, 2018

Published: March 30, 2018

Copyright: Simioni et al. This is an open-access article distributed under the terms of the Creative Commons Attribution License 3.0 (CC BY 3.0), which permits unrestricted use, distribution, and reproduction in any medium, provided the original author and source are credited.

Resveratrol can be implied in anti-aging actions by influencing the mitochondrial environment and metabolic diseases, by regulating the levels of some inflammatory mediators and cytokines and by modulating lipolysis [125, 152, 153]. Mitochondrial dysfunction has been proved to be associated with aging and disease development [154], and it was seen

Furthermore, resveratrol maintains the vascular fitness through its antioxidant and anticoagulant activities, and on the other hand is relevant in blocking the formation of new blood vessels, in inhibiting the VEGF release and attenuating Hypoxia-Inducible Factor (HIF-1 α) in different tumor cells [163].

It is reported that also curcumin possesses anti-

ASSESSMENT OF CAROTENOIDS

Impact of Carotenoid Assessment

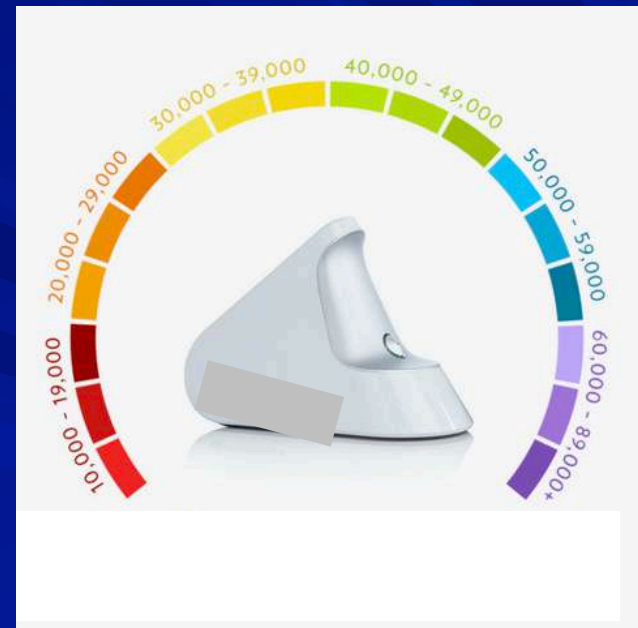Because carotenoids appear to play a key role in retinal diseases, intensive research has resulted in a variety of innovative carotenoid assessment techniques. The breadth of possibilities for assessing retinal carotenoids is often confusing because methodologies, units of measurement, and the presentation of results vary widely. Accurate readings of carotenoid status are important in order to correctly advise individuals with regards to supplementation. Furthermore, in diseases such as macular telangiectasia type 2 (MacTel), the assessment of carotenoids may be crucial to the diagnosis, as reduced MP levels as well as abnormal distributions are among the first signs of the disease. Therefore, the measurement of carotenoids can impact clinical practice, and the evaluation of MP may eventually become an integral part of comprehensive ophthalmological care. The following sections describe and aim to give an organized overview of different MP assessment techniques.

A large variety of methods are used to assess carotenoid status in humans, most of which are focused on the eye, but carotenoids can also be measured in tissue outside of the eye, such as the skin, blood, and the brain. Measurements of ocular carotenoids can be distinguished between subjective (psychophysical) and objective (optical) methods used to assess the amount of MP. In subjective methods, a direct answer from the patient is required, whereas objective measurement methods typically require just enough cooperation to generate an image (73).

Measuring Carotenoids and the Macular Pigment

Biophotonic Scanner

- ★ Measures carotenoids
- ★ Based on an optical method known as Resonant Raman Spectroscopy (RSS)
 - 📋 Used for many years in research laboratories
- ★ Skin RRS measurements
 - 📋 Noninvasive
 - 📋 Objective
 - 📋 Reliable methods to assess carotenoid levels
 - Ocular
 - Systemic



Carotenoid Levels



Scanner correlates to blood and macular pigment

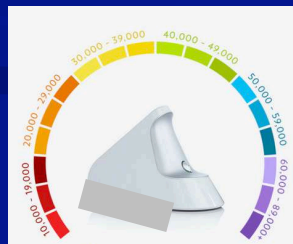
read study

👓 Biomarker of health for diet and lifestyle

★ Yale University

👓 Phospholipid bi-layer

👓 Carotenoids, flavonoids, and polyphenols



Clinical and Epidemiologic Research

Correlations Between Macular, Skin, and Serum Carotenoids

Christopher D. Conrady,¹ James P. Bell,¹ Brian M. Besch,¹ Aruna Gorusupudi,¹ Kelliann Farnsworth,¹ Igor Ermakov,² Mohsen Sharifzadeh,² Maia Ermakova,² Werner Gellermann,^{1,2} and Paul S. Bernstein¹

¹Department of Ophthalmology and Visual Sciences, Moran Eye Center, Salt Lake City, Utah, United States

²Image Technologies Corporation, Salt Lake City, Utah, United States

Correspondence: Paul S. Bernstein, Moran Eye Center, University of Utah School of Medicine, 65 Mario Capecchi Drive, Salt Lake City, UT 84132, USA; paul.bernstein@hsc.utah.edu.

Submitted: March 7, 2017
Accepted: June 18, 2017

Citation: Conrady CD, Bell JP, Besch BM, et al. Correlations between macular, skin, and serum carotenoids. *Invest Ophthalmol Vis Sci*. 2017;58:3616–3627. DOI:10.1167/ios.17.21818

Purpose. Ocular and systemic measurement and imaging of the macular carotenoids lutein and zeaxanthin have been employed extensively as potential biomarkers of AMD risk. In this study, we systematically compare dual wavelength retinal autofluorescence imaging (AFI) of macular pigment with skin resonance Raman spectroscopy (RRS) and serum carotenoid levels in a clinic-based population.

Methods. Eighty-eight patients were recruited from retina and general ophthalmology practices from a tertiary referral center and excluded only if they did not have all three modalities tested, had a diagnosis of macular telangiectasia (MacTel) or Stargardt disease, or had poor AFI image quality. Skin, macular, and serum carotenoid levels were measured by RRS, AFI, and HPLC, respectively.

Results. Skin RRS measurements and serum zeaxanthin concentrations correlated most strongly with AFI macular pigment volume under the curve (MPVUC) measurements up to 9° eccentricity relative to MPVUC or rotationally averaged macular pigment optical density (MPOD) measurements at smaller eccentricities. These measurements were reproducible and not significantly affected by cataracts. We also found that these techniques could readily identify subjects taking oral carotenoid-containing supplements.

Conclusions. Larger macular pigment volume AFI and skin RRS measurements are noninvasive, objective, and reliable methods to assess ocular and systemic carotenoid levels. They are an attractive alternative to psychophysical and optical methods that measure MPOD at a limited number of eccentricities. Consequently, skin RRS and MPVUC at 9° are both reasonable biomarkers of macular carotenoid status that could be readily adapted to research and clinical settings.

Keywords: macular pigment, carotenoids, macula

The New Standard



Quick Test
(approx. 30 sec)

Portable

Cost Effective

Remeasure in 60 days

Reassurance to you and patient

Raman Spectroscopy



Resonance Raman spectroscopic evaluation of skin carotenoids as a biomarker of carotenoid status for human studies

Susan T. Mayne^{a,*}, Brenda Cartmel^a, Stephanie Scarmo^{a,b}, Lisa Jahns^c, Igor V. Ermakov^d, Werner Gellermann^d

^a Yale School of Public Health and Yale Cancer Center, 60 College Street, New Haven, CT 06510, USA

^b Center for Science in the Public Interest, 1220 L Street, Suite 300, Washington, DC 20004, USA

^c USDA/ARS Grand Forks Human Nutrition Research Center, 1020 2nd Avenue North, Grand Forks, ND 58203, USA

^d Department of Physics and Astronomy, University of Tennessee, Knoxville, TN 37996, USA

ARTICLE INFO

Article history:

Available online xxxx

Keywords:

Carotenoids

Skin

Resonance Raman spectroscopy

Beta-carotene

Biomarker

ABSTRACT

Resonance Raman spectroscopy is a non-invasive method that has been developed to assess carotenoid status in human tissues and human skin *in vivo*. Skin carotenoid status has been suggested as a promising biomarker for human studies. This manuscript describes research done relevant to the development of this biomarker, including its reproducibility, validity, feasibility for use in field settings, and factors that affect the biomarker such as diet, smoking, and adiposity. Recent studies have evaluated the response of the biomarker to controlled carotenoid interventions, both supplement-based and dietary [e.g., provision of a high-carotenoid fruit and vegetable (F/V)-enriched diet], demonstrating consistent response to intervention. The totality of evidence supports the use of skin carotenoid status as an objective biomarker of F/V intake, although in the cross-sectional setting, diet explains only some of the variation in this biomarker. However, this limitation is also a strength in that skin carotenoids may effectively serve as an integrated biomarker of health, with higher status reflecting greater F/V intake, lack of smoking, and lack of adiposity. Thus, this biomarker holds promise as both a health biomarker and an objective indicator of F/V intake, supporting its further development and utilization for medical and public health purposes.

*Arch Biochem Biophys. PMC 2014 Nov 15.

ARVO STUDY

Interrelationships between Macula, Skin and Serum Carotenoids- Paul Bernstein, Werner Gellerman et al
ARVO May 2016

Conclusions:

"Our results emphasize the importance of measuring the total amount of carotenoids in the macula region using an objective image based modality such as AFI w Spectralis rather than subjective MPOD."

Skin resonance Raman Spectroscopy of skin carotenoids is a reasonable biomarker of macula carotenoid status. and correlates better than than subjective MPOD tests.



The objective hand scanner is better than the subjective Macuscope, QuantifEYE, and Densitometer for estimating macula pigment.

Vulnerable to Oxidation

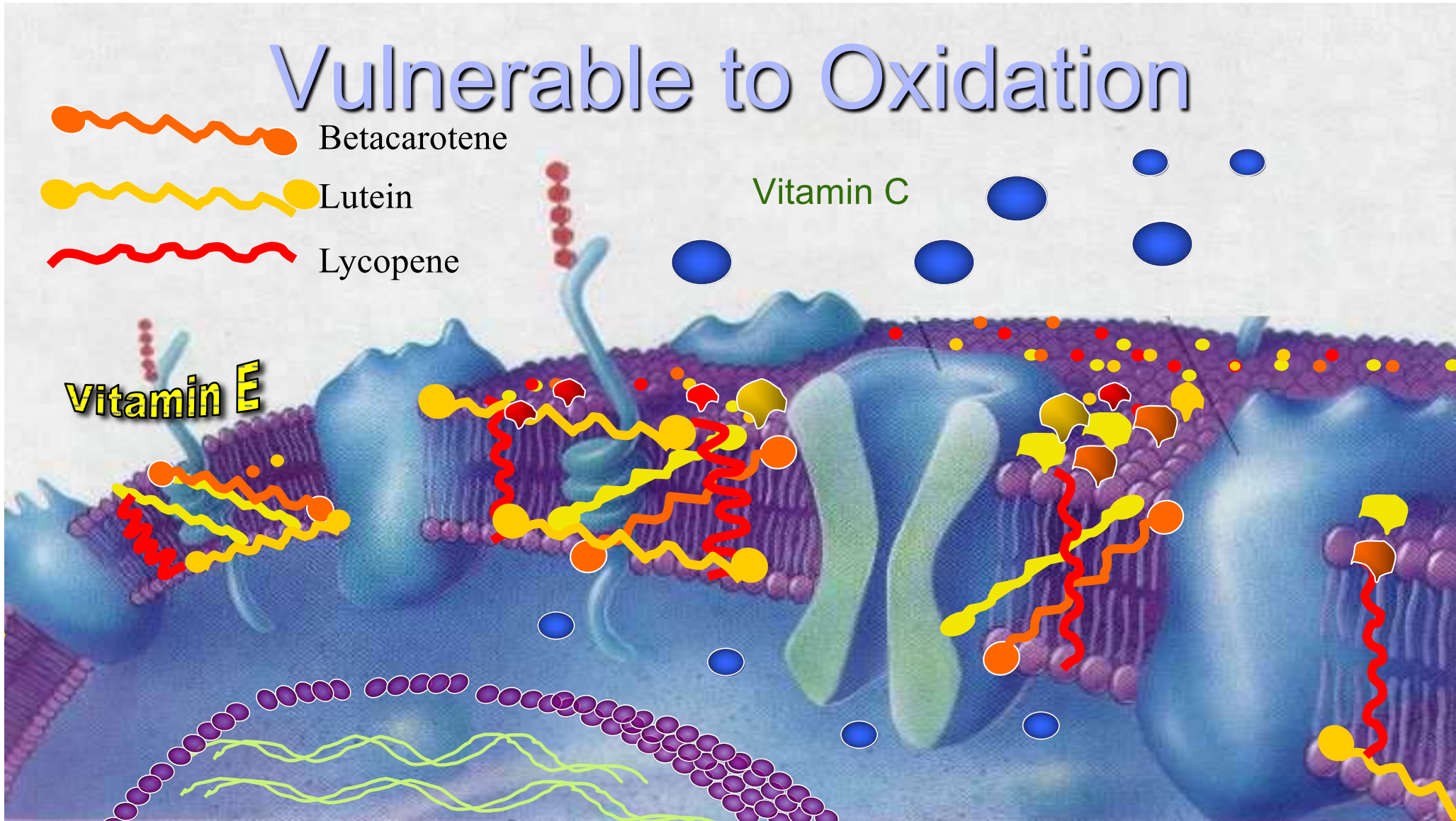
 Betacarotene

 Lutein

 Lycopene

Vitamin C

Vitamin E



The background is a solid dark blue with a pattern of lighter blue diagonal lines and streaks, creating a sense of motion or depth.

Are you taking a supplement?

53-year-old man

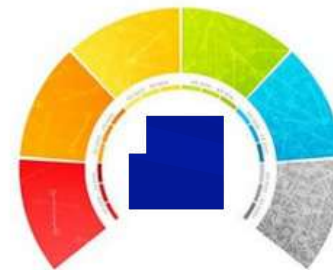- 👓 Family history of AMD
 - ★ Dad with 43 injections for AMD
- 👓 Pre-diabetic with borderline HbA1c
- 👓 Vision 20/20 OU
- 👓 DFE- retina clear
- 👓 OCT normal
- 👓 Passes dark adaptation

CONGRATULATIONS ON TAKING THE FIRST STEPS TOWARDS OPTIMIZING YOUR SCS

Dear [REDACTED]

Recently, on 12/15/2020, you met with me and I scanned the palm of your hand with the [REDACTED] BioPhotonic Scanner. Your scan returned a Skin Carotenoid Score (SCS) of 26000.

This score represents the current carotenoid level of your skin. The higher the score, the more carotenoids your body is receiving.



26000

Ingredients

Ingredients	Amount	% Daily Value
Serving Size: 1 Packet		
Vitamin A (83% as Beta Carotene (1875 mcg RAE) from <i>Blakeslea trispora</i> , and Vitamin A palmitate) (375 mcg RAE)	2250 mcg RAE	250%
Vitamin C (as Calcium Ascorbate)	200 mg	222%
Vitamin D (as Cholecalciferol)	5 mcg (200 IU)	25%
Vitamin E (as D-Alpha-Tocopheryl Acetate, D-Alpha Tocopherol, Tocotrienols)	50.3 mg	335%
Vitamin K (as Phytonadione)	20 mcg	17%
Thiamin (as Thiamine Mononitrate)	3.75 mg	313%
Riboflavin (as Riboflavin)	4.25 mg	327%
Niacin (as Niacinamide)	17.5 mg NE	109%
Vitamin B6 (as Pyridoxine Hydrochloride)	5 mg	294%
Folate	500 mcg DFE (300 mcg folic acid)	125%
Vitamin B12 (as Cyanocobalamin)	15 mcg	625%
Biotin (as Biotin)	75 mcg	250%
Pantothenic Acid (as D-Calcium Pantothenate)	15 mg	300%
Calcium (as Calcium Carbonate, Di-Calcium Malate, Calcium Ascorbate)	250 mg	19%

Calcium (as Calcium Carbonate, Di-Calcium Malate, Calcium Ascorbate)	250 mg	19%
Iodine (as Potassium Iodide)	50 mcg	33%
Magnesium (as Magnesium Glycinate, Magnesium Oxide)	125 mg	30%
Zinc (as Zinc Bisglycinate)	7.5 mg	68%
Selenium (as L-Selenomethionine, Sodium Selenite)	70 mcg	127%
Copper (as Copper Bisglycinate)	0.5 mg	56%
Manganese (as Manganese Bisglycinate)	1 mg	43%
Chromium (as Chromium Nicotinate Glycinate)	100mcg	286%
Molybdenum (as Molybdenum Bisglycinate)	37.5 mcg	83%
Polyphenol and Flavonoid Blend	97.5 mg	*
Catechins (from <i>Camellia sinensis</i> Leaf Extract)	(45 mg)	*
Quercetin	(25 mg)	*
Grape Seed Extract (min. 95% Polyphenols)	(12.5 mg)	*
Citrus Bioflavonoids (from Citrus Fruits)	(12.5 mg)	*
Resveratrol (from <i>Polygonum cuspidatum</i> root extract)	(2.5 mg)	*
Mixed Tocopherols (Gamma, Delta & Beta Tocopherols)	53 mg	*
Alpha-Lipoic Acid	15 mg	*
Inositol (as Inositol)	5 mg	*
Carotenoid Blend	3.5 mg	*
Lycopene (as Lycopene)	(2.5 mg)	*
Lutein (from Marigold Flower Extract)	(1 mg)	*
Boron (as Boron Citrate)	1.5 mg	*
Vanadium (as Vanadyl Sulfate)	10 mcg	*

OTHER INGREDIENTS: Gelatin, Microcrystalline Cellulose, Croscarmellose Sodium, Stearic Acid, Magnesium Stearate, Silicon Dioxide, Titanium Dioxide.

CONTAINS: Fish (Cod, Pollack, Haddock, Hake, Cusk, Redfish, Sole, Flounder).

SUPPLEMENT FACTS

Supplement Facts

Serving Size 2 Softgels

Servings Per Container 60

Amount Per Serving		% DV
Total Calories	15	
Total Fat	1 g	1%*
Saturated Fat	0 g	0%*
Trans Fat	0 g	
Vitamin D ₃ (as cholecalciferol)	12.5 mcg (500 IU)	63%
Vitamin K ₂ (as menaquinone-7)	20 mcg	17%
Ultra-pure fish oil concentrate:	1055 mg	**
EPA (Eicosapentaenoic acid)	300 mg	**
DHA (Docosahexaenoic acid)	200 mg	**
Citrus Bioflavonoids	100 mg	**
(including hesperidin and naringin)		
Purple corn (<i>Zea mays</i> L.) cob extract	66.67 mg	**
including anthocyanins		
Alpha Lipoic Acid	50 mg	**
Quercetin (from <i>Dimorphandra mollis</i> fruit extract)	37.5 mg	**
D-Limonene (from <i>Citrus sinensis</i> peel)	25 mg	**
Rosemary (<i>Rosmarinus officinalis</i> L.) leaf extract	18.75 mg	**
including carnosic acid		
Resveratrol (from <i>Polygonum cuspidatum</i> root)	15 mg	**
Coenzyme Q10	15 mg	**
Lycopene	2.5 mg	**
Lutein (from marigold flower (<i>Tagetes erecta</i>))	2 mg	**
Astaxanthin (from <i>Haematococcus pluvialis</i> algae)	0.5 mg	**

* Percent Daily Values are based on a 2,000 Calorie Diet.

** Daily Value (DV) not established.

OTHER INGREDIENTS: Gelatin, Glycerin, Beeswax, Sunflower Lecithin, Vanillin.

CONTAINS: Fish (anchovies, sardines, mackerel).

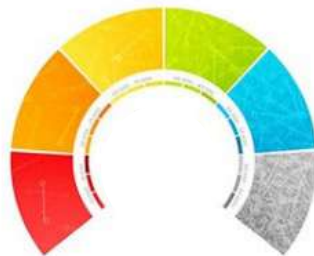53-year-old man

CONGRATULATIONS ON TAKING THE FIRST STEPS TOWARDS OPTIMIZING YOUR SCS

Dear [REDACTED]

Recently, on 12/27/2020, you met with me and I scanned the palm of your hand with the BioPhotonic Scanner. Your scan returned a Skin Carotenoid Score (SCS) of 33000.

This score represents the current carotenoid level of your skin. The higher the score, the more carotenoids your body is receiving.



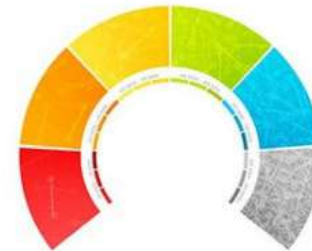33000

CONGRATULATIONS ON TAKING THE FIRST STEPS TOWARDS OPTIMIZING YOUR SCS

Dear [REDACTED]

Recently, on 01/23/2021, you met with me and I scanned the palm of your hand with the BioPhotonic Scanner. Your scan returned a Skin Carotenoid Score (SCS) of 47000.

This score represents the current carotenoid level of your skin. The higher the score, the more carotenoids your body is receiving.



47000

Raster Comparison Report

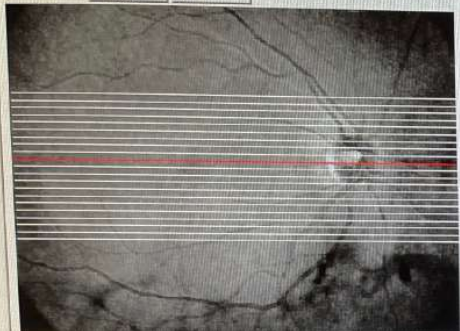Scan 09/29/2020 13:20:09

Reference En Face IR

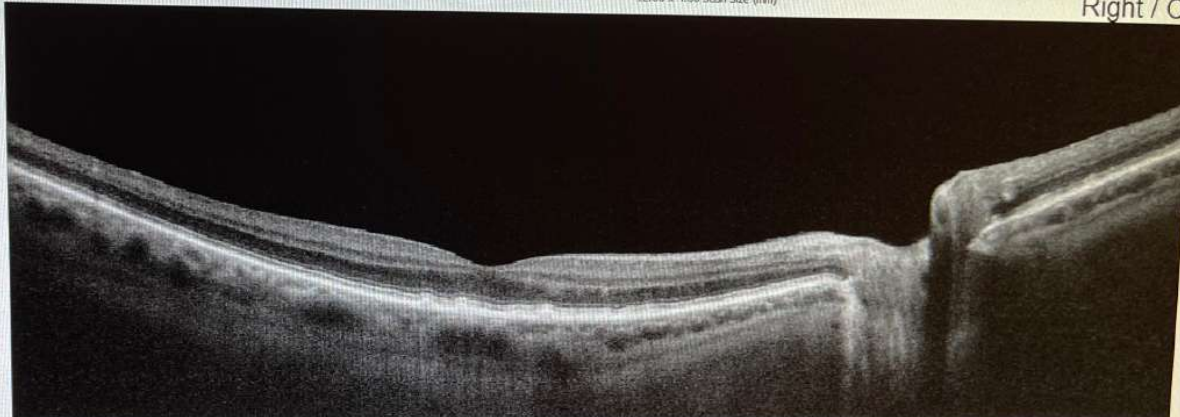Signal Strength Index 55

12.00 x 4.00 Scan Size (mm)

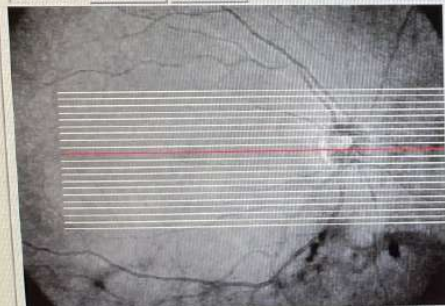
Right / OD



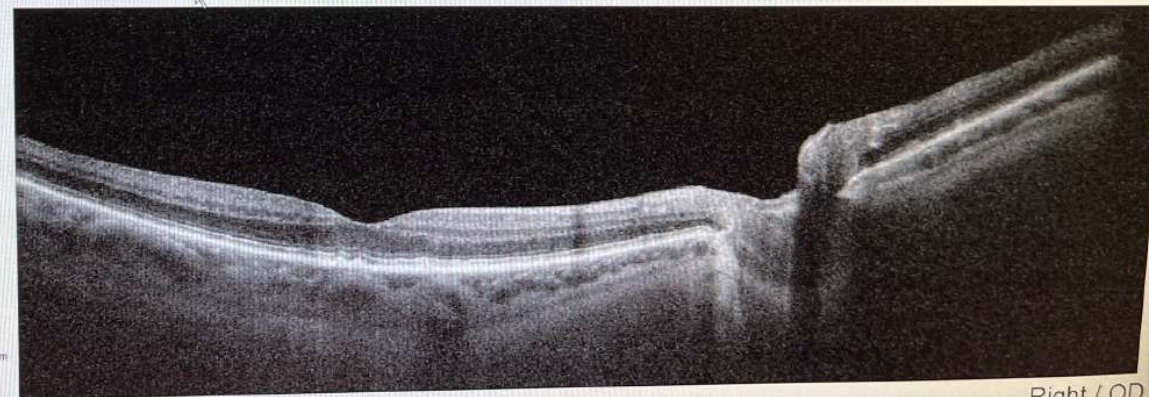10 250µm



Reference En Face IR



10 250µm



Signal Strength Index 43

12.00 x 4.00 Scan Size (mm)

Right / OD

Scan 06/23/2021 10:22:11

Print

OU Report

49°F Sunny 10:46 AM 6/23/2021

N of 3
So Far

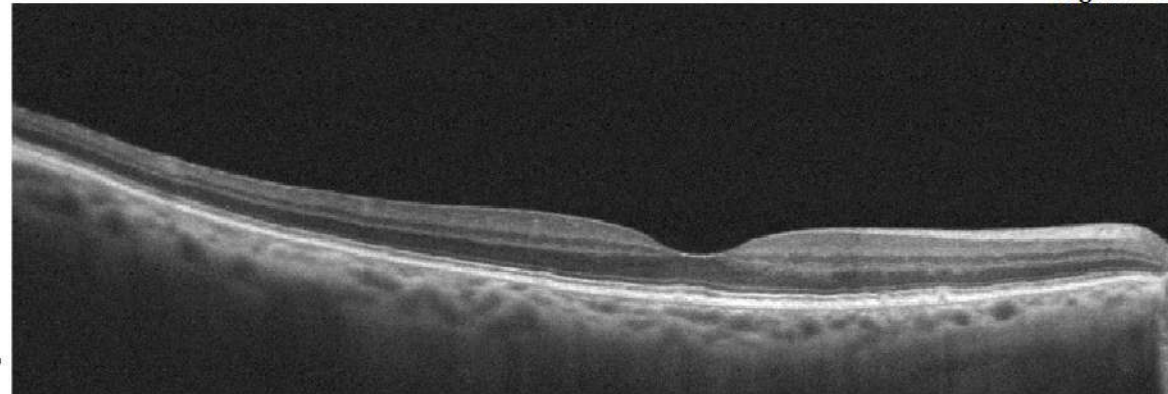
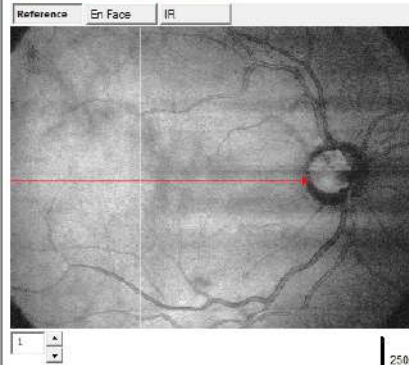
Cross Line Comparison Report

Scan 04/05/2021 14:33:33

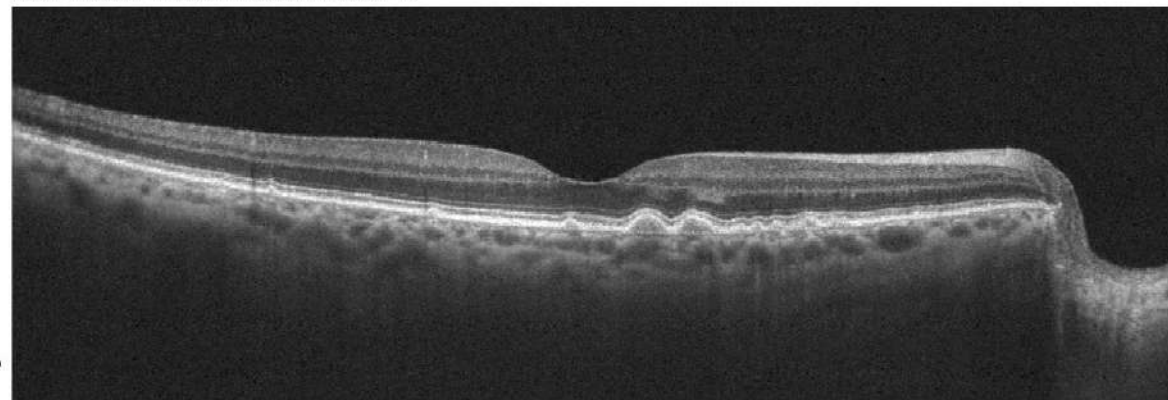
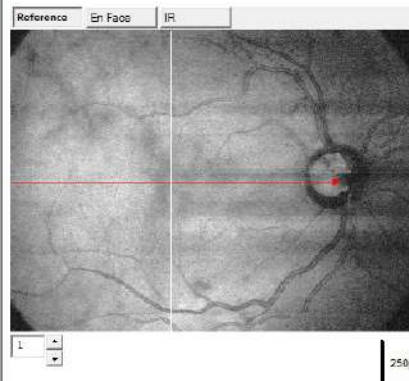
Signal Strength Index 58

10.00 Scan Size (mm)

Right / OD



☒ Auto Zoom



Scan 09/21/2020 10:40:42

Signal Strength Index 59

10.00 Scan Size (mm)

Right / OD

Print

OU Report

Treat and Extend!

Comment:

Mr. Burke has exudative AMD in each eye. He is doing well in each eye today with no recurrent CNVM activity. I recommend we treat each eye with Eylea again today and increase our follow-up interval.

The patient has a stable operculated break in the right eye which we will continue to monitor moving forward as well.

We'll see him again in about 11 or 12 weeks and keep you apprised as to his progress. Since this is longer than we have gone before, especially in his left eye, I asked him to keep a close watch on his vision and contact us right away if there is any worsening prior to his next visit.

Sincerely,

Deepam Rusia, M.D., M.B.A.

CC: Julie Lesneski CRNP

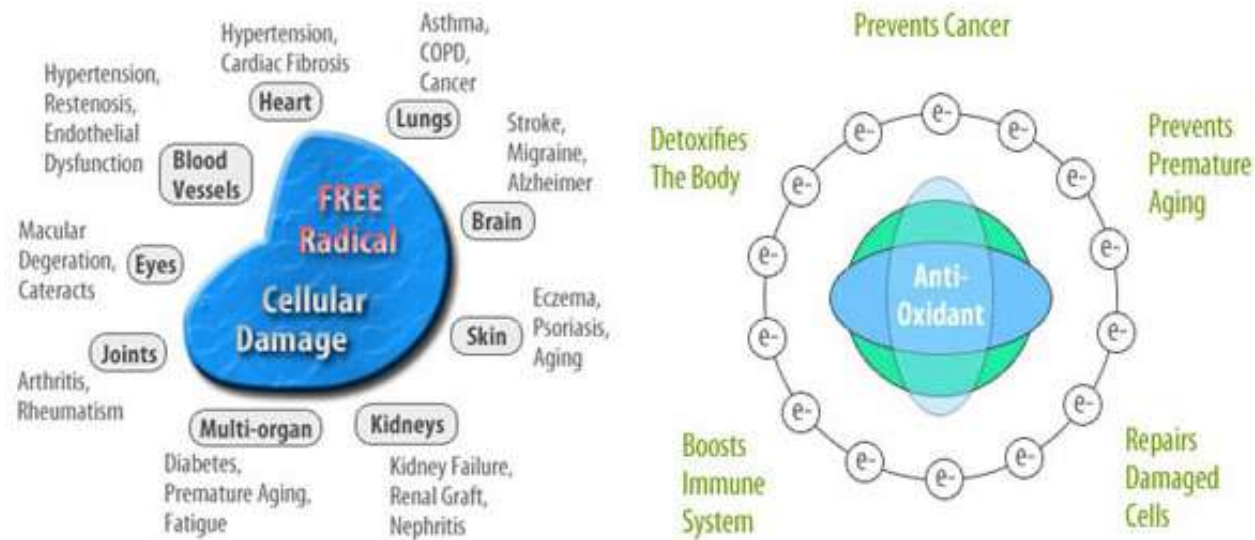Phone: 412-683-5300
800-456-4393

PITTSBURGH
300 Oxford Drive
Suite 300

2000 Oxford Drive
Suite 670
Pittsburgh, PA 15107

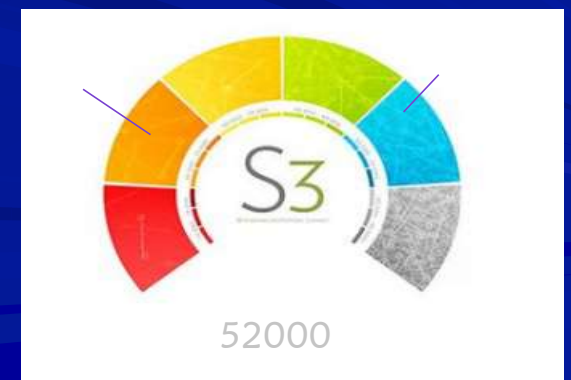Cloverleaf Commons
51 Dutilh Road
Suite 200

Screen Everyone



Carotenoid and Antioxidant Levels in Ocular Disease and Systemic Health

- 👓 Plenty of evidence that carotenoids are beneficial in ocular and systemic prevention
- 👓 Patients are looking for guidance
 - ★ Many are on supplements
 - 📋 Surprised what they are doing is minimally helping
- 👓 Measuring ensures the patient
- 👓 Antioxidants in the eye and body go beyond lutein and zeaxanthin
- 👓 Dr. Oz “Ultimate nutritional lie detector”
- 👓 Best benefit of all...



1:16 PM Sat Oct 23

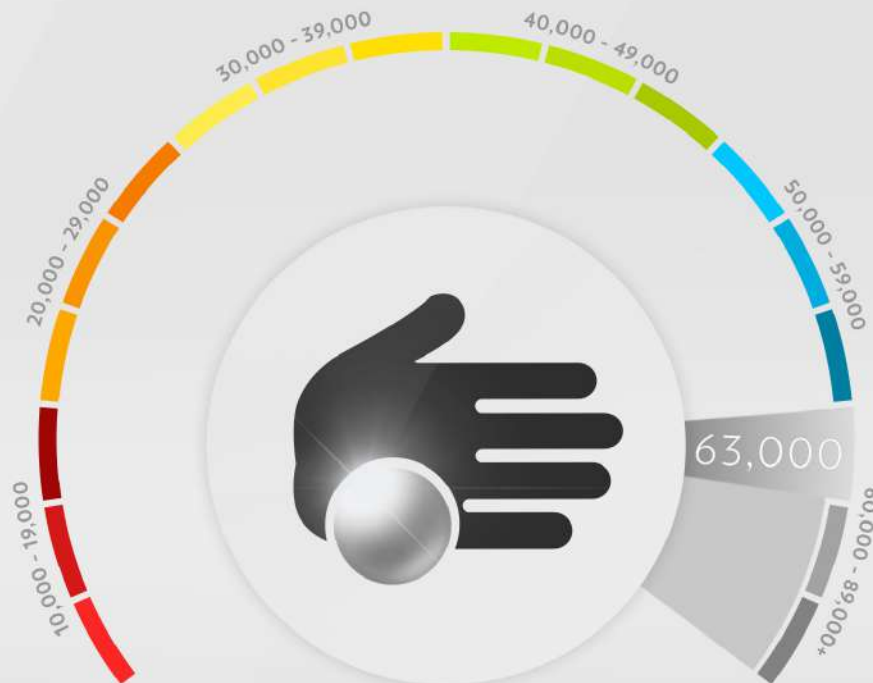
88%

GREG CALDWELL
grubc@aol.com

5200953148879799



CANCEL



NEXT

SCAN COMPLETE




Thank You for This Opportunity

Do it for:

- ★ Yourself
- ★ Your family
- ★ Your staff
- ★ Your patients





Optometric
Education
Consultants

Questions? Thank You

Carotenoid Levels in Ocular Disease and Systemic Health

Greg Caldwell, OD, FAAO

Mackinac Island
Optometric Education Consultants
Saturday, August 27, 2022

