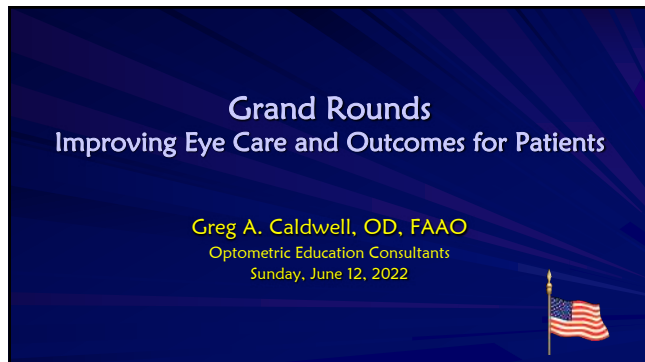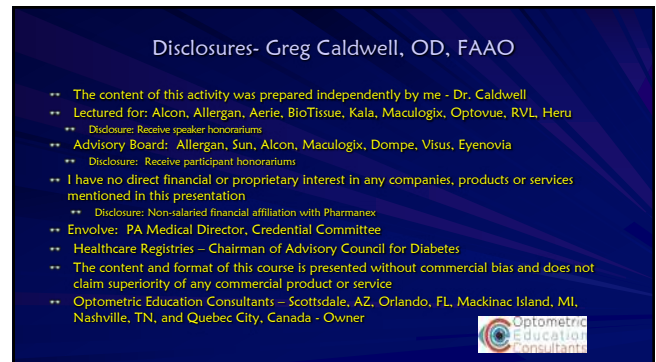
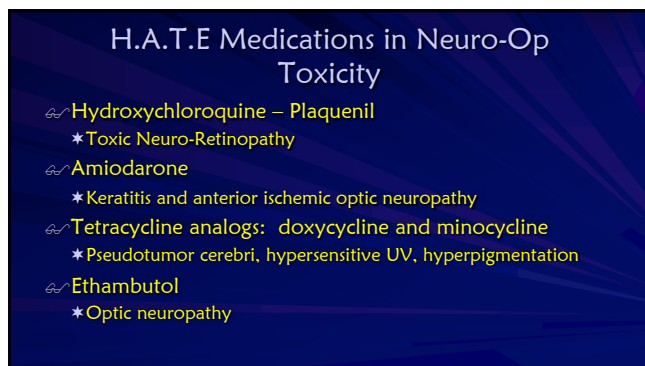


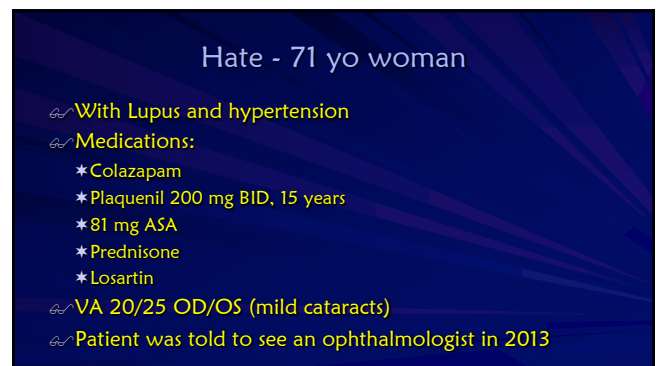
1



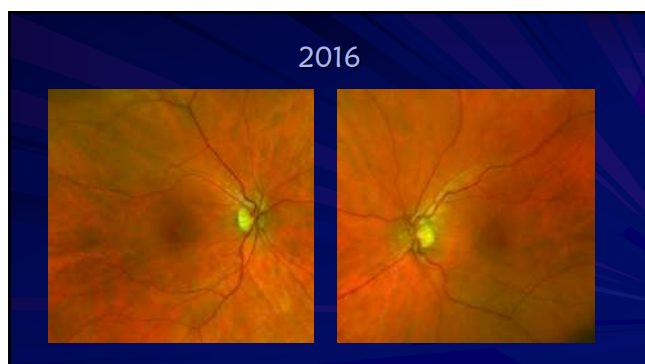
2



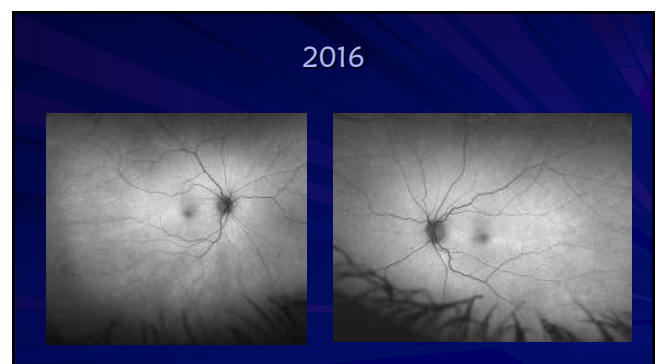
5



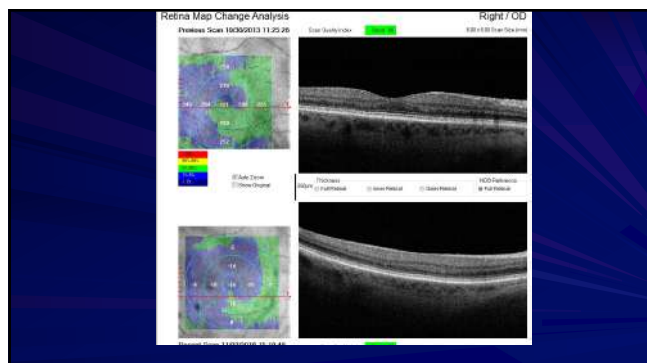
6



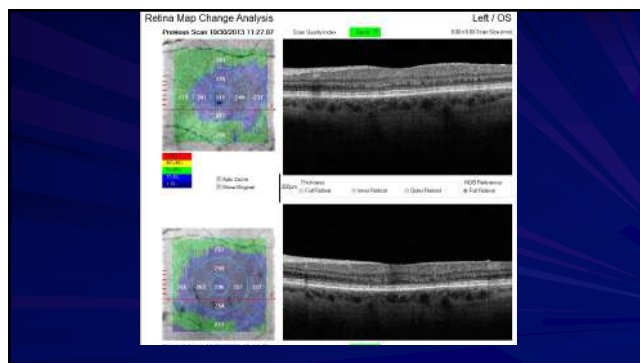
7



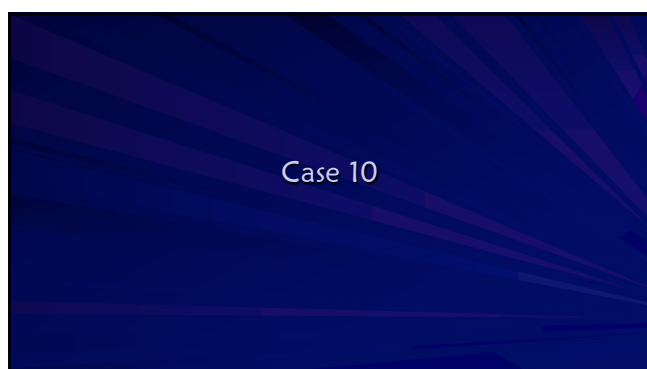
8



9



10

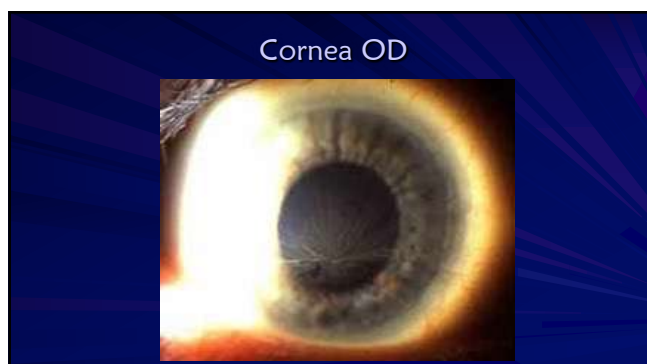


11

hAte- 65-year-old woman

- Referred by an optometrist due to corneal edema and map-like anterior opacities
 - Impression is EBMD versus corneal degeneration
- Patient reports decreasing vision over past 6-9 months
 - Especially at near
- Vision 20/50 OU

12

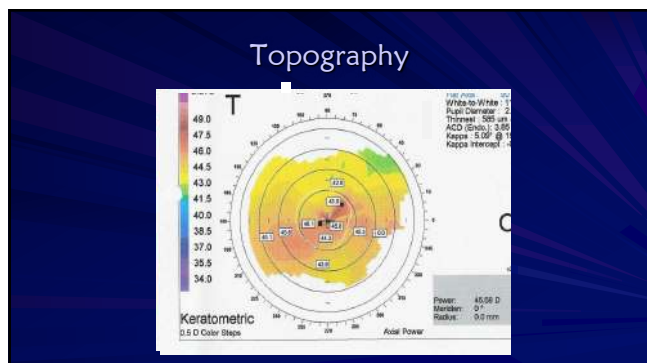


13

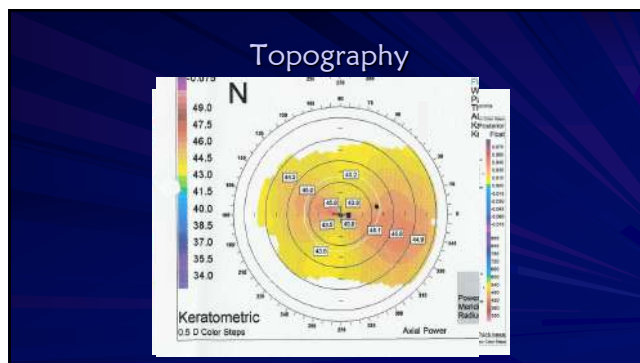
Patient's Medications

- Baby ASA
- Lanoxin
- Synthroid
- Glucophage
- Pravochol
- Amiodarone
- Neurotin
- Zolof
- Vitamin E

14



15



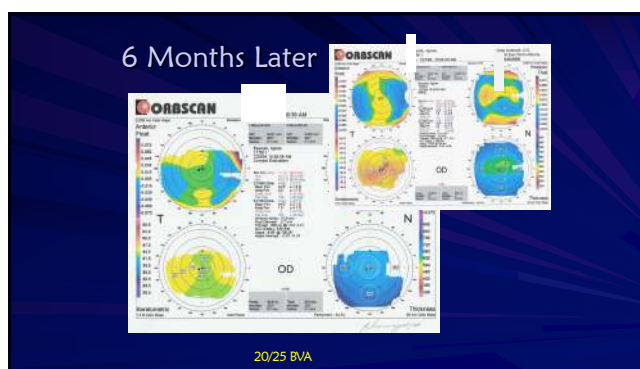
16

Called Primary Care Physician to Discuss Findings

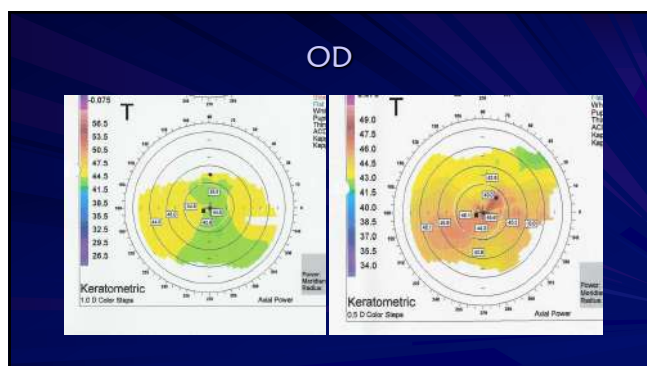
- ~ D/C amiodarone
- ~ Primary Care Physician switches patient to diltiazem

Class	Action	Drugs
I	Sodium channel blockade	Quinidine, Procainamide, Disopyramide, Lignocaine, Mexiletine, Tocainide, Flecainide, Phenylephrine
II	β -adrenergic blockade	Propranolol, Acebutolol, Carvedilol, Esmolol ...
III	Prolong repolarisation	Amiodarone, Bretylium, Sotalol, Difetilide, Azimilide
IV	Ca ²⁺ antagonism	Verapamil, Diltiazem, Semotiadil

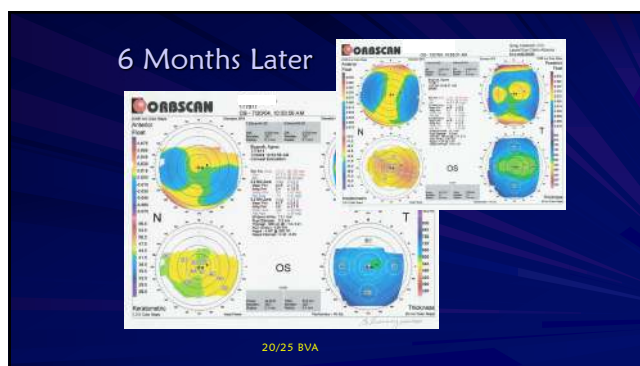
17



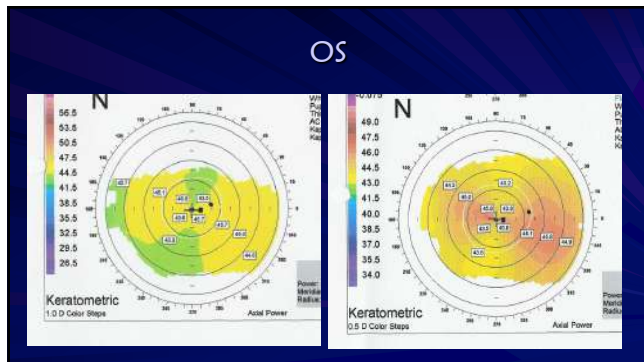
18



19



20



21

Amiodarone Ocular Side Effects

- Halos and colored lights, reported symptoms
- Corneal opacities
 - Epithelial basal cell layer
 - Bilateral, dose and duration related
 - Reversible
 - Dot, Linear, cornea verticillata (whorl like pattern found later)
- Conjunctiva, lens, retina and optic nerve deposits
- Optic neuropathy has been reported
 - Unilateral and bilateral cases

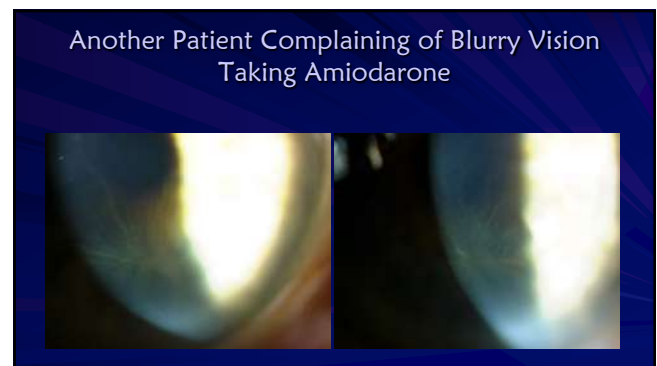<http://www.optometry.co.uk/articles/20020517/patel20020517.pdf>

22

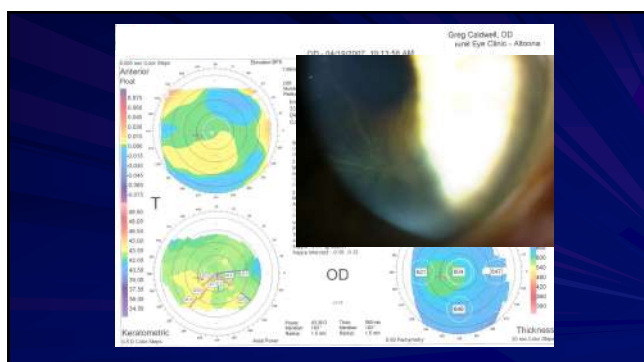
Cornea Verticillata (Whorls)

- Drug-induced
 - Amiodarone
 - Chloroquine/hydroxychloroquine
 - Tamoxifen
 - Chlorpromazine
 - Indomethacin

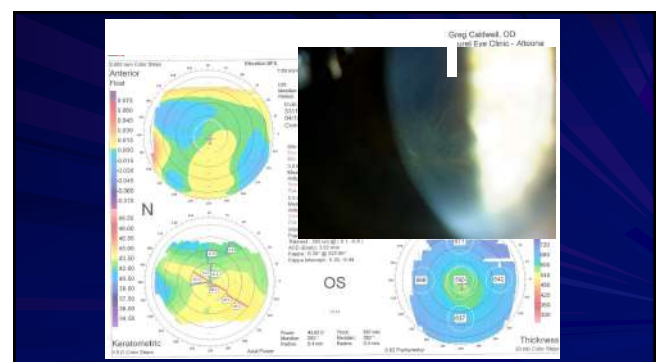
23



24



25



26

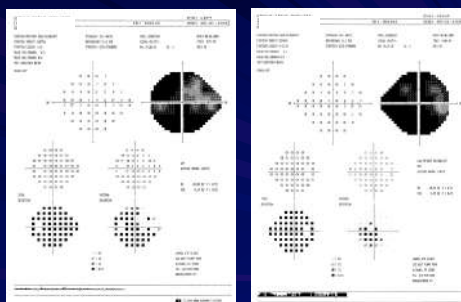
Case 11

67-year-old man complains of vision slowly deteriorating over the past 8 months

- ~ History of NA-ION 10 months ago OD
- ~ Patient sees family physician for physical due to recent NA-ION
 - * Patient has not been to PCP for 35 years
 - * Patient started Cardarone
 - * VA 20/80 OD 20/25 OS (9 months ago)
- ~ VA 20/400 OD 20/200 OS (today)
- ~ CF: severe constriction OU
- ~ SLE: vortex corneal whorls OU

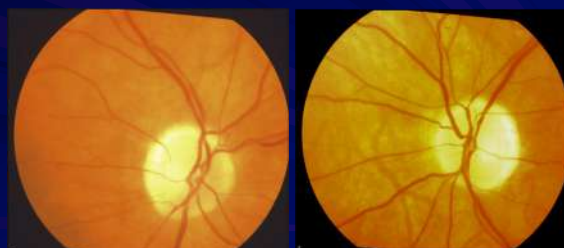
27

28



29

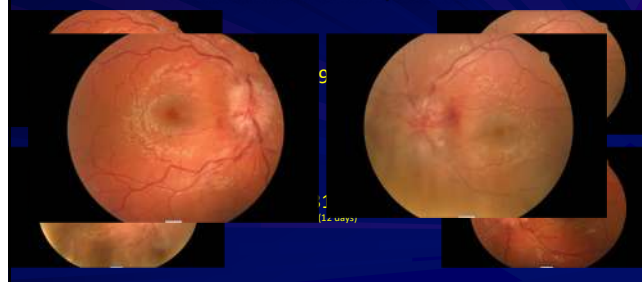
Amiodarone Optic Neuropathy



30

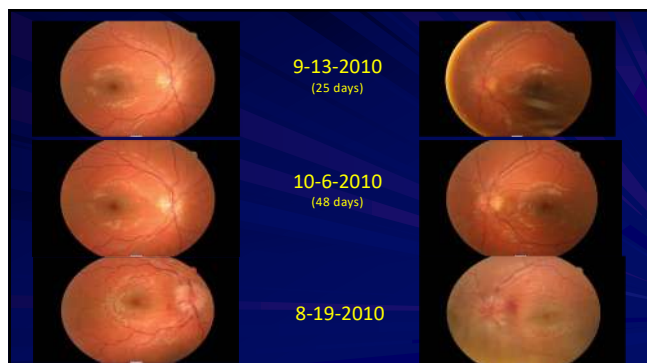
haTe-Doxycycline and Minocycline

Benign intracranial hypertension "It's not rare if it's in your chair"

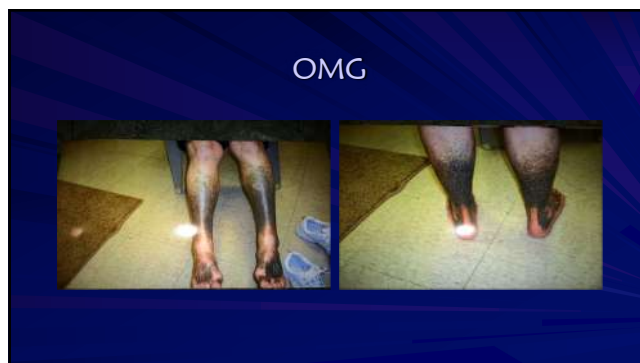


31

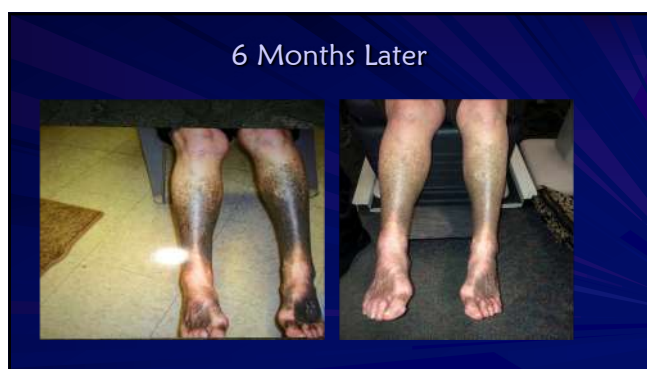32



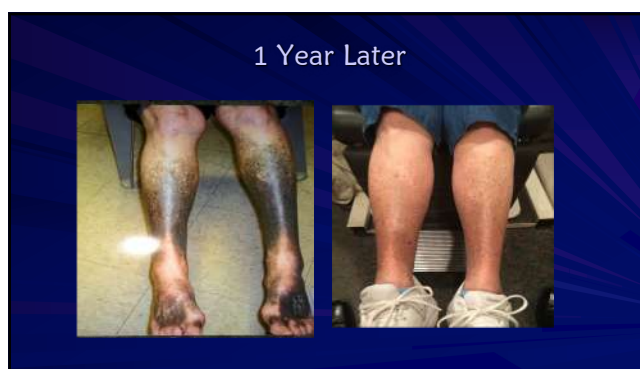33



34



35

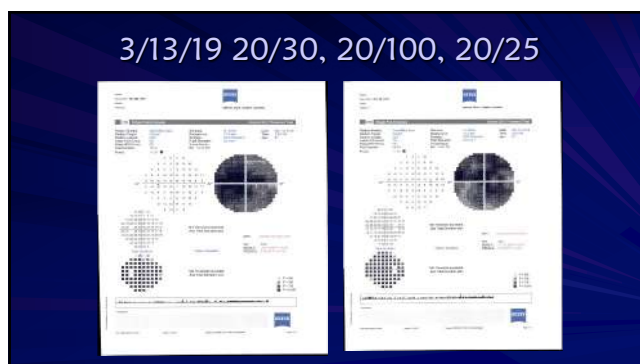


36

hatE- 81-year-old woman

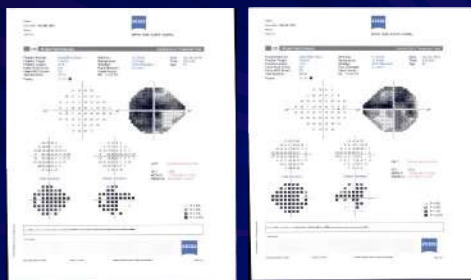
- Calls the office reporting decreased vision (3-13-19)
 - * Was warned vision could decrease due her medications
 - * Glaucoma patient
- Mycobacterium avium infection
- Ethambutol, rifampin, and azithromycin
 - * Ethambutol started October 2017
- Glaucoma patient
 - * Was on latanoprost and Rhopressa
 - * Had KDB
 - No glaucoma drops currently

37




38

4/29/19 20/25, 20/50, 20/20




39

7/29/19 20/20, 20/25, 20/20



40

Progression



41

Optometric Public Service Announcement
Pay Very Close Attention

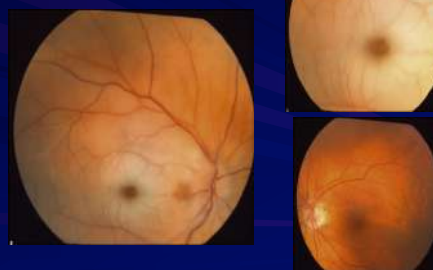42

80-year-old man

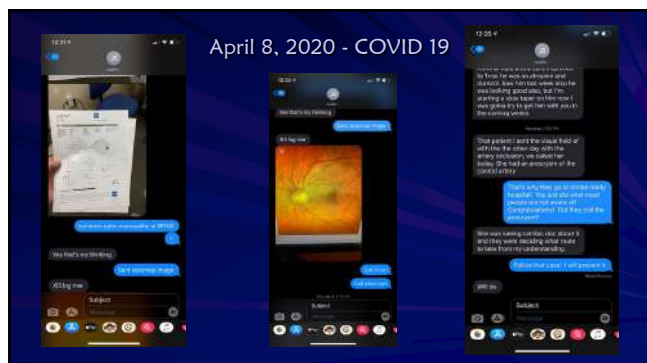
- Reports a sudden loss of vision OD
- Vision is count fingers at 2 feet OD and 20/25 OS
- APD OD grade 4
- Fundus photos OU

43

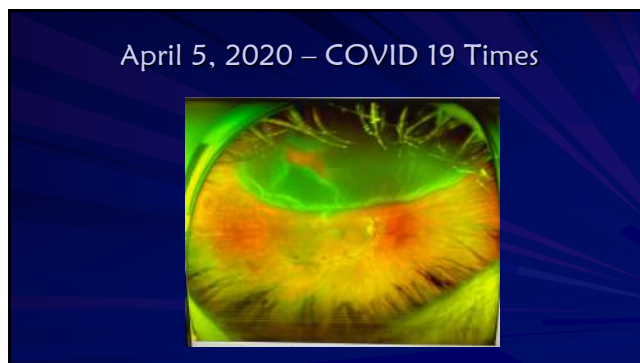Photos OU



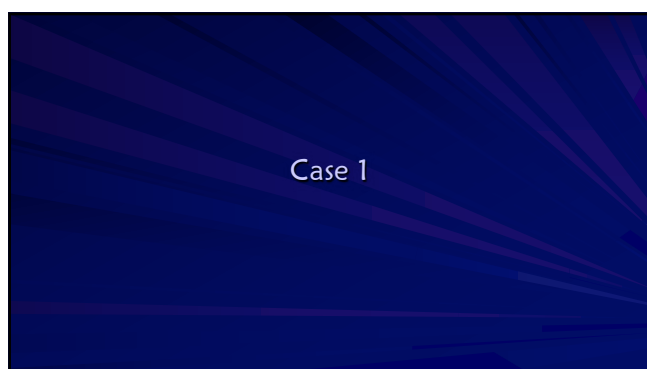
44



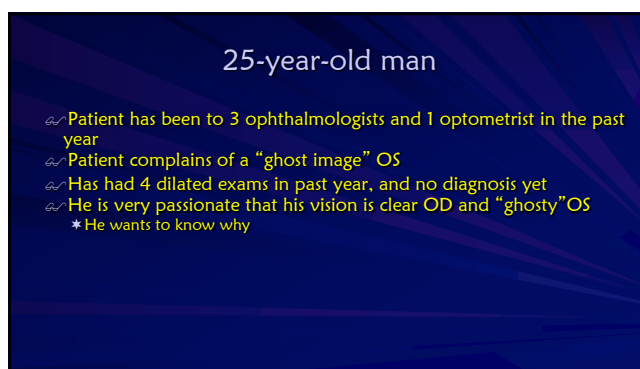
51



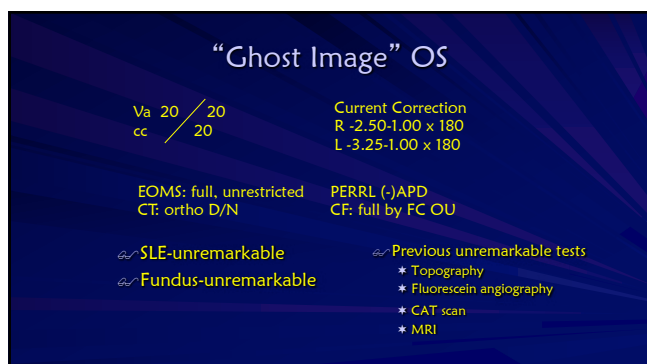
52



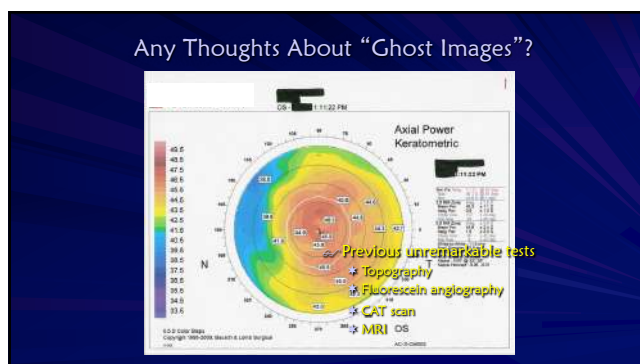
53



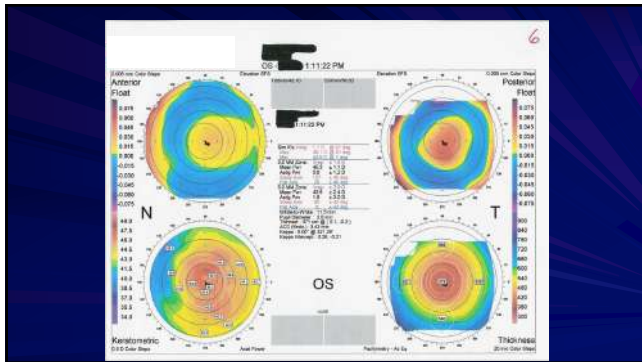
54



55



56



57

How I felt when I finally realized keratoconus
starts posteriorly



58

Forme Fruste Keratoconus

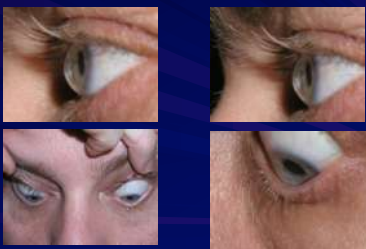- 👉 Treatment
- 👉 RGP lens in office and trial frame over refraction
 - ★ Eliminated "ghost image"
- 👉 Patient currently only in spex
 - ★ Not interested in RGP lens
- 👉 RTC 1 year, BVA and topographies

59

Case 2

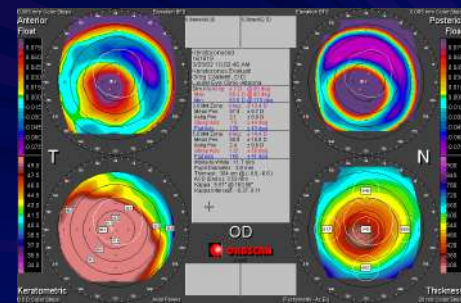
60

Advanced Keratoconus

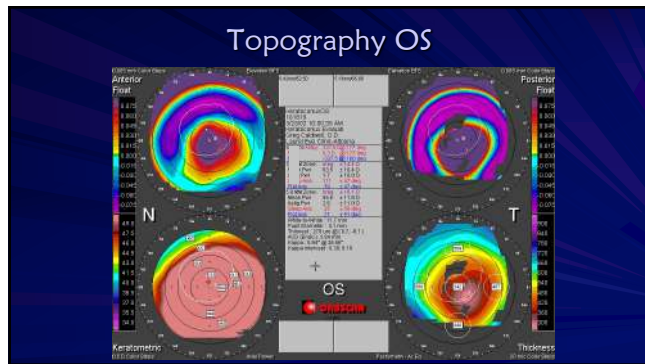


61

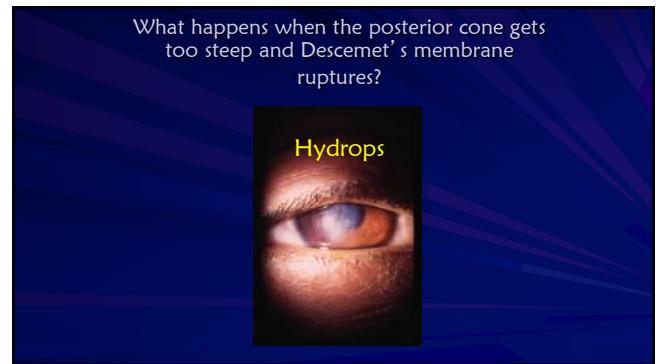
Topography OD



62



63




64


Keratoconus

- Progressive corneal disease**
 - * Focal thinning, steepening, bulging, and irregular shape
 - * Loss of biomechanical strength
 - * Bilateral, asymmetric, clinically non-inflammatory
- Caused by a combination of genetic and environmental factors**
 - * Allergies and eye rubbing
- Onset in puberty**
 - * Typically progressive to 4th decade of life
 - * Previously estimated 1:2000 (1986 US), more recent estimate 1:375 (2017 Netherlands)

Normal

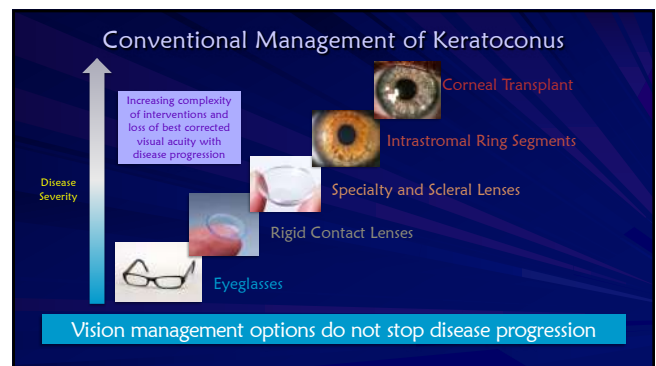

KC



Photos courtesy of Dr. Alex Goh, MD, PhD


66



67

Importance of Early Diagnosis in Keratoconus

- As keratoconus progresses, it becomes more challenging to manage
- Progressive keratoconus often results in:
 - Loss of visual acuity
 - Decreased tolerance to contact lens wear, caused by the ongoing changes in the cornea
- The earlier progressive keratoconus is diagnosed, the sooner treatment can be provided that may slow the progression of the disease.¹
- Important to diagnose and educate patients before visual function is lost**
- CXL is an early intervention intended to slow or halt the progression of keratoconus



1. Gelles, J. D., OD, FIAO, FCLSA. (2017, April). The Optometrist's Role in Keratoconus Management. Advanced Ocular Care.

68

Watch Out for Keratoconus!

Potential Signs & Symptoms

Typically onset occurs in teenage years or early twenties

- Frequent Changes in Refraction or Increasing Cylinder
- Reduced Best Corrected Visual Acuity
- Frequent Headaches
- Halos and Ghosting
- Family History of Keratoconus
- Excessive Eye Rubbing
- Difficulty Seeing at Night
- Increased Light Sensitivity

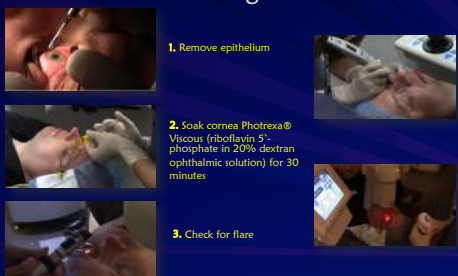
If you believe a patient may have keratoconus, perform a diagnostic exam or First An Expert at CollegeOptom.com to order them for a KC screening.

LOOK OUT FOR KC!

- Look out** for warning signs in medical history
 - History of eye rubbing
 - Family & genetic predispositions
- Look out** for visual complaints
 - Blurred vision
 - Distortion of images
- Look out** for refractive anomalies
 - Distortion of mires on keratometry
 - Error messages on autorefractors
 - Unsatisfactory attempts at vision correction & progressive loss of UCVA & BCVA
 - Increasing astigmatism

69

Cross-linking Procedure Summary



1. Remove epithelium
2. Soak cornea Photrex-B® Viscous (riboflavin 5'-phosphate in 20% dextran ophthalmic solution) for 30 minutes
3. Check for flare
4. Once flare is observed, measure corneal thickness. If corneal thickness is less than 400 µm, instill 2 drops of Photrex-B (riboflavin 5'-phosphate in ophthalmic solution) until the corneal thickness increases to at least 400 µm.
5. Irradiate for 30 minutes. Continue applying Photrex-B Viscous (riboflavin 5'-phosphate in 20% dextran ophthalmic solution) during irradiation.

* Refer to prescribing information for entire FDA-approved procedure

70

Descemet's Stripping Endothelial Keratoplasty DSEK



71

Case 3

72

28-year-old man

- Had LASIK 14 months ago
- His right eye is now very blurry
- He tried calling for an appointment the center is now closed

73


Va 20 / 40
cc 20

Current Correction
R +0.50-7.00 x 040
L -0.25 sphere

EOMS: full, unrestricted PERRL (-)APD
CT: ortho D/N CF: full by FC OU

- SLE-trace fibrosis at flap edges, no stain
- SLE-few multi-directional striae OD>OS
- SLE-clean interface OU
- Fundus-unremarkable

74



Diagnosis:

- Keratectasia 2" LASIK
- RGP OD 20/20-2
- This lasted for about 3 months
- Multiple RGP, later due to progression of astigmatism to 8.5 D (BVA 20/50-2)
- Finally PKP was done Jan 2006

75

Case 4

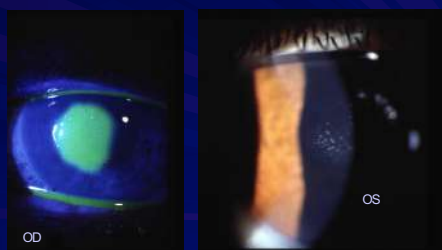
76

43-year-old man

- ~ Called your office today
- ~ Eye pain in the right eye since this morning
- ~ OD 20/80 OS 20/20
- ~ Externals: normal
- ~ Review of Systems: unremarkable

77

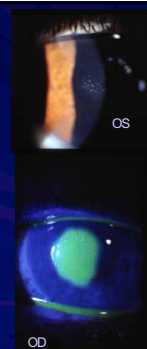
Slit Lamp Evaluation



78

43-year-old male further history reveals

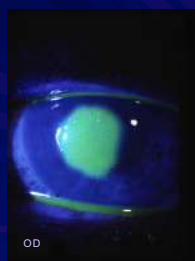
- ~ Fourth time in past 24 months
- ~ Uses Muro 128
 - * Cits qid
 - * Ung qHS
- ~ Diagnosis:
 - * Recurrent Corneal Erosion secondary to Epithelial Basement Membrane Dystrophy (EBMD)



79

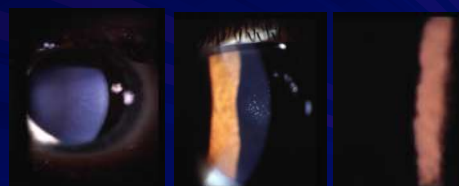Treatment

- ~ Antibiotic, topical
- ~ Pain management
 - * Depending on severity
 - Bandage contact lens
 - Oral ibuprofen (200 mg) (16)
 - Maximum 3200 mg daily
 - Oral acetaminophen (500 mg) (6)
 - Maximum 3000 mg daily
 - Oral narcotic (need DEA number)
 - Lortab (500/5)
 - They provide good pain relief
 - A degree of sedation
 - Tend to minimally impact the digestive system and kidney
 - It's not that they're dramatically more potent than OTC analgesics like aspirin, acetaminophen, ibuprofen or naproxen
 - Topical NSAID



80

Review of Map-Dot-Fingerprint



81

Treatment Options

(Once Abrasion Resolved, to Help Prevent Recurrence)

When is it time for surgical procedure?

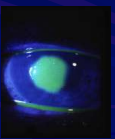
Answer: medical treatment failure

Medically

- Hypertonic
 - Gits
 - Ung
- Bandage contact lens
 - Nocturnal
- Doxycycline/Minocycline
- Amniotic membrane (PROKERA™)

Surgical/Procedures

- Anterior stromal micropuncture
- Debridement
 - Chemically
 - Mechanically
 - Beaver blade/diamond burr
- Excimer phototherapeutic keratectomy (PTK)





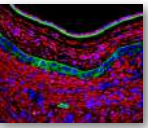
82

The Basics of Amniotic Membrane

83

The Amniotic Membrane


- The amniotic membrane is the innermost lining of the placenta (amnion)
- Amniotic membrane shares the same cell origin as the fetus
 - Stem cell behavior
- Structural similarity to all human tissue

84

The CRYOTEK™ Method

- Patented and proprietary cryopreservation
- Ensures key active components of the **Extracellular Matrix (ECM)** are retained
- The **only** method that retains both:
 - The integrity of the tissue structure
 - The key active (ECM) components
- Safe and effective
 - Supported by over **300** peer-reviewed articles
 - Over **100,000** implanted
- Bio-Tissue Cryopreserved Amniotic Membrane is the **ONLY** AM granted wound healing indication by the FDA.



85

Technology Highlights

Impressive regenerative **platform** that possesses natural growth factors and optimal scaffolding properties within a complex extracellular matrix that are:

- Anti-inflammatory
- Anti-scarring
- Anti-angiogenic

Therapeutic actions:

- Promotes Stem Cell Expansion
- Suppresses pain
- Promotes cellular migration
- Expedites recovery



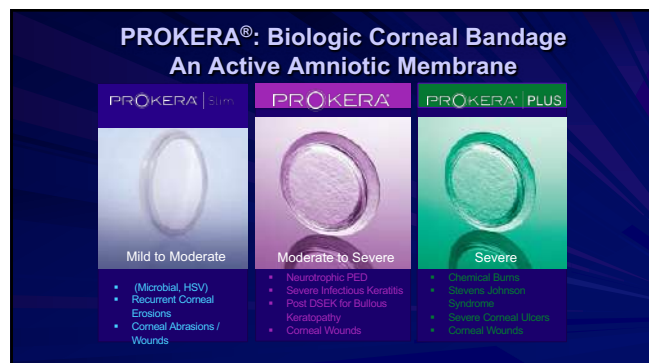86

PROKERA®: BIOLOGIC CORNEAL BANDAGE

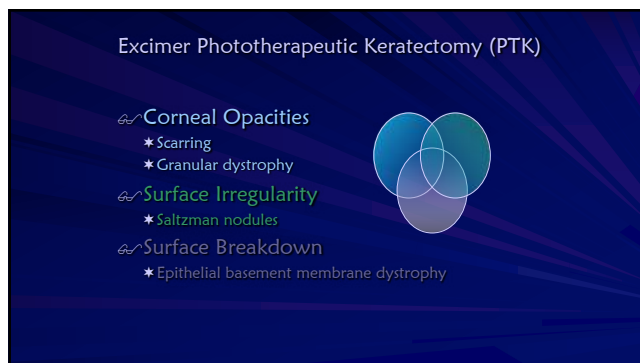
- PROKERA® utilizes the proprietary CryoTek™ cryopreservation process that maintains the active extracellular matrix of the amniotic membrane which uniquely allows for regenerative healing.
- PROKERA® is the only FDA-cleared therapeutic device that both reduces inflammation and promotes scar less healing
- PROKERA® can be used for a wide number of ocular surface diseases with severity ranging from mild, moderate, to severe



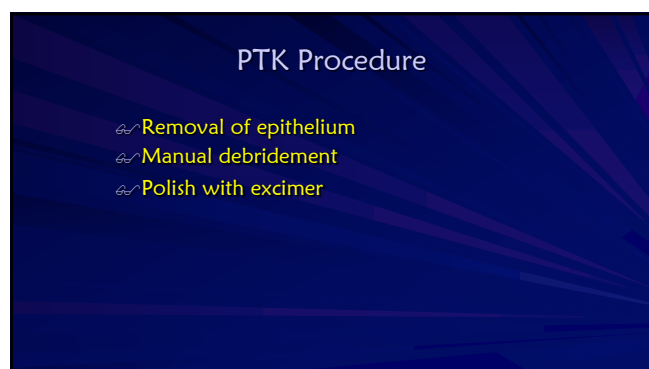
87



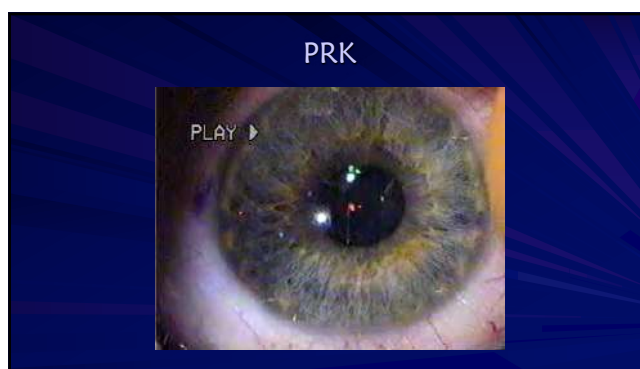88



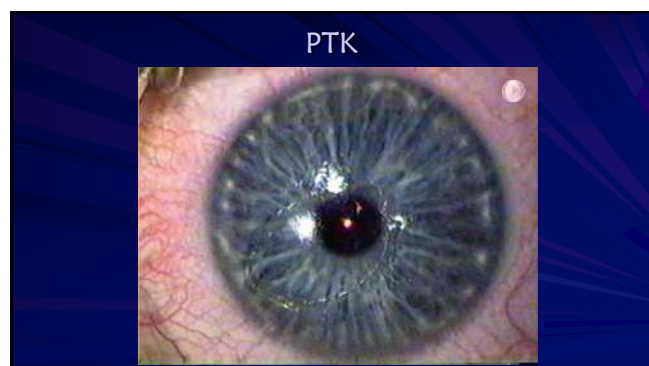89



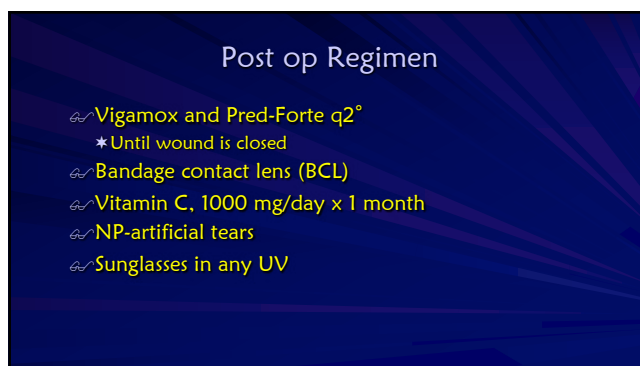
90



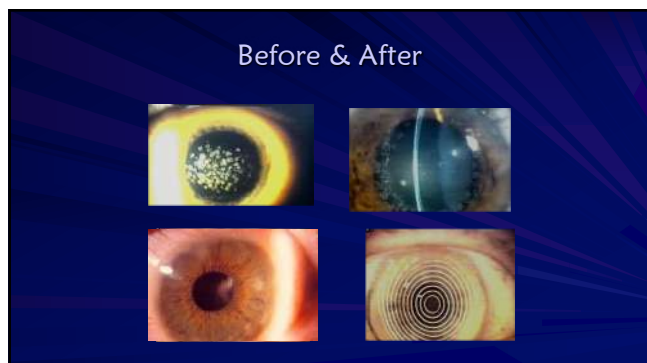
91



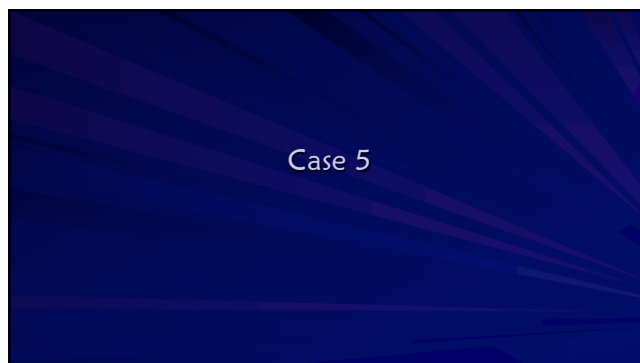
92



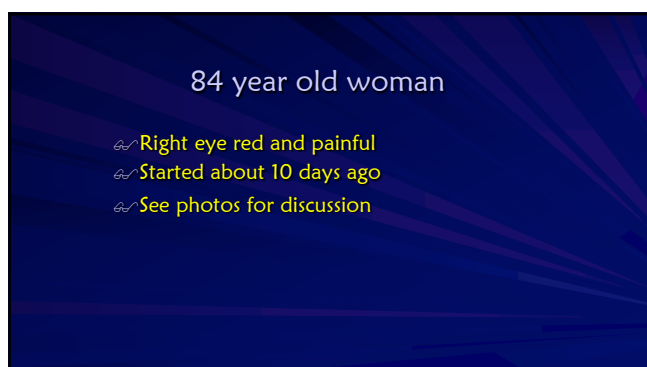93



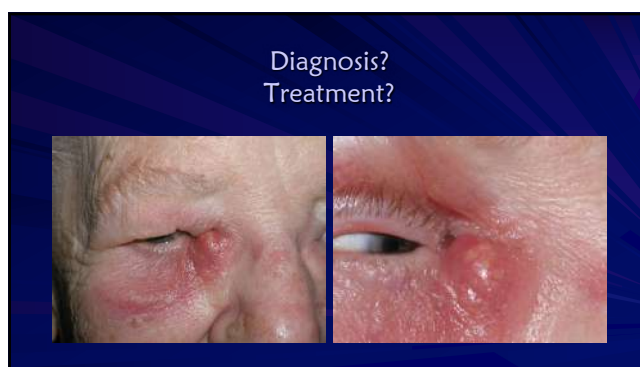94



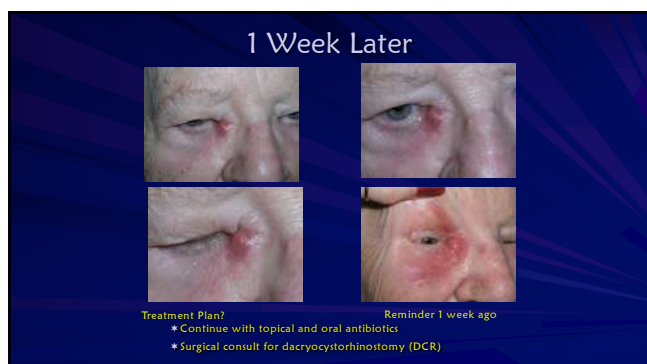95



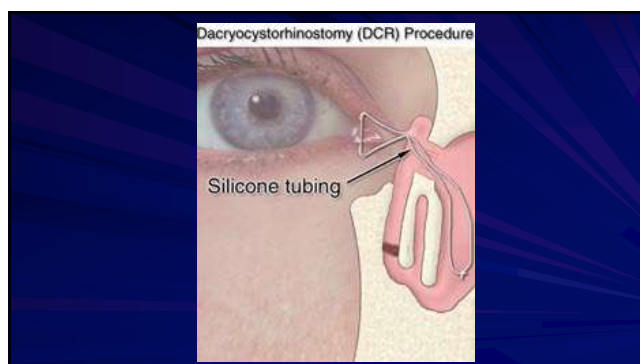
96



97

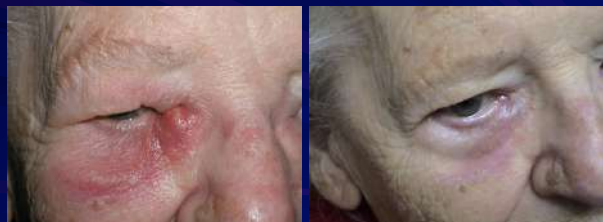

98



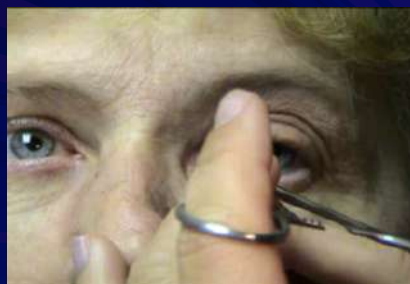99

After Dacryocystorhinostomy (DCR)



100

Tube Removal



101

Case 6

102

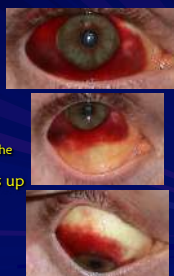35-year-old man

- Wants another opinion due to "hemorrhage on my right eye"
- Happened 3 days ago after vomiting
 - * Claims food poisoning from chicken Caesar salad
 - * Still feels a little nauseated
- Saw ophthalmologist 3 days ago, told he had a bruise on his eye and it should go away in 1-2 weeks

103

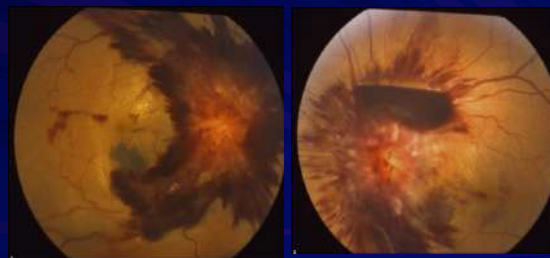
35-year-old man

- BVA 20/100 OD, 20/70 OS
 - * Hx of amblyopia OD
 - * Current Rx OD +5.50 OS +4.50
- Any concerns?
 - * Patient noticed blurry vision OS
 - * Started 2 weeks ago
 - * Did not mention because he is more concerned about the blood on his right eye
- Headaches for 2 weeks, decrease if patient stands up
- ROS: unremarkable
- Decide to dilate OU



104

Retinal Findings



105

Differential Diagnosis

- ~ Hypertensive retinopathy
- ~ Blood dyscrasia
- ~ Terson's syndrome
- ~ Valsalva retinopathy
- ~ Purtscher's retinopathy
- ~ Shaken baby syndrome

106

Terson's Syndrome

- ~ Terson's syndrome originally was defined by the occurrence of vitreous hemorrhage in association with subarachnoid hemorrhage
- ~ Terson's syndrome now encompasses any intraocular hemorrhage associated with intracranial hemorrhage and elevated intracranial pressures
- ~ Intraocular hemorrhage includes the development of subretinal, retinal, sub-hyaloidal, or vitreal blood
- ~ The classic presentation is in the sub-hyaloidal space

107

Treatment

- ~ Emergency referral to neurologist due to high suspicion of intracranial hemorrhage and elevated intracranial pressure
- ~ Intracranial hemorrhage confirmed with MRI
- ~ Patient later diagnosed with Hairy Cell Leukemia and cryptococcal meningitis

108

Case 7

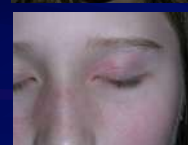109

8-year-old girl

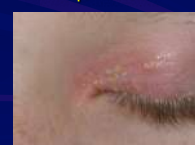- ~ Mom noticed the left eyelid has become red and has pimples
- ~ Started two days ago
- ~ Slowly getting more pimples on the eyelid
- ~ Globe not affected

110

Slit Lamp Evaluation



- ~ **Diagnosis**
 - * Herpes simplex blepharitis
- ~ **Treatment**
 - * 400 mg Acyclovir 5x/day
 - * Call to pediatrician



111

Case 8

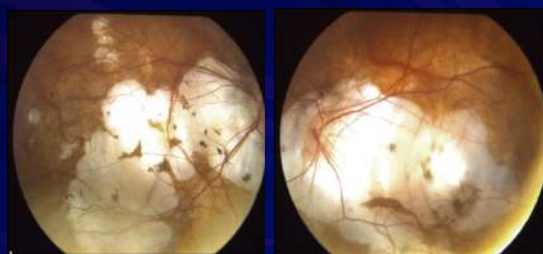
112

58-year-old woman

- ~ VA OD 20/200 OS 20/400
- ~ Longstanding history of macular degeneration
- ~ Anything suspicious here?
 - * ?? Longstanding AMD in 58-year-old??
- ~ History of cataract surgery OU
- ~ Glasses Rx OD -1.00 OS -1.00

113

Axial length 29.85 mm



OD -18.00 OS -18.50 prior to cataract surgery

114



At what diopter value is a patient considered a degenerative or pathological myope?

115

Degenerative Myopia

- ~ Differs from refractive myopia
 - * There is an alteration of globe structure that is progressive
 - * Primary alteration is a posterior elongation of eyeball as a result of progressive thinning of sclera
 - Posterior staphyloma

116

Degenerative Myopia

- ~ Findings
 - * Lacquer cracks
 - * Posterior staphyloma
 - * Fuch's spot
 - * RPE and choroidal atrophy
 - * Scleral crescents
 - * Vessel straightening
 - * Disc tilting
 - * Peripheral retinal changes
- } Can be found in refractive and degenerative myopes

117

Conditions Associated With Degenerative Myopia

- ☞ Fetal Alcohol Syndrome
- ☞ Ocular albinism
- ☞ Down's Syndrome
- ☞ Low birth weight
- ☞ Infantile glaucoma
- ☞ Retinopathy of Prematurity
- ☞ Marfan's Syndrome

118

Treatment

- ☞ BVA with glasses/contact lenses
- ☞ Education regarding trauma and possible eye hazards
- ☞ Monitor for neovascularization and peripheral retinal changes
- ☞ Follow-up at least yearly

119

Which patient is at higher risk of retinal detachment?



Two patients are in your office
-8.00 D refractive myope
-14.00 D degenerative myope

120

- ☞ Refractive myopia
 - * Peripheral retina concerns
- ☞ Degenerative myopia
 - * Posterior pole concerns

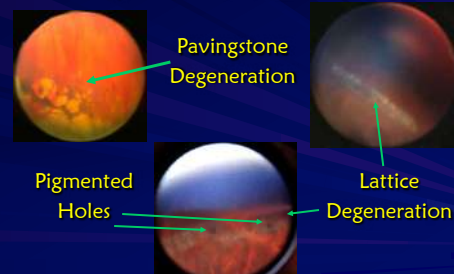
121

Clinical Pearl

- ☞ Refractive myopia
 - * Peripheral retina is general concern
- ☞ Degenerative/Pathological myopia
 - * Posterior pole is general concern
 - ☐ Posterior staphyloma

122

Peripheral Fundus Findings



123

Case 9

124

88-year-old man
I see faces of friends that I have not
seen for years, wheels of cars and at
times pine trees

BVA
Count fingers at 2 feet OU

Current Correction
R plano
L -1.00 sphere

EOMS: full, unrestricted
CF: ortho D/N by Hirschberg

PERRL (-)APD
CF: central defect OU

125

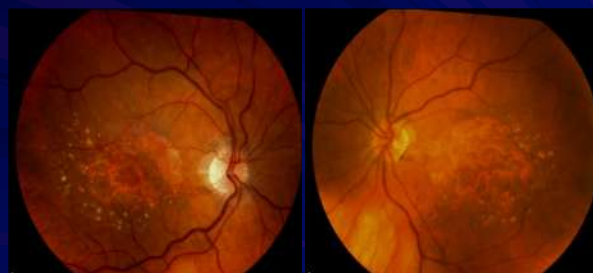
Recommend psyche consult?

Alert and Oriented x 3

- * Person
 - Knows who he is, who is with him
- * Place
 - Knows where he is, knows where he lives
- * Time
 - Knows what month, day, date and year

126

Diagnosis and Treatment?



127

Charles Bonnet Syndrome “Release Hallucination”

Visual hallucinations

- * Irritative (brief)
 - Epilepsy
 - Migraine
- * Release (continuous)
 - Stroke
 - Sensory deprivation

128

Treatment

Reassurance

- * That this is normal for patient with severe vision loss to experience hallucinations

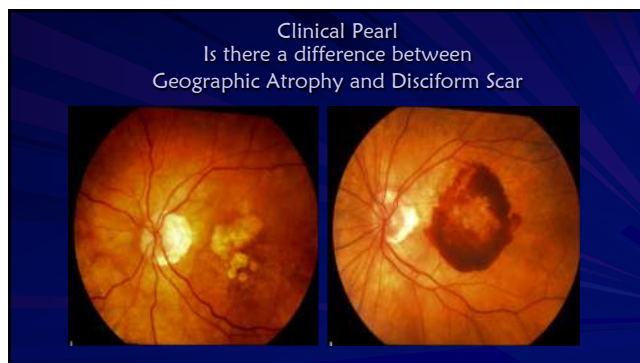
Clinical Pearl

- * Any patient 20/100 or worse in better eye
 - Ask the patient

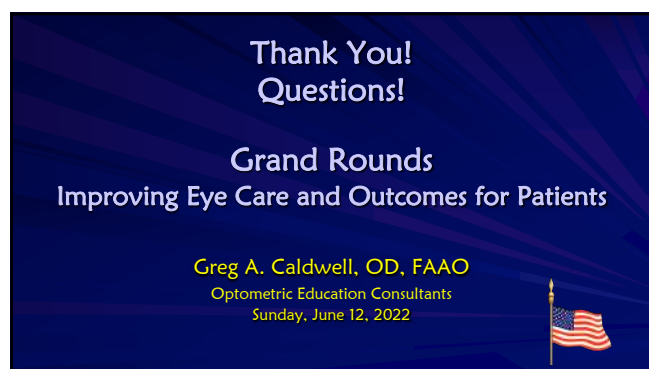
129



130



131



133