Angle Closure Glaucoma

Danica J. Marrelli, OD, FAAO
University of Houston College of Optometry
Dmarrelli@uh.edu

Financial Disclosure

- I have received consulting and/or speaking fees from:
  - Carl Zeiss Meditec
  - Allergan
  - Bausch & Lomb
  - Ivantis
  - Novartis
  - Santen

Ultrasound biomicroscopy (UBM) images used with permission from The Ocular Imaging Center of the New York Eye & Ear Infirmary

Epidemiology of Angle Closure

- Accounts for ~25% of glaucoma cases
  - ~80 million people worldwide with glaucoma
  - ~60 million with open angle glaucoma
  - ~20 million with angle closure glaucoma
    - 26.6 million angle closure by 2050 (18.4m in Asia)
  - Asymptomatic disease in 75% of cases
- Accounts for ~ 50% of blindness due to glaucoma
  - In China, primary angle closure glaucoma accounts for 91% of bilateral blindness from glaucoma

Differing Presentations of Angle Closure: SYMPTOM-BASED

- Acute
- Sub-acute
- Chronic

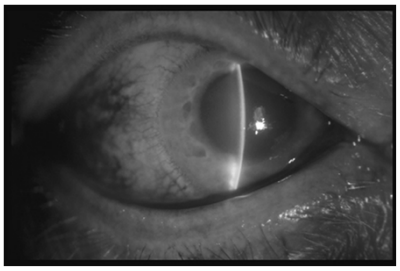

- Problems with symptom-based classification

Etiology/Mechanism of Angle Closure

- Physical crowding of anterior segment and resultant contact between iris and trabecular meshwork (TM) leads to increased IOP
  - Physical obstruction of TM: rapid rise in IOP
  - Prolonged iridotrabecular contact (ITC) may result in PAS
  - Intermittent frictional contact over prolonged period of time may damage TM architecture and function

What causes ITC? (i.e. where is the problem?)

- Pupil block (major contributor)
- Anterior, non-pupillary block (ciliary body)
  - Plateau iris configuration
  - Plateau iris syndrome
  - Pseudo-plateau iris
- Lens-induced
  - Phacomorphic
  - Subluxation of lens
- Retro-lenticular forces
  - Malignant glaucoma
  - Choroidal effusion/ciliary body rotation

Pupillary Block

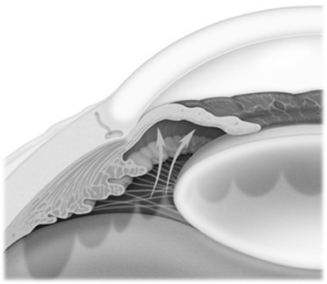

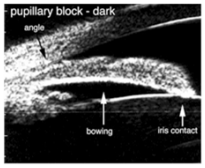

Plateau Iris Configuration

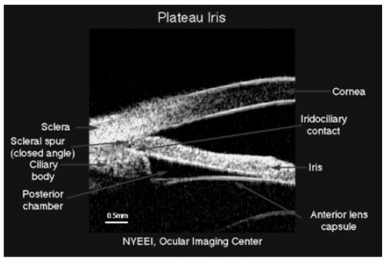

NOT a pupillary block mechanism

Retrolenticular forces

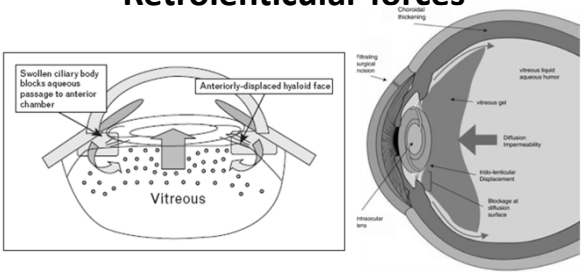

- Forces posterior to the lens push the lens-iris diaphragm forward
- "Aqueous misdirection" following cataract or glaucoma drainage surgery
- Swelling or anterior rotation of CB with subsequent forward movement or rotation of lens-iris diaphragm (shallow supraciliary detachment, ciliary effusion, etc)

Classification of Angle Closure (Old)

- <u>Primary Angle Closure</u>
  - With Pupillary Block
    - Acute/Subacute/Chronic
  - Without Pupillary Block (Iris Plateau)
- <u>Secondary Angle Closure</u>
  - With Pupillary Block
    - Lens-induced
    - Complete posterior synechiae
  - Without Pupillary Block
    - Anterior Pulling (NVG, ICE syndrome)
    - Posterior Pushing (Drug-induced/Choroidal Expansion, malignant glaucoma/aqueous misdirection)

Classification of Angle Closure (newer)

- Primary Angle Closure Suspect (PACS)
  - 3+ quadrants of ITC
  - No symptoms
  - No elevated IOP
  - No PAS
  - No disc or field changes
- Primary Angle Closure (PAC)
  - 3+ quadrants of ITC
  - Symptoms, elevated IOP, and/or PAS
  - No disc or field changes
- Primary Angle Closure Glaucoma (PACG)
  - ITC with structural and/or functional changes

Risk Factors for PRIMARY Angle Closure (Pupillary Block)

- Demographic
  - Older age
  - Female
  - Asian heritage
- Ocular Biometry
  - Shorter axial length
  - Shorter anterior chamber depth*
  - Lens position
  - Hyperopia

Diagnosis of Angle Closure

- Key Questions:
  - Is pathologic AC present?
  - Has it occurred previously?
  - Could it occur in the future?
- If yes to above:
  - Why is the angle narrow? (*where* is the problem)
  - Has there been damage to ocular tissue?
  - Is the damage a threat to vision?

Detection of Angle Closure

- Gonioscopy
- Ultrasound biomicroscopy
- Anterior segment OCT
- Provocative testing

Gonioscopy

- The reference standard for dx of angle closure
- Advantages:
  - Inexpensive
  - Quick
  - Dynamic (synechiae vs appositional closure)
- Disadvantages:
  - Subjective
  - Patient cooperation
  - Direction of gaze
  - Not quantifiable
  - Different classification systems

www.gonioscopy.org

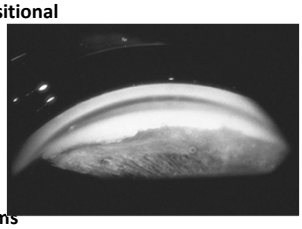

Gonioscopy

- Tips:
  - Room lights OFF
  - Minimal light needed to see structures
  - Don't indent eye
  - Observe the corneal wedge
- Four Questions:
  1. Does the iris touch the TM?
  2. If not, is there evidence it has before?
  3. If so, is the contact reversible?
  4. If not, how much synechial closure is there?

Ambient Illumination – It Makes a Difference!!!

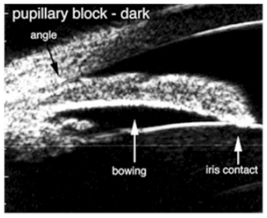

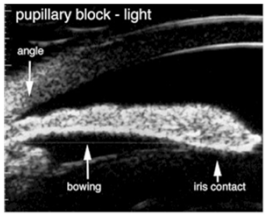

Gonioscopy

- Indirect Gonioscopy lenses



Gonioscopy

- Clinical Landmarks
  - Schwalbe's Line
  - Trabecular Meshwork
  - Scleral Spur
  - Ciliary Body
- Visibility of landmarks depends on concavity of angle, depth or angle, and insertion point of iris

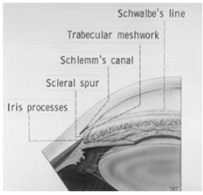

Gonioscopy Classification

- **Shaffer System**
  - **IV: iris/TM angle is 45 degrees**
  - **III: iris/TM angle is 20-45 degrees**
  - **II: iris/TM angle is 20 degrees**
  - **I: iris/TM angle is 10 degrees**
  - **Slit: iris/TM angle less than 10 degrees**
  - **O: Iris is against the TM**

Shaffer Grading System

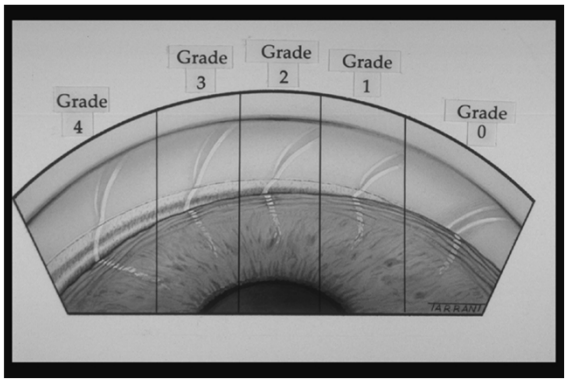

Gonioscopy Classification

- **Spaeth Grading System:**
  - **Expands Shaffer system to describe peripheral iris contour & insertion of the iris root as well as the effect of indentation**

Spaeth Grading System

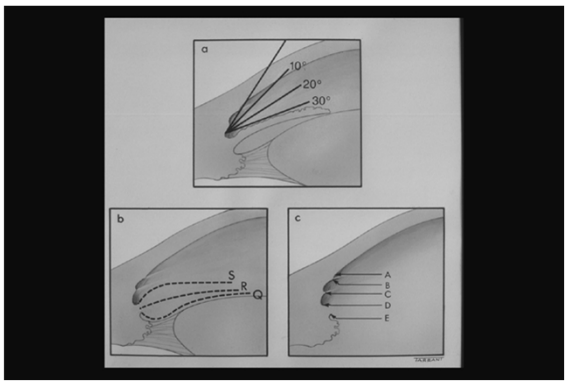

Peripheral Anterior Synechiae

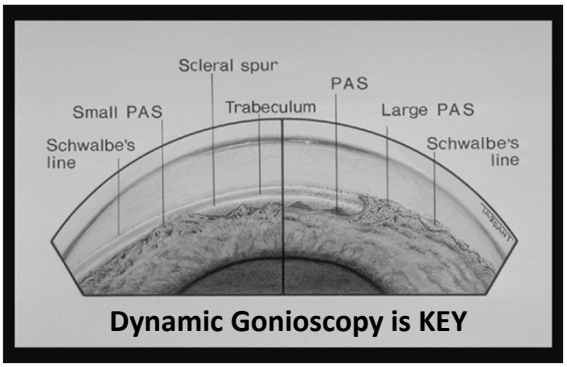

Dynamic Gonioscopy is KEY

Indentation Gonioscopy

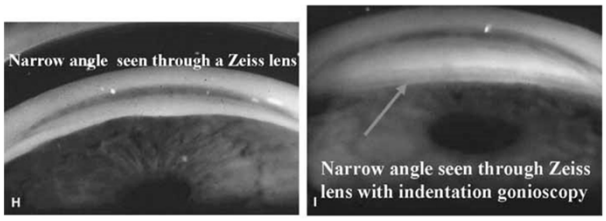

Peripheral Anterior Synechiae

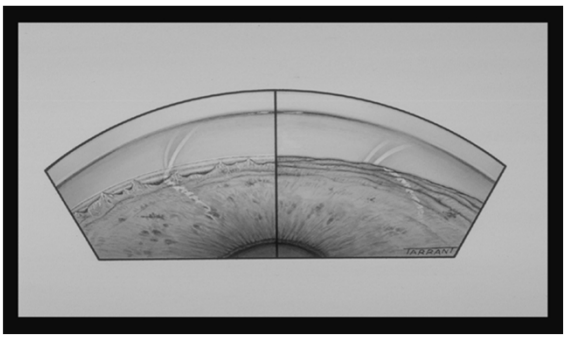

Peripheral Anterior Synechiae

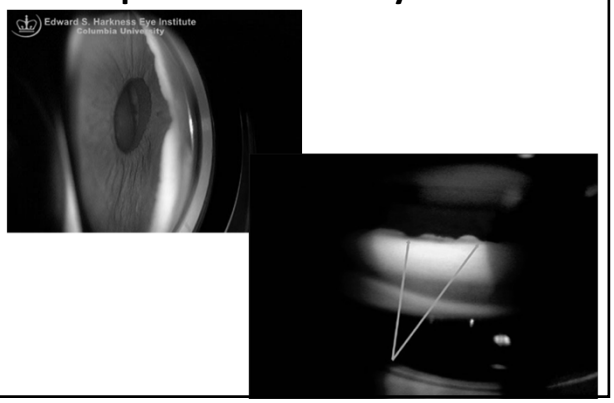

"Double-Hump" Sign in Plateau Iris Configuration

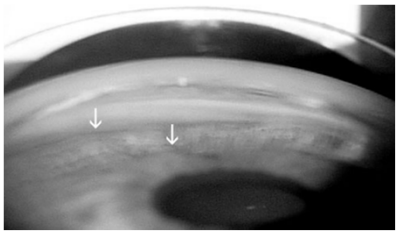

Ultrasound Biomicroscopy

- **Advantage:**
  - **Excellent delineation of structures behind iris pigment****
  - **Excellent in detecting plateau or pseudo-plauteau**
- **Disadvantage:**
  - **Requires patient in supine position**
  - **Requires water bath (older instrumentation)**
  - **Highly dependent on technician skill**

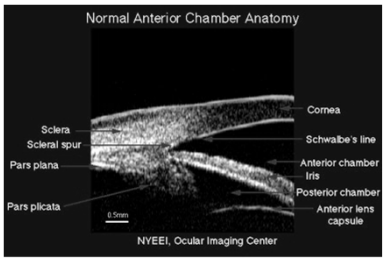

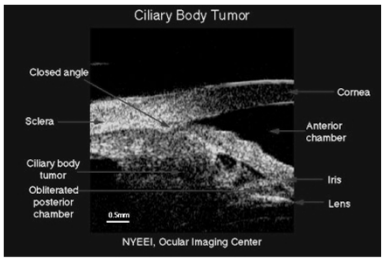

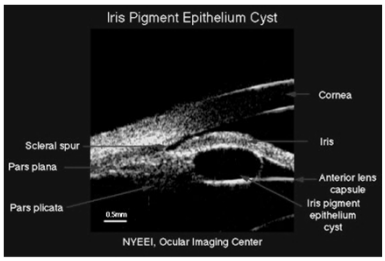

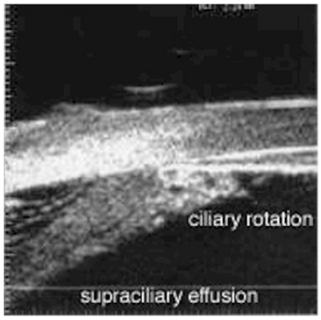

Anterior Segment OCT

- **Advantage:**
  - **Very high resolution**
  - **Rapid technique**
  - **No contact required**
- **Disadvantage:**
  - **No / limited imaging behind the iris pigment**

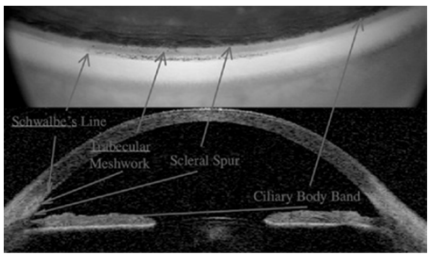

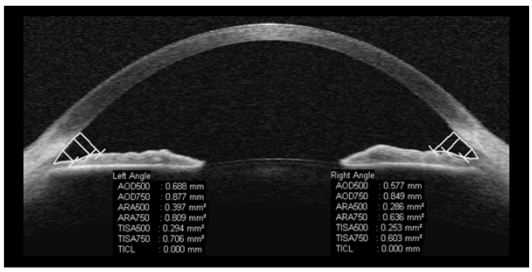

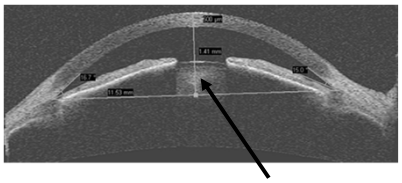

Lens Vault

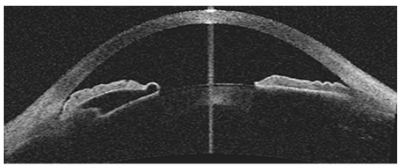

Management of Primary <u>ACUTE</u> Angle Closure (Pupillary Block)

- **Goals**
  - **Reduce IOP**
  - **Re-open AC (if possible)**
  - **Prevent recurrence of AC**
  - **Control residual IOP if irreversible TM dysfunction**

Acute Primary Angle Closure

- Reduce IOP/Re-open AC
  - Medicine:
    - Topical BB
    - Topical brimonidine/apraclonidine
    - Oral CAI (Diamox 500 mg – NOT Sequels)
    - Possibly oral hyperosmotic
    - Topical low dose pilocarpine
    - Compression gonioscopy
- Prevent recurrence of AC
  - LPI
- Repeat gonioscopy and monitoring of IOP is very important

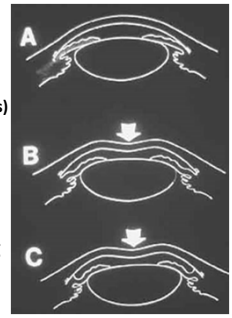

Laser Iridotomy

- WGA consensus:
  - LPI mandatory in these eyes :
    - with acute angle closure
    - Fellow eyes of acute angle closure
    - PAC patients
  - LPI optional in PACS patients
- Complications:
  - AC bleed
  - Corneal endothelial damage
  - IOP elevation
  - Accelerated cataract formation

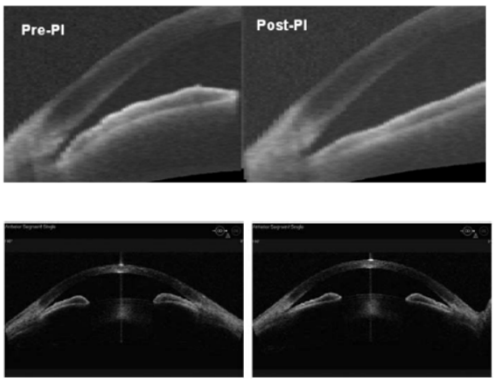

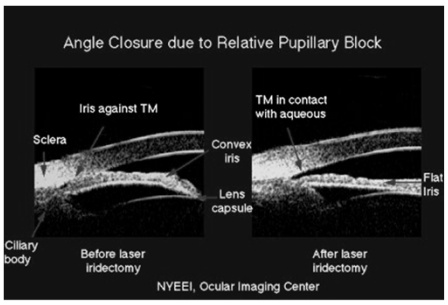

Alternatives to LPI

- Laser iridoplasty
- Lens removal

Laser Iridoplasty

- Large spot size, low energy argon laser burns
- Placement 360˚ in most peripheral portion of the iris possible
- As effective as medications in acute angle closure
- Very effective in plateau iris syndrome
- Effective in AAC patients unresponsive to treatment or in whom an iridotomy cannot be performed

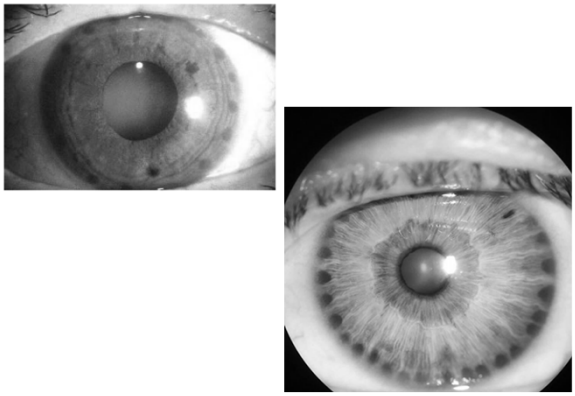

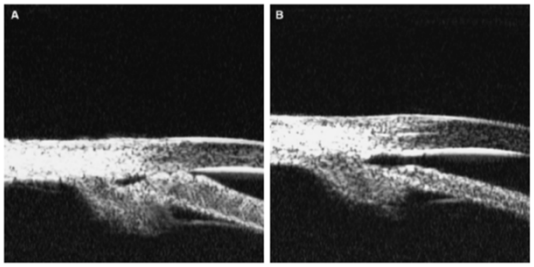

CLEAR LENS EXTRACTION

Effectiveness of early lens extraction for the treatment of primary angle-closure glaucoma (EAGLE): a randomised controlled trial

Augusto Azuara-Blanco, Jennifer Burr, Craig Ramsay, David Cooper, Paul J Foster, David S Friedman, Graham Scotland, Mehdi Javanbakht, Claire Cochrane, John Norrie, for the EAGLE study group

Summary

Background Primary angle-closure glaucoma is a leading cause of irreversible blindness worldwide. In early-stage disease, intraocular pressure is raised without visual loss. Because the crystalline lens has a major mechanistic role, lens extraction might be a useful initial treatment.

Methods From Jan 8, 2009, to Dec 28, 2011, we enrolled patients from 30 hospital eye services in five countries. Randomisation was done by a web-based application. Patients were assigned to undergo clear-lens extraction or receive standard care with laser peripheral iridotomy and topical medical treatment. Eligible patients were aged 50 years or older, did not have cataracts, and had newly diagnosed primary angle closure with intraocular pressure 30 mm Hg or greater or primary angle-closure glaucoma. The co-primary endpoints were patient-reported health status, intraocular pressure, and incremental cost-effectiveness ratio per quality-adjusted life-year gained 36 months after treatment. Analysis was by intention to treat. This study is registered, number ISRCTN44464607.

Findings Of 419 participants enrolled, 155 had primary angle closure and 263 primary angle-closure glaucoma. 208 were assigned to clear-lens extraction and 211 to standard care, of whom 351 (84%) had complete data on health status and 366 (87%) on intraocular pressure. The mean health status score (0·87 [SD 0·12]), assessed with the European Quality of Life-5 Dimensions questionnaire, was 0·052 higher (95% CI 0·015–0·088, p=0·005) and mean intraocular pressure (16·6 [SD 3·5] mm Hg) 1·18 mm Hg lower (95% CI −1·99 to −0·38, p=0·004) after clear-lens extraction than after standard care. The incremental cost-effectiveness ratio was £14 284 for initial lens extraction versus standard care. Irreversible loss of vision occurred in one participant who underwent clear-lens extraction and three who received standard care. No patients had serious adverse events.

Interpretation Clear-lens extraction showed greater efficacy and was more cost-effective than laser peripheral iridotomy, and should be considered as an option for first-line treatment.

Lens Extraction – EAGLE Study

- Effectiveness in Angle-Closure Glaucoma of Lens Extraction (EAGLE)
  - Randomized 155 patients with PAC and 263 with PACG to LPI or clear lens extraction
    - Mild/mod PACG –OR- newly diagnosed PAC with IOP >30mmHg
  - 208 patients underwent CLE; 211 LPI
  - 36 months data:
    - Mean IOP was 1.18mmHg lower in CLE group
    - FEWER medications and procedures in CLE group
  - Does this influence how we practice?

Treatment of Residual Elevated IOP

- **DESPITE LPI, laser iridotomy, or lens extraction, elevated IOP may persist.**
  - **Prostaglandin analogs very effective in lowering IOP**
  - **Typically treat similarly to POAG**
    - **Miotic therapy ineffective in eyes with significant PAS**
  - **Filtration surgery and/or tube shunts may be needed in cases with extensive PAS**

What About "Occludable" Angles (PACS)?

- **Only a small number of PACS patients will develop PAC**
- **Prophylactic LPI can result in over treatment**
- **Potential Risks**

Laser peripheral iridotomy for the prevention of angle closure: a single-centre, randomised controlled trial

Mingguang He, Yuzhen Jiang, Shengsong Huang, Dolly S Chang, Beatriz Munoz, Tin Aung, Paul J Foster*, David S Friedman*

Summary

Background Primary angle-closure glaucoma affects 20 million people worldwide. People classified as primary angle closure suspects have a higher but poorly quantified risk of developing glaucoma. We aimed to assess efficacy and safety of laser peripheral iridotomy prophylaxis against primary angle-closure glaucoma in Chinese people classified as primary angle closure suspects.

Methods In this randomised controlled trial, bilateral primary angle closure suspects aged 50–70 years were enrolled at the Zhongshan Ophthalmic Center, a tertiary specialised hospital in Guangzhou, China. Eligible patients received laser peripheral iridotomy in one randomly selected eye, with the other remaining untreated. The primary outcome was incident primary angle closure disease as a composite endpoint of elevation of intraocular pressure, peripheral anterior synechiae, or acute angle-closure during 72 months of follow-up in an intention-to-treat analysis between treated eyes and contralateral controls. This trial is registered with the ISRCTN registry, number ISRCTN45213099.

Findings Of 11 991 screened individuals, 889 individuals were randomly assigned from June 19, 2008 (889 treated and 889 untreated eyes). Incidence of the primary outcome was 4·19 per 1000 eye-years in treated eyes compared with 7·97 per 1000 eye-years in untreated eyes (hazard ratio 0·53; 95% CI 0·30–0·92; p=0·024). A primary outcome event occurred in 19 treated eyes and 36 untreated eyes with a statistically significant difference using pair-wise analysis (p=0·0041). No serious adverse events were observed during follow-up.

Interpretation Incidence of angle-closure disease was very low among individuals classified as primary angle closure suspects identified through community-based screening. Laser peripheral iridotomy had a modest, albeit significant, prophylactic effect. In view of the low incidence rate of outcomes that have no immediate threat to vision, the benefit of prophylactic laser peripheral iridotomy is limited; therefore, widespread prophylactic laser peripheral iridotomy for primary angle-closure suspects is not recommended.

Funding Fight for Sight, the Sun Yat-Sen University 5010 Project Fund, Moorfields Eye Charity, and the National Natural Science Foundation of China.

ZAP Trial

- 889 primary angle closure suspects received LPI in one eye and no treatment in other.
- Followed for minimum of 72 months
  - Primary outcomes:
    - Incident primary angle closure (elevated IOP, PAS, or Acute Angle Closure)
    - 19 TREATED EYES
    - 36 UNTREATED EYES
- WHAT DOES THIS MEAN FOR US?

Clinical & Experimental Ophthalmology

Clinical and Experimental Ophthalmology 2013; 41: 282–292 doi: 10.1111/j.1442-9071.2012.02885.x

Review

Management algorithms for primary angle closure disease

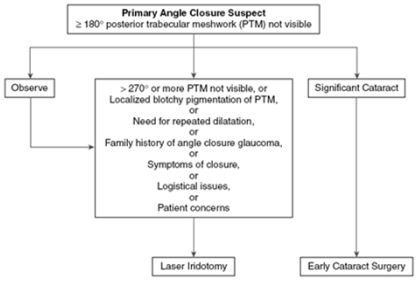

ZAP, LiGHT & SALT

Three recent studies address long-standing questions in glaucoma, and they may change your practice.

When to Do LPI

Consider LPI in patients who have the following:

- symptoms such as headaches or eye pain that suggest the onset of primary angle closure,
- a family history of angle closure,
- signs such as PAS, high IOP, or an anterior lens surface that vaults into the anterior chamber.

Or those who may need dilated exams for diabetes and/or may not follow up or may travel to remote areas.

Provocative Testing for Angle Closure

- **Dark/prone test**
  - **45 minutes in dark room, prone position**
    - **CANNOT sleep**
  - **Immediate check of IOP without turning on lights**
  - **Patient at risk: >6mm Hg increase in IOP**
  - **Problems:**
    - **Cumbersome**
    - **Impractical**
    - **Won't detect all cases**
- **WGA Consensus: Not practical or predictable**

Aqueous Misdirection/Malignant Glaucoma

- **More common in patients with narrow angles and/or PAS, following intraocular surgery**
- **See uniform flattening of AC and increased IOP**
- **Treatment: aggressive use of cycloplegics, alpha-agonists, carbonic anhydrase inhibitors; YAG the anterior vitreous in pseudophakic patients**
  - **50% of patients can be managed medically or with laser; remainder will need surgical intervention**

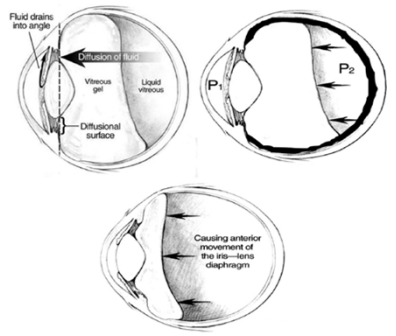

FIGURE 10. Schematic descriptions of ocular fluid movement. (Top left) An eye with posteriorly detached vitreous is shown indicating that fluid normally moves through the vitreous gel and exits the anterior chamber (AC) through the trabecular meshwork and uveoscleral pathways. (Top right) The black shaded area represents choroidal expansion, which immediately increases intraocular pressure. As aqueous humor exits the AC, the pressure differential from the posterior vitreous fluid compartment (P2) to the AC (P1) is responsible for a net movement of fluid anteriorly. This would be associated with some forward movement (toward the cornea) of the lens, intensifying resistance at the iris-lens channel (relative pupil block). In this manner, choroidal expansion could contribute to producing angle-closure in predisposed eyes. (Bottom) Choroidal expansion leads to differential pressure across the vitreous gel, as in top right figure, but in an eye with poor vitreous fluid conductivity, the pressure difference is not adequately equilibrated, as the vitreous compresses and moves forward, causing both iris and lens to flatten the AC in typical malignant glaucoma.

Quigley HA, Am J Ophthalmol 2009; 148: 657-669

Topiramate-Induced Angle Closure

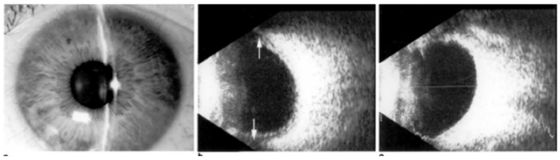

TOPIRAMATE (TOPAMAX®, TROKENDI XR®)

- FDA approved for:
  - Various Epileptic Disorders
  - Migraines
  - Pain
  - Weight loss
    - phentermine with topiramate (Qsymia®)
- Sulfa-based with carbonic anhydrase inhibition

Topiramate-induced Angle Closure

- **May cause myopic shift and acute angle closure – occurs in 3/100,000**
- **Usually occurs within the first two weeks – one case was after only two doses at 25mg/day**
- **Pathophysiology:**
  - **- Unknown what triggers reaction:**
    - **- Possible blood-eye barrier disruption?**
    - **- Hypersensitivity reaction?**
    - **- Change in membrane potential?**

  1) Choroidal effusion

  2) Anterior displacement of Iris/CB/Lens diaphragm

  3) Zonules relax

  4) Lens thickens

  5) Induced Myopia

  6) Acute angle closure
- **IOP: usually below 40**
  - **- Some degree of CB shutdown with detachment**
  - **- Carbonic Anhydrase inhibition**

OCT

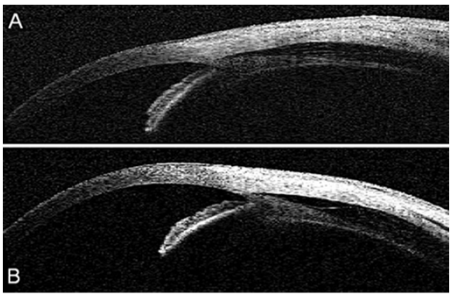

- **Fig. 2** - *Anterior segment optical coherence tomography shows bilateral, shallow, anterior ciliochoroidal detachments and angle closure with anterior rotation of the ciliary body* (**A,** *right eye*, **B,** *left eye). van Issum et al.* "Topiramate-induced acute bilateral angle closure and myopia: pathophysiology and treatment controversies."

Treatment – DIFFERENT THAN PRIMARY ANGLE CLOSURE!!!

- Discontinuation of Topamax
- Strong, short course of cycloplegic:
  - 1 or 2 doses generally sufficient

  1) Relaxes ciliary muscles
  2) Iris/Lens/CB diaphragm displace posteriorly
  3) Zonules tighten
  4) Angle opens/Myopia reduced
- Pilocarpine contraindicated:
  - Causes ciliary spasm, exacerbating choroidal detachment
  - Slightly pro-inflammatory

Treatment continued

- IOP – lowering agents:
  - Beta-blockers and Alpha-agonists typically first choice
  - Prostaglandins effective but not first choice due to pro-inflammatory properties & because of delayed onset of effect
  - Topical CAIs also effective but not commonly used since they are Sulfa-based, and thus chemically related to Topiramate (although no incidences of angle closure have been reported with topical CAIs)
- Steroids:
  - Tighten capillary junctions as well as decrease CB swelling
- Surgical:
  - LPI is not effective because mechanism is not pupillary block
  - Drainage of suprachoroidal fluid – very rarely done (usually medical therapy is sufficient)
  - Trabeculectomy/Filtering surgery - only if PAS formed after resolution

Topamax-induced Angle Closure - Treatment

- NO PILO
- NO DIAMOX
- NO INDENTATION

- YES: AQUEOUS SUPPRESSANTS, CYCLOPLEGICS, STEROID

Management of Secondary AC

- **With pupillary block:**
  - **Lens-induced**
  - **Posterior synechiae**
- **Without pupillary block:**
  - **Anterior pulling:**
    - **NV: immediate treatment of retina**
    - **ICE: medical management, filter/tube**
  - **Posterior pushing:**
    - **Drug-induced: D/C drug**
    - **Choroidal effusions: IOP-lowering meds, steroids, atropine**
    - **Aqueous misdirection: mydriatics, acetazolamide, vitrectomy and/or nd:YAG to anterior vitreous face**

Conclusion

- **Angle closure and angle closure glaucoma are <u>more common</u> that we may think**
- **<u>Acute</u> angle closure is *not* the most common presentation of angle closure**
- **<u>Pupillary block</u> is not the ONLY cause of angle closure**
- **The optometrist must be alert to the possibility of angle closure in your practice**
  - **Become proficient at gonioscopy with compression**
  - **Remember to re-gonio patients**
- **LPI is not the end of the story…**

Thank you for your attention!

Questions?

Dmarrelli@uh.edu