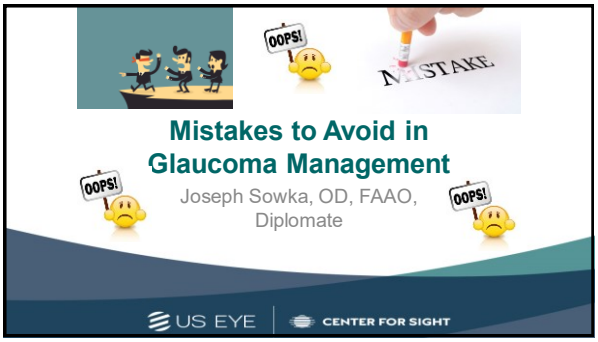

1

2

MISTAKE TO AVOID

- Not recognizing a neurologic field
- Thinking glaucoma causes optic disc pallor
- Diagnosing NAAION in glaucoma patients
- Not recognizing when the OCT is wrong
- Treating red disease
- Not treating real disease
- Changing therapy based upon one bad IOP or field
- Not getting enough pre-treatment…and post-treatment IOPs
- Not recognizing patients who will likely do well
- Not identifying patients who likely will not do well.

4

MISTAKE TO AVOID

- Not recognizing a neurologic field

5

74 YOF

- Diagnosed with glaucoma in Jamaica
- Ran out of meds: IOP 20 mm OU
- 20/50 OD, 20/40 OS
- NS 2+
- PERRL(-)RAPD

6

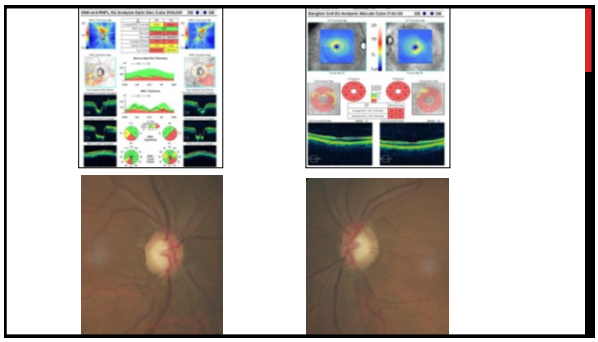

7

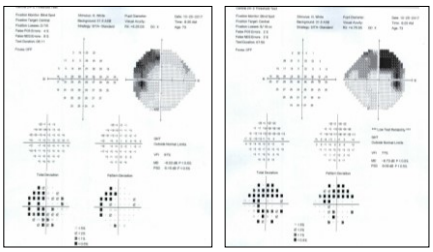

8

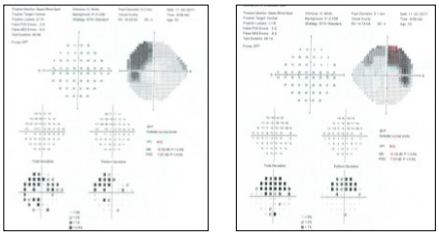

9

FINDINGS: There is a large T1 hypointense and T2 iso- to hyperintense lesion extending between the sella into the suprasellar region showing heterogeneous enhancement on the post-contrast images measuring 2.7 cm craniocaudal x 2.1 cm AP x 2 cm transverse. Findings are compatible with a pituitary macroadenoma. It is resulting in compression of the optic chiasm and slightly compressing upon the hippocampus. There is preservation of the signal void of the cavernous carotids. There is possible extension into the cavernous sinus medially. There is slanting of the floor of the sella.

The ventricles are in midline. There are multiple bilateral periventricular and subcortical T2 hyperintensities most commonly representing chronic small vessel ischemia in this age group.

The globes are symmetric. There is no lens dislocation. The post-septal soft tissues are preserved with no definite intra- or extraconal mass. The optic nerves are symmetric at the orbital level showing no abnormal enhancement.

IMPRESSION:
1. Large heterogeneous enhancing sella/suprasellar mass resulting in compression of the optic chiasm compatible with a pituitary macroadenoma.
2. Bilateral periventricular and subcortical T2 hyperintensities compatible with chronic small vessel ischemia.

10

65 YOF- POAG OU

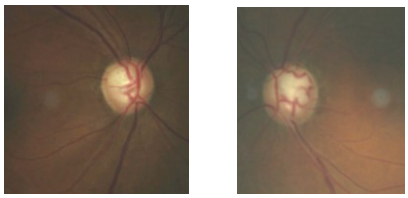

Peak IOP unknown; s/p SLT OU and on latanoprost at first visit.

11

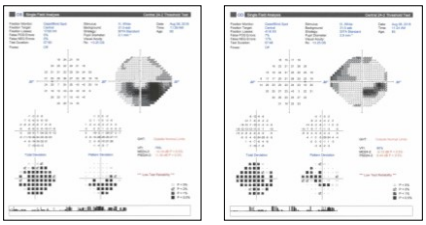

Oh, by the way, she remembered waking up 10 years ago unable to speak for several hours.

12

MISTAKE TO AVOID

- **Thinking glaucoma causes optic disc pallor**

14

RULE

Pallor in excess of cupping indicates something other than, or in addition to, glaucoma

15

RULE

Nothing notches a nerve like glaucoma

16

IN THE AGE OF IMAGING, DO WE REALLY NEED FIELDS?

- **54 YO Nigerian man**
- **Referred for glaucoma management**
- **Told he had glaucoma 6 years earlier- no Tx**
- **6/9 OD; HM OS**
  - Vision loss from glaucoma- not coming back
- **30 mm Hg OD; 23 mm Hg OS**
  - Lumigan- 17 mm Hg OD, 15 mm Hg OS

17

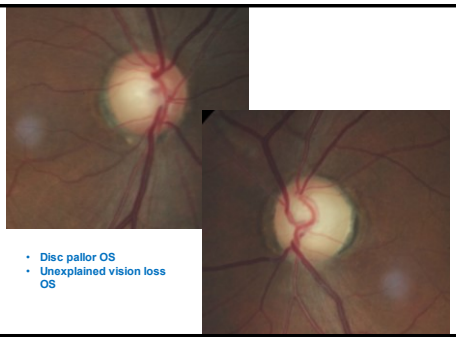

- **Disc pallor OS**
- **Unexplained vision loss OS**

18



Do we really need fields in this case?

19

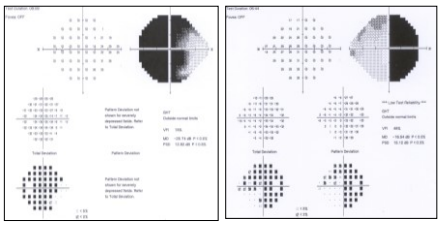

Yes, we still need to do fields in the age of imaging.

Sometimes its not glaucoma

20

MISTAKE TO AVOID

- Diagnosing non-arteritic anterior ischemic optic neuropathy in glaucoma patients

23

NAAION IS A GREAT DIAGNOSIS OF CONVENIENCE

- There is no test to conclusively diagnose it
- There is no treatment so nothing that you need to do for it
- It's a great explanation for pallor in a glaucoma patient
- But… 97% of NAAION patients have c/d of 0.2/0.2 or less.
- NAAION is a disease of non-cupping and glaucoma is a disease of *cupping*.

24

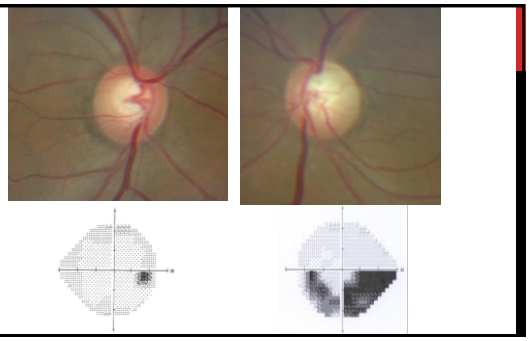

25

MISTAKE TO AVOID

- Not recognizing when the OCT is wrong

27

ISSUES IN IMAGING

- OCT is not a Silicon Valley Rumplestilskin. You cannot put in straw and get out gold
- The use and overemphasis of imaging technology to the exclusion of additional clinical findings and assessment of risk will put patients in peril.
- Exactly how much confidence should an OCT give you as to whether or not a patient has glaucoma?
  - Depends how much confidence you had before you imaged the patient.

28

28

ISSUES IN IMAGING

- Normative Database
- Signal Quality
- Blink/Saccades
- Segmentation Errors
- Media Opacities
- Axial Length

29

29

WHAT TO LOOK FOR WHEN INTERPRETING OCT SCANS

- Quality score
- Illumination
- Focus clarity
- Image centered
- Any signs of eye movement
- Segmentation accuracy
- B Scan Centration
- Missing data
- Media issues
- Maculopathy for GCC scans

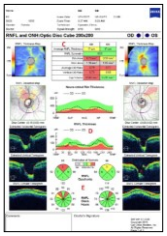

30

30

RTVue-100

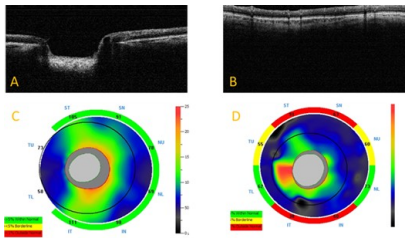

31

31

EYE MOVEMENT

32

32

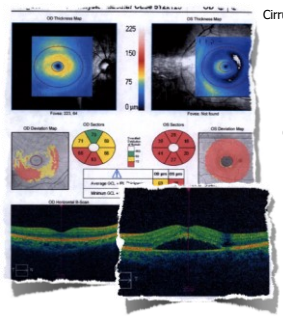

Cirrus

Accidentally find CSC when looking for glaucoma

33

33

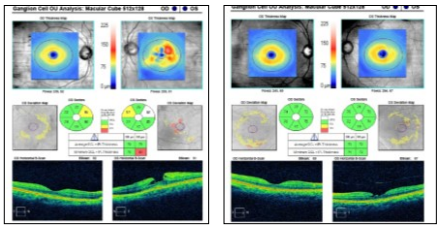

34

34

IF YOU THINK DEVICES MEASURE TISSUE ACCURATELY EVERY TIME…

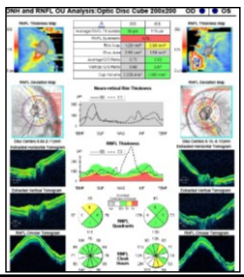

35

35

Spectralis

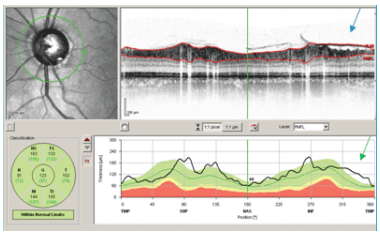

36

Spectralis

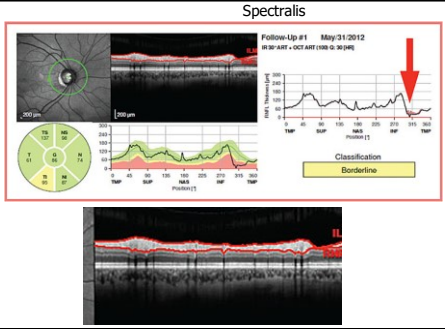

37

Spectralis

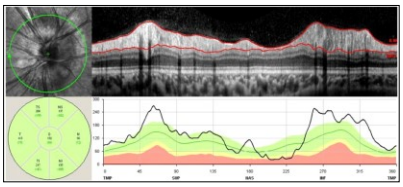

38

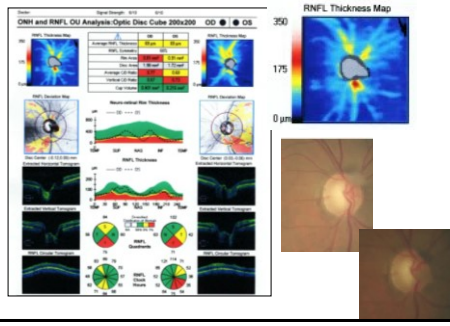

39

FLOOR EFFECT

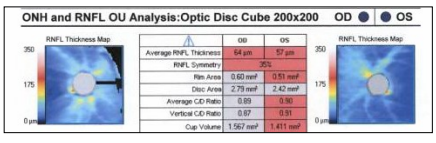

40

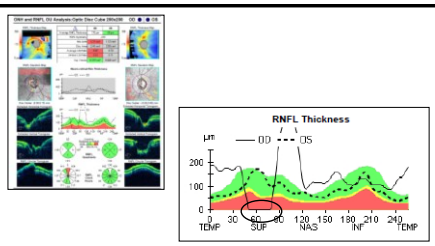

Don't make clinical decisions based upon bad data

41

MISTAKE TO AVOID

- Treating red disease

42

RED DISEASE – A NEW CLINICAL NON-ENTITY

- A supratentorial, non-glaucomatous masquerade disease
- Afflicts the educated patient (especially with Internet access) with good health care plans and/or wealth
- Debilitating to the patient and painful for the visual care provider to treat

Sherlock, NS. 2005. *Journal of Irreproducible Results and Senseless Studies*

43

SCANNING LASER OPHTHALMOSCOPY EXAMPLE OF RED DISEASE

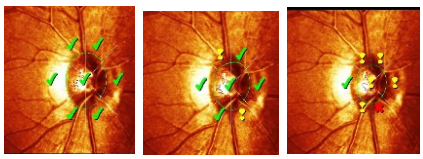

First Visit | Follow up visit #1 | Follow up visit #2

HRT3 Optic Nerve Head Changes
How long did this change take?

44

WITHIN 15 MINUTES! HRT DISC SIZING ARTIFACT

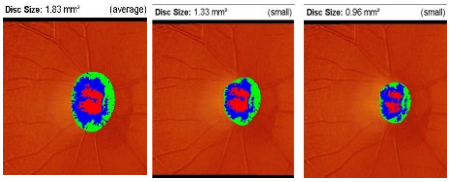

45

HELP! THE DIAGNOSTIC IMAGING DOESN'T AGREE WITH MY DIAGNOSIS!

- Low risk OHTN
- Local OD wants imaging for baseline

46

OCT RNFL NORMAL...

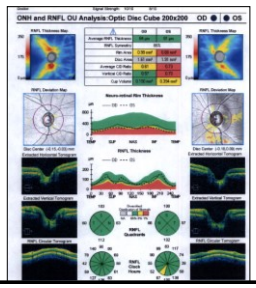

47

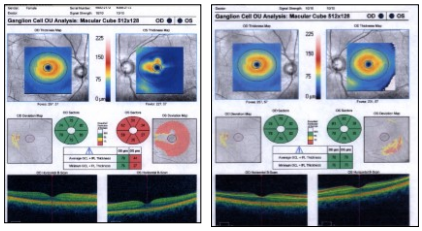

…but markedly abnormal GCC OS

Same patient, same day, same quality, GCC now normal

Signal strength: 10/10 OD, OS on both images

48

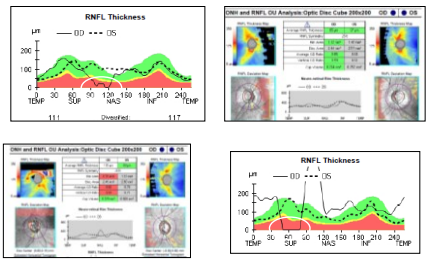

Don't make clinical decisions based upon bad data

49

CASE: 62 YOHM

- **Asymptomatic; 20/20 OD; OS**
- **PERRL (-) RAPD**
- **TA 30 mm OD, 28 mm OS**
  - Isolated measurement
  - 12-17 mm OD, 13-17 mm OS
    - 11 visits
- **Gonio: open OU w/o abnormalities**
- **CCT: 597 OU**

50

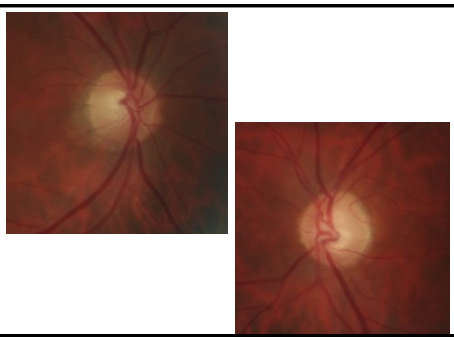

51

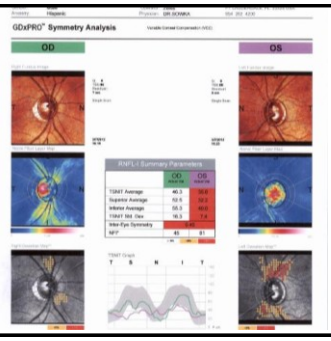

52

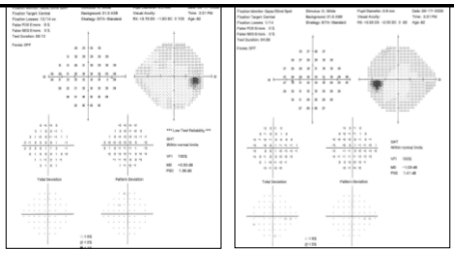

53

MISTAKE TO AVOID

- Not treating green disease

55

GREEN DISEASE– AN INSIDIOUS CLINICAL *ENTITY*

A glaucomatous process masquerading as non-disease

Afflicts inexperienced, poorly-educated doctors who simply want a machine to make all clinical decisions for them

Debilitating to the patient and painful for the visual care provider, but a boon for malpractice attorneys

Sherlock NS. 2015. *Journal of Irreproducible Results and Senseless Studies*

56

HELP! THE DIAGNOSTIC IMAGING DOESN'T AGREE WITH MY DIAGNOSIS!

- **56 YOM- Glaucoma suspect since 2012**

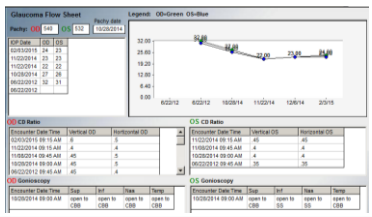

57

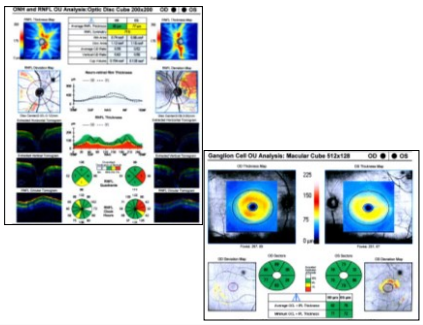

58

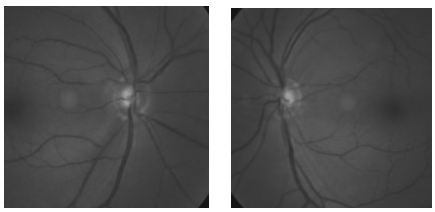

60

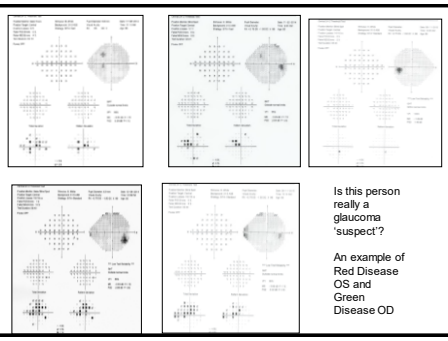

Is this person really a glaucoma 'suspect'?

An example of Red Disease OS and Green Disease OD

61

GREEN DISEASE

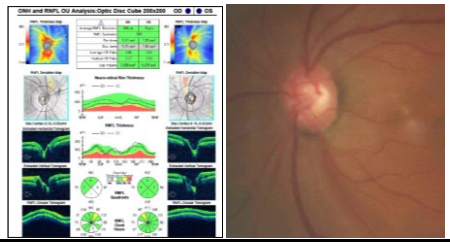

62

GREEN DISEASE

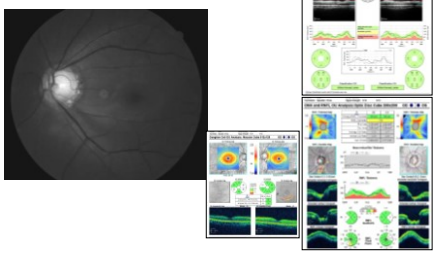

63

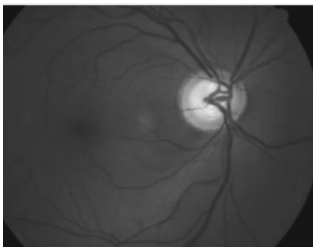

64

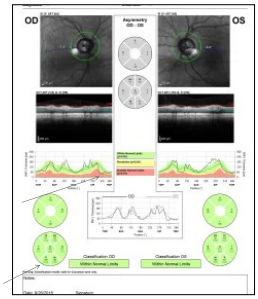

65

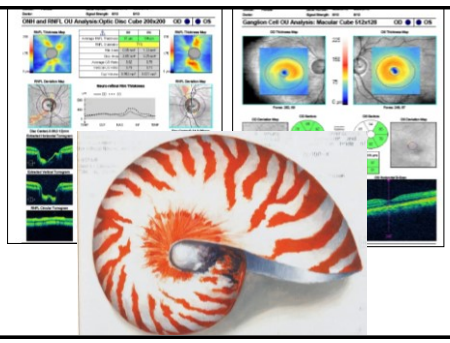

66

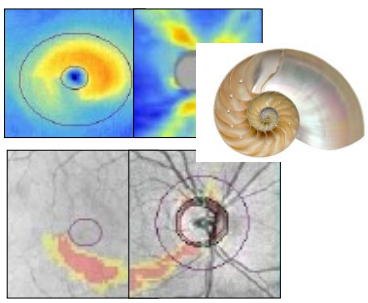

67

OCT IMAGING TAKE HOME POINTS

- Serial overlays/imaging to determine baseline (intra-session) noise
- Good signal strength
- Good segmentation without errors
- Optic nerve head exam for disc hemorrhage, pallor, myopic, and tilted nerve heads
- Determine structure-function correlation
- Follow all ancillary tests visual fields and optic nerve head photos for progression

68

CAUTIONS ABOUT IMAGING

- No current technology is better than the human eye and common sense
- Beware of "Red Disease"
- Treat Real Disease and not Red Disease
- Don't miss Green Disease
- Know the limitations of the technology: normative database, reproducibility, resolution, quality of imaging
- Technologies come and go

69

MISTAKE TO AVOID

- Changing therapy based upon one bad IOP or field
- Not getting enough pre-treatment…and post-treatment IOPs

70

MISTAKE TO AVOID

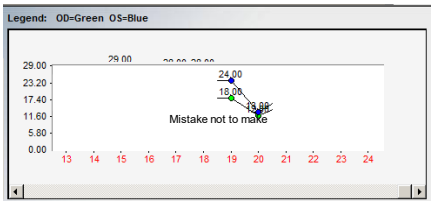

- Not getting enough pre-treatment…and post-treatment IOPs

71

MISTAKE TO AVOID

- Not recognizing patients who will likely do well

77

CLINICAL PEARL

- You can only call a glaucoma patient "well controlled" in retrospect
- Some patients progress slowly without treatment and some progress rapidly, even with treatment
  - You don't know who is who until you follow up over time

78

PATIENTS I WORRY LESS ABOUT

79

66 YOM

- Starting IOP 58 mm Hg; CCT 536
  - 20/30 OD; OS not seeing due to vascular occlusion
- Stepped regimen: Brimonidine, dorzolamide/timolol, latanoprost, pilocarpine (GlaucAll)- IOP 14 mm Hg

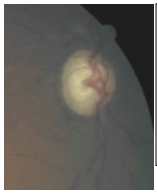
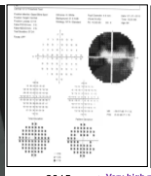
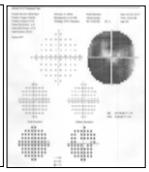

2015

- Very high peak IOP
- Exceptional IOP reduction (75%)

2017

80

61YOM

- IOP 30 mm; CCT 545
- Latanoprost, dorzolamide/timolol – 12 mm

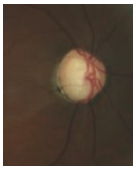
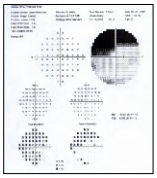


- High peak IOP
- Excellent IOP reduction (60%)

2012 2017

81

53 YOM

- Peak IOP: 32 mm OD, 43 mm OS; CCT 453 OD, 446 OS
- Latanoprost: 15-18 mm OD, 18-22 mm OS
  - Recently added dorzolamide



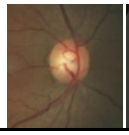
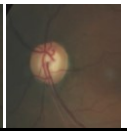

- High peak IOP
- Significant initial IOP reduction with 1 med
- Low med load

82

63 YOF: GLAUCOMA OS X 5 YEARS

- IOP typical range: 14-18 OD; 15-18 OS; CCT: 556 OD; 543 OS
- Unilateral disease; symmetrical IOP
- Pt chooses observation.


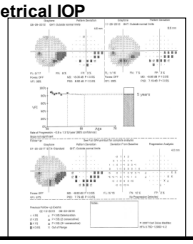

- True "normotensive" range
- Moderate disease not threatening fixation
- Stable

83

MISTAKE TO AVOID

- Not identifying patients who likely will not do well.

84

WHICH PATIENTS REPRESENT UNSUSPECTING DANGER?

85

65 YOM

- **Peak IOP 22 mm OD, 29 mm OS; CCT 560**
  - Followed 7 yrs
- **Latanoprost, dorzolamide/timolol, brimonidine- 15 mm OD, 14 mm OS**
- **Time to MMT: 3 ½ years**

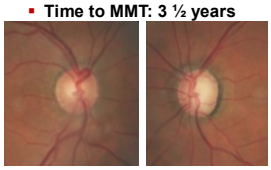

- Peak IOP not terribly high
- Short duration to MMT
- High med load for modest reduction ☹

OD

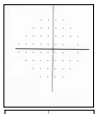

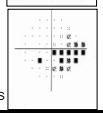

OS

Fields unchanged; possible disc change OS

86

55 YOF

- **Initial: Peak IOP??- treated since age 35**
  - Timolol; CCT 472 OD, 497 OS; Disc change OD 2010
  - Currently: latanoprost, dorzolamide/timolol, brimonidine; 15 mm OU
    - Followed 15 yrs



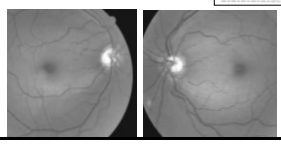



- Young age
- Long duration of treatment
- MMT
- Thin cornea ☹

87

55 YOF

- **Shows late progression on field OU at IOP of 15 mm OU**
  - Difficulty arranging surgery due to insurance
  - Pt had to leave country 4 months
  - Switched latanoprost with Rocklatan (other meds continued)
  - IOP now 09 mm OD, 10 mm OS

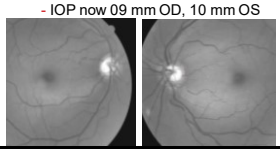



- Young age
- Long duration of treatment
- MMT
- Thin cornea ☹

88

53 YOF

- **Peak IOP: 20 mm OD, 22 mm OS; CCT: 510 OD, 508 OS**
- **Treated IOP: 12-15 mm OD, 12-16 mm OS**
  - Brimonidine, latanoprost, dorzolamide/timolol
  - Field progression documented previously

Low baseline IOP (low 20s), MMT to achieve 'modest IOP reduction, bilateral recurrent disc hemorrhages ☹

89

69 YOF: POAG OU X 11 YEARS

- **Peak IOP: 20 mm OU; CCT: 540 OD, 532 OS**
  - Dorzolamide/timolol; latanoprost OU; IOP- 15 mm OD, 14 mm OS



- Bilateral disc hemorrhages
- Low peak/baseline IOP
- Modest pressure reduction
- High med load
- Field/ disc change ☹

90

THINGS THAT GIVE ME COMFORT



91

OTHER THINGS THAT GIVE ME COMFORT

- High initial peak IOP
  - 30s and 40s better than low 20s
- Significant IOP reduction
  - Regardless of disc/ field status
- Good initial response to one medication
- Minimal medications
- High peak IOP and significant medical response

92

THINGS THAT MAKE ME UNCOMFORTABLE

93

OTHER THINGS THAT MAKE ME UNCOMFORTABLE

- Exfoliation
- Disc hemorrhages
- Rapid escalation in therapy
  - Adding 2 meds w/i 3 years
- Low peak IOP
  - Low to mid 20s bad
  - Mid teens- not so bad
- Poor initial IOP reduction
- Low peak IOP and poor initial IOP reduction

Patients worse prognosis

94

ODE TO GLAUCOMA TREATMENT

When the pressure starts high and the treated drop great,

Likely a good outcome is to be the fate.

Compliance, exfoliation and disc hemorrhage must be watched,

So the case doesn't get botched.

Most patients can be predicted,

And your Zen won't be afflicted

But some patients will surprise,

And cause your blood pressure to rise.

Lowering 22 down to 18 is not enough,

Go for 50% so they don't snuff.

Joseph Sowka, OD

95

BE AWARE OF THE GRAY AREA WHERE DANGER LURKS…

96

...MAY YOU HAVE NOTHING BUT KITTENS AND BUNNIES

97