

OCT and OCT Angiography Wellness

Why and How to Implement Early Detection into Your Practice

Greg A. Caldwell, OD, FAAO
Optometric Education Consultants

August 29, 20/20



Disclosure Statement
(next slide)

Disclosures- Greg Caldwell, OD, FAAO

- Will mention many products, instruments and companies during our discussion
 - ★ I don't have any financial interest in any of these products, instruments or companies
- Pennsylvania Optometric Association –President 2010
 - POA Board of Directors 2006-2011
- American Optometric Association, Trustee 2013-2016
- I never used or will use my volunteer positions to further my lecturing career
- Lectured for: Aerie, Alcon, Allergan, BioTissue, OptoVue
- Advisory Board: Allergan, Maculogix, Sight Sciences, Sun, Takeda
- Involve: PA Medical Director, Credential Committee
- Optometric Education Consultants- Scottsdale, St. Paul, Quebec City, Nashville, and Orlando/Disney OCT Users meeting; Owner



Resource: OCT Community for OCT and OCT-A




OCT CONNECT

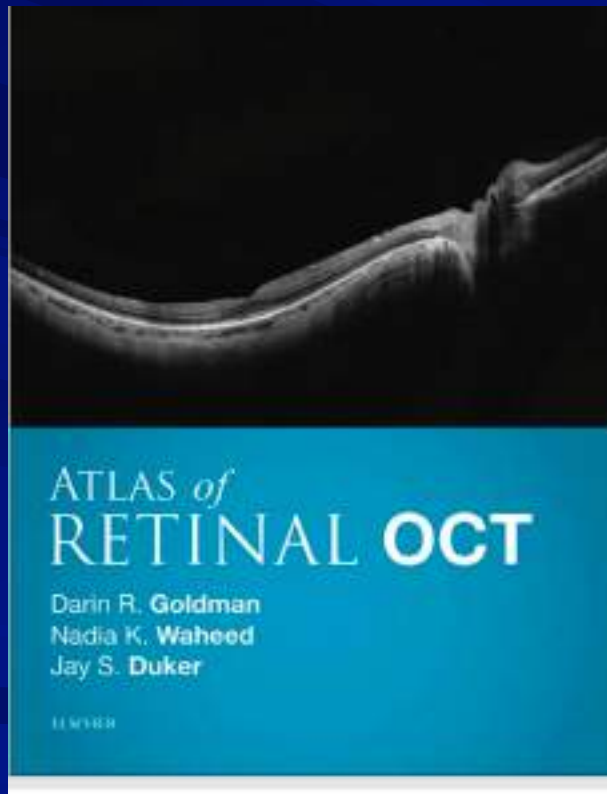
Post your questions & cases so we can #OCTConnect!



Join this group to become part of our
OCT Connect Family!




Book Resources



Optical Coherence Tomography Angiography Atlas: A Case Study Approach

Julie A. Rodman, OD MSc FAAO



\$149.95

ISBN 10 1-63001-641-2

ISBN 13 978-1-63001-641-1

200 pp Hard Cover

Pub. Date: 2019

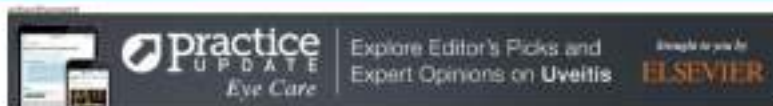Order# 66411

How Many People Here Have an OCT?

OCT, Wellness, Angiography

Daily Digest

Eye Care



JOURNAL SCANS

Recovering Vision in Corneal Epithelial Stem Cell-Deficient Eyes

Cori Leno, Andrew Day, 2019 Apr 26. *OPINION* Ahead of Print, HK Sains, H Palanca, C Boleyn, et al.
#Cornea #Ophthalmology #Contact Lenses #Cornea and External Diseases #Lentil Stem Cell Deficiency
#Ophthalmology/Ophthalmology #Primary Care Ophthalmology

Anterior Segment OCTA Assessment of Acute Chemical Injury

Am J Ophthalmol. 2019 May 06. *OPINION* Ahead of Print, SGM Fung, RM Stewart, SK Dhalla, et al.
#Ophthalmology/Ophthalmology #Cornea and External Diseases #Lentil Stem Cell Deficiency
#Ophthalmology/Ophthalmology #Primary Care Ophthalmology

Incidence, Epidemiology, and Transformation of Ocular Myasthenia Gravis

Am J Ophthalmol. 2019 May 05. *OPINION* Ahead of Print, TM Heroldts, MT Black, OD Hodge, et al.
#Ophthalmology/Ophthalmology #Ocular Eye Care #Neuro Ophthalmology #Ophthalmology/Ophthalmology #Primary
Care Ophthalmology

NEWS

Therapeutic Fused for Unilateral Optic Nerve Lesions in MS

HealthDay. 2019 May 17.
#Ophthalmology/Ophthalmology #Optic Nerve Pathology



ADVERTISEMENT

The best jobs
in medicine
and healthcare
are right here.

ELSEVIER



Published in Eye Care

Journal Scan / Research - May 11, 2019

Detection of Choroidal Neovascularization in Pigment Epithelial Detachment

Acta Ophthalmologica

[Save](#) [Recommend](#) [Share](#) [Get Topic Alerts](#)

TAKE-HOME MESSAGE

- This study evaluated the agreement between OCTA and multimodal imaging for the detection of choroidal neovascularization (CNV) in patients with pigment epithelial detachment with and without subretinal/intraretinal fluid (PED+F and PED-F). OCTA demonstrated concordance with the other modalities in determining the presence of CNV in patients with PED+F, with an accuracy of 85.45%.
- The authors suggest that the diagnosis of PED can be made without the need for dye angiography in eyes indicating signs of CNV on OCTA.

— Raza Shah, MD

Abstract

Macular and Peripapillary Angiographic Changes With Intravitreal Injections

Retina (Philadelphia, Pa.)

[Save](#) [Recommend](#) [Share](#) [Get Topic Alerts](#)

TAKE-HOME MESSAGE

- This retrospective observational study of 39 patients with various retinopathies assessed retinal perfusion density changes on OCT. Results showed that an acute change in intraocular pressure due to intravitreal injections was associated with a decrease in macular and peripapillary perfusion density.
- These findings suggest that intravitreal injections may lead to the development of glaucoma, causing damage to the macula and optic nerve.

—Raza M. Shah, MD

Abstract

This abstract is available on the publisher's site.

[Access this abstract now](#)

PURPOSE

Intravitreal injections acutely and temporarily increase intraocular pressure (IOP), and this may have cumulative long-term effects including an increased risk for glaucoma surgery. This study was designed to measure retinal perfusion density changes on optical coherence tomography (OCT) angiography and OCT thickness alterations associated with acutely increased IOP after intravitreal injections.

METHODS

Retrospective observational clinical study of 40 eyes (39 patients) with various retinopathies from October 2016 to June 2017 at a tertiary care retina clinic in NYC. Patients were older than 18 years, with vision



practice
UPDATE

ADVERTISEMENT

The best jobs
in medicine
and healthcare
are right here.

ELSEVIER

myhealthtalent.com

Published in Eye Care

Journal Scan / Research - March 30, 2019

Detection of Clinically Unsuspected Retinal Neovascularization With Wide-Field OCTA

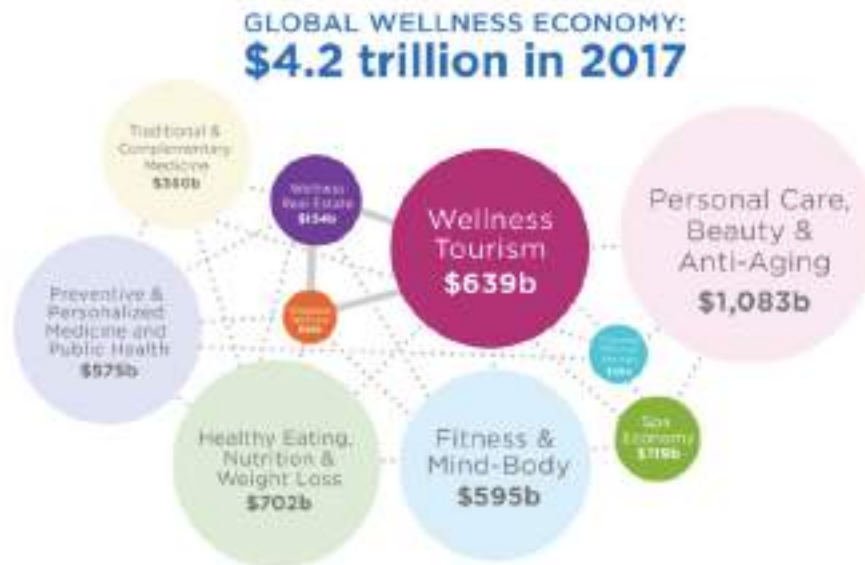Retina (Philadelphia, Pa.)

[Save](#) [Recommend](#) [Share](#) [Get Topic Alerts](#)

TAKE-HOME MESSAGE

- This study evaluated the accuracy of wide-field optical coherence tomography angiography (OCTA) for detection of clinically unsuspected neovascularization (NV) in patients with diabetic retinopathy. There were 27 participants, who underwent a clinical examination, standard 7-field color photography, and OCTA with commercial and prototype swept-source devices. Nonproliferative diabetic retinopathy was found to be mild in 13 patients, moderate in 7, and severe in 7 based on photographic grading. The conventional 6- x 6-mm OCTA detected NV in 2 eyes (7%) and the 3- x 3-mm scan detected none. Both prototype and commercial wide-field OCTA detected NV in 2 additional eyes. All eyes with OCTA-detected NV were photographically graded as severe nonproliferative DR.
- Wide-field OCTA can aid in the detection of retinal changes that would seemingly escape detection otherwise. However, the study population in this study was small, and the positive findings were particularly few, which makes it difficult to draw any significant conclusions.

Wellness Industry



• 170b

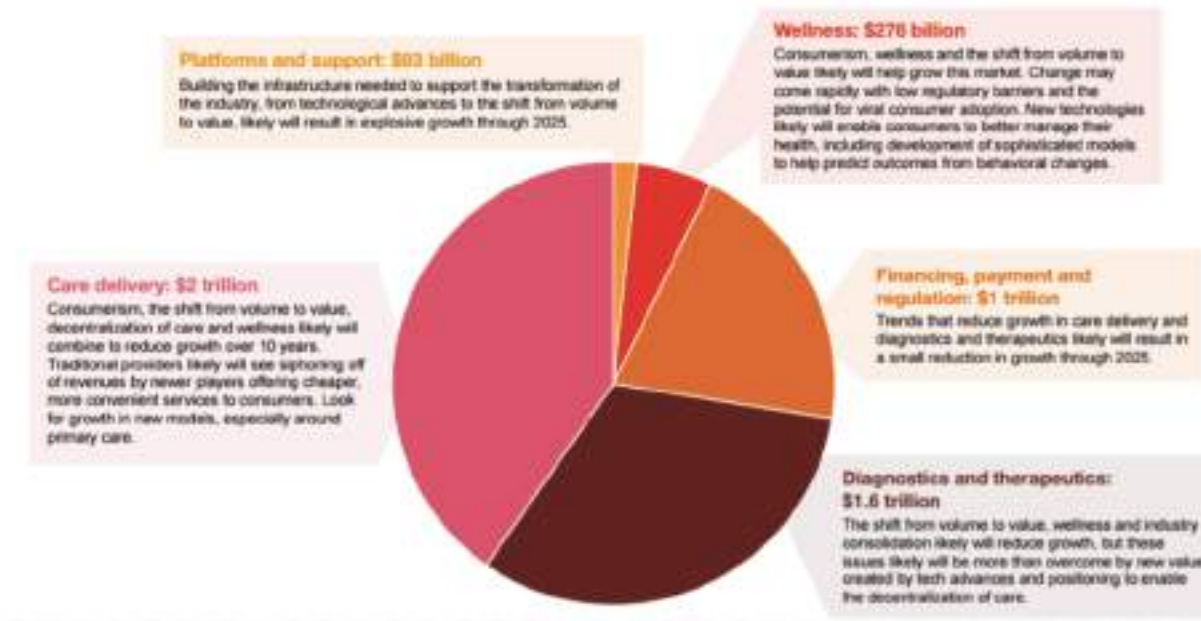


- Optometry Industry
- 65b

• Global Wellness institute 2018

Primary Medical Care

The US health industry is a \$5 trillion ecosystem dominated by care delivery. Over the next decade, the balance will likely shift, with growth in wellness and platforms and support.



- Health Institute Research 2016

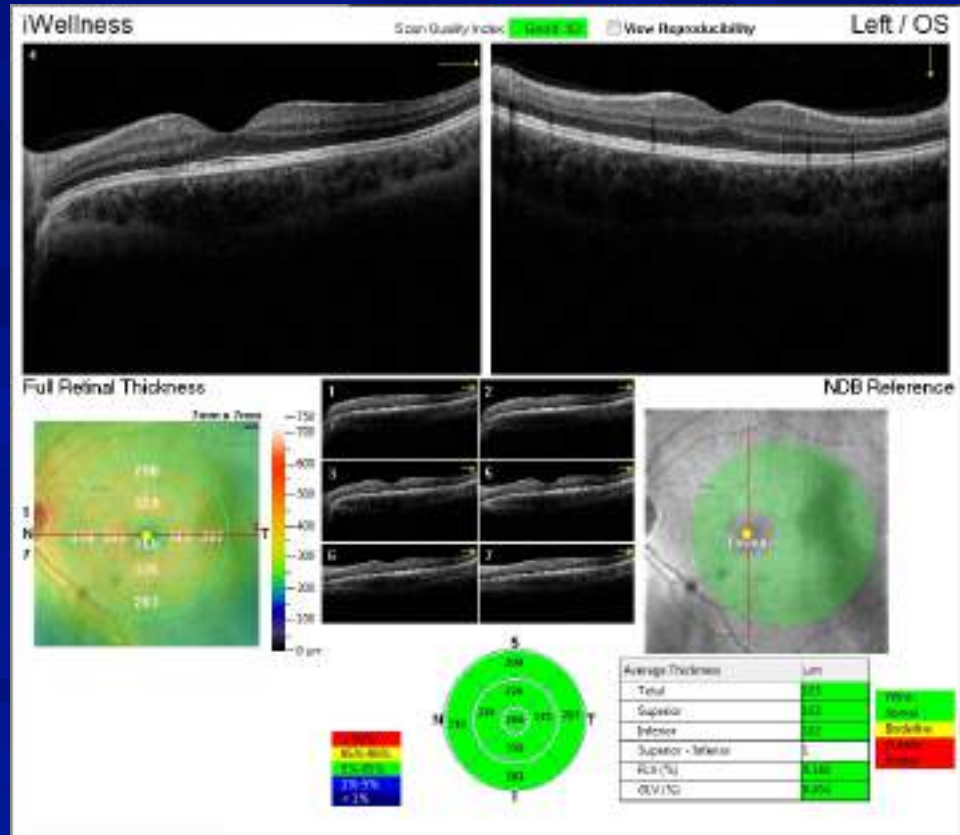
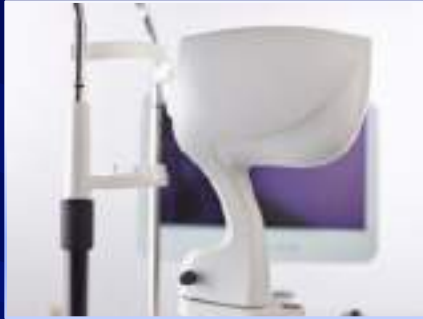My/Our Wellness Program

Our Transition

- ↳ Optos for over 15 years
- ↳ OCT Wellness for 5 years
 - ★ Retina and GCC
 - ★ Retina, GCC, angiography

iVue®

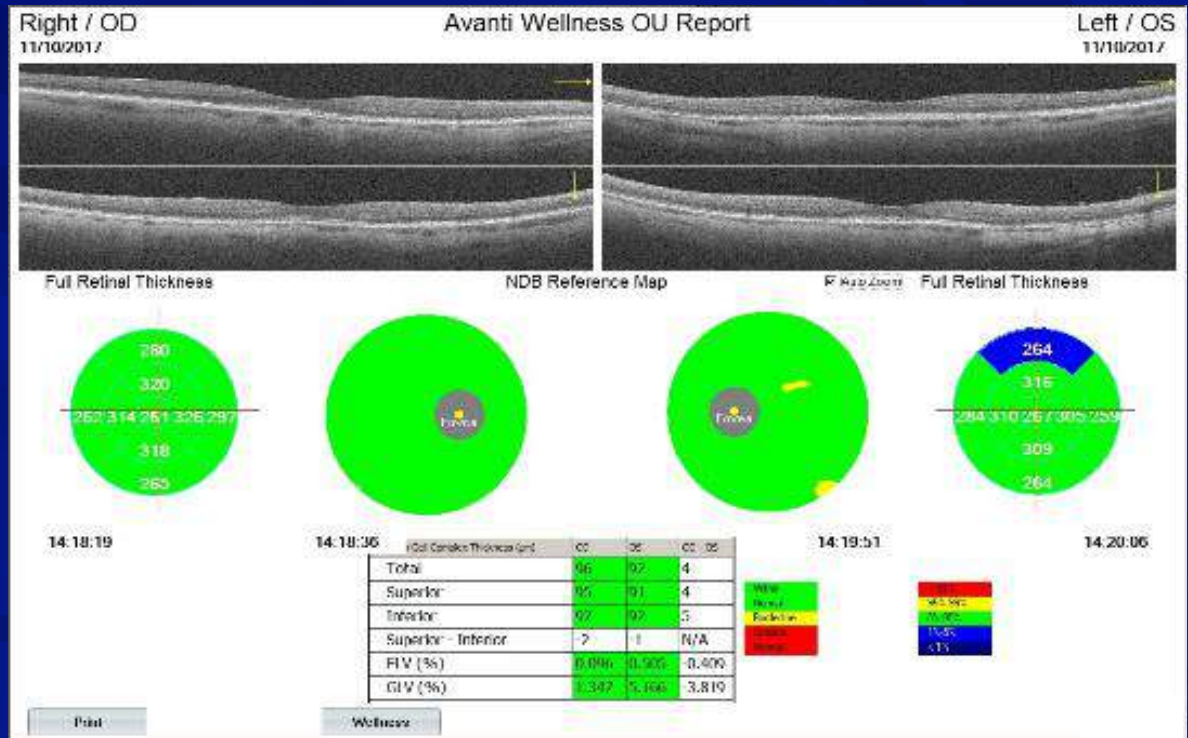
Wellness



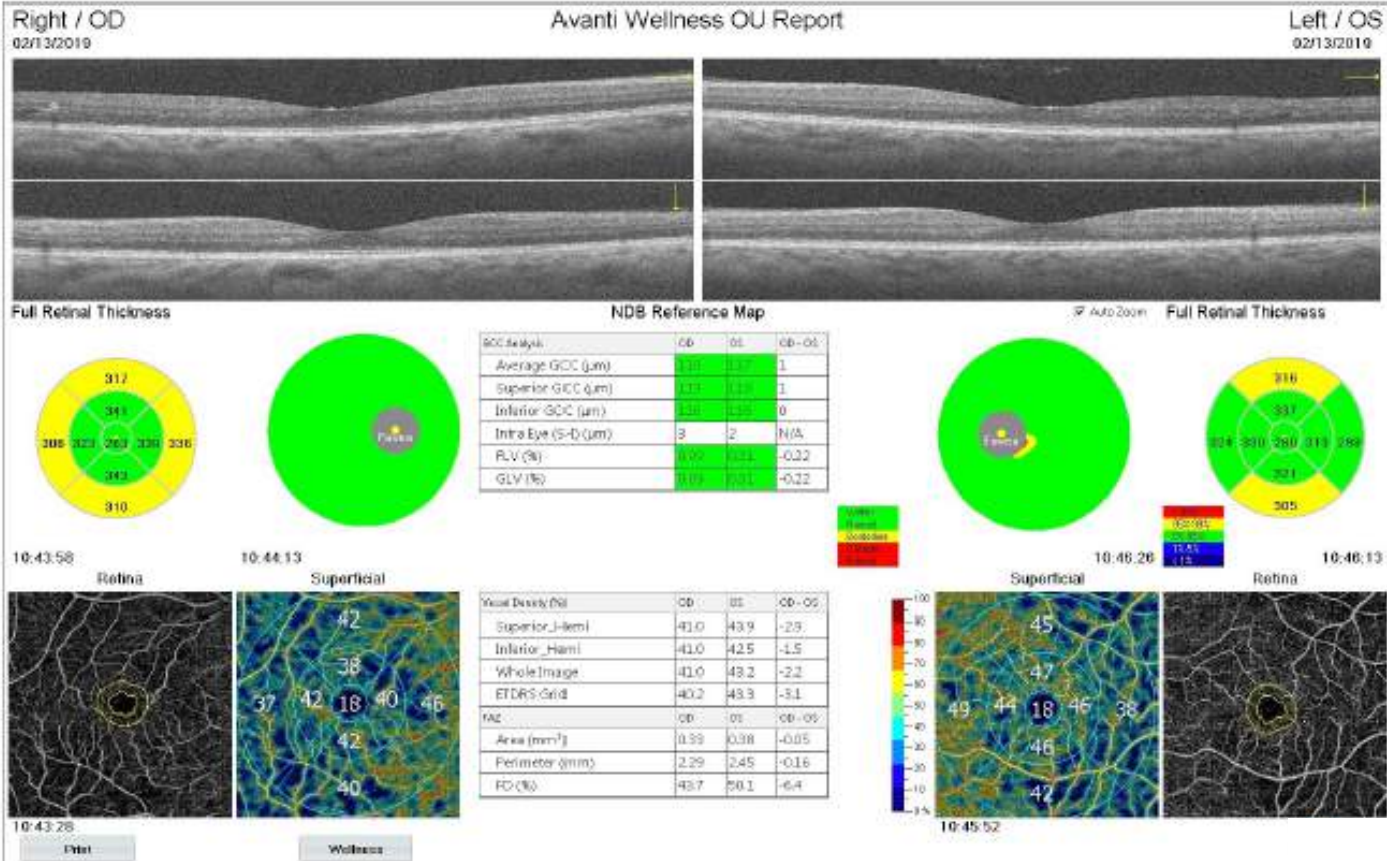
AngioVue® OCT Angiography

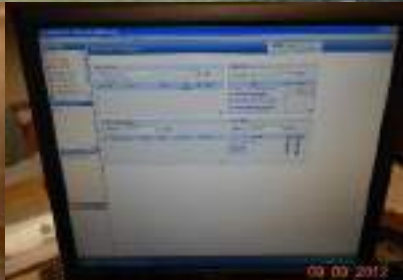
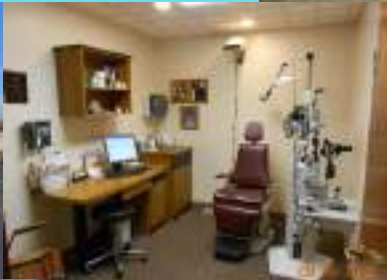

Wellness



AngioWellness





Comments

🔗 Where is Duncansville, PA?

🔗 Annual income for Duncansville, PA

★ \$42,500

🔗 OCT Angiography and Widefield Imaging

★ Enhances patient care

★ Elevates the practice

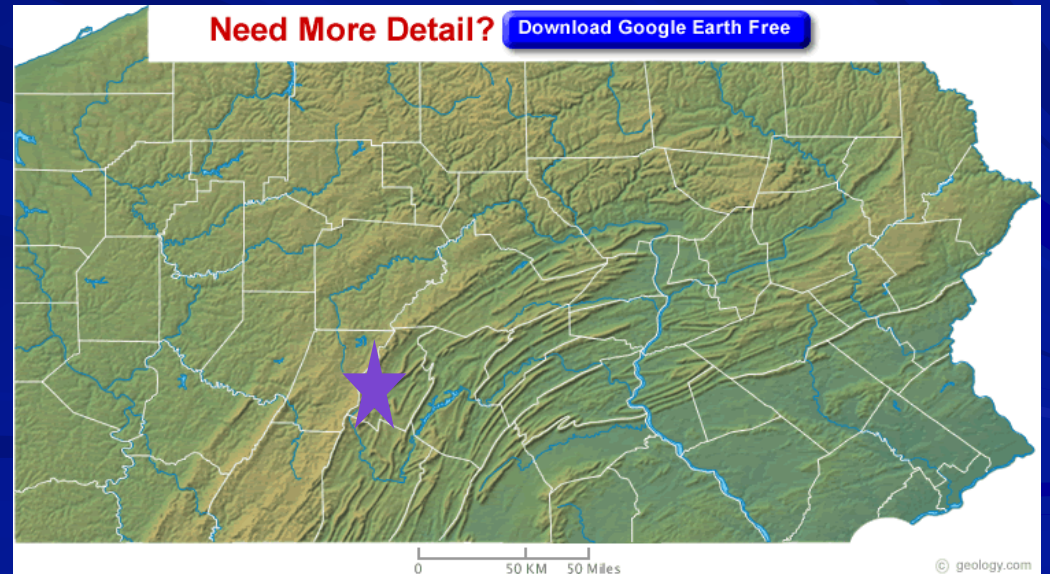
📄 Patient point of view

📄 Medical community

★ Additional benefits to the office

📄 Cash flow

📄 Stability



Optometry's Instrument

2018 with 2.8 Full Time Equivalent

Wellness

👁️ 2355 scans

👁️ Optos/Optovue Wellness

★ 1315, \$50, \$65,750

👁️ Optos/Optovue Wellness and
Retina OCT-A

★ 984, \$70, \$68,880

👁️ OCT-A

★ 37, \$35, \$1,295

👁️ OCT-Wellness

★ 19, \$35, \$665

👁️ **\$136,590**

★ **\$48,782**

Medical OCTs

👁️ 765 scans

👁️ Glaucoma

★ 92133 406

★ Approx \$37, \$15,022

👁️ Retina

★ 92134 356

★ Approx \$40, \$14,240

👁️ Anterior Segment

★ 92132 3*

★ Approx \$31, \$93

👁️ **\$29,355**

★ \$10,484

\$165,945

★ **\$59,266**

A Look at Wellness

👁️ Total wellness OCTs for 2018

- ★ 2355
- ★ 197 per month

👁️ January 1, 2019 thru December 31, 2019

- ★ 2765 wellness OCTs
- ★ 231 per month

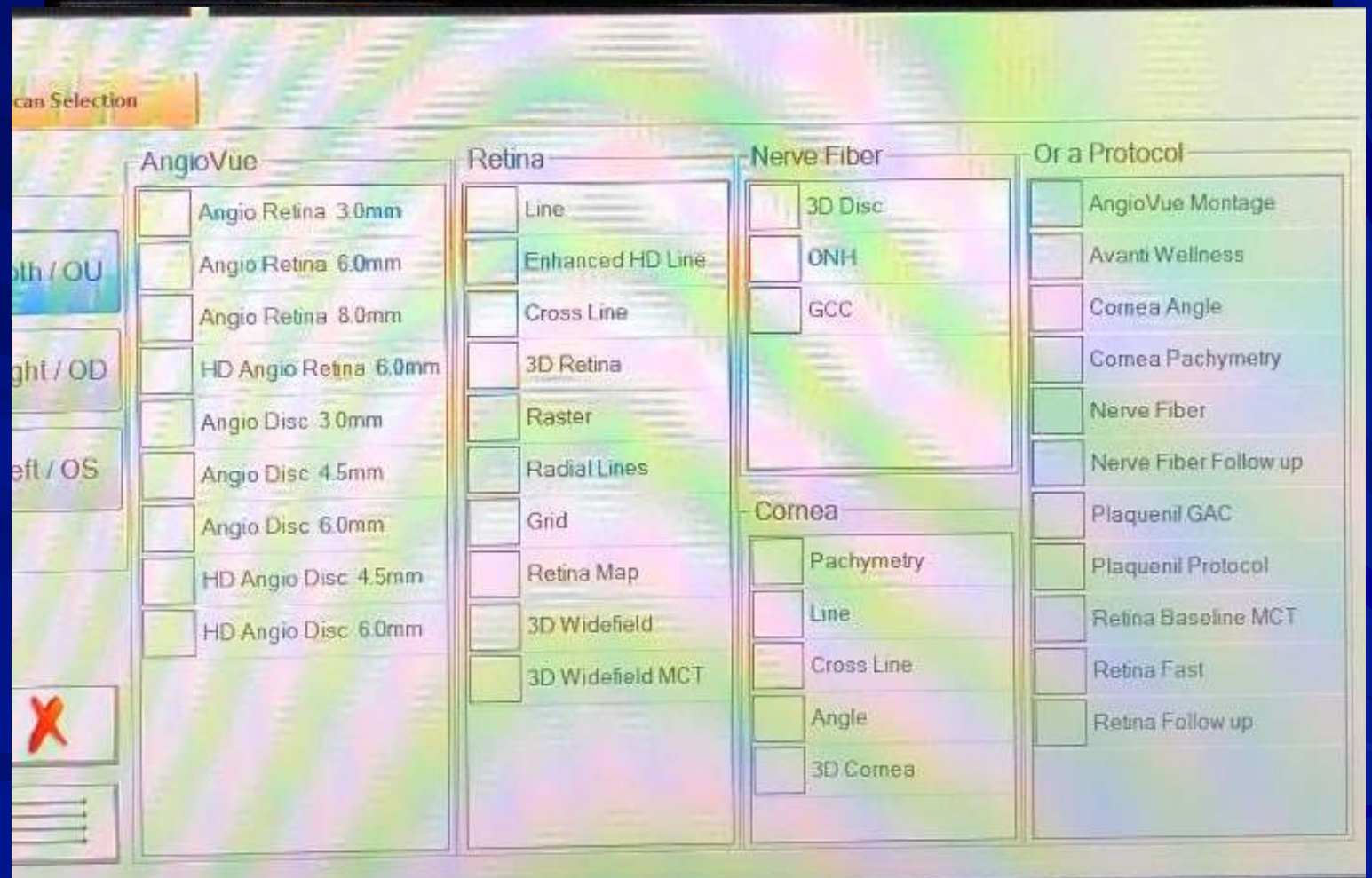
👁️ Wellness for 2020 thru August 25, 2020

- ★ 1512
- ★ June 371
- ★ July 239

👁️ OCT Angiography

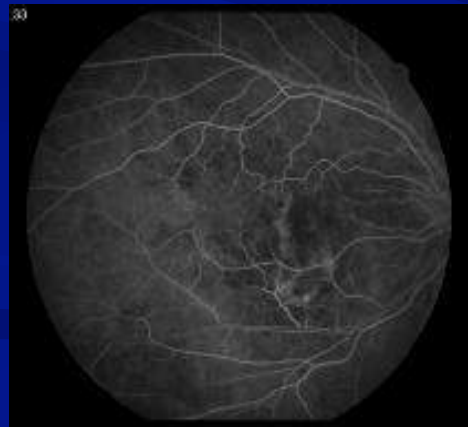- ★ Enhances patient care
- ★ Elevates the practice
 - 📄 Patient point of view
 - 📄 Medical community
- ★ Additional benefits to the office
 - 📄 Cash flow
 - 📄 Stability

A Nice Feature

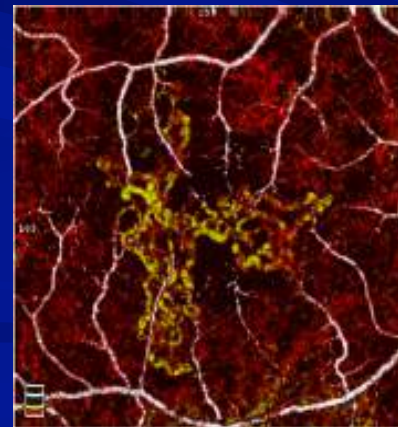


OCT Angiography A New Approach to Protecting Vision

- ▶ Non-invasive visualization of individual layers of retinal vasculature
- ▶ Pathology not obscured by fluorescein staining or pooling
- ▶ Image acquisition requires less time than a dye-based procedure
- ▶ Reduced patient burden allows more frequent imaging to better follow disease progression and treatment response

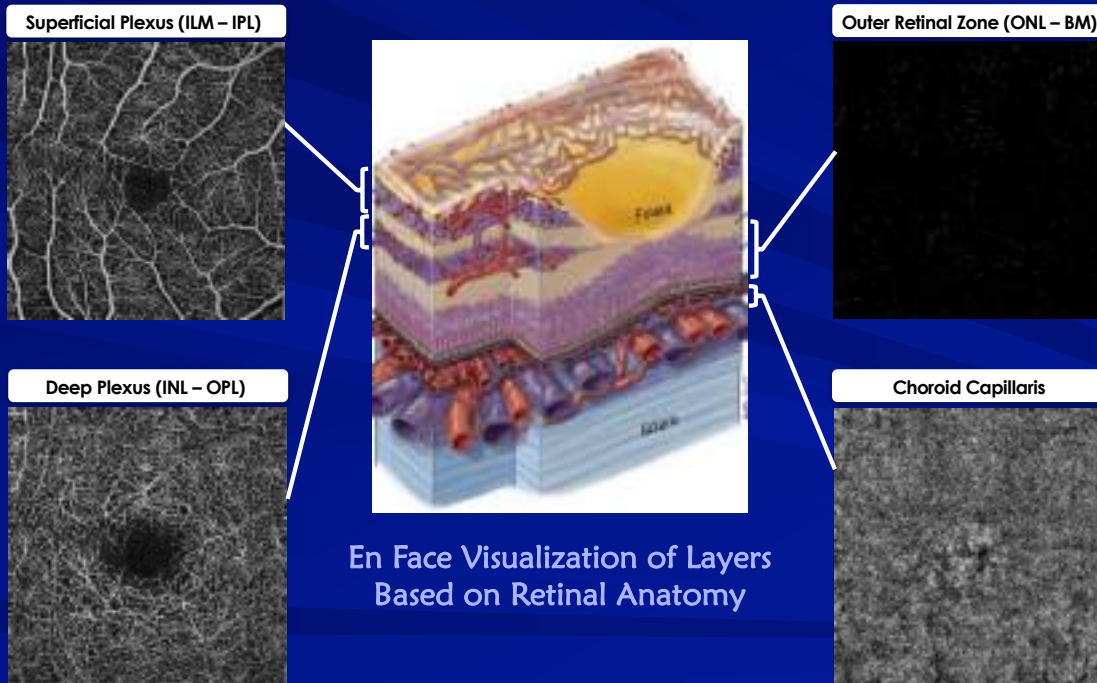


FA of CNV

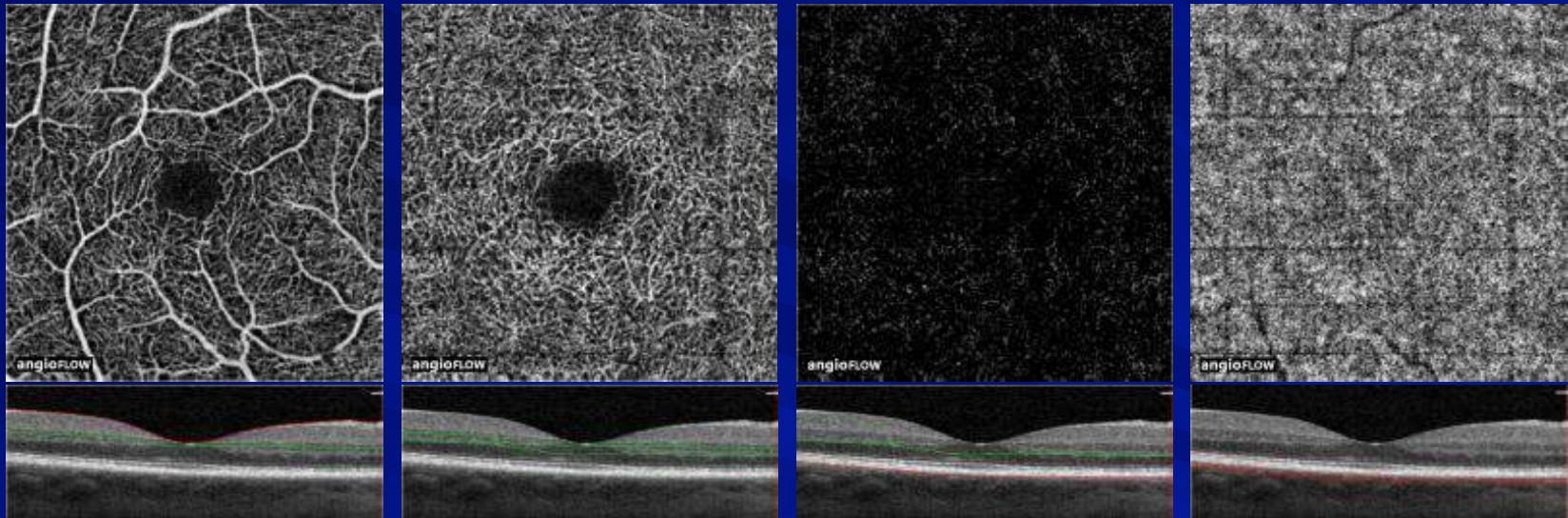


OCTA of CNV

Enface OCT-A Slabs Based on Retinal Anatomy



Normal Retinal Vasculature



Superficial Capillary Plexus

3 μ m Below ILM \rightarrow 15 μ m
Below IPL

Deep Capillary Plexus

15 μ m Below ILM \rightarrow 70 μ m
Below IPL

Outer Retina

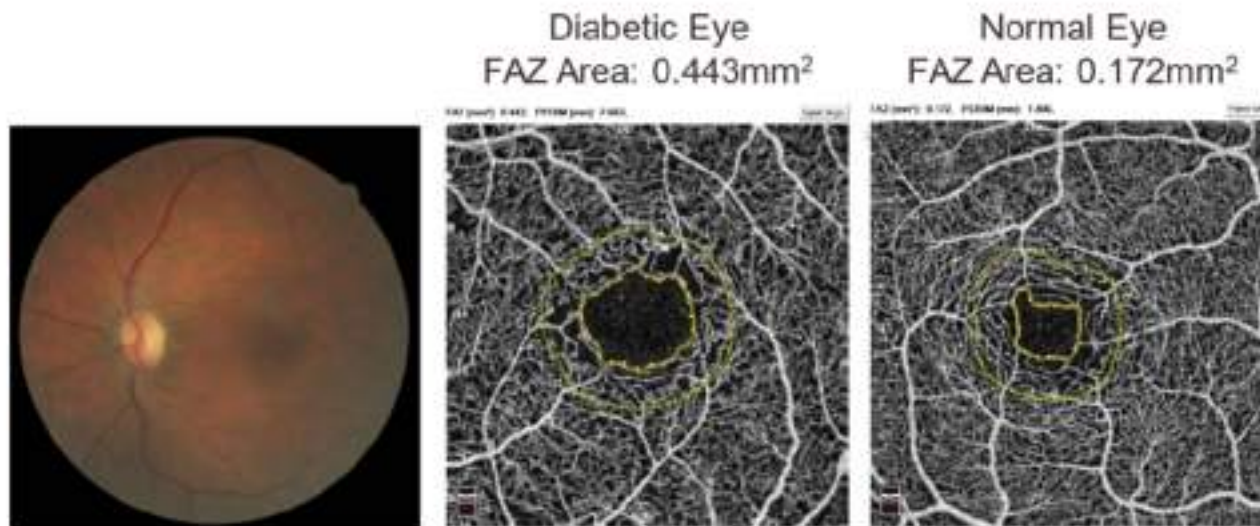
70 μ m Below IPL \rightarrow 30 μ m
Below RPE Reference

Choriocapillaris

30 μ m Below RPE Reference \rightarrow 60 μ m
Below RPE Reference

Identify Early Vascular Changes in Diabetic Eyes


Patients with DM have a larger FAZ than healthy eyes.³



3. Di, G., Weihong, Y., Xiao, Z. et al. *Graefes Arch Clin Exp Ophthalmology* (2016) 254: 873. <https://doi.org/10.1007/s00417-015-3143-7>
Images courtesy of Julie Rodman, OD, FAAO

Assess Disease Progression with Multiscan View

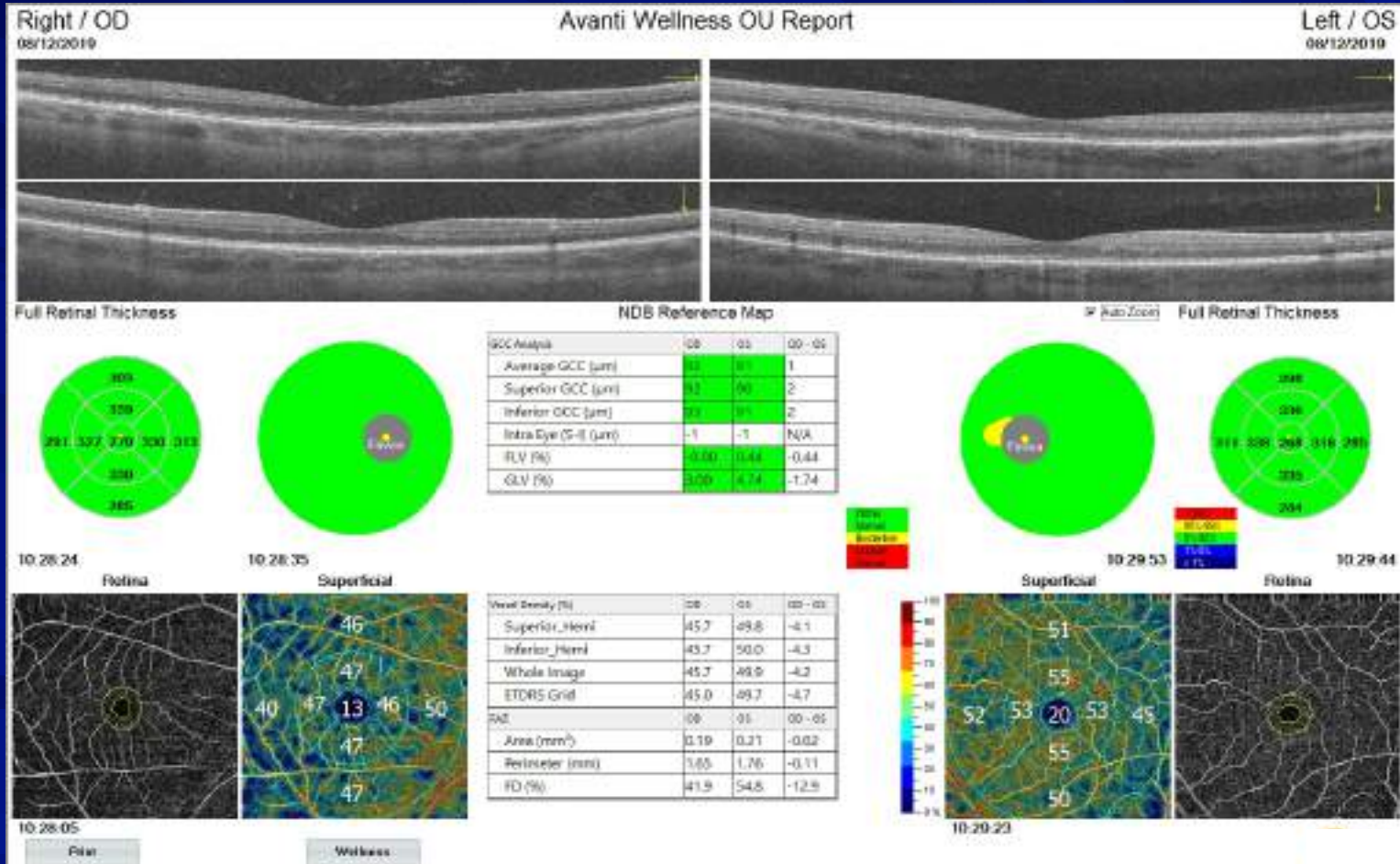
Vessel Density Decreases Significantly with Disease Severity⁴



4. Nesper FL, Roberts PK, Orishi AC, et al. Quantifying Microvascular Abnormalities With Increasing Severity of Diabetic Retinopathy Using Optical Coherence Tomography Angiography. *Investigative Ophthalmology & Visual Science*. 2017;58(6):Bio307-Bio315. doi:10.1167/iov.17-21787.

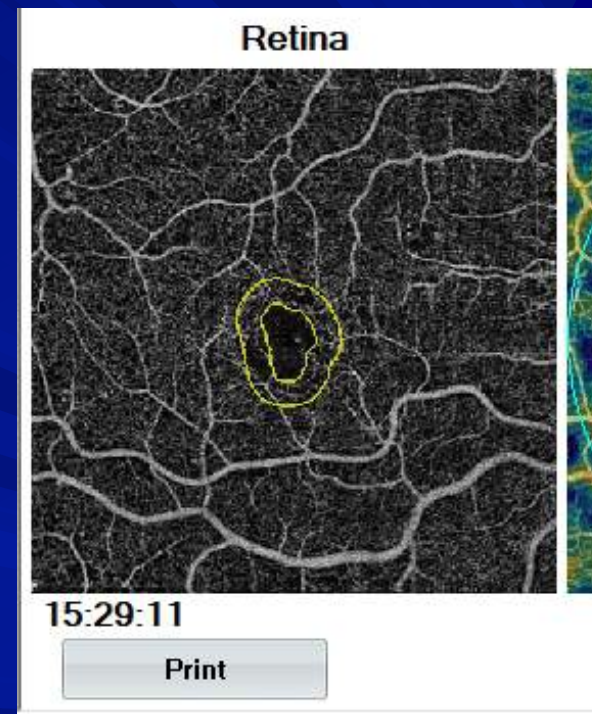
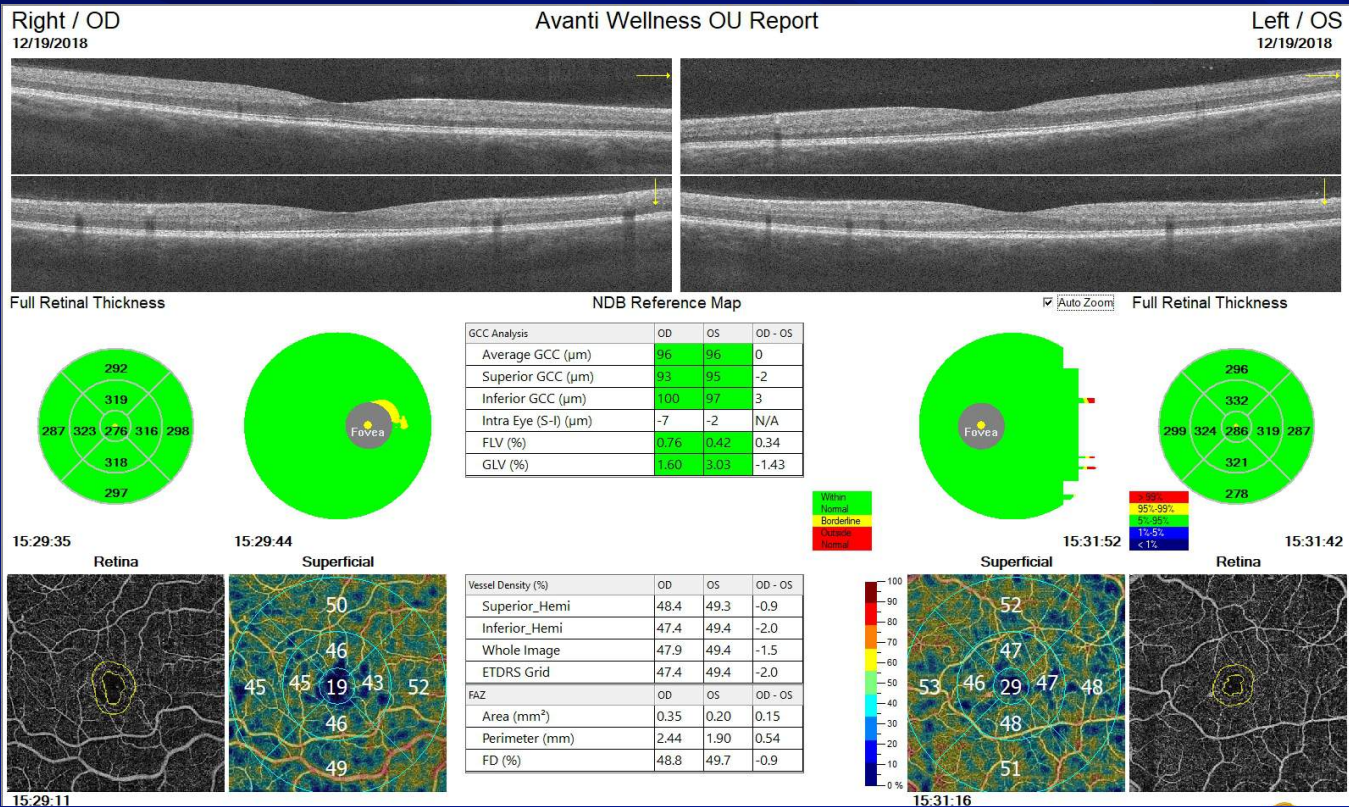
AngioWellness Report

Comprehensive Eye Exam - Healthy



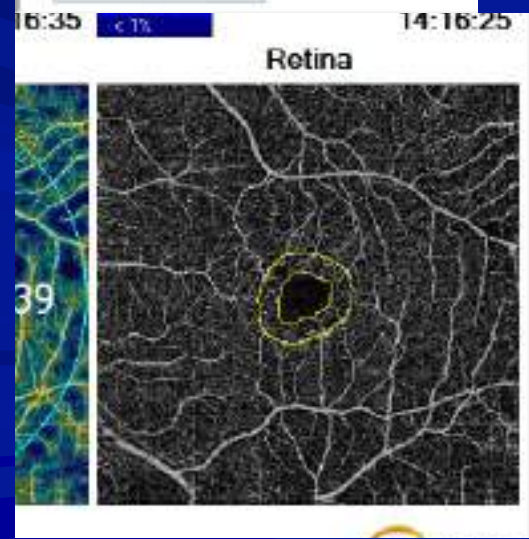
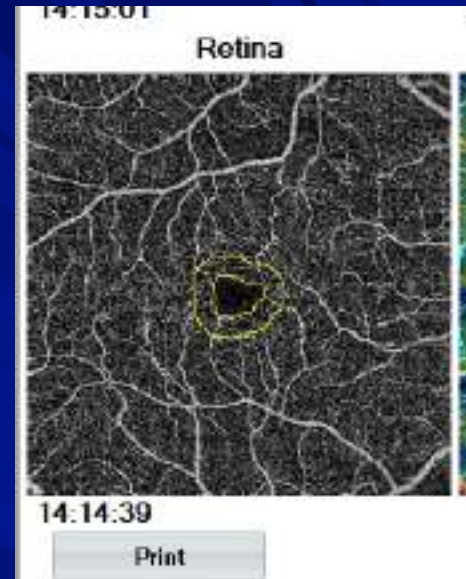
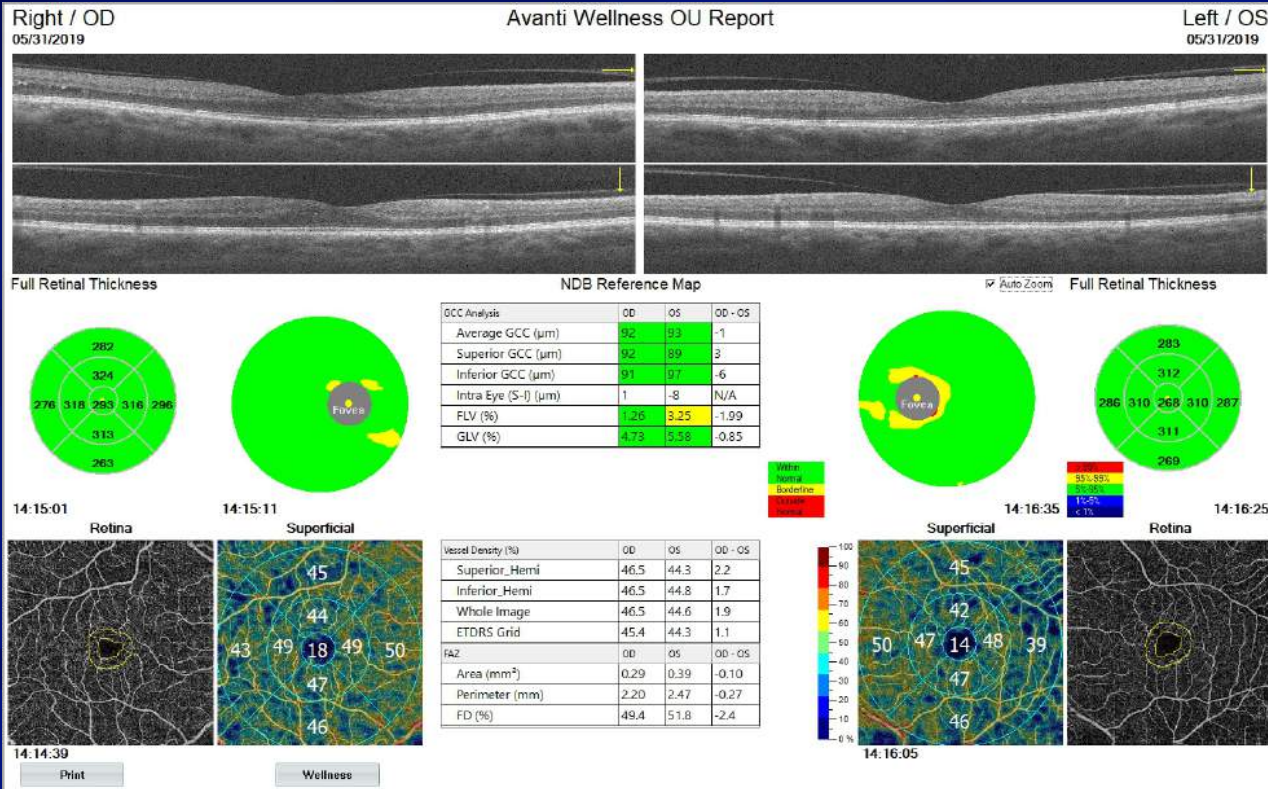
AngioWellness Report

Patient 1 with Diabetes



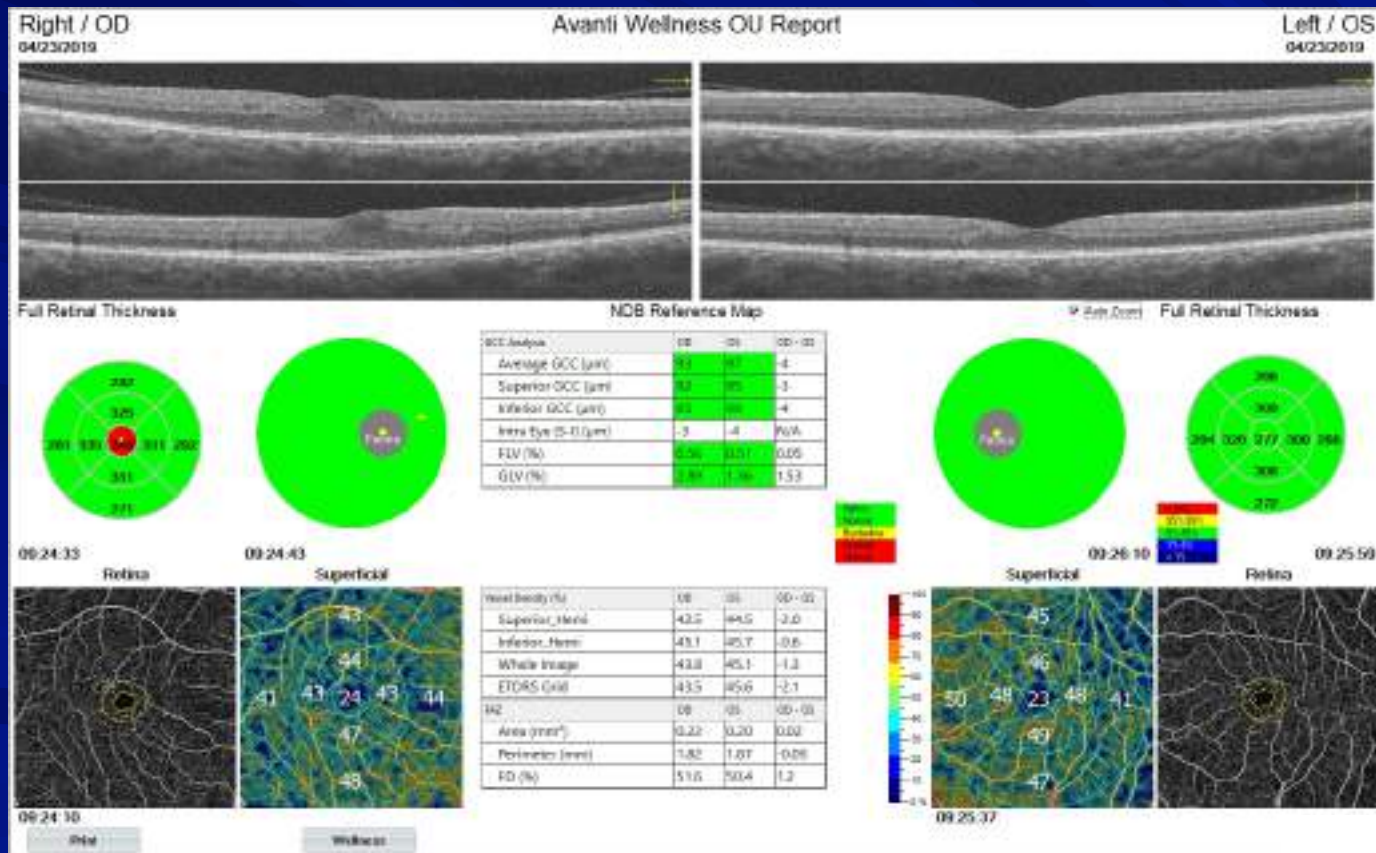
AngioWellness Report

Patient 2 with Diabetes



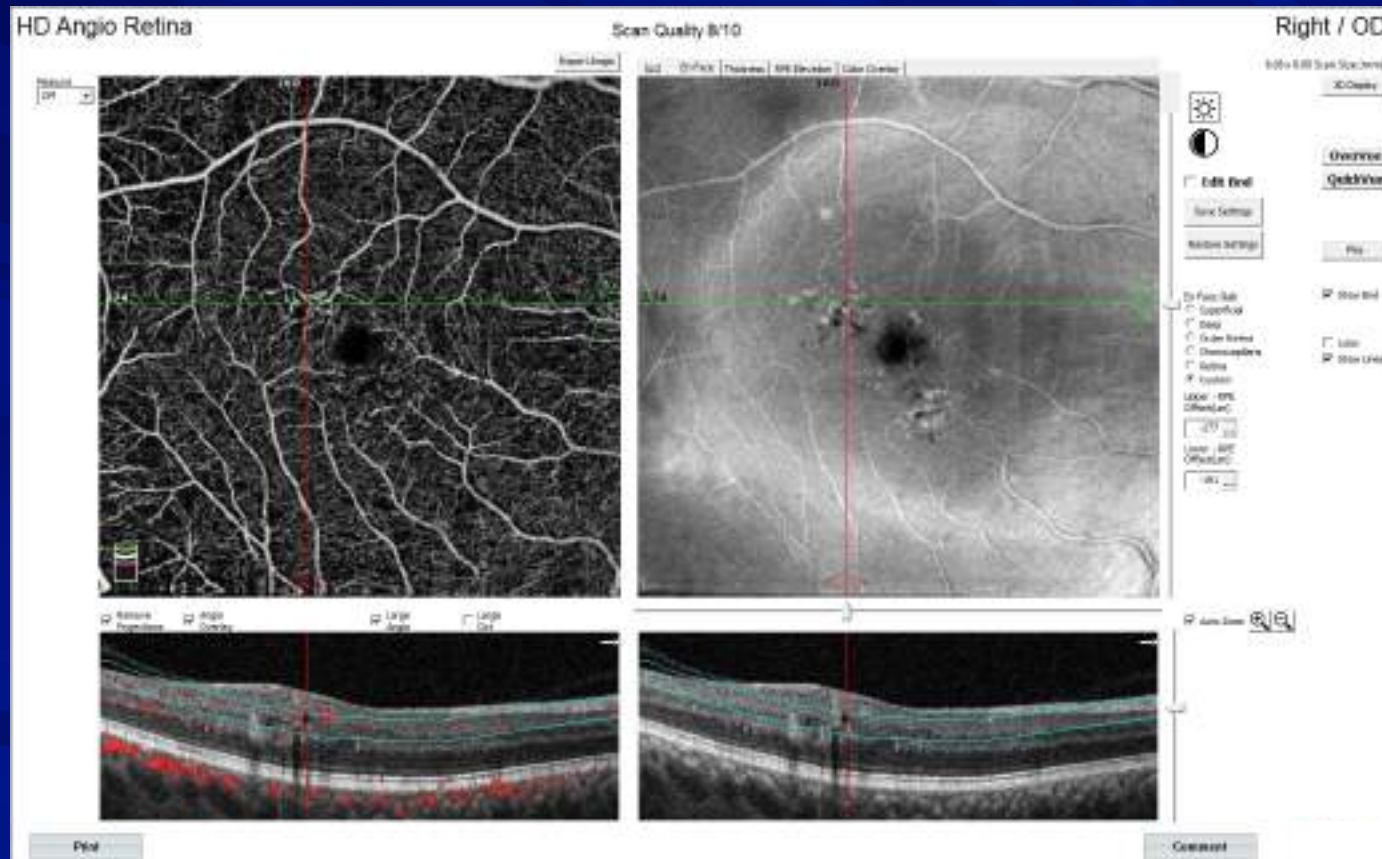
AngioWellness Report

Patient 3 with Diabetes



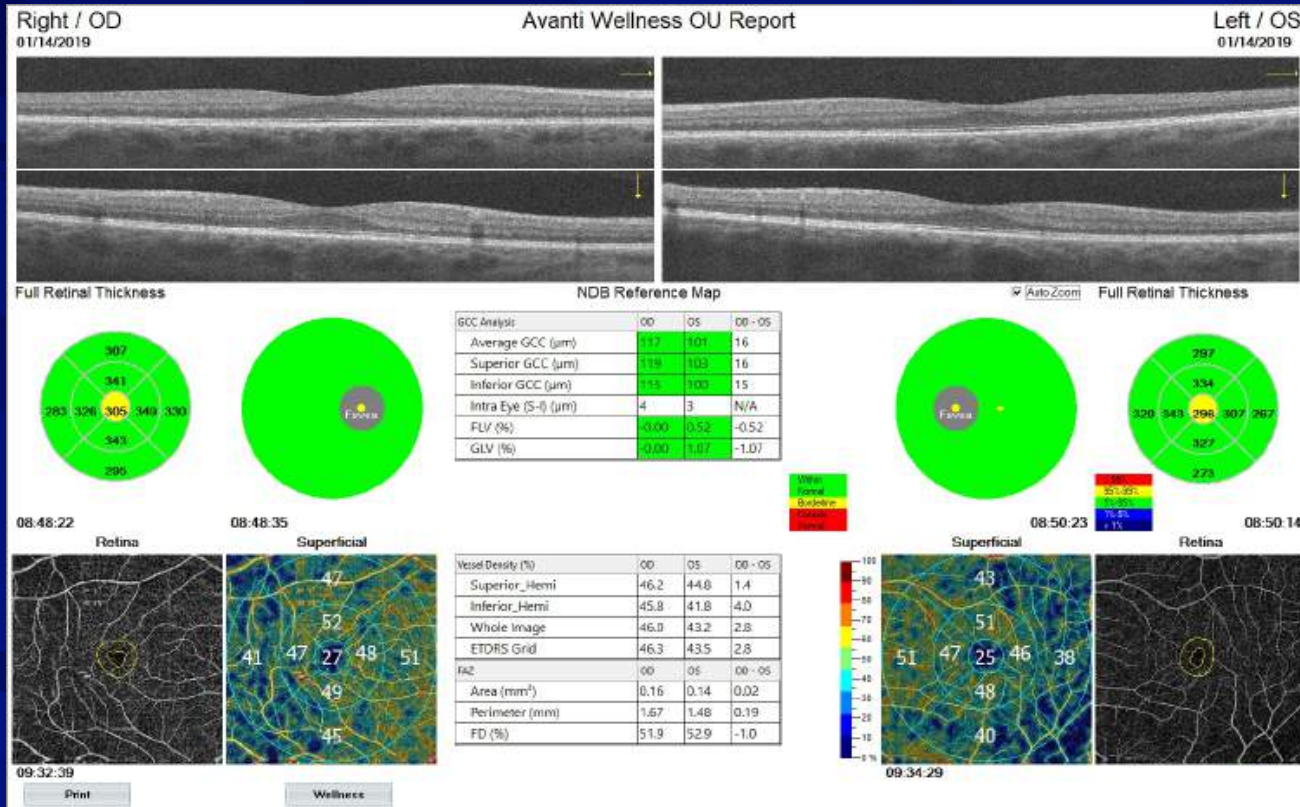
AngioWellness Report

Patient 3 with Diabetes



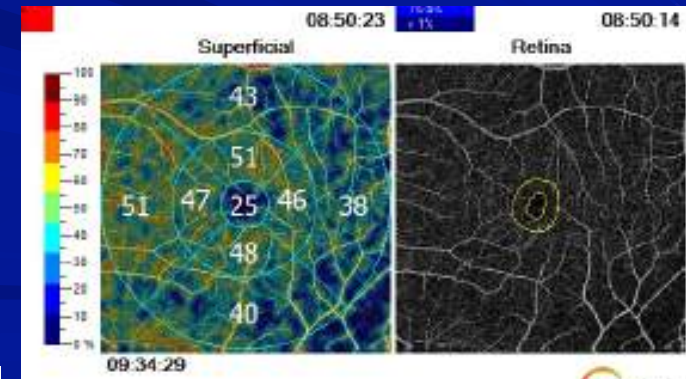
AngioWellness Report

Glaucoma IOPs 24 OU



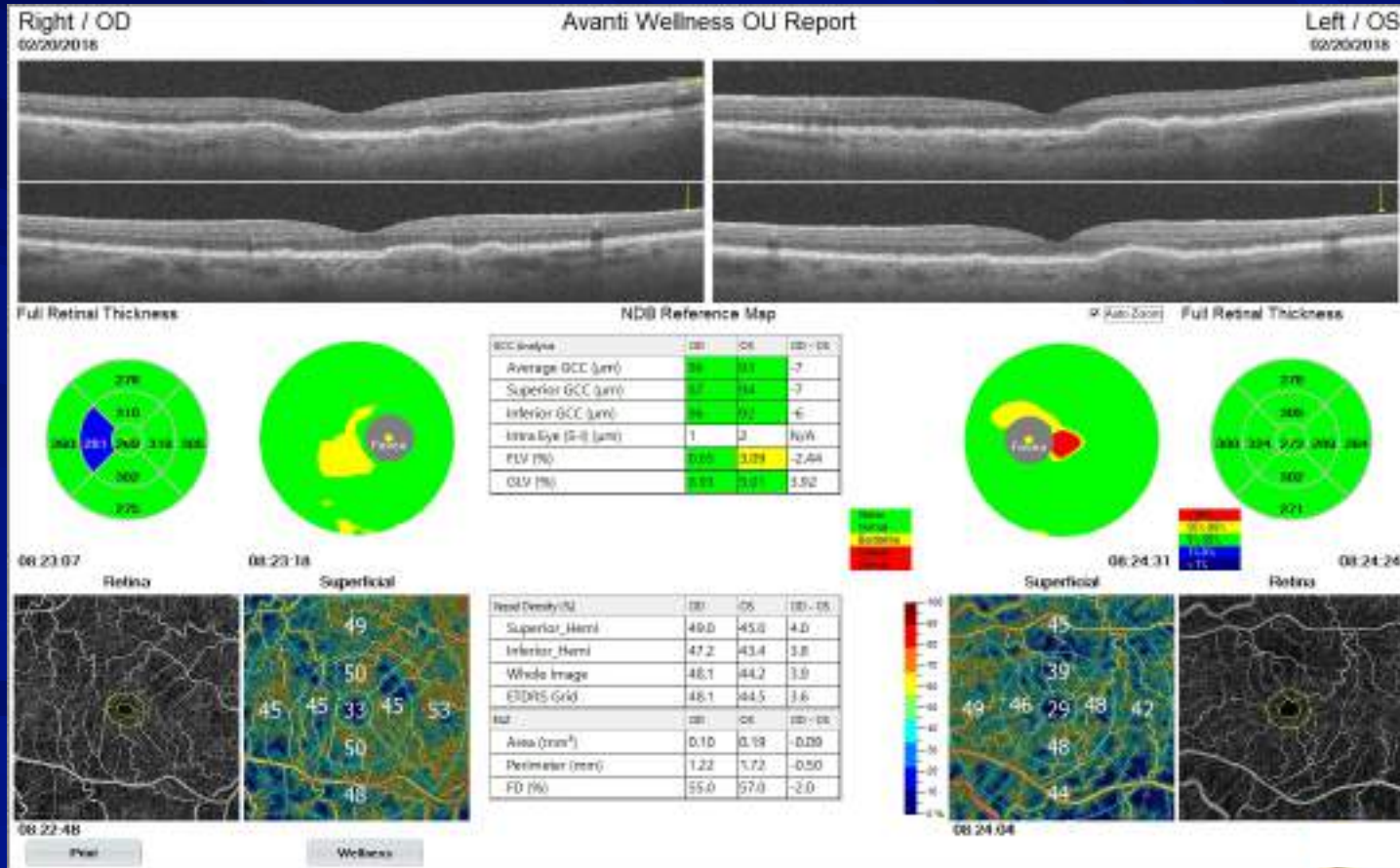
NDB Reference Map

GCC Analysis:	00	05	00-05
Average GCC (µm)	317	301	16
Superior GCC (µm)	319	303	16
Inferior GCC (µm)	315	300	15
Intra Eye (S-I) (µm)	4	3	N/A
FLV (%)	-0.00	0.52	-0.52
GLV (%)	-0.00	1.07	-1.07



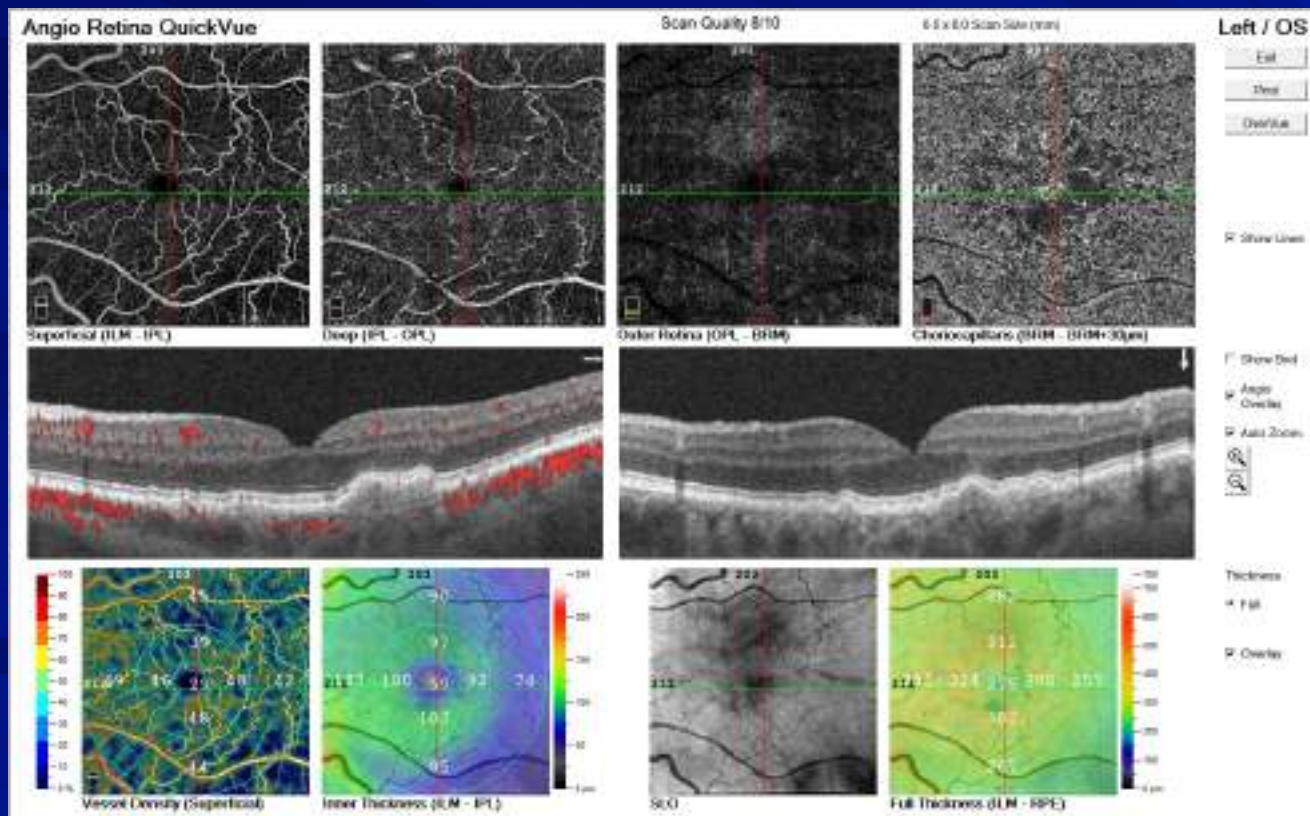
AngioWellness

AMD Patient



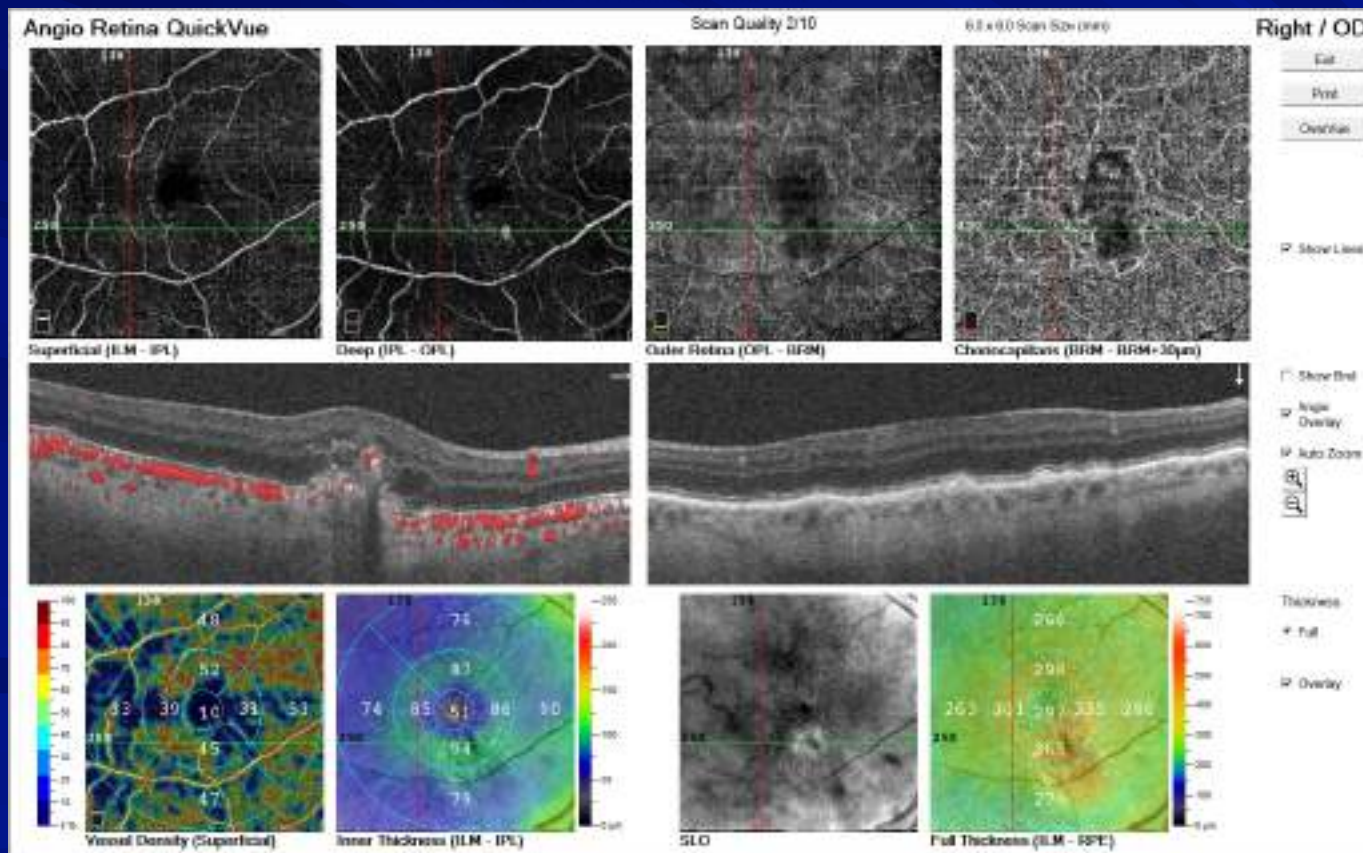
AngioWellness

AMD Patient



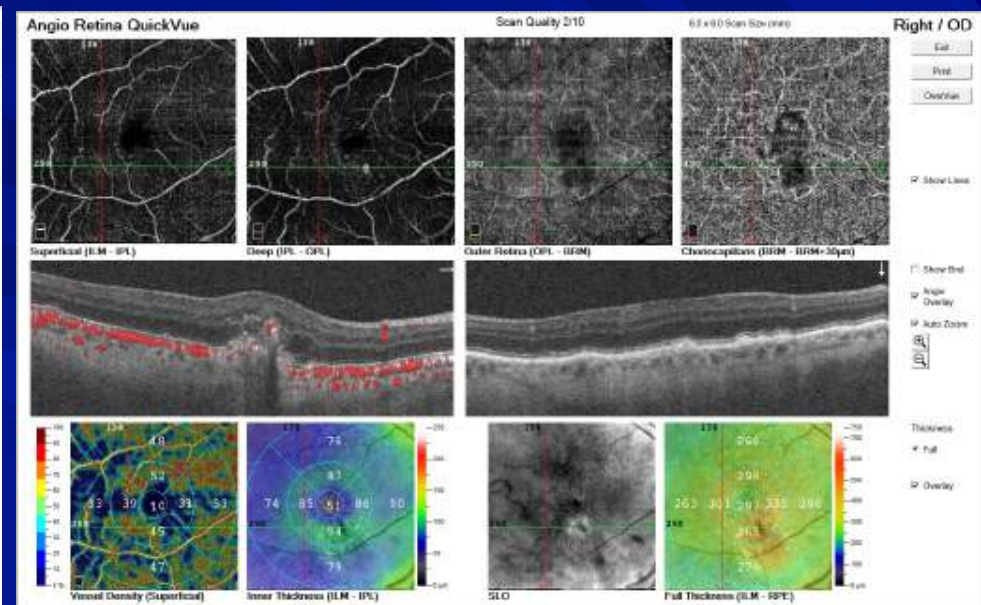
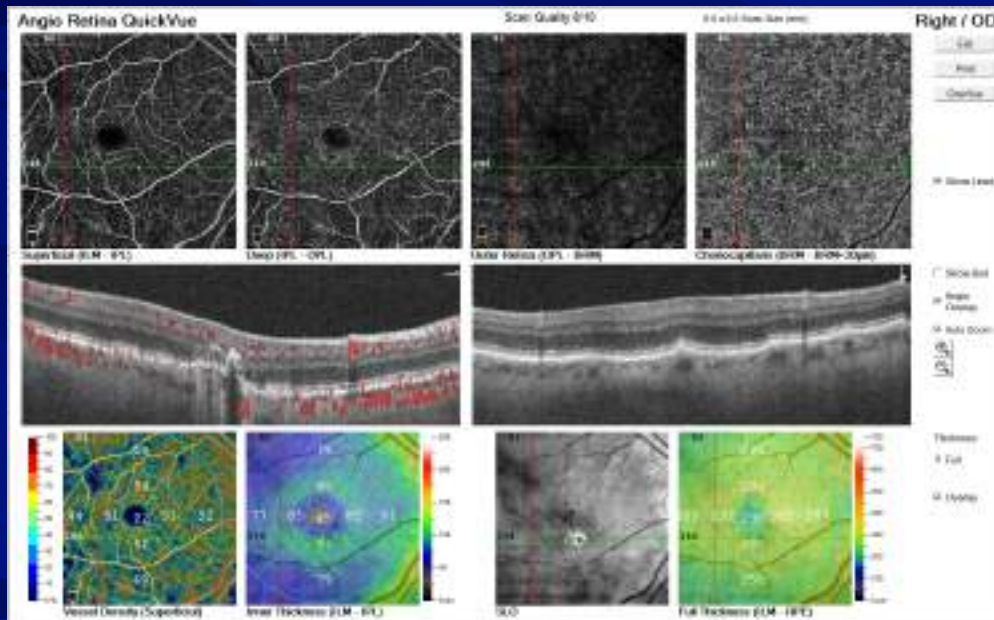
Evaluation AMD Patients for Neovascularization

Patient 1 Early Detection



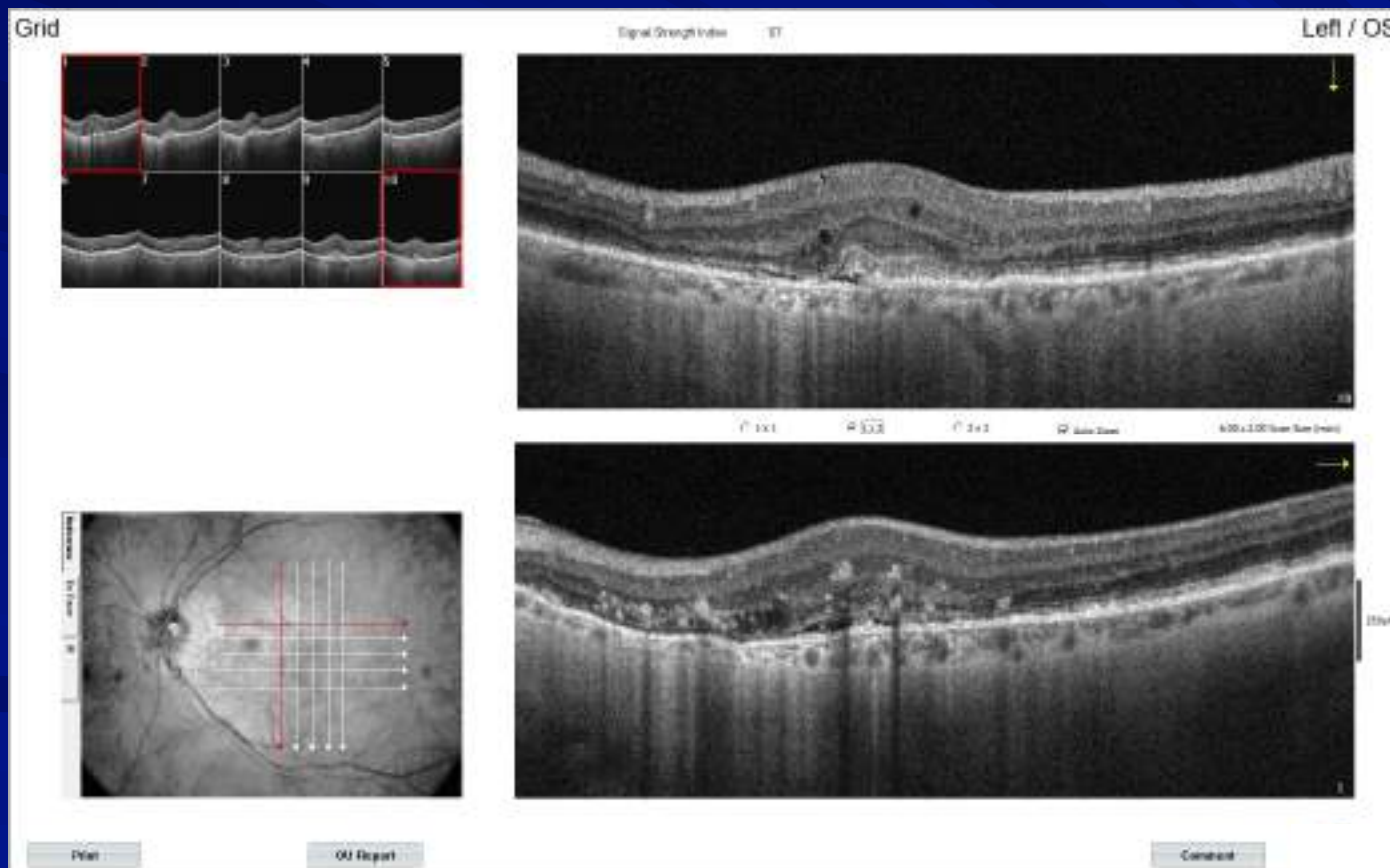
Evaluation AMD Patients for Neovascularization

Patient 1 Early Detection and Early Treatment



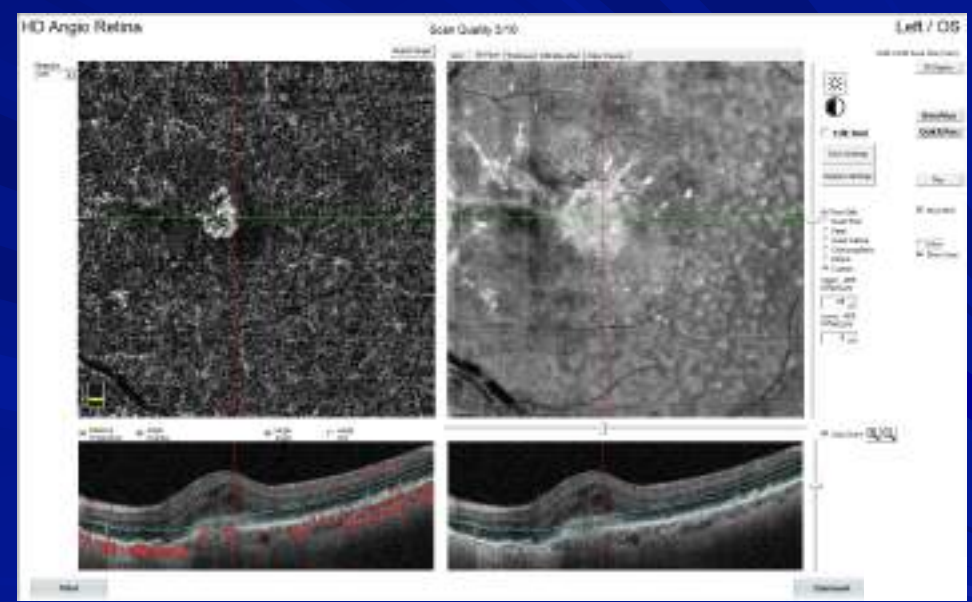
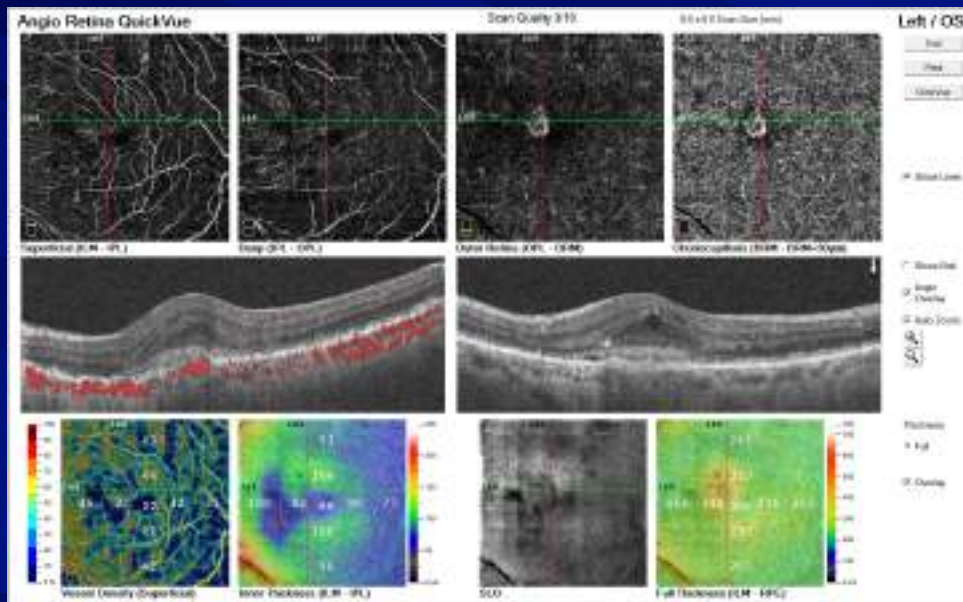
Evaluation AMD Patients for Neovascularization

Patient 2 Early Detection




Evaluation AMD Patients for Neovascularization

Patient 2 Early Detection



Steps and Tools of How Our Office Offers the Wellness

- ☞ Every patient coming in for a comprehensive eye exam is offered the Wellness package
- ☞ It all starts at the front desk at check in
- ☞ Everyone knows the script



Our Patient Script

“The doctor WANTS you to have the Optomap and OCT photo’s done today. When combined these photo’s capture the surface and layers of the retina which gives the doctor a complete image. During your exam the doctor will review these photos with you. Carefully read over this form, check what you would like to have done today, and sign / date the bottom”

Tips:

☞ Only answer questions about cost if asked

☞ Don’ t say: “You do not have to fill this out if you don’t want any of the photos”

Wellness Images and OCT-A Information

Healthcare has moved to Early Detection

Vision threatening diseases such as glaucoma, macular degeneration, diabetic retinopathy, or changes from high blood pressure or cholesterol often have no outward signs or symptoms, so our practice is using state-of-the-art technology to assess the health of your eyes. Our doctors can detect vision threatening and systemic diseases in their very early stages, when they are most treatable.

Optomap & Wellness OCT: Our wellness images include both the Wellness OCT retinal scan and Optomap. The Wellness OCT allows the doctors to view the layers of the retina below the surface image captured by the Optomap. **The doctor wants you to have these tests as part of your annual visit today. The cost is only \$50.**

Optomap, Wellness OCT, & OCT-A: If you are suffering from diabetes, high blood pressure, high cholesterol, rheumatological disease, have a family history or diagnosis of age-related macular degeneration. **The doctor wants you to have these tests as part of your annual visit today. In this bundled package, the OCT-A only costs an additional \$20, for a total of \$70.**

Yes, I accept the fee and would like to have:

_____ **Optomap & Wellness OCT** (routine annual exam)

_____ **Optomap, Wellness OCT, & OCT-A** (annual exam for patients with diabetes, high blood pressure, cholesterol, rheumatological disease, family history or diagnosis of age-related macular degeneration)

Signature: _____ Date: _____

Our Forms Given
to Patient

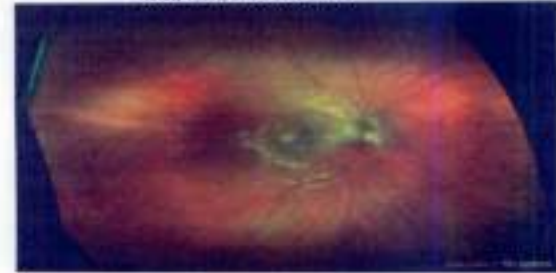
Healthcare has moved to Early Detection

Our wellness imaging is designed to detect and monitor for the earliest potential of possible blindness caused by:

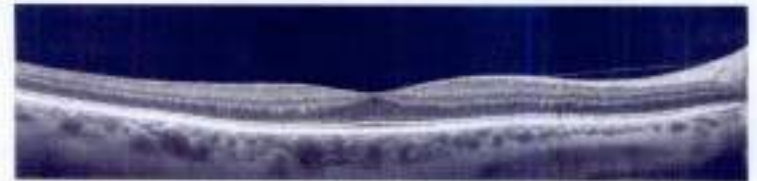
Macular Degeneration
Diabetic Retinopathy
Glaucoma

Hypertensive Retinopathy
Retinal Tumors
Cholesterol Deposits

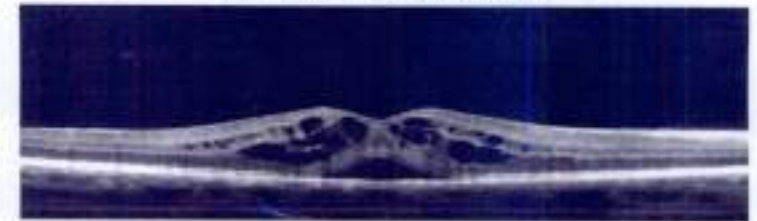Holes, Tears, and Detachments



Normal Wide Field Retina Image on the Optomap Retinal Exam



Normal Retinal Cross-Section on iWellness OCT



Diseased Retinal Cross-Section on iWellness OCT

Benefits: That Our Staff Uses

- ↳ Complete image behind the eye; larger view than with the slit lamp
- ↳ Quick; takes minutes at most
- ↳ Patient friendly, non-invasive, no pain or drops to acquire images
- ↳ Becomes a part of the medial record that will be compared to past images for any change and / or start a baseline for future photos
 - ★ “Just like a driver’s license photo, you change over time without realizing it”
- ↳ Do not have to have age related disease for these photo’s to be done / beneficial
- ↳ There are not always signs or symptoms of problems; asymptomatic

Program Recap of OCT Angiography

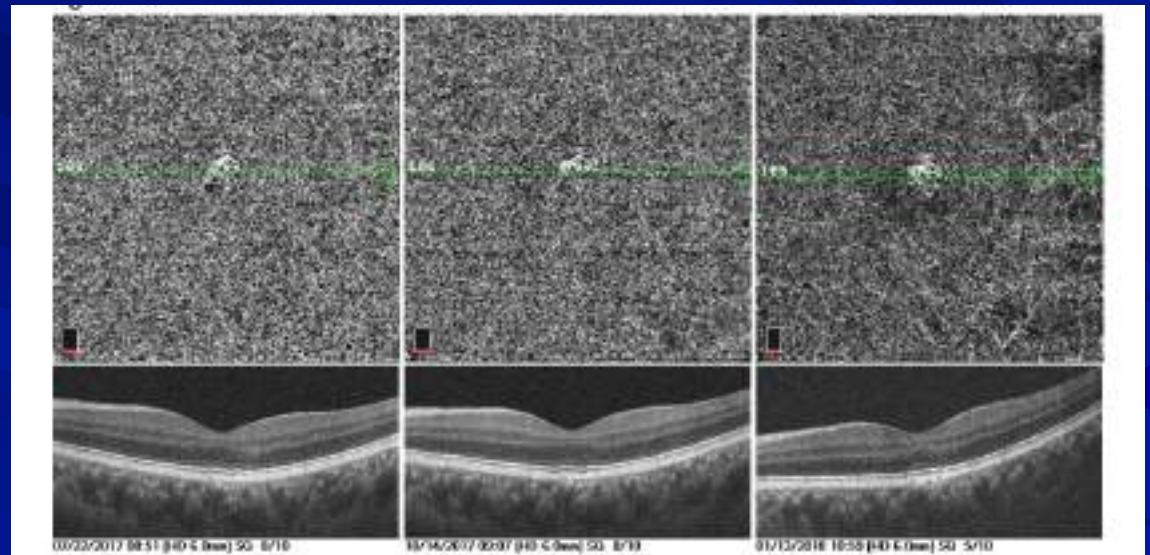
- 👁️ Expand patient care and practice revenue with OCT Angiography
- 👁️ Value of early detection of abnormal retinal vessels in comprehensive eye exams
 - ★ Patients with diabetes
 - ★ Glaucoma or ocular hypertensive patients
 - ★ Macular degeneration
- 👁️ How to educate staff and patients on OCT Angiography
- 👁️ Using vascular imaging in the diagnosis, treatment, and management on ocular disease

Final Thoughts

 I can't say it enough

 OCT Angiography and Wellness

- ★ Enhances patient care
- ★ Elevates the practice
 - ☐ Patient point of view
 - ☐ Medical community
- ★ Additional benefits to the office
 - ☐ Cash flow
 - ☐ Stability



Billing an OCT Angiography

👁️ Wellness

👁️ No CPT Code

👁️ Medical

👁️ No CPT Code

A Look at Wellness

👁️ Total wellness OCTs for 2018

- ★ 2355
- ★ 197 per month

👁️ January 1, 2019 thru December 31, 2019

- ★ 2765 wellness OCTs
- ★ 231 per month

👁️ Wellness for 2020 thru August 25, 2020

- ★ 1512
- ★ June 371
- ★ July 239

👁️ OCT Angiography

- ★ Enhances patient care
- ★ Elevates the practice
 - 📄 Patient point of view
 - 📄 Medical community
- ★ Additional benefits to the office
 - 📄 Cash flow
 - 📄 Stability

Resource: OCT Community for OCT and OCT-A




OCT CONNECT

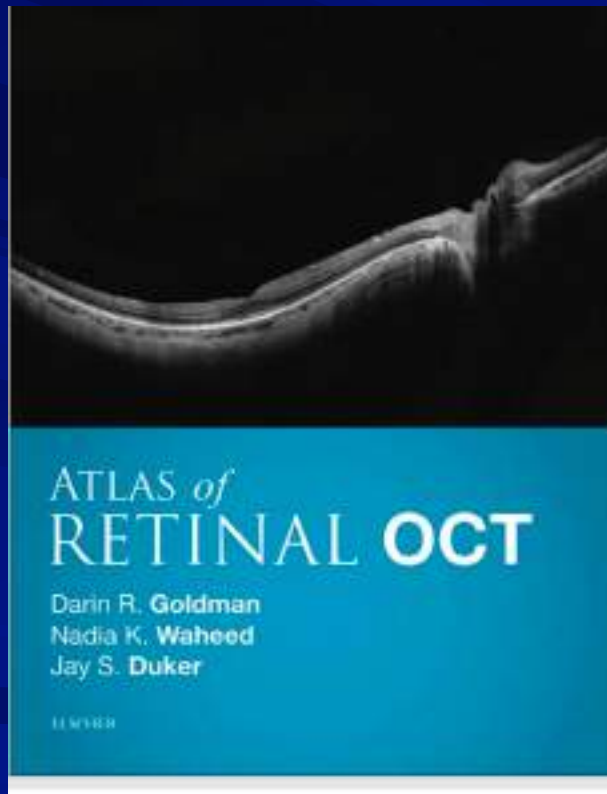
Post your questions & cases so we can #OCTConnect!



Join this group to become part of our
OCT Connect Family!




Book Resources



Optical Coherence Tomography Angiography Atlas: A Case Study Approach

Julie A Rodman, OD MSc FAAO



\$149.95

ISBN 10 1-63001-641-2

ISBN 13 978-1-63091-641-1

200 pp Hard Cover

Pub. Date: 2019

Order# 66411

Thank-You and Hope You Enjoyed

Greg Caldwell, OD, FAAO
Grubod@gmail.com

