


OCT and OCT Angiography in Glaucoma

Greg Caldwell, OD, FAAO
Optometric Education Consultants
August 29, 20/20




Disclosure Statement (next slide)

1

Disclosures- Greg Caldwell, OD, FAAO

- Will mention many products, instruments and companies during our discussion
- * I don't have any financial interest in any of these products, instruments or companies
- Pennsylvania Optometric Association -President 2010
 - POA Board of Directors 2006-2011
- American Optometric Association, Trustee 2013-2016
- I never used or will use my volunteer positions to further my lecturing career
- Lectured for: Aerie, Alcon, Allergan, BioTissue, OptoVue
- Advisory Board: Allergan, Maculogix, Sight Sciences, Sun, Takeda
- Envolve: PA Medical Director, Credential Committee
- Optometric Education Consultants- Scottsdale, St. Paul, Quebec City, Nashville, and Orlando/Disney OCT Users meeting; Owner




2

OCT Anterior Segment Applications in Glaucoma

4

OCT for Pachymetry in Glaucoma



5

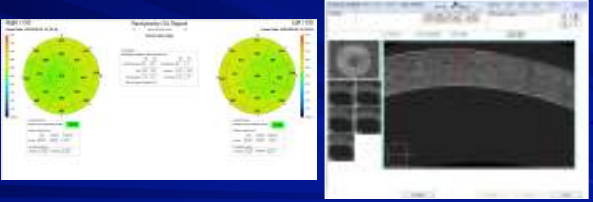
Pachymetry

Ultrasonic versus Optical versus OCT



6

Anterior Segment Imaging Pachymetry



7

55 Year Old Men

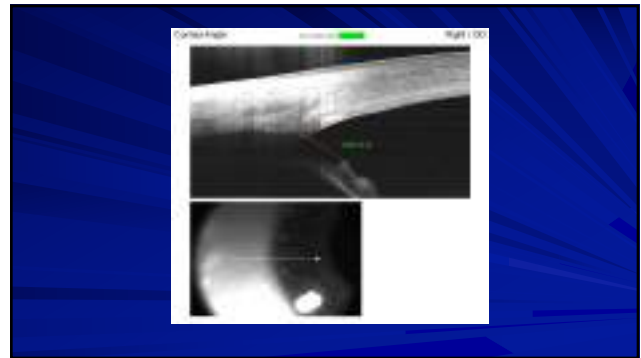
500 microns CCT and 21 mm Hg with Goldmann **600 microns CCT and 21 mm Hg with Goldmann**

What is the true IOP?

1. 18 mm Hg
2. 21 mm Hg
3. 24 mm Hg
4. Don't Know

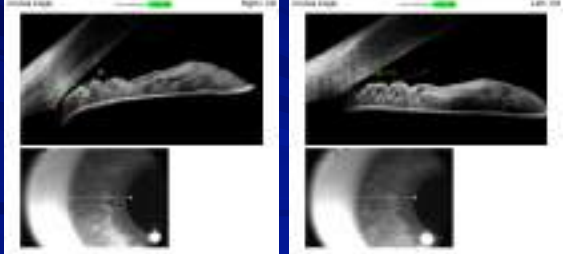
Corneal Curvature
Corneal Thickness
Corneal Rigidity

8

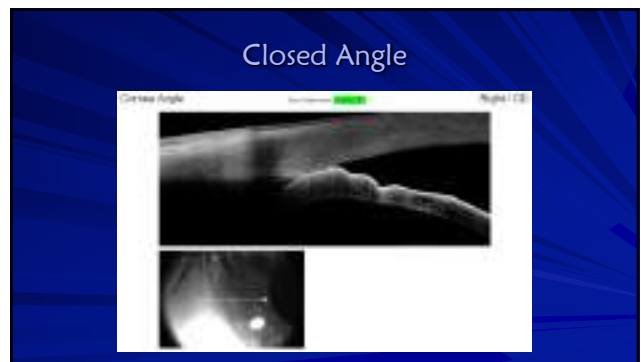


9


Less Than 15 Degrees Get Consult



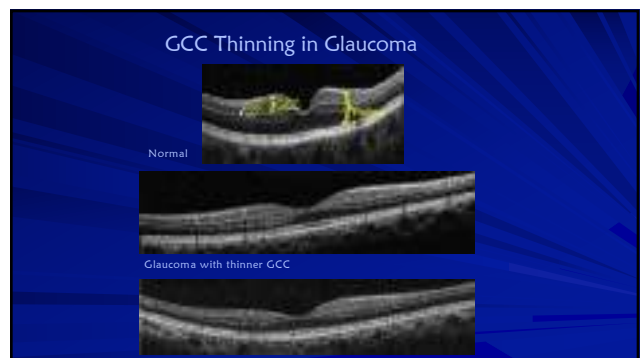
10



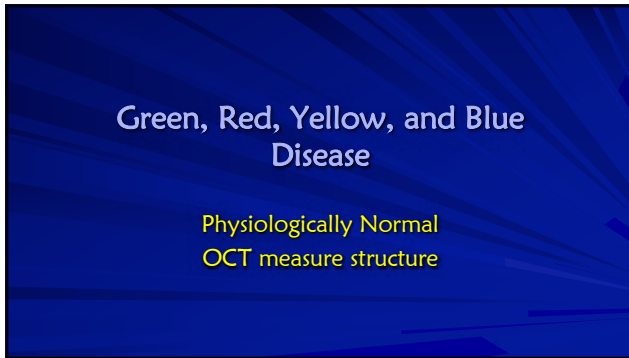
11



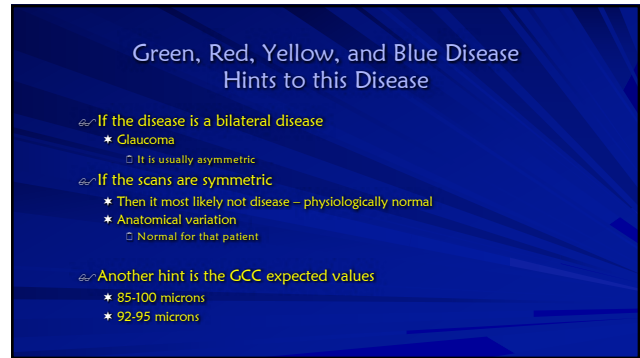
12



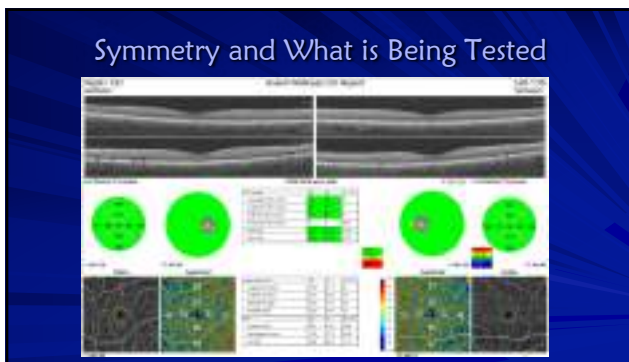
13



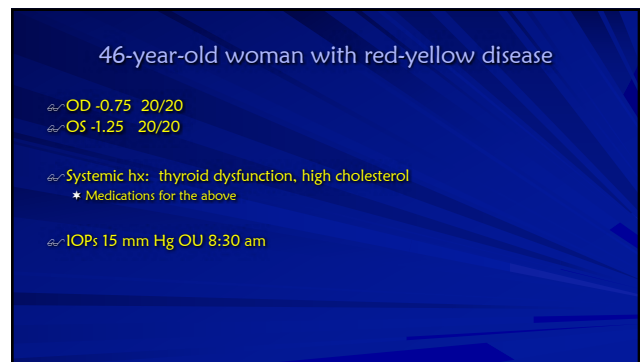
14



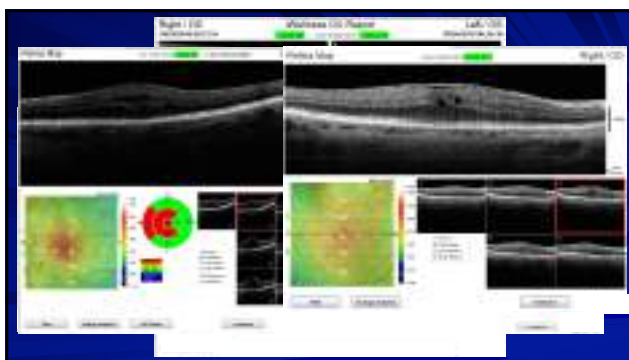
15



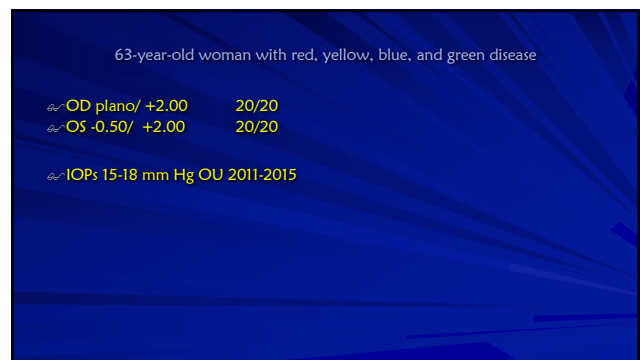
16



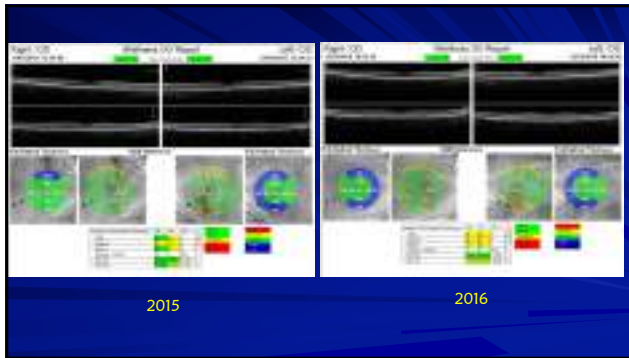
17



18



19



20

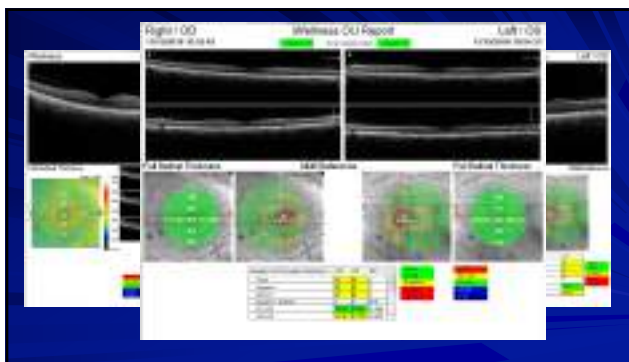
58-year-old with yellow disease

OD +1.00 20/20
OS +1.25 20/20

IOPs: 13/15 mm Hg at 11:24 am

(pay attention to FLV and GLV)

21



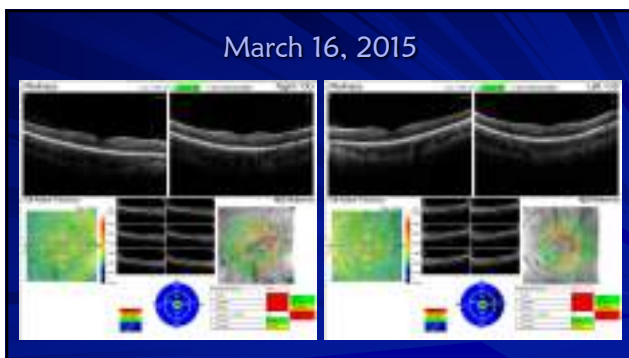
22

40 yo man with red, blue, green disease

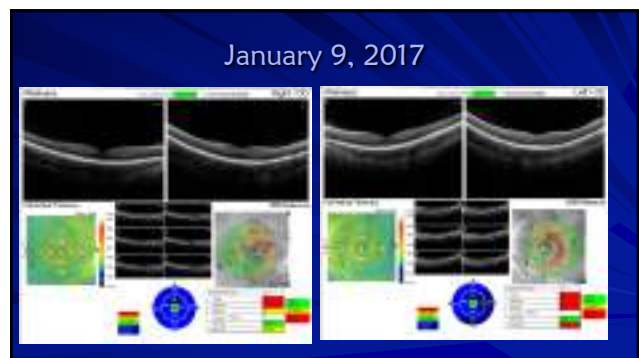
OD -7.50 - 0.75 x 110 20/20
OS -7.50 - 0.75 x 105 20/20

IOPs: 15/13 mm Hg at 6:30 pm

23

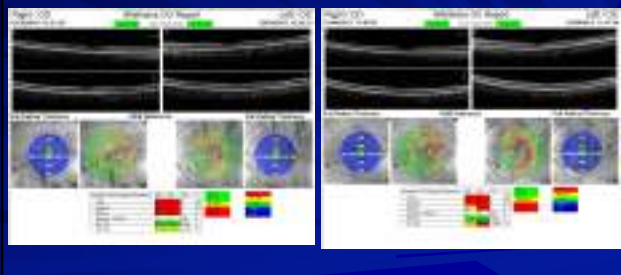


24



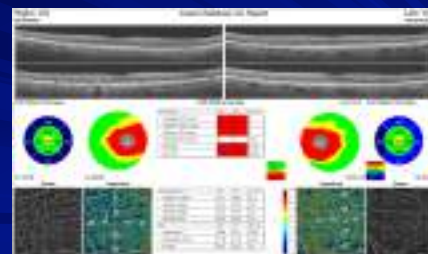
25

22 months apart



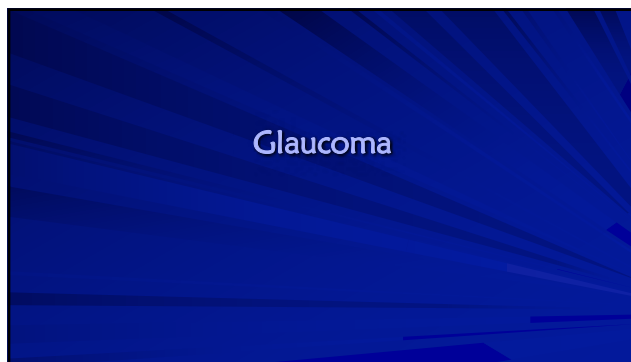
26

79 year-old-woman with DM



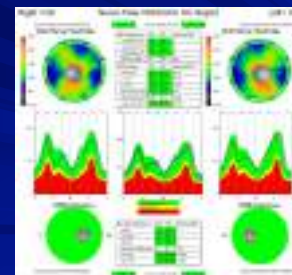
27

Glaucoma

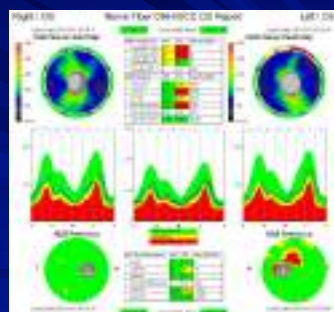


28

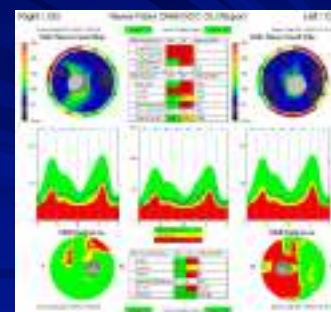
NFL and GCC



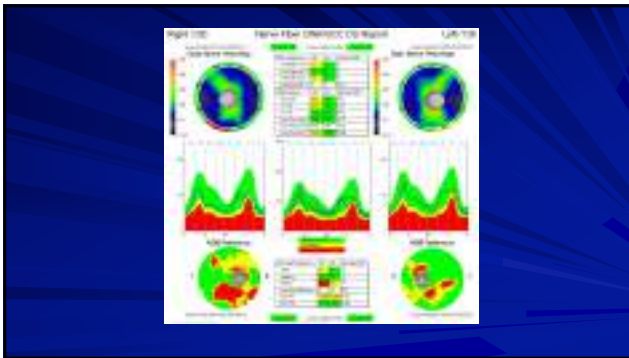
29



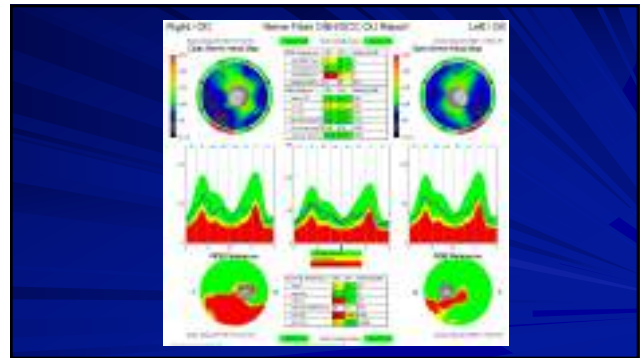
30



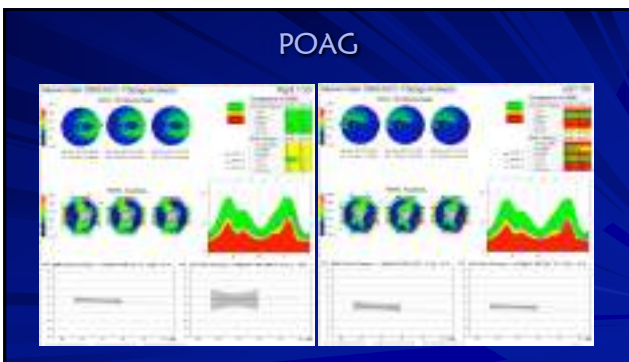
31



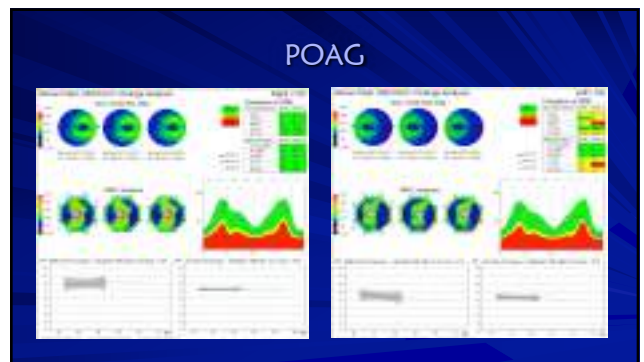
32




33



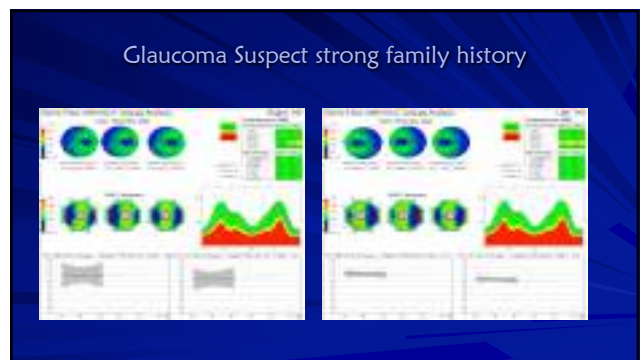
34



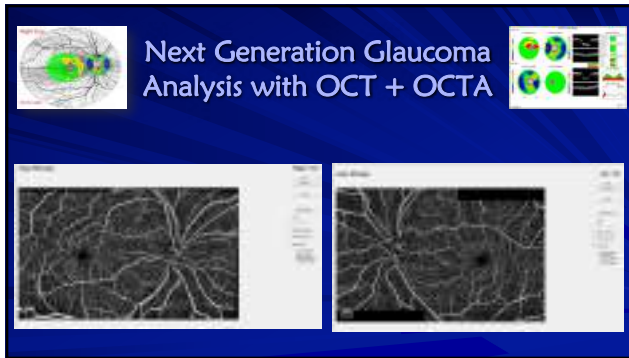
35



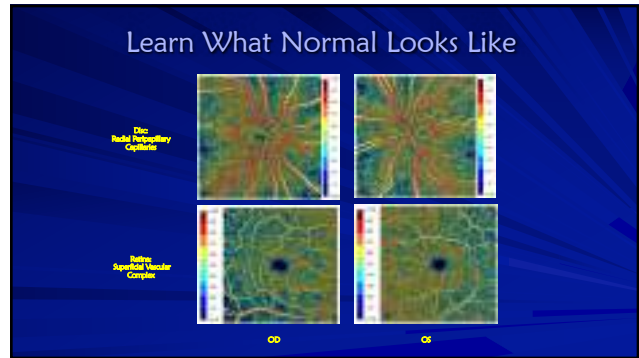
36



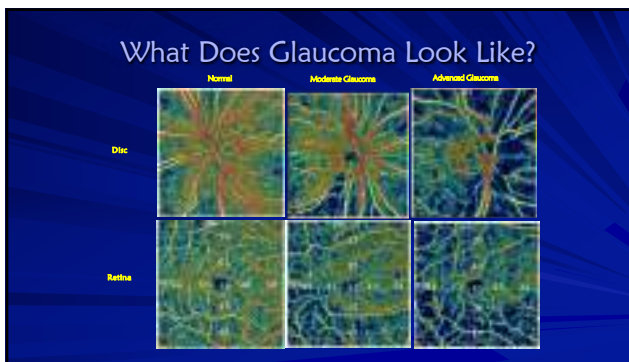
37



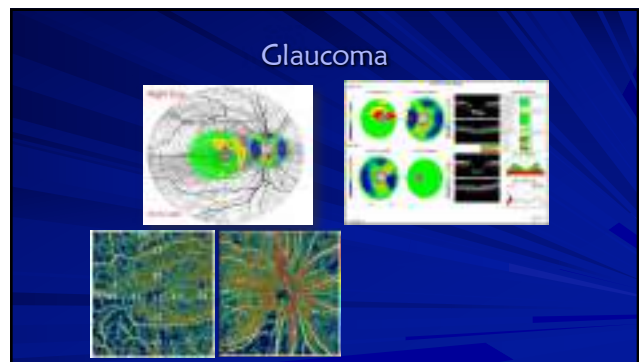
38



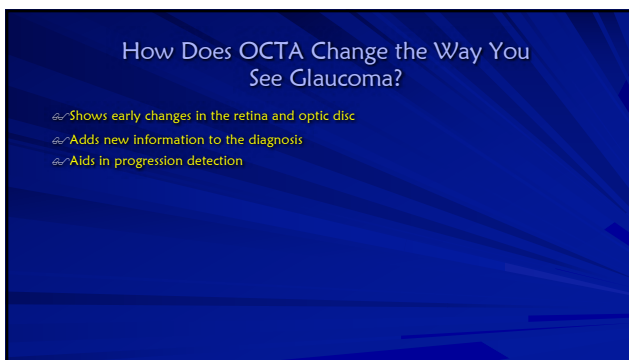
39



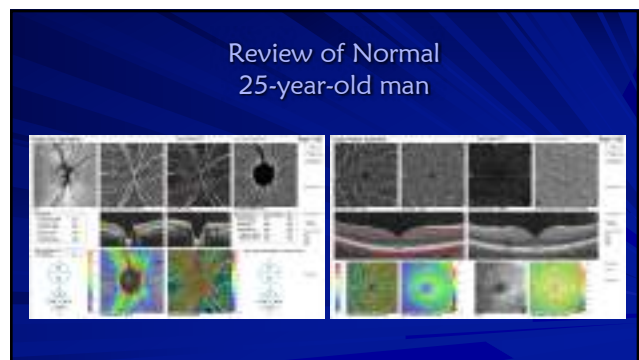
40



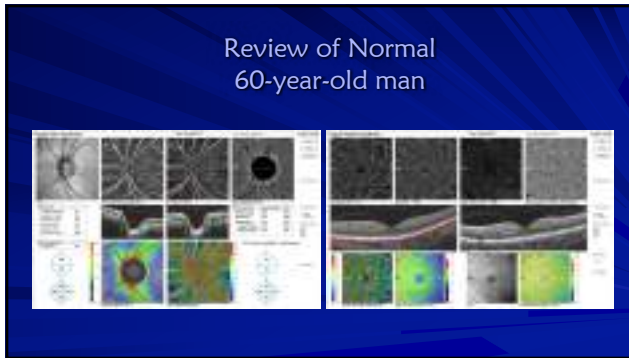
41



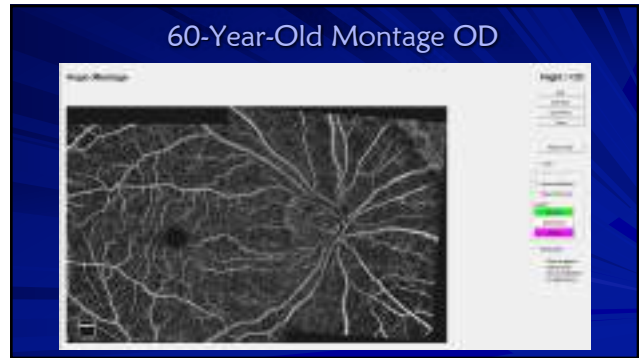42



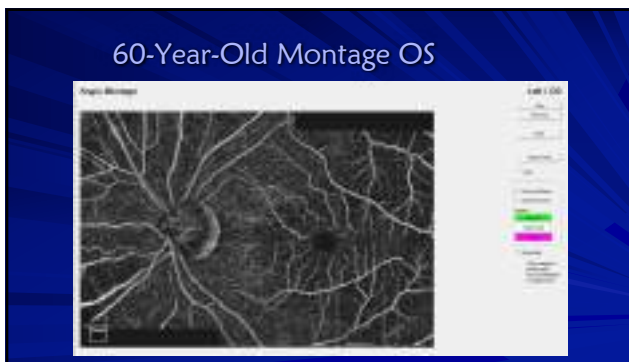
43



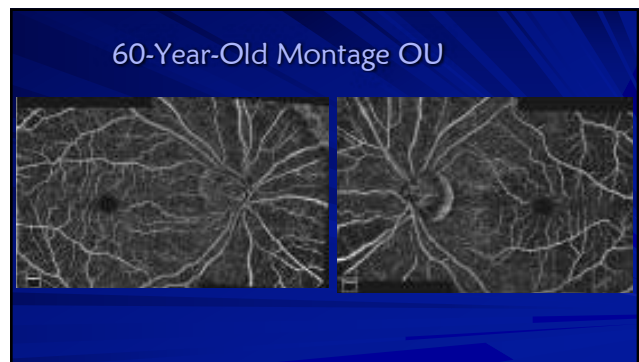
44



45



46




47

68-year-old woman with glaucoma

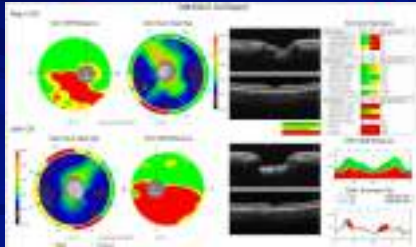
- Wants second opinion for glaucoma management
- Recently had cataract surgery OS with iStent
 - * September 25, 2017
 - * Dorzolamide 2% BID OS, Lumigan 0.01% QD OS
- Our practice recently performed cataract surgery and Kahook dual blade (KDB) MIGS
 - * July 24, 2018
 - * IOP_{CAT}: 12 and 16 at 11:27 am

48




49

OCT GCC and NFL



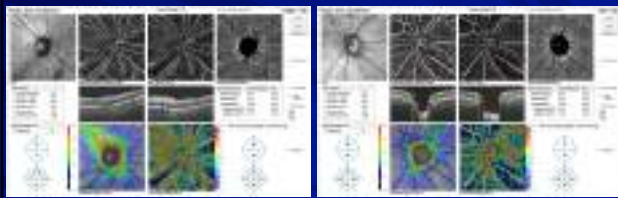
50

Visual Fields



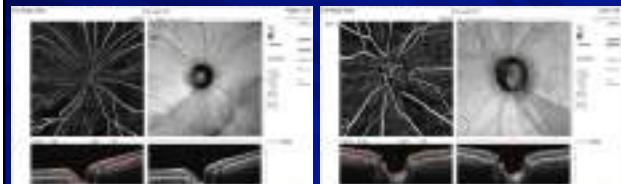51

Angiography and AngioAnalytics of Disc



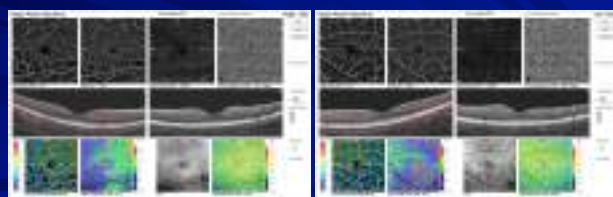
52

En Face Radial Peripapillary Capillaries (RPC)



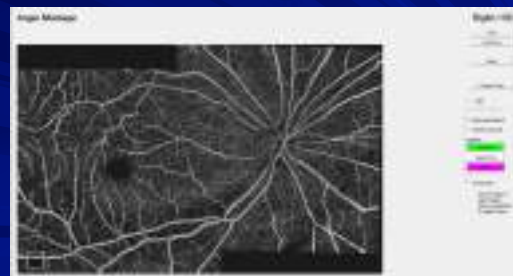53

Angiography and AngioAnalytics of Retina



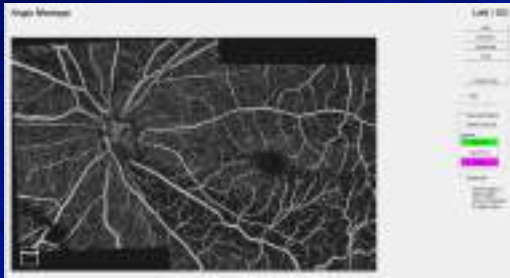
54

Montage OD



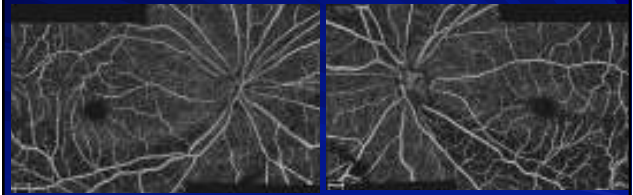
55

Montage OS



56

Montage OU



57

74-year-old man

- POAG, OS > OD
- Lumigan 0.01% QD OU
- Combigan BID OU



58

VF OD and OS 1-26-2018



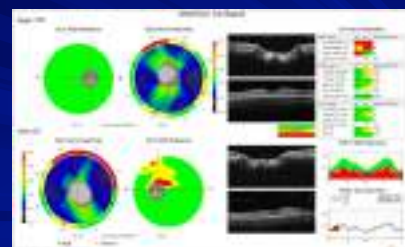
59

VF OD and OS GPA 1-26-2018

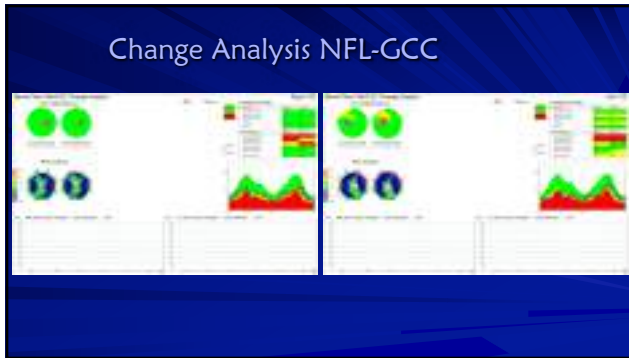

60

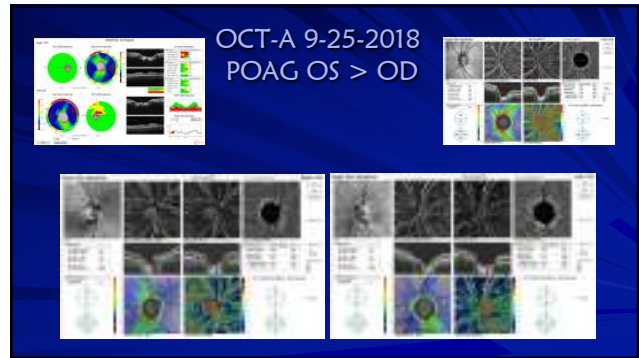
OCT NFL and GCC 9-25-2018



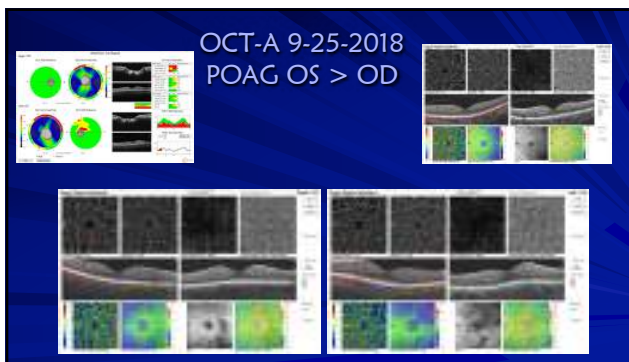
61



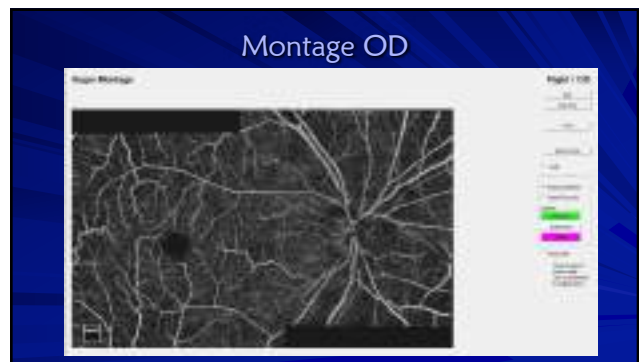62



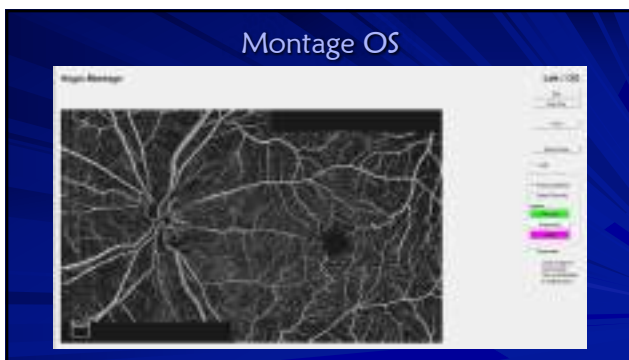
63



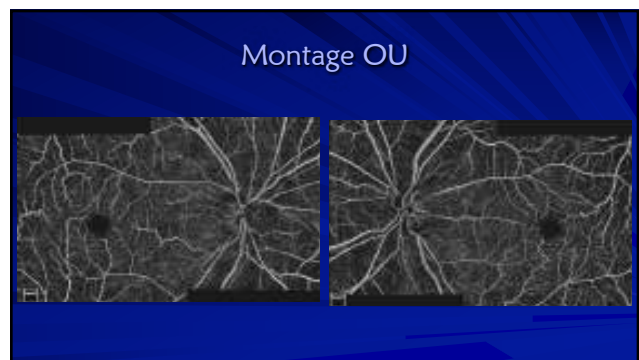
64



65



66



67

They do read their EHR communication



68

49 year old man

- ✓ Ocular Hypertension since 2014
 - ★ No treatment
- ✓ Pigment Dispersion
- ✓ Baseline IOP or Tmax 26/26
 - ★ 2014— March 2018
- ✓ Today 30/32, new Tmax 9-25-18



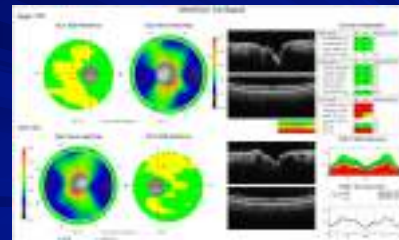
69

VF 24-2 Sita-Faster 9-25-2018



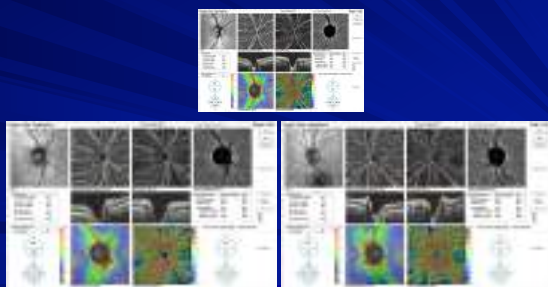
70

OCT NFL and GCC 3-22-18



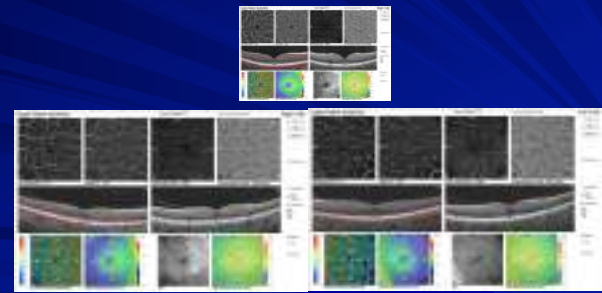
71

OCT-A 9-25-2018



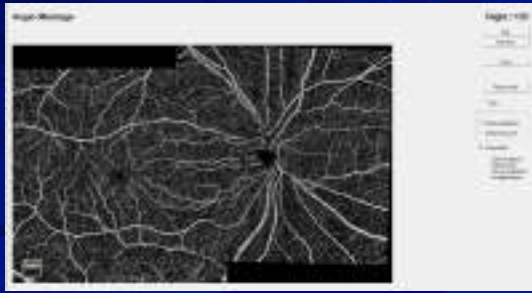72

OCT-A 9-25-2018



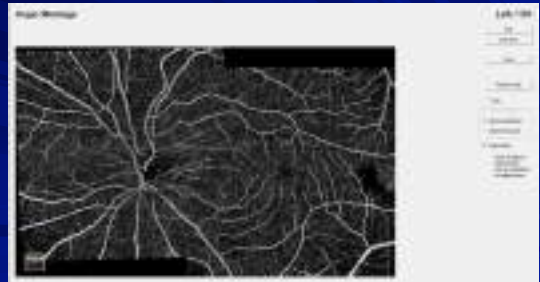
73

Montage OD



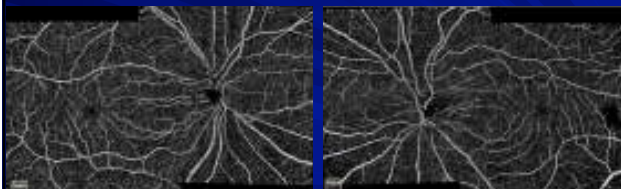
74

Montage OS



75

Montage OU



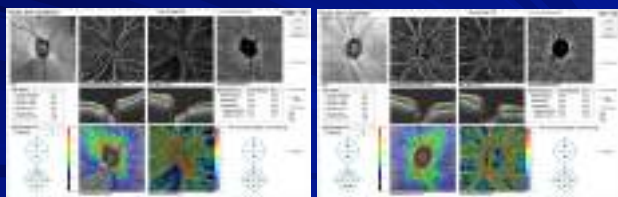
76

How Does OCTA Change the Way You See Glaucoma?

- ~ Shows early changes in the retina and optic disc
- ~ Adds new information to the diagnosis
- ~ Aids in progression detection

77

Glaucoma versus Other Optic Neuropathy



78

Hope You Enjoyed
Thank You!

Greg

79