

OCT
Red, Yellow, and Blue Disease
What is Real Disease
and
What is Physiologically Normal

Greg Caldwell, OD, FAAO
Optometric Education Consultants
August 29, 20/20



Disclosure Statement
(next slide)

Disclosures- Greg Caldwell, OD, FAAO

- Will mention many products, instruments and companies during our discussion
 - ★ I don't have any financial interest in any of these products, instruments or companies
- Pennsylvania Optometric Association –President 2010
 - POA Board of Directors 2006-2011
- American Optometric Association, Trustee 2013-2016
- I never used or will use my volunteer positions to further my lecturing career
- Lectured for: Aerie, Alcon, Allergan, BioTissue, OptoVue
- Advisory Board: Allergan, Maculogix, Sight Sciences, Sun, Takeda
- Involve: PA Medical Director, Credential Committee
- Optometric Education Consultants- Scottsdale, St. Paul, Quebec City, Nashville, and Orlando/Disney OCT Users meeting; Owner



Financial Obligations



Green, Red, Yellow, and Blue Disease

Physiologically Normal
OCT measure structure

Green, Red, Yellow, and Blue Disease Hints to this Disease

🔗 If the disease is a bilateral disease

- ★ Glaucoma

- 📄 It is usually asymmetric

🔗 If the scans are symmetric

- ★ Then it most likely not disease – physiologically normal

- ★ Anatomical variation

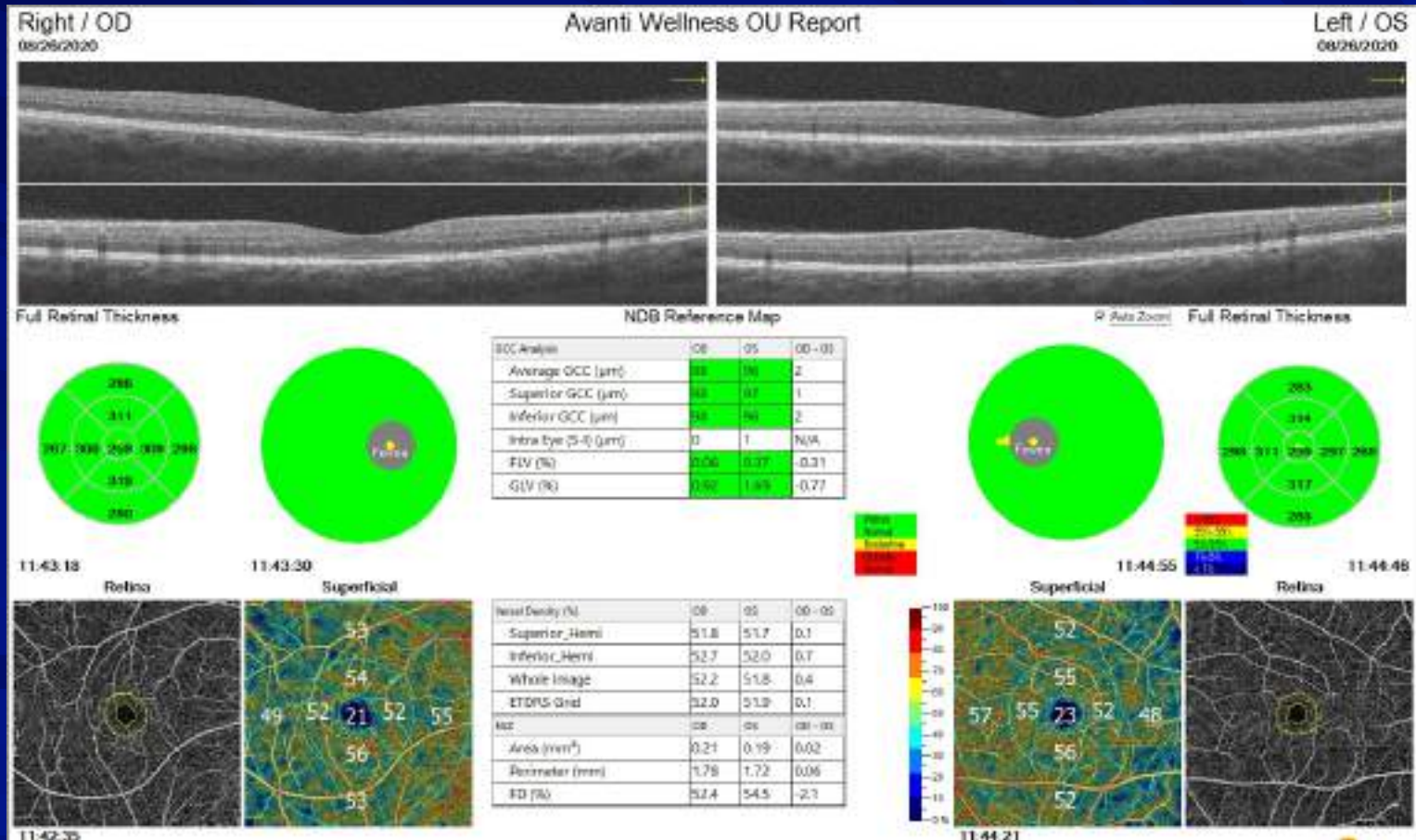
- 📄 Normal for that patient

🔗 Another hint is the GCC expected values

- ★ 85-100 microns

- ★ 92-95 microns

Symmetry and What is Being Tested



46-year-old woman with red-yellow disease

👁️ OD -0.75 20/20

👁️ OS -1.25 20/20

👁️ Systemic hx: thyroid dysfunction, high cholesterol

★ Medications for the above

👁️ IOPs 15 mm Hg OU 8:30 am

Right / OD
10/24/2016 08:27:57

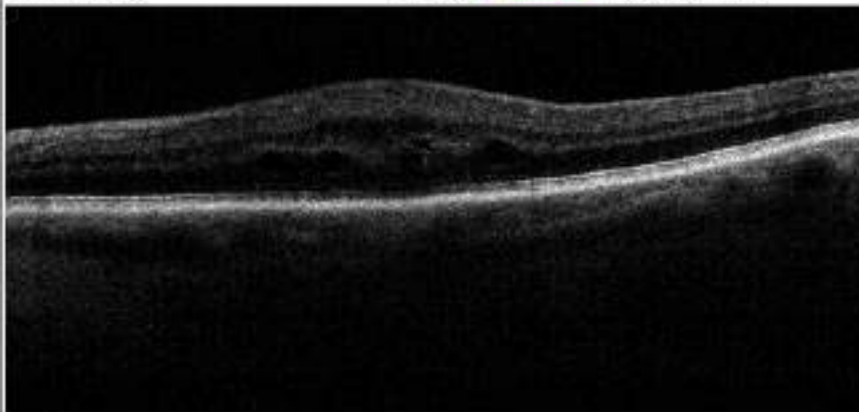
iWellness OU Report

Good 99 Scan Quality Index Good 99

Left / OS
10/24/2016 08:28:38

Retina Map

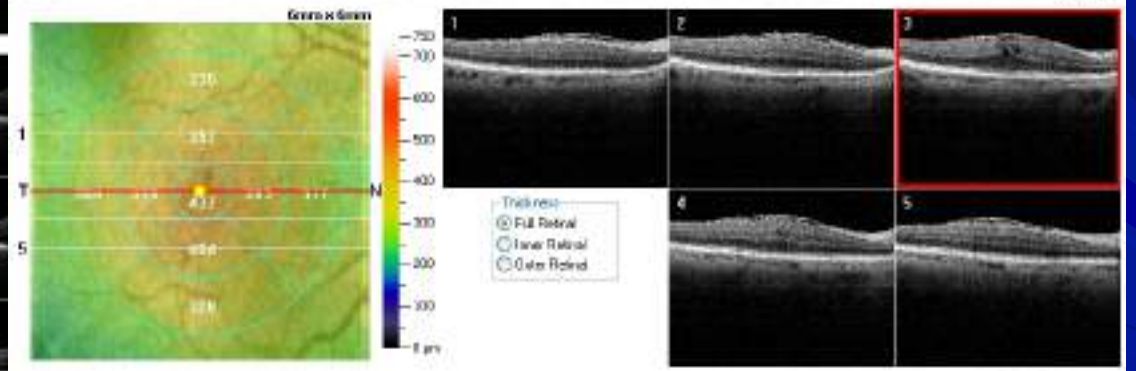
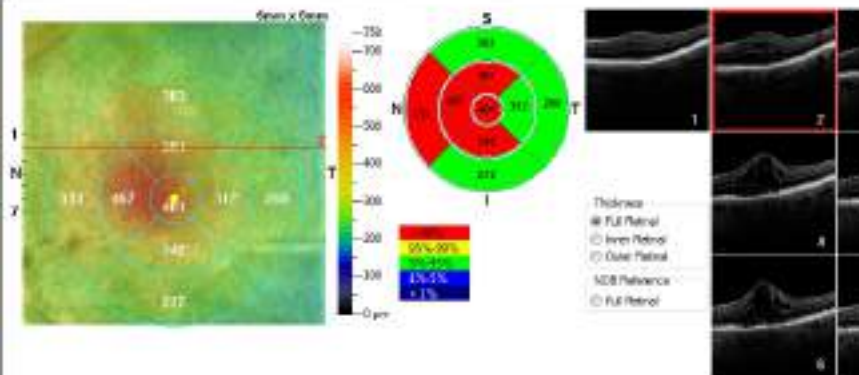
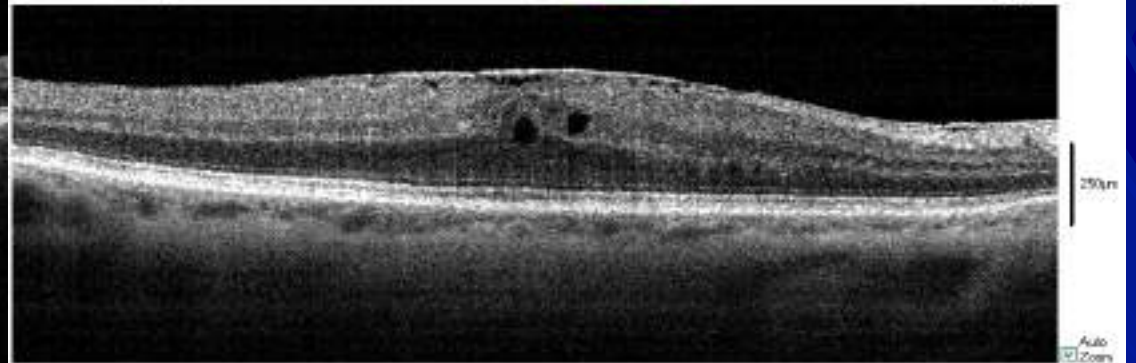
Scan Quality Index: Good 99 View Reproducibility



Retina Map

Scan Quality Index: Good 99

Right / OD



Print Change Analysis OU Report Comment

Print Change Analysis

Comment

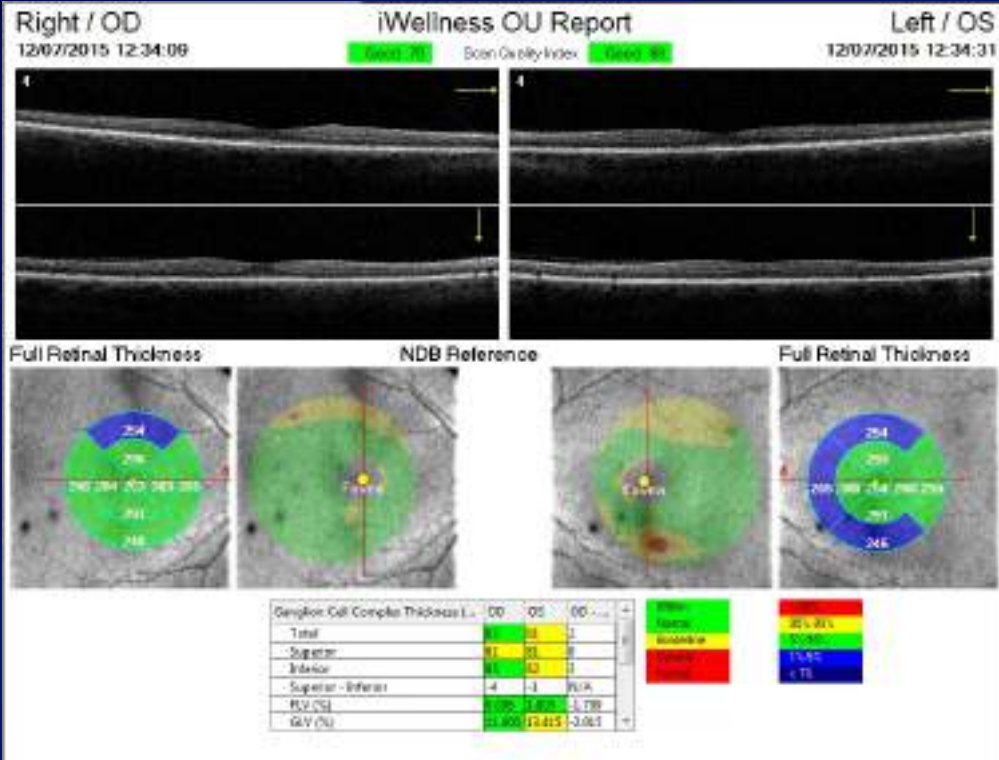
Comment

63-year-old woman with red, yellow, blue, and green disease

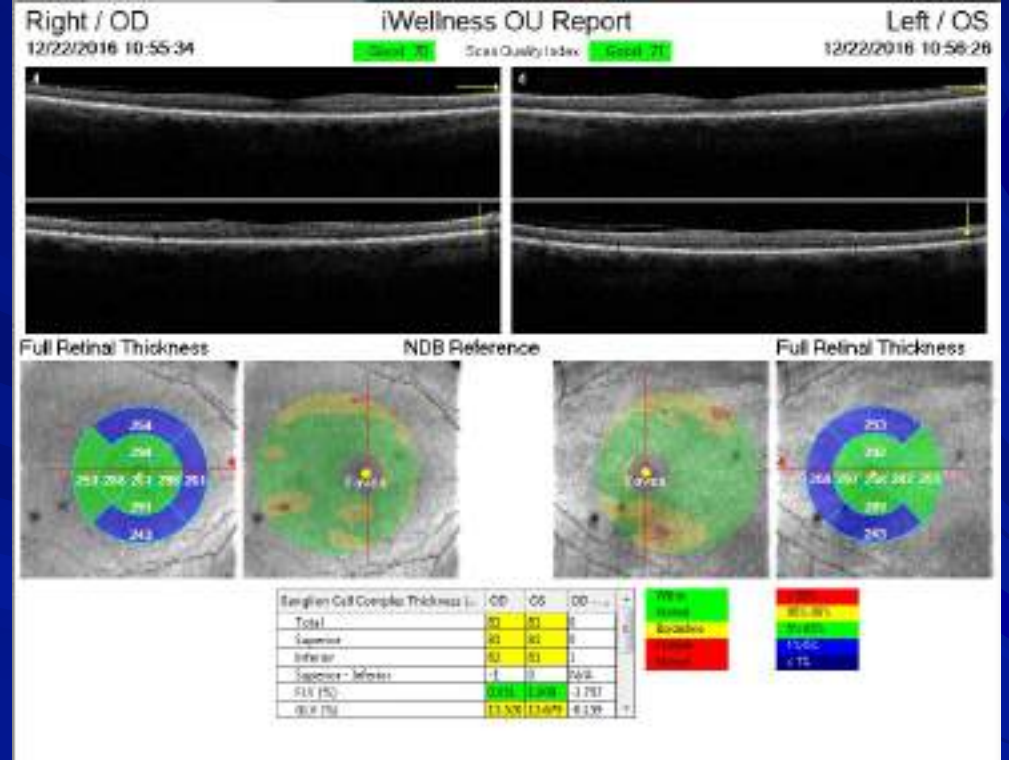
👁️ OD plano/ +2.00 20/20

👁️ OS -0.50/ +2.00 20/20

👁️ IOPs 15-18 mm Hg OU 2011-2015



2015



2016

58-year-old with yellow disease

👁️ OD +1.00 20/20

👁️ OS +1.25 20/20

👁️ IOPs: 13/15 mm Hg at 11:24 am

👁️ (pay attention to FLV and GLV)

Right / OD

11/15/2016 10:53:43

iWellness OU Report

Good 77

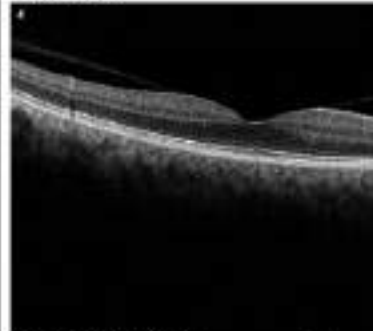
Scan Quality Index

Good 71

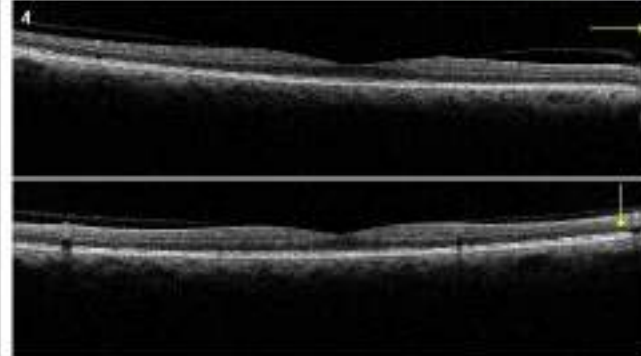
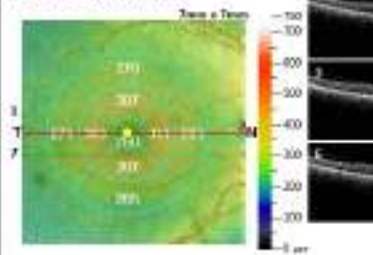
Left / OS

11/15/2016 10:54:21

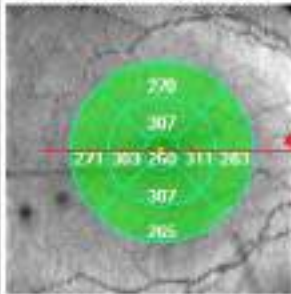
iWellness



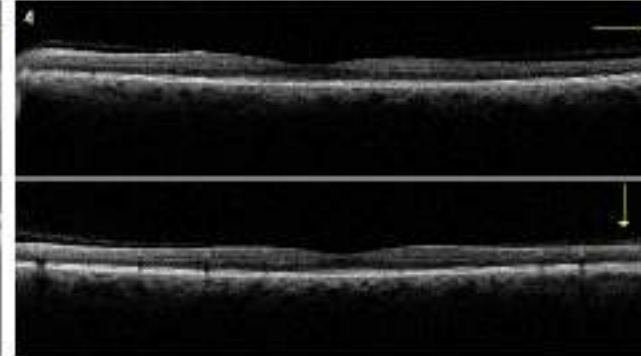
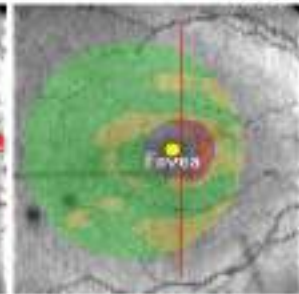
Full Retinal Thickness



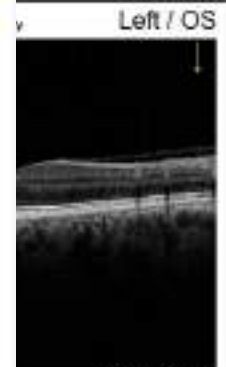
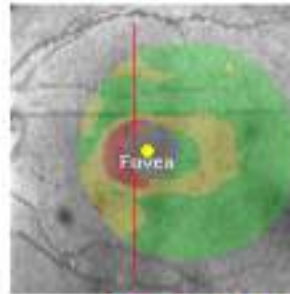
Full Retinal Thickness




NDB Reference




Full Retinal Thickness



NDB Reference



| Ganglion Cell Complex Thickness (... | OD | OS | OD - OS |
|--------------------------------------|--------|--------|---------|
| Total | 82 | 81 | 1 |
| Superior | 82 | 81 | 1 |
| Inferior | 81 | 81 | 0 |
| Superior - Inferior | 1 | 0 | N/A |
| FLV (%) | 0.942 | 1.218 | -1.268 |
| GLV (%) | 12.517 | 12.785 | -0.268 |



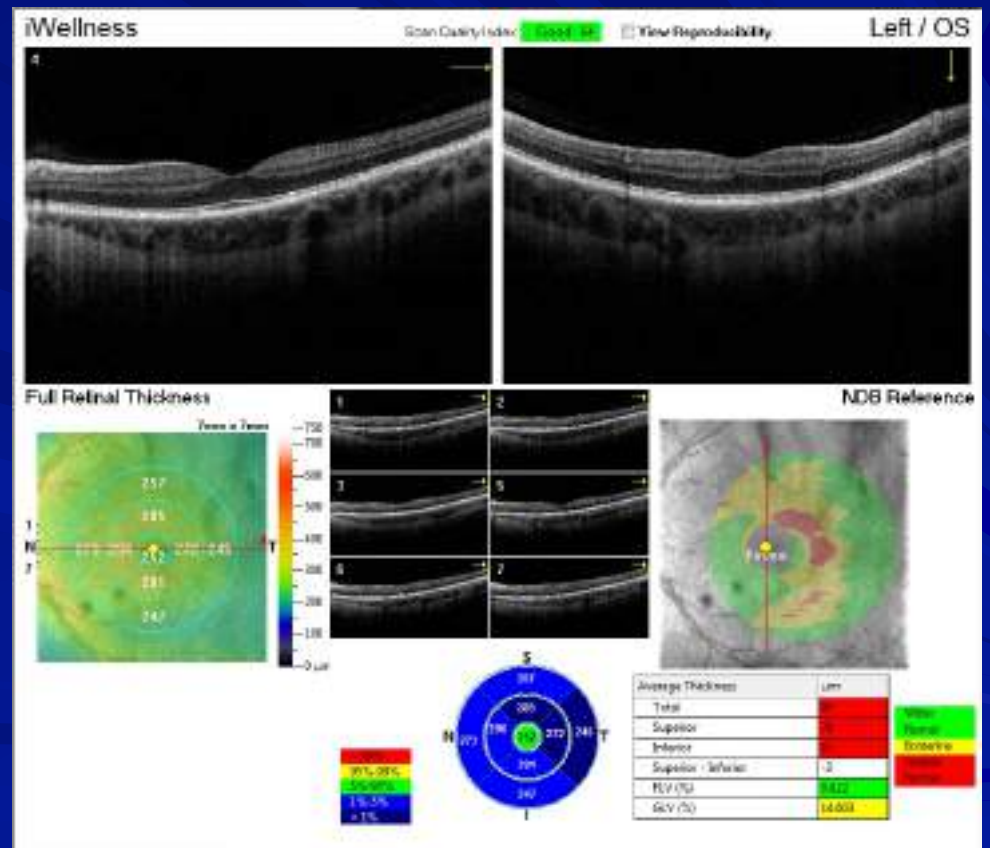
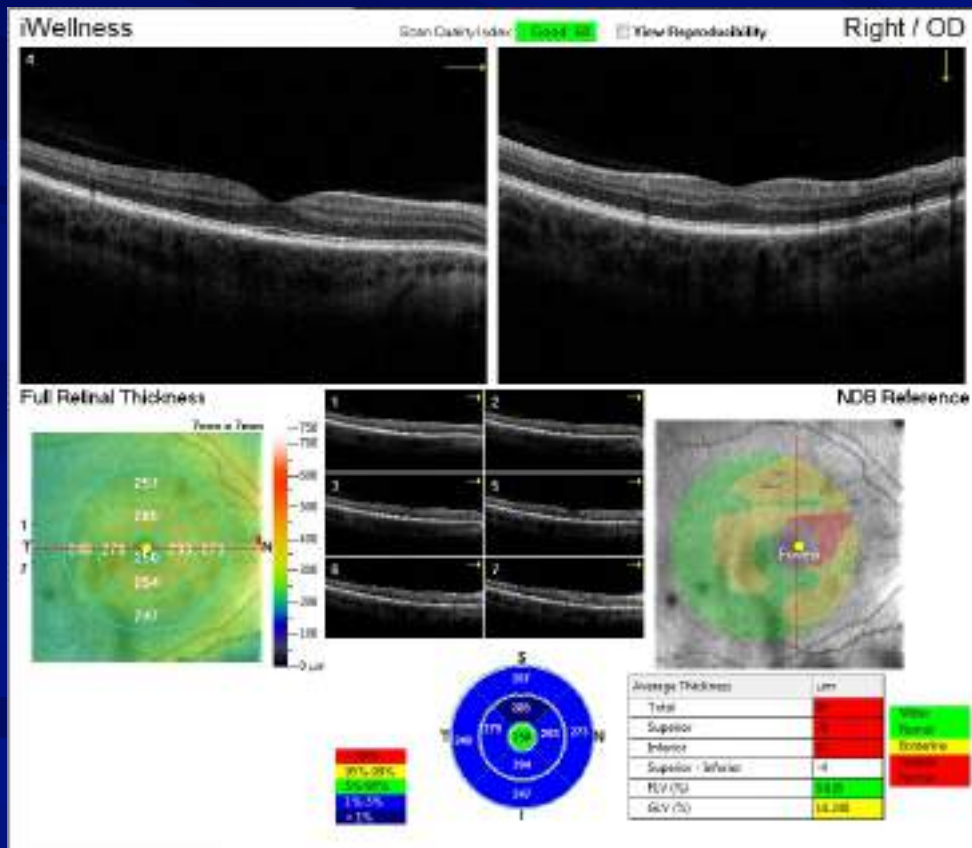
40 yo man with red, blue, green disease

👁️ OD -7.50 – 0.75 x 110 20/20

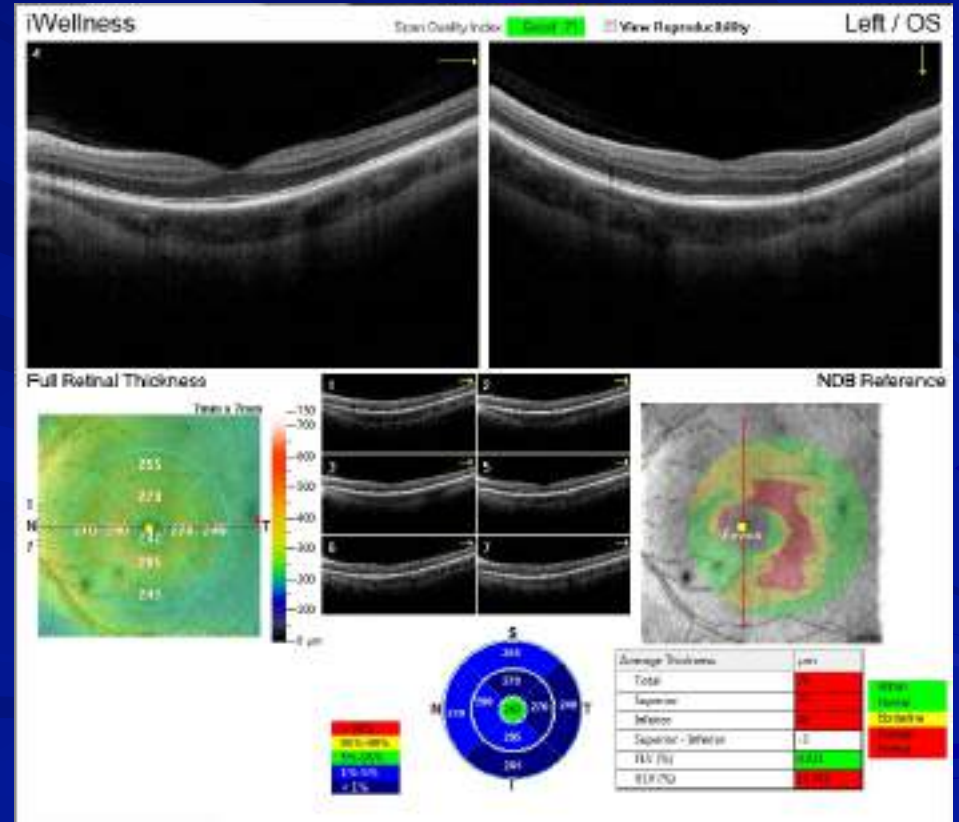
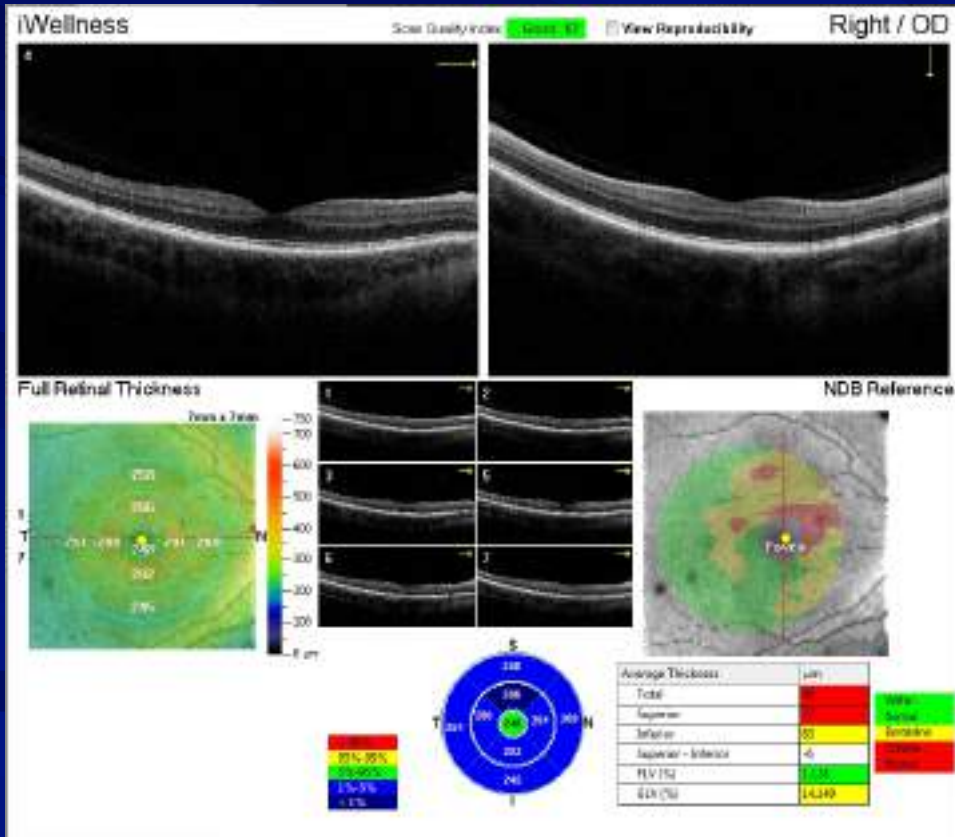
👁️ OS -7.50 – 0.75 x 105 20/20

👁️ IOPs: 15/13 mm Hg at 6:30 pm

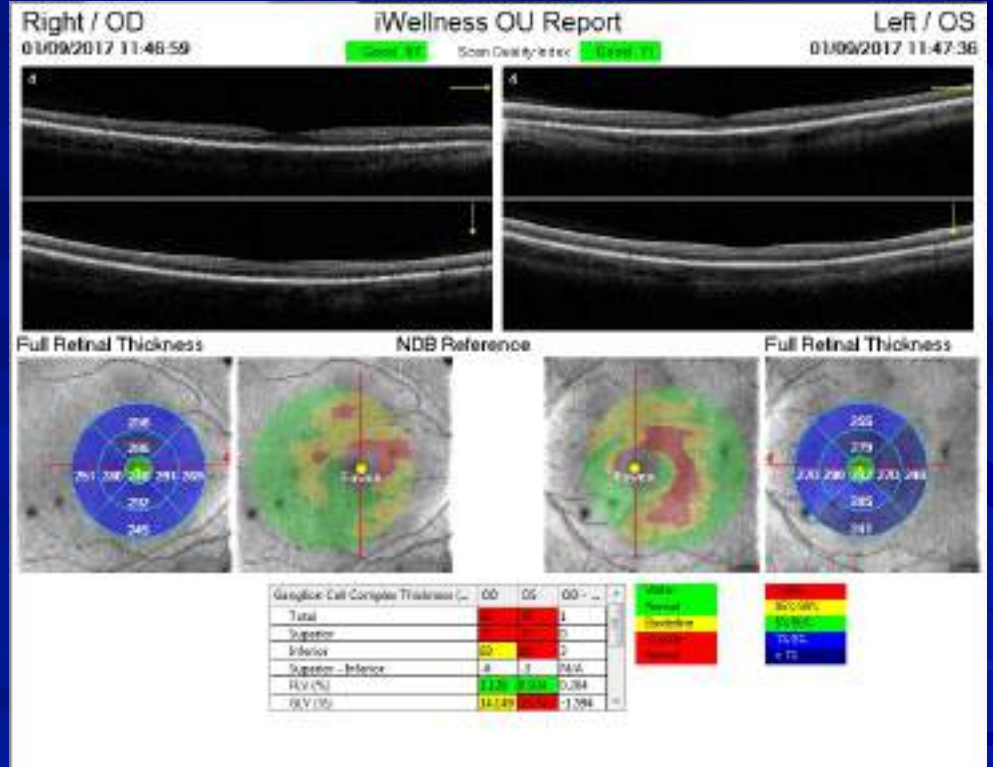
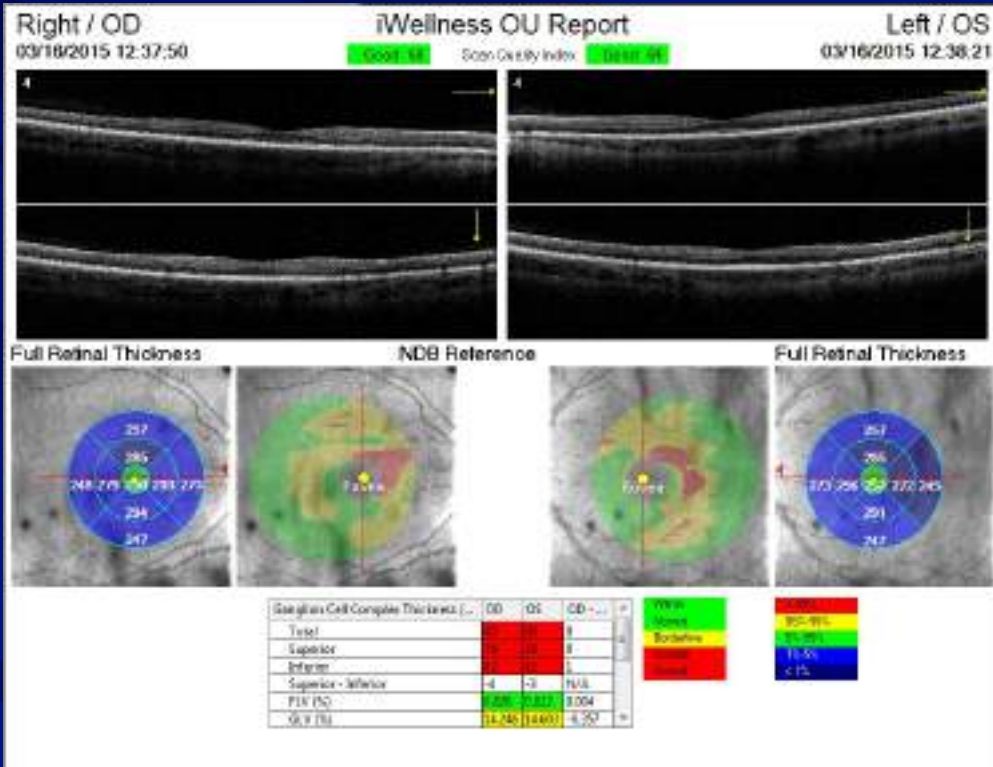
March 16, 2015



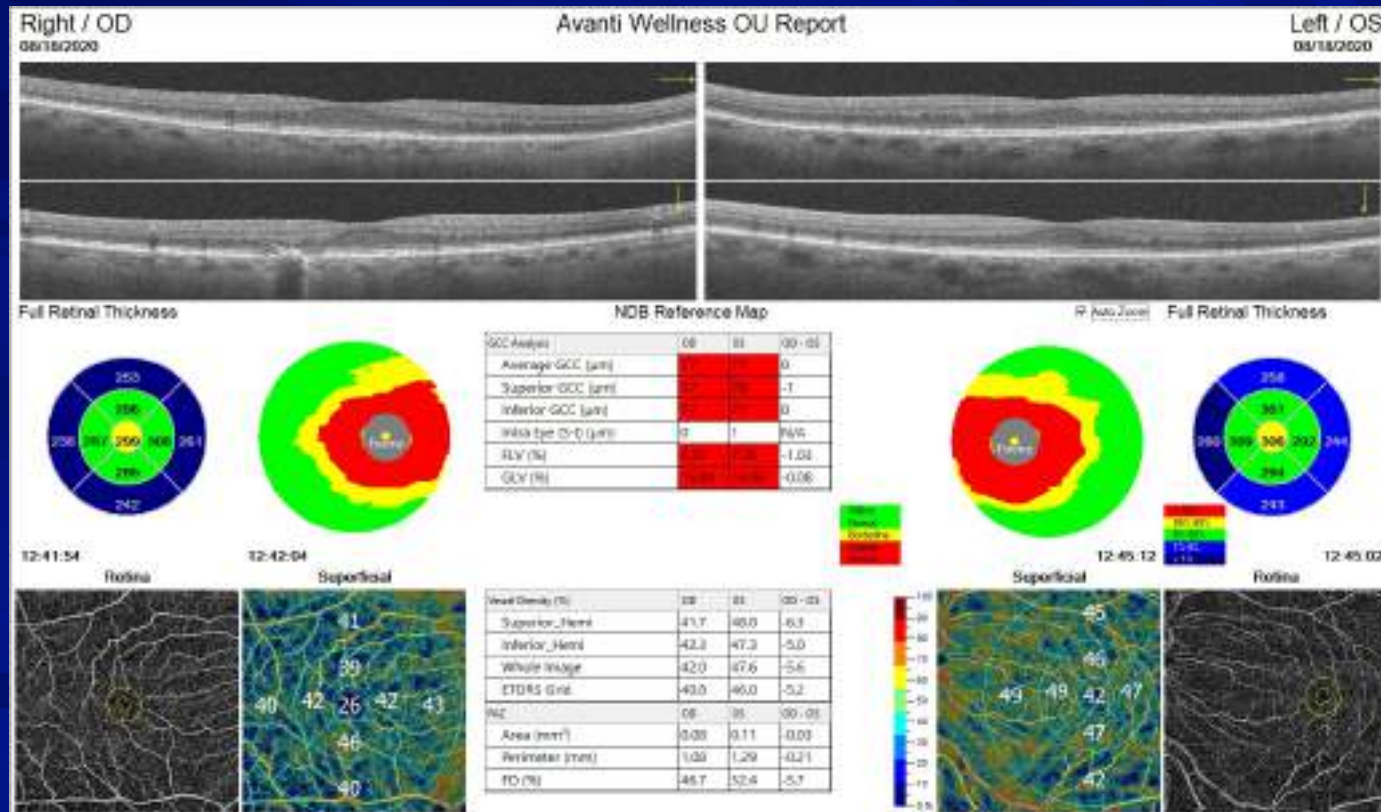
January 9, 2017



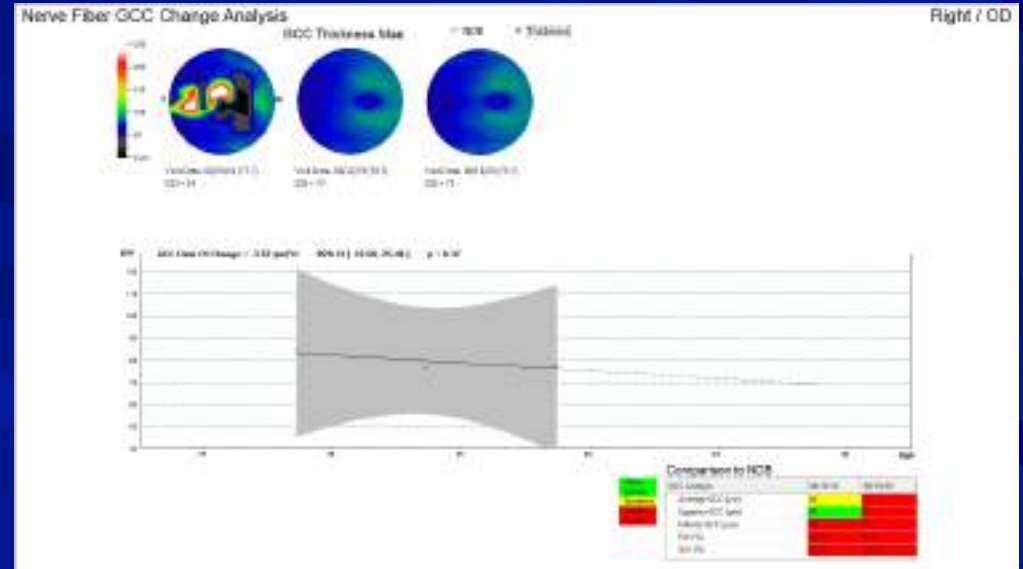
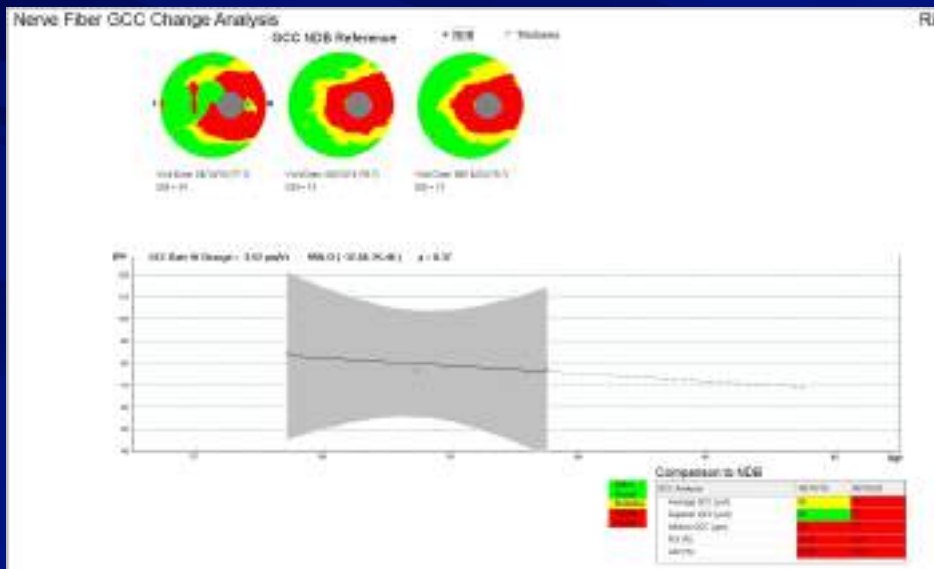
22 months apart



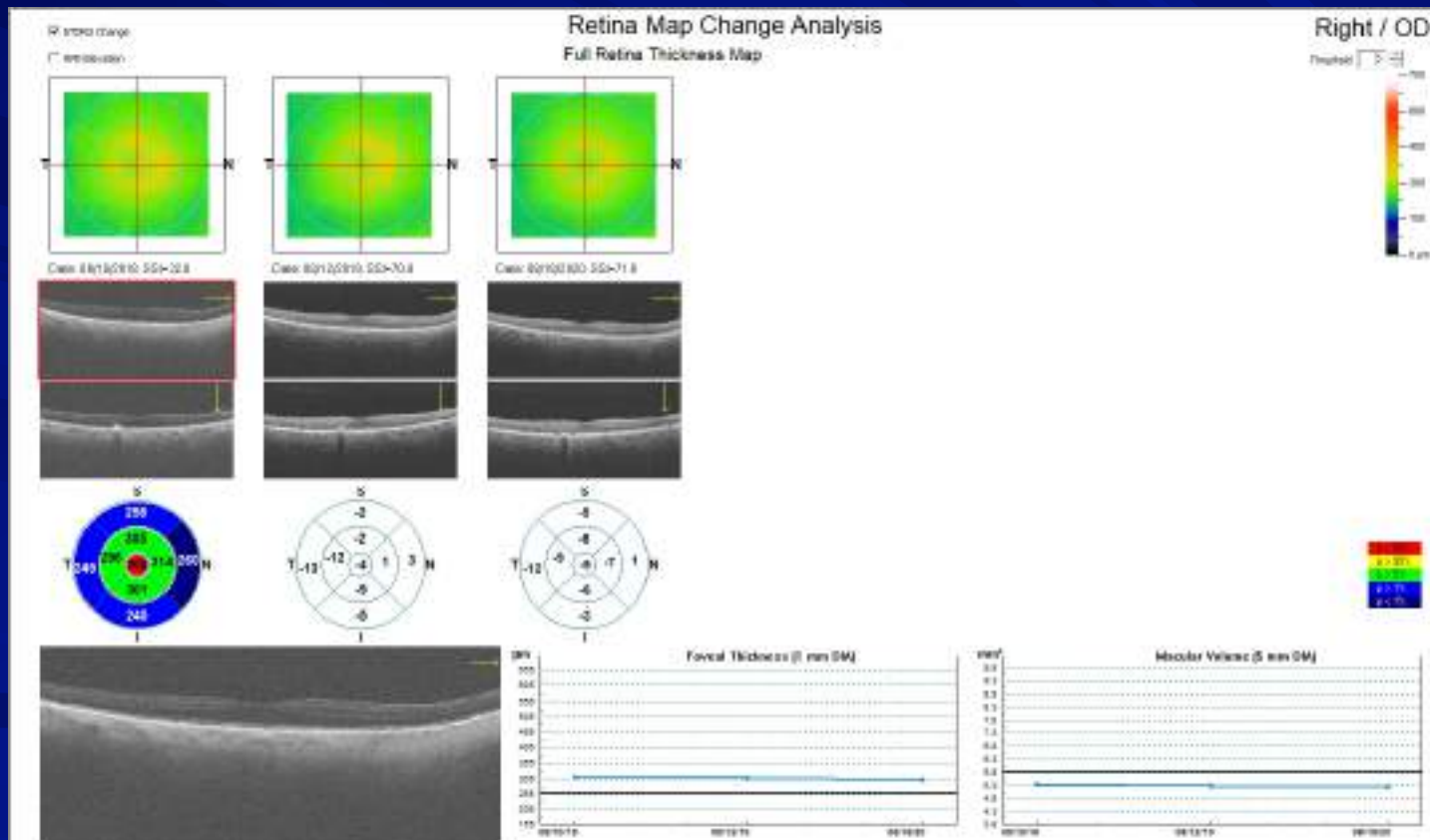
79 year-old-woman with DM



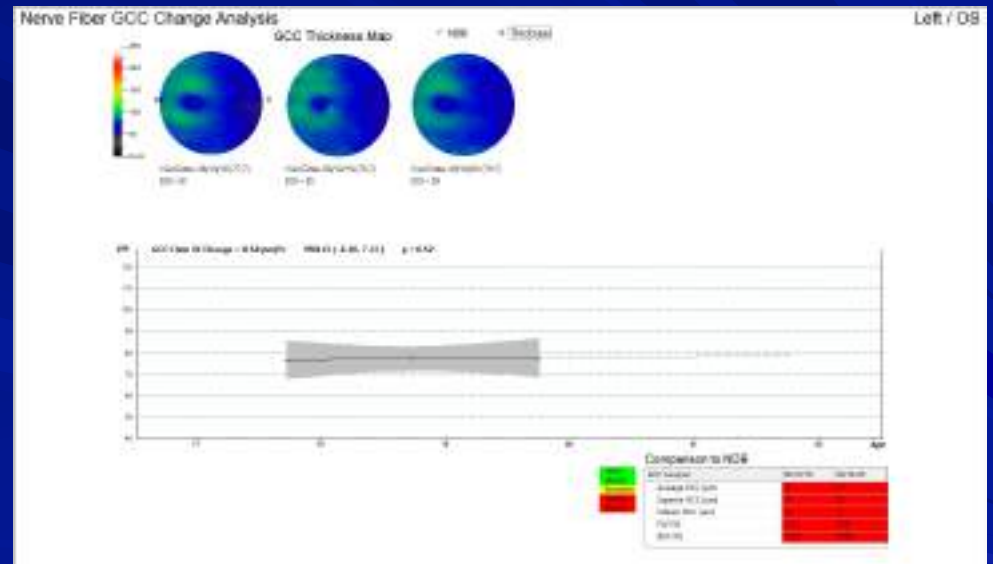
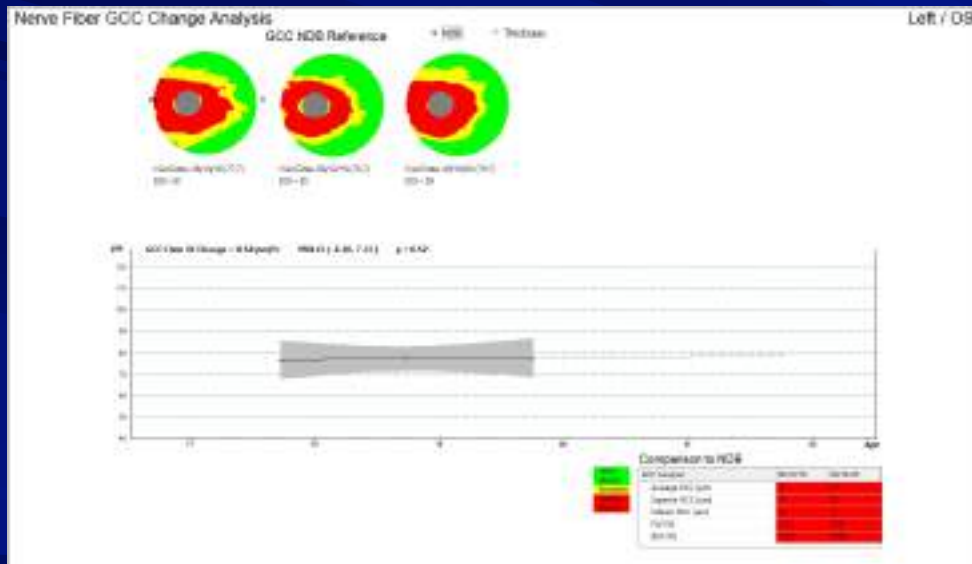
79 year-old-woman with DM



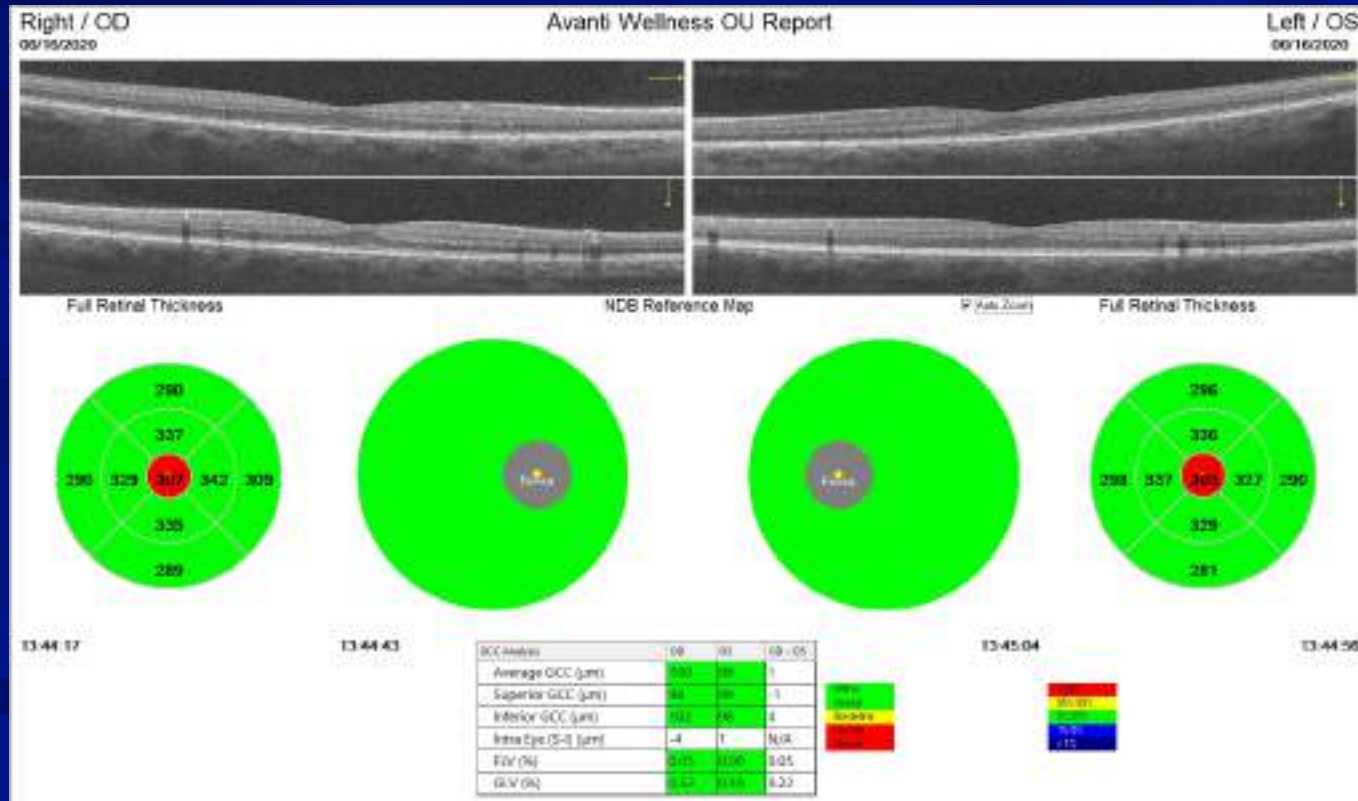
79 year-old-woman with DM



79 year-old-woman with DM



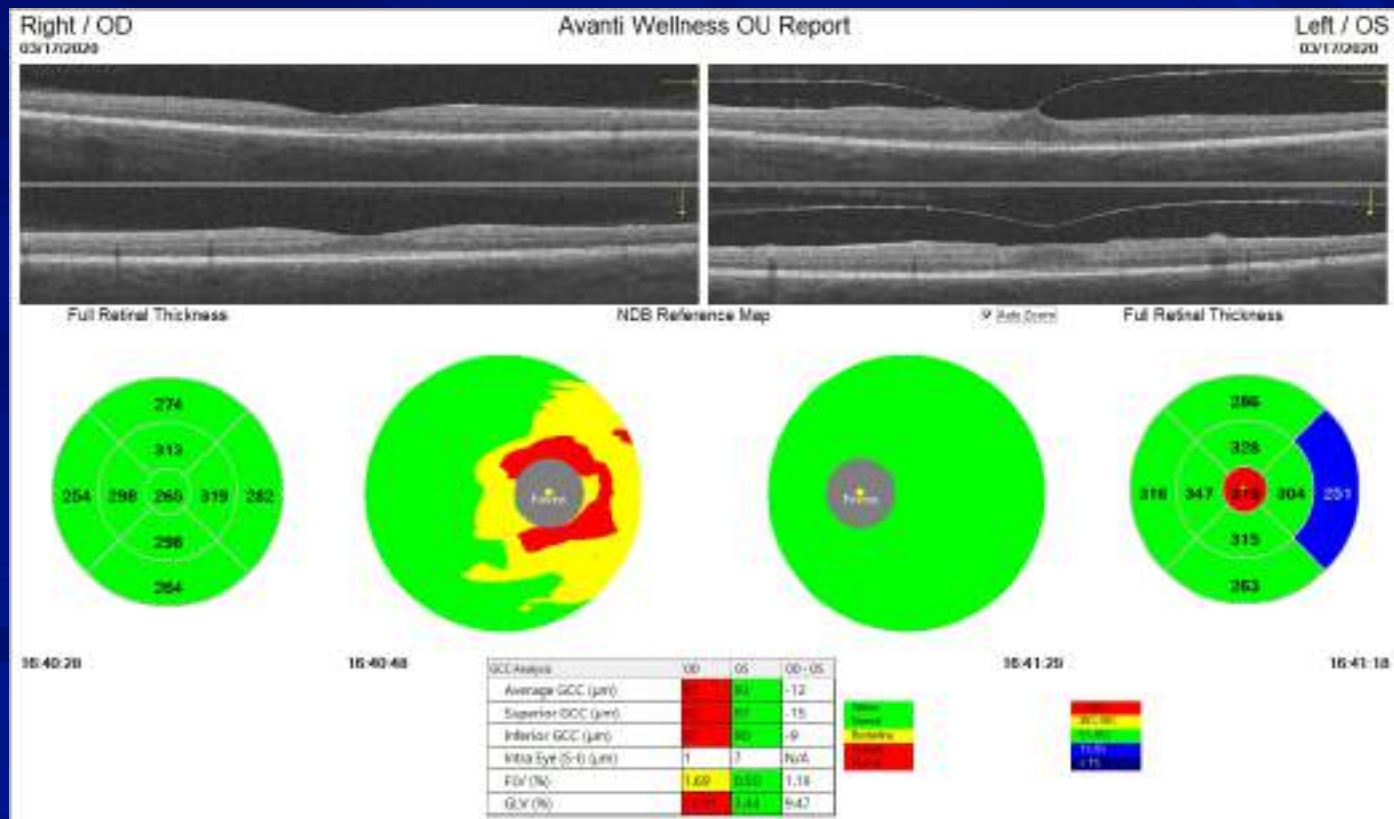
28-year-old man with myopia



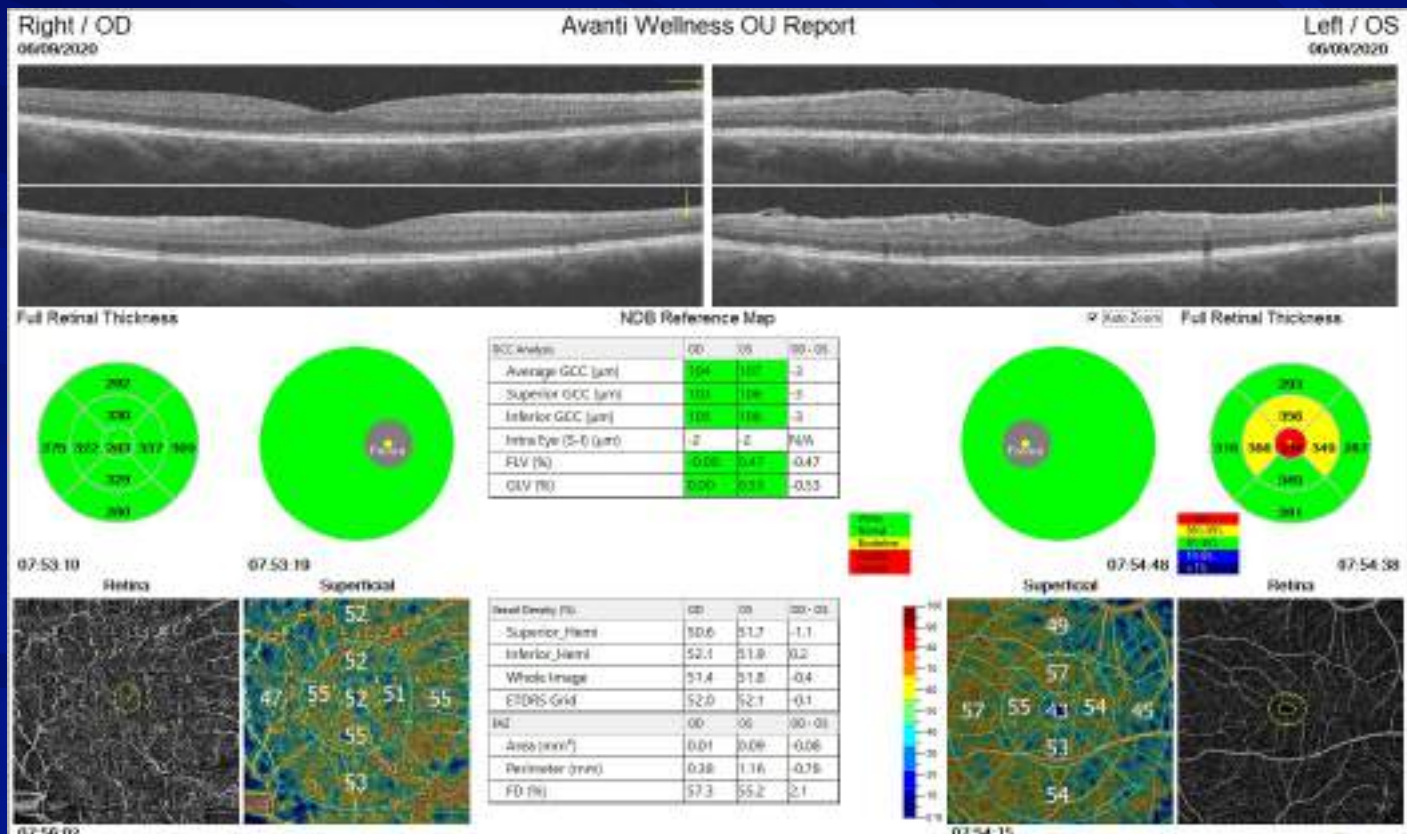
Green, Red, Yellow, and Blue Disease

Real Disease

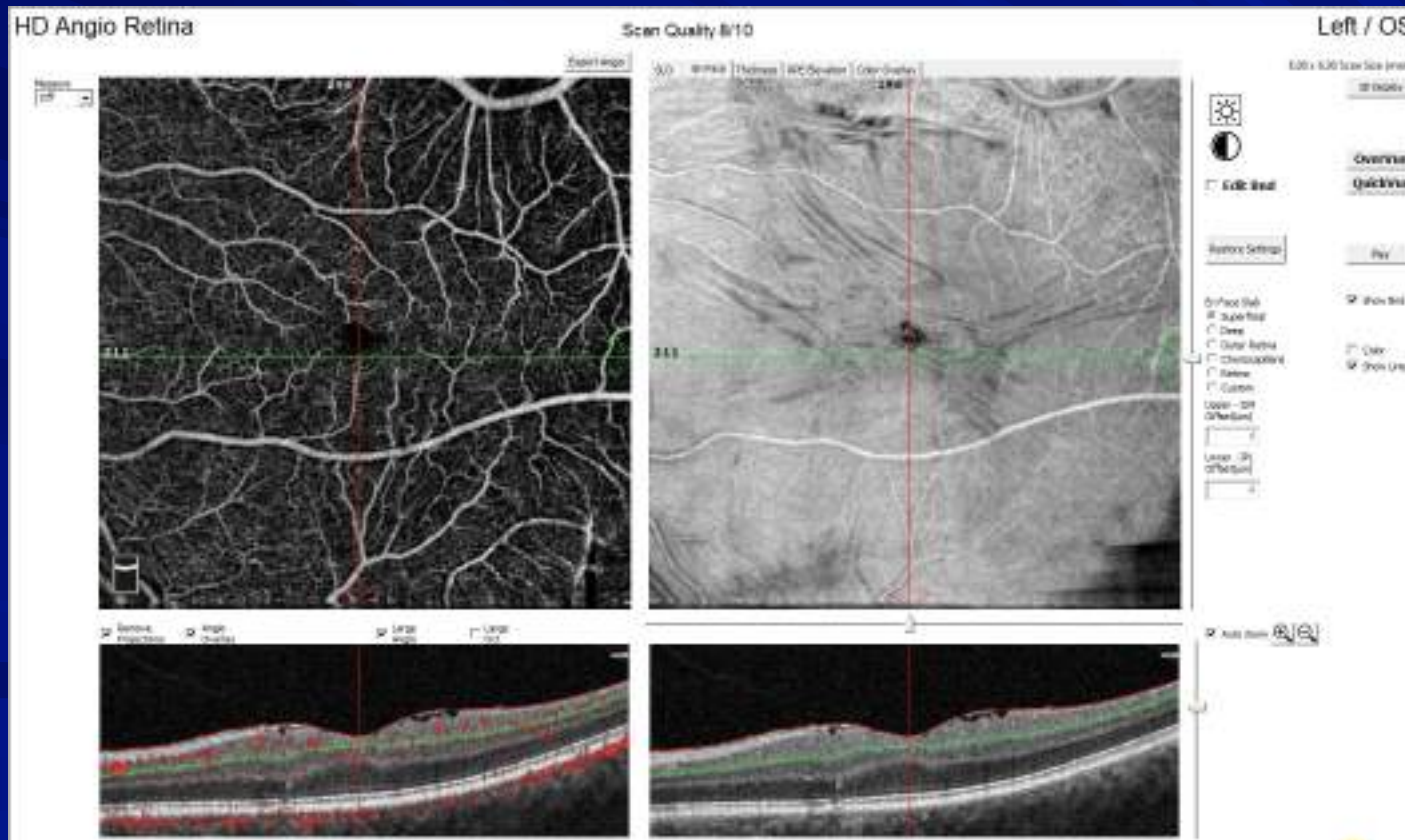
30-year-old woman “Need my CL updated”



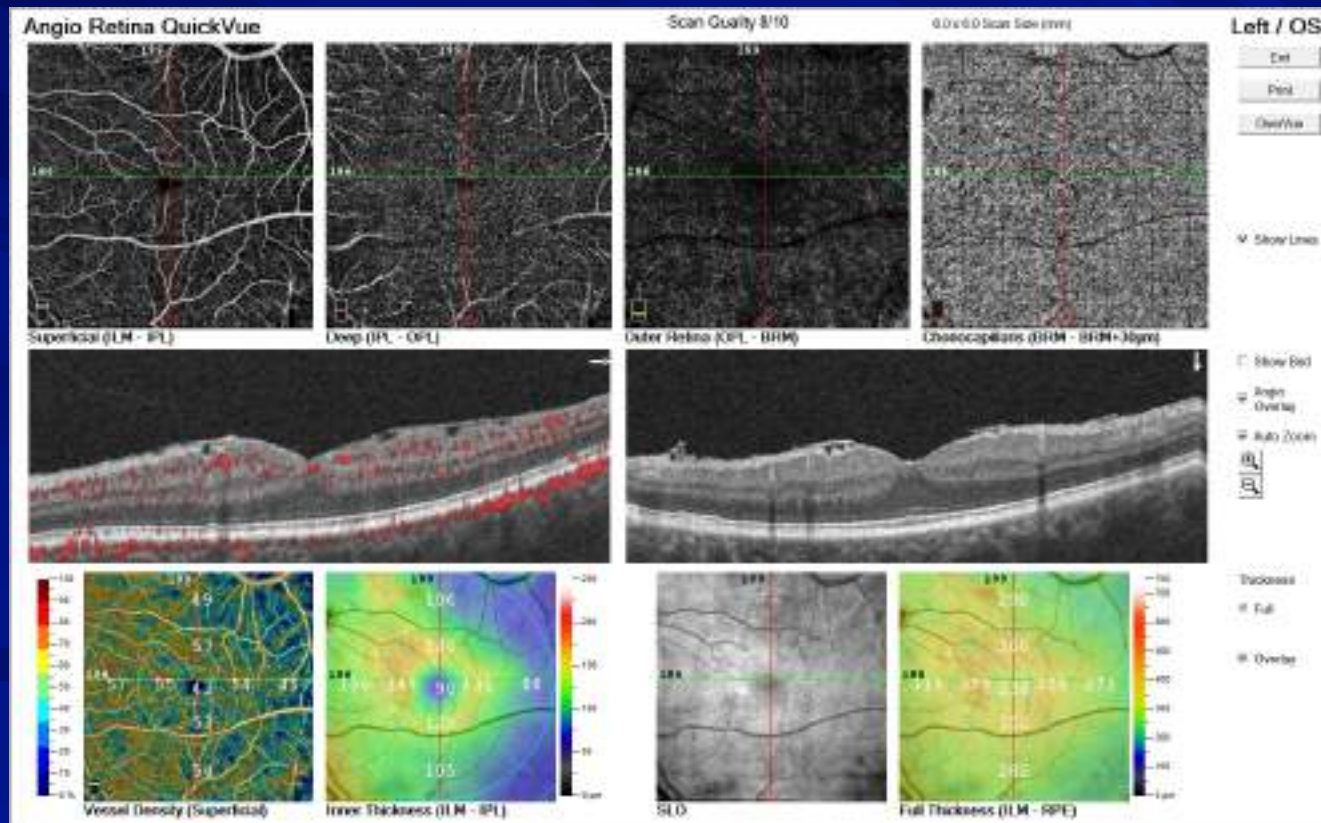
72-year-old man Cataract check



72-year-old man Cataract check

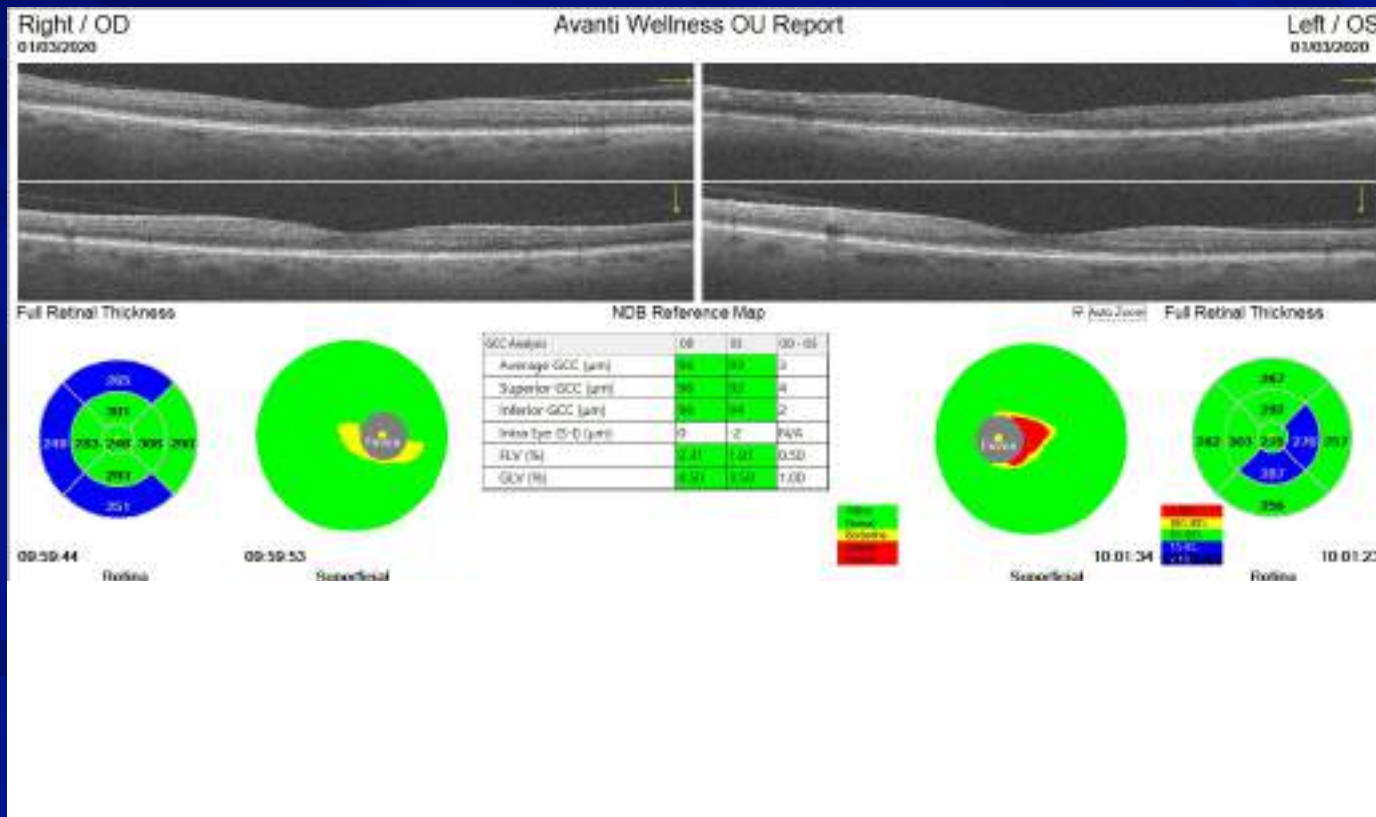


72-year-old man Cataract check

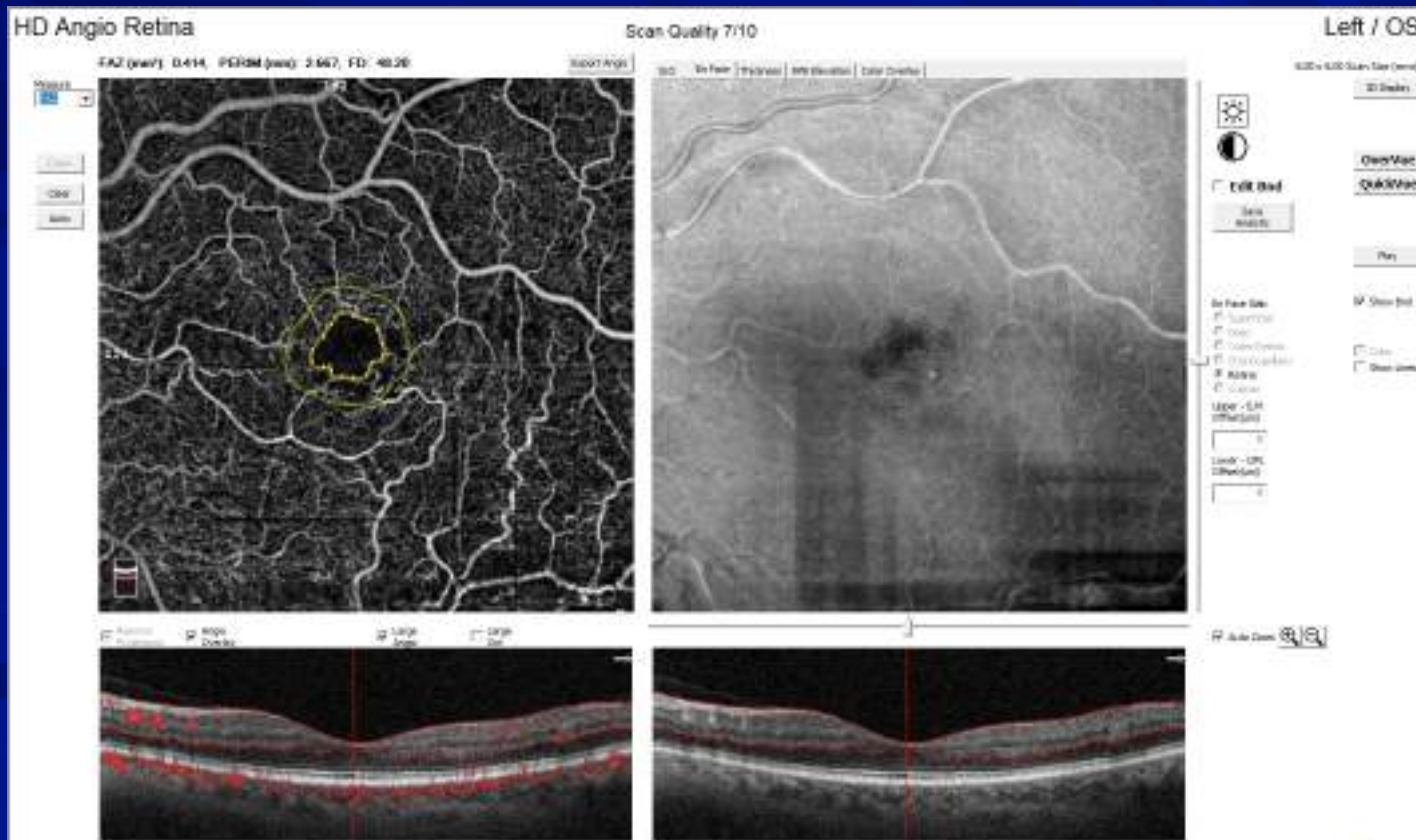


63-year-old woman with DM

HbA1c = 8.0




63-year-old woman with DM HbA1c = 8.0



59-year-old man with DM

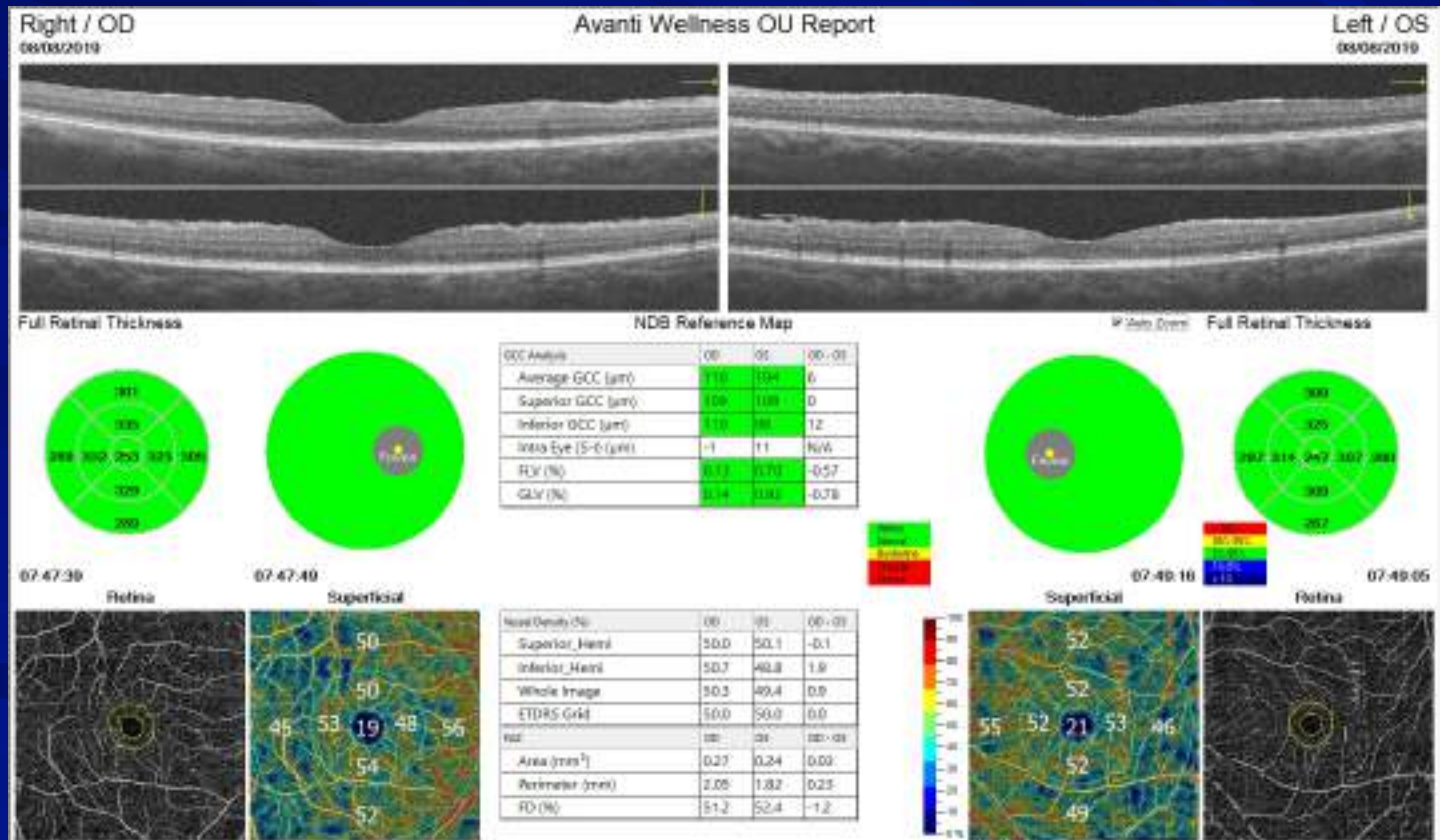
HbA1c = 7.8



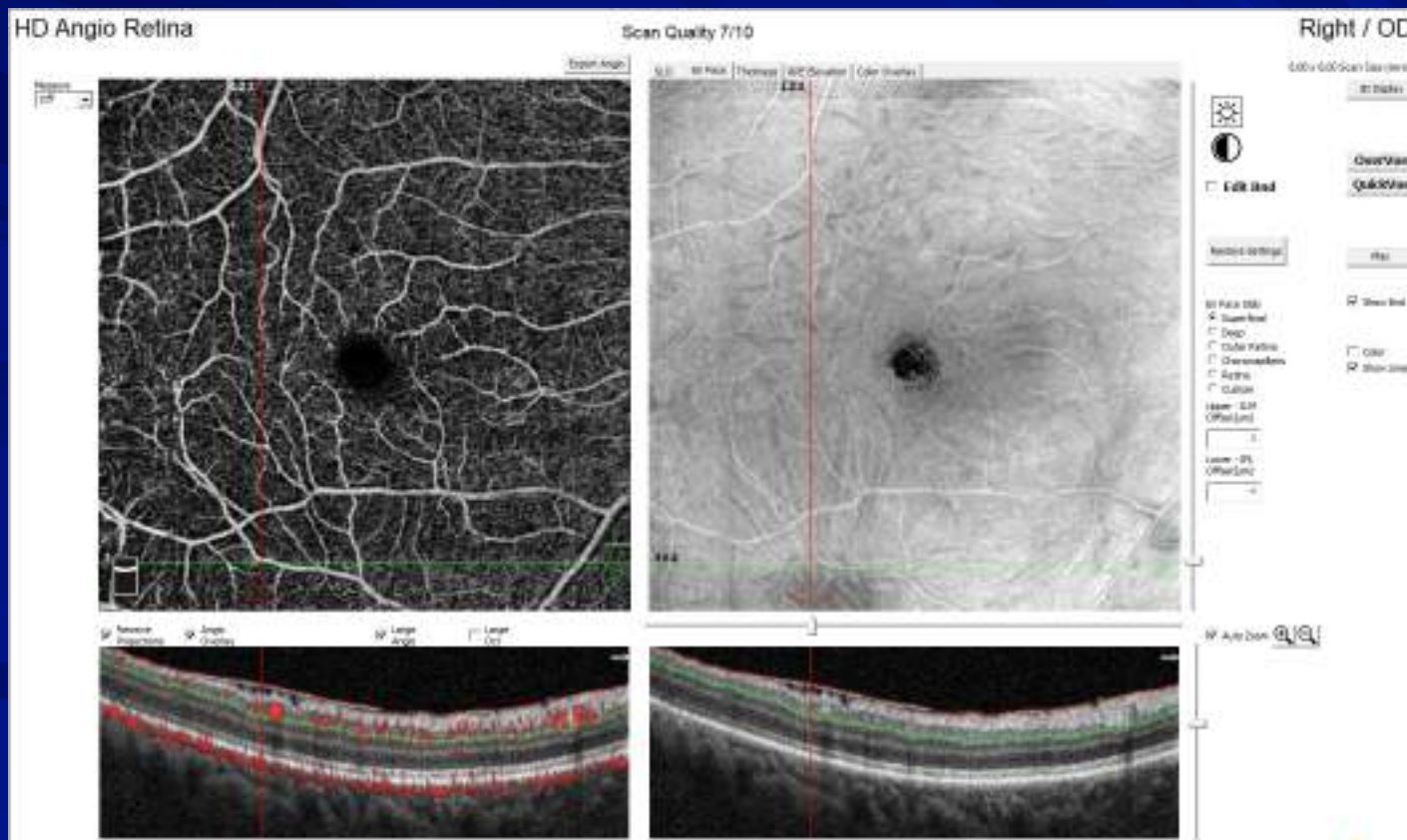
Advanced Interpretation

Green Disease

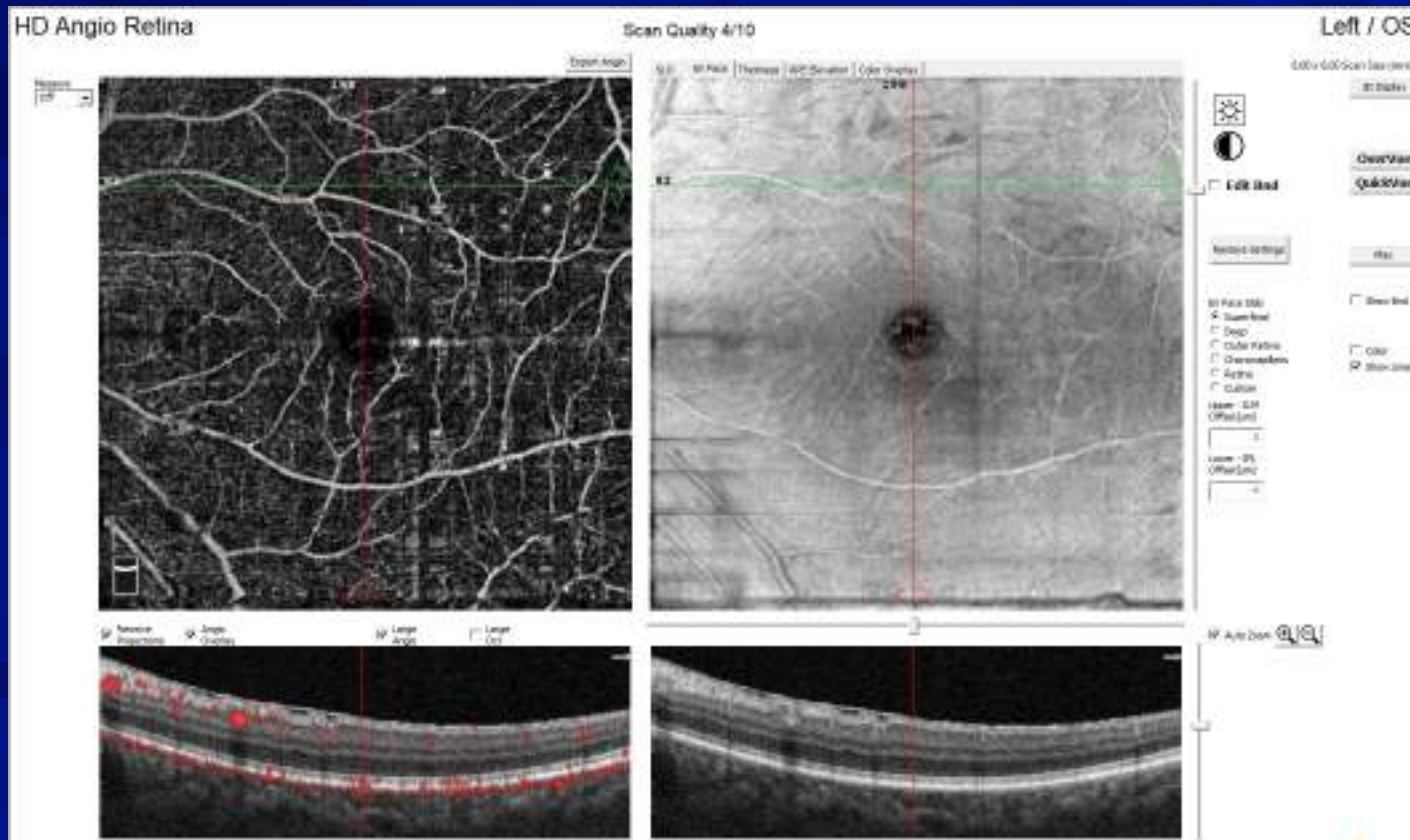
71-year-old woman Cataract Check



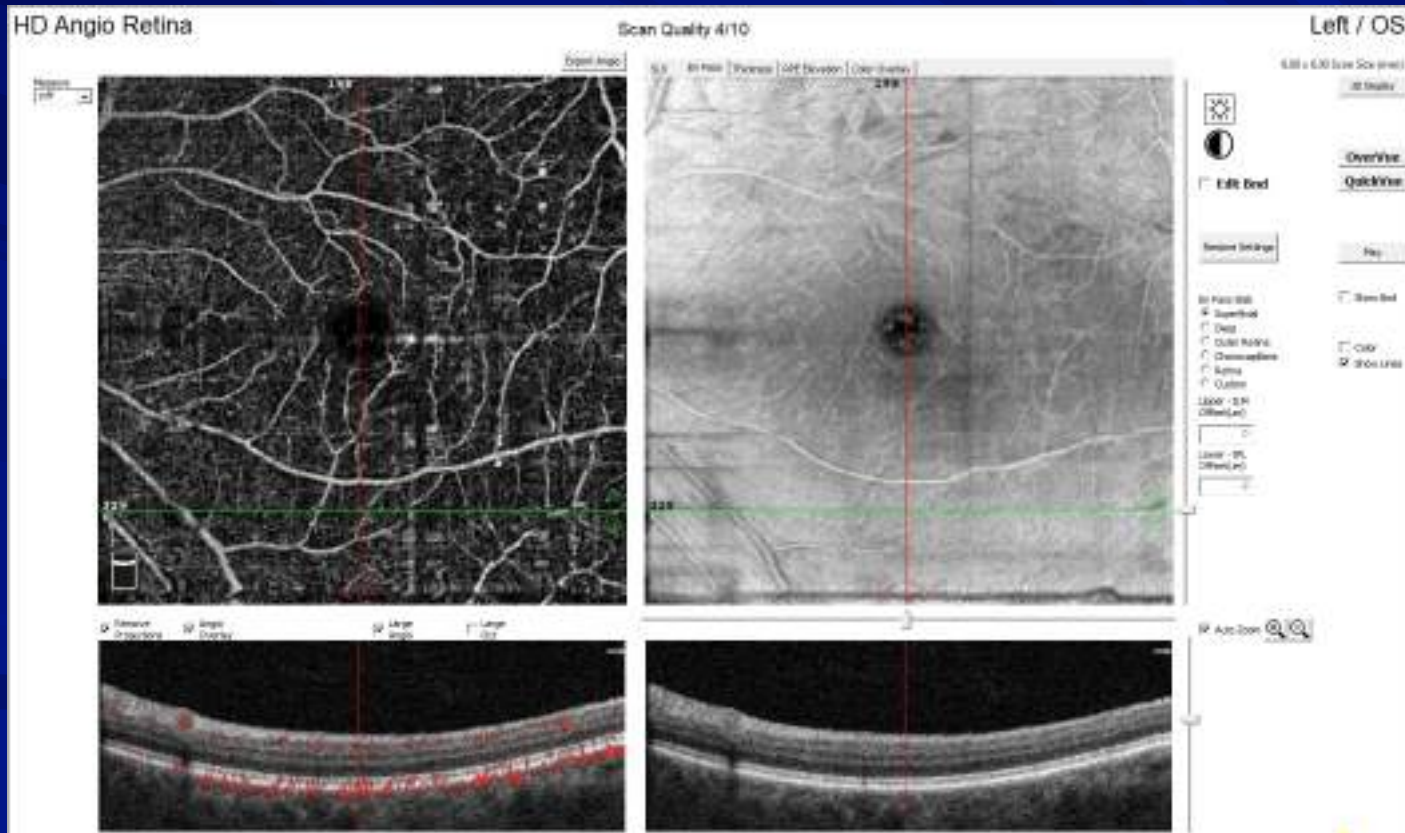
71-year-old woman Cataract Check



71-year-old woman Cataract Check



71-year-old woman Cataract Check



GREEN DISEASE– AN INSIDIOUS CLINICAL ENTITY

A glaucomatous process masquerading as non-disease

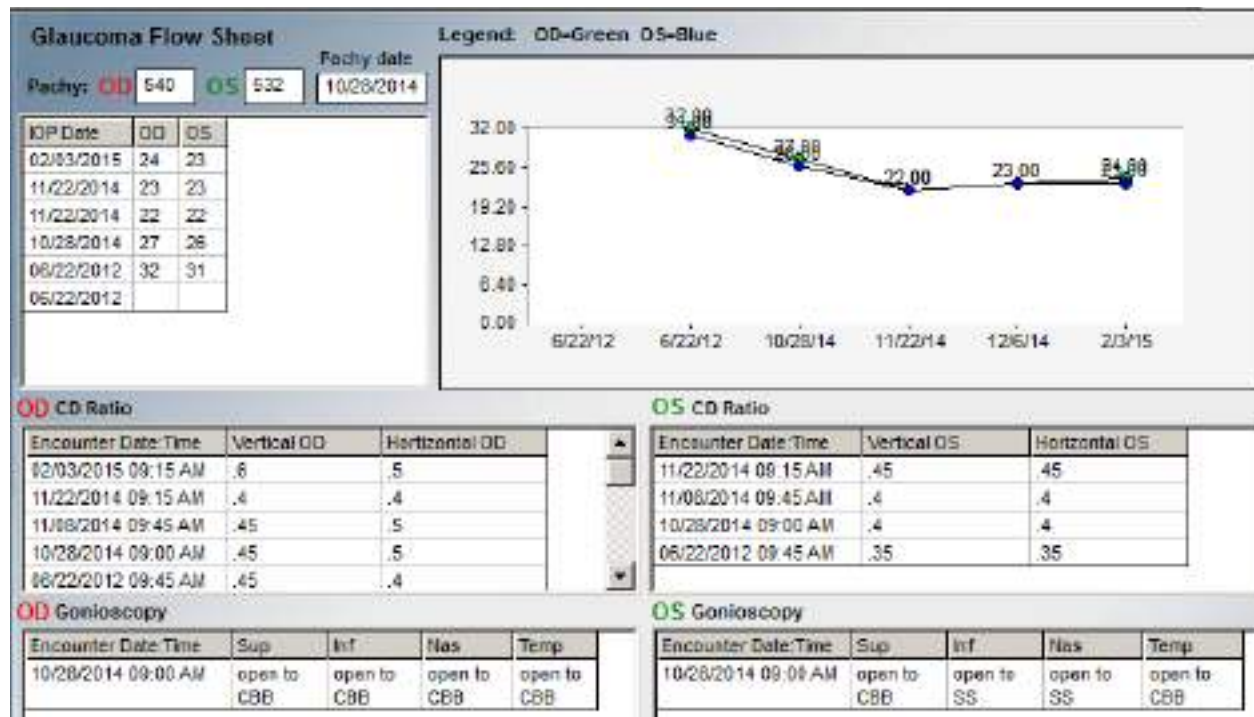
Afflicts inexperienced, poorly-educated, and lazy doctors who simply want a machine to make all clinical decisions for them

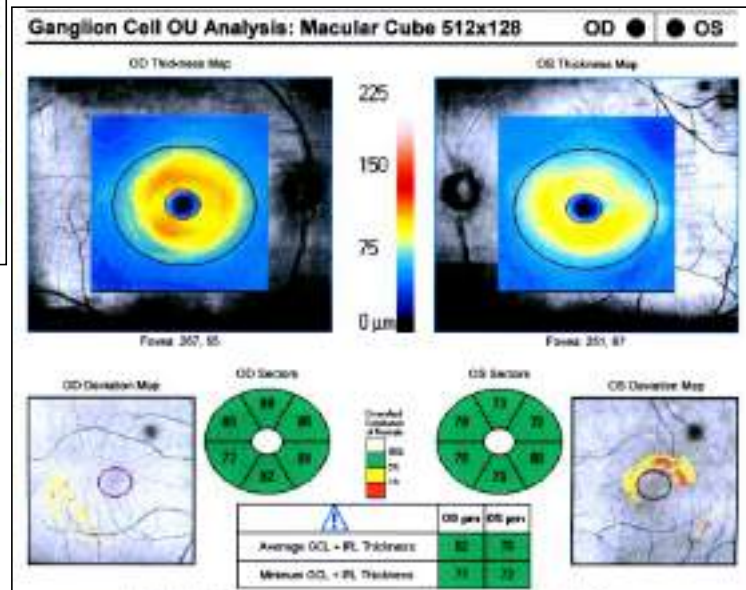
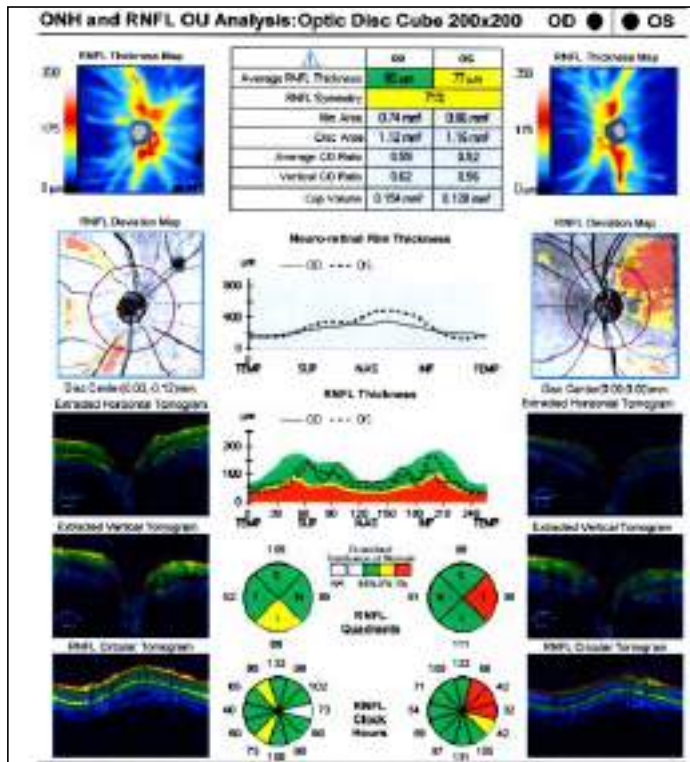
Debilitating to the patient and painful for the visual care provider, but a boon for malpractice attorneys

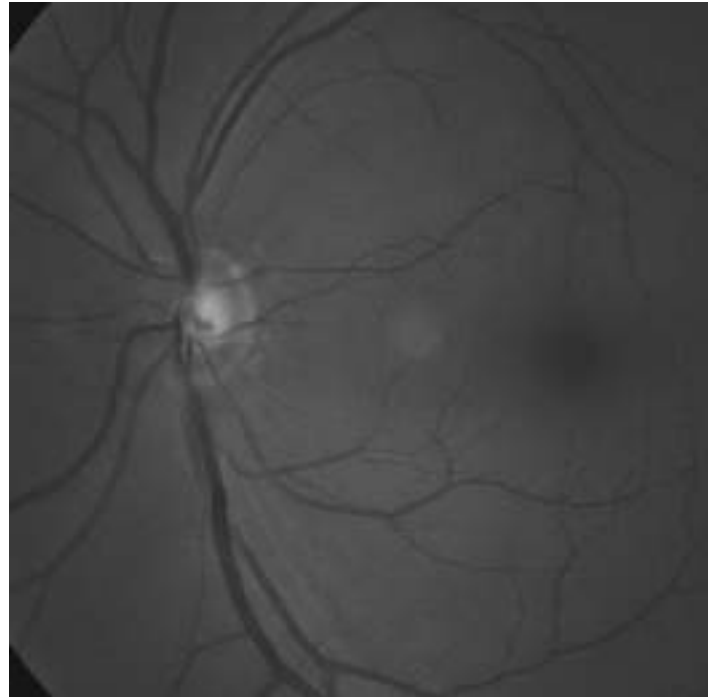
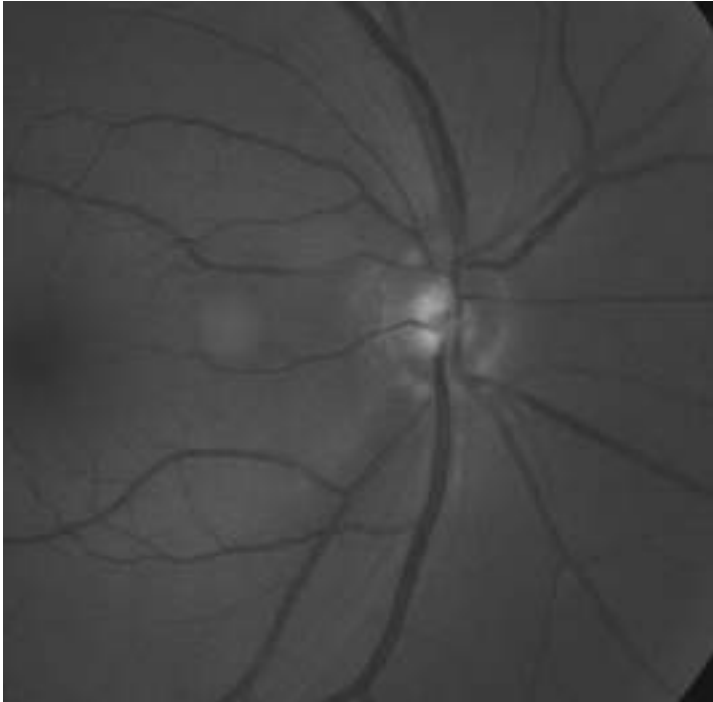
NS Sherlock. *Journal of Irreproducible Results and Senseless Studies*. 2015.






HELP! THE DIAGNOSTIC IMAGING DOESN'T AGREE WITH MY DIAGNOSIS!

- 56 YOM- Glaucoma suspect since 2012



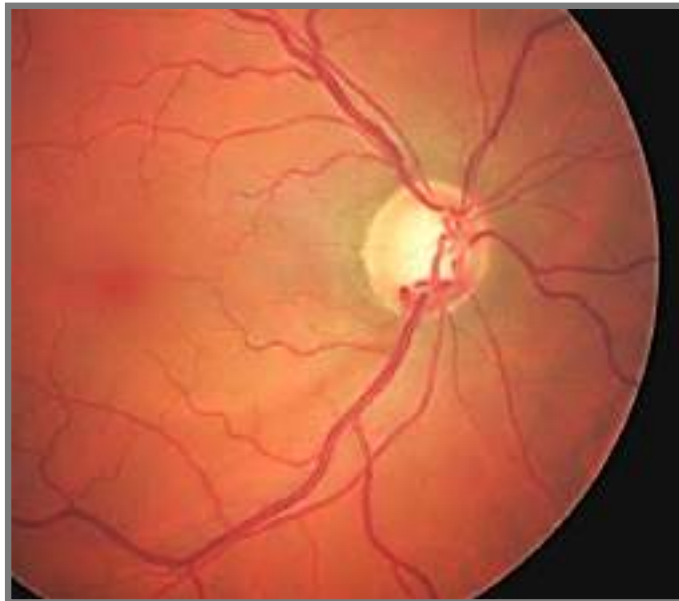



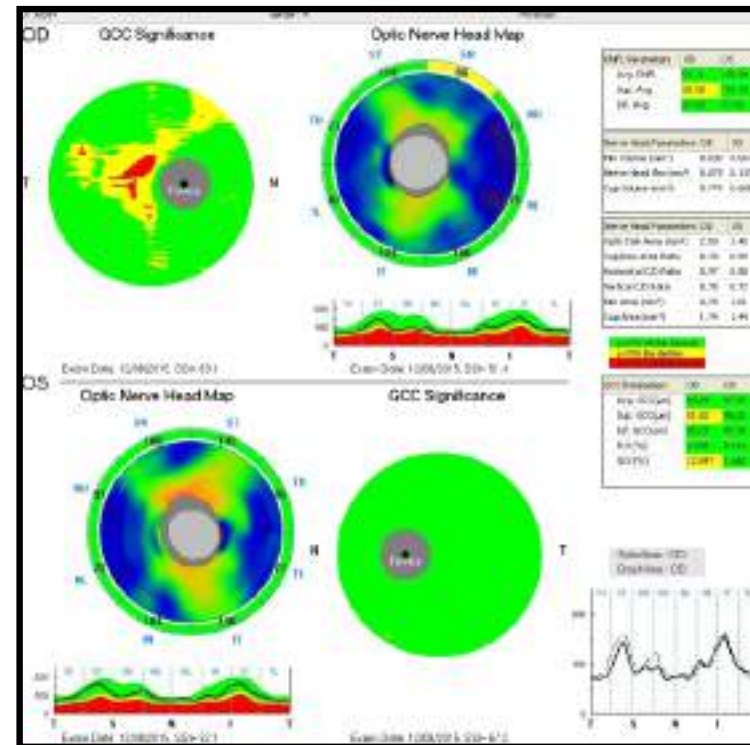


Is this person really a glaucoma 'suspect'?

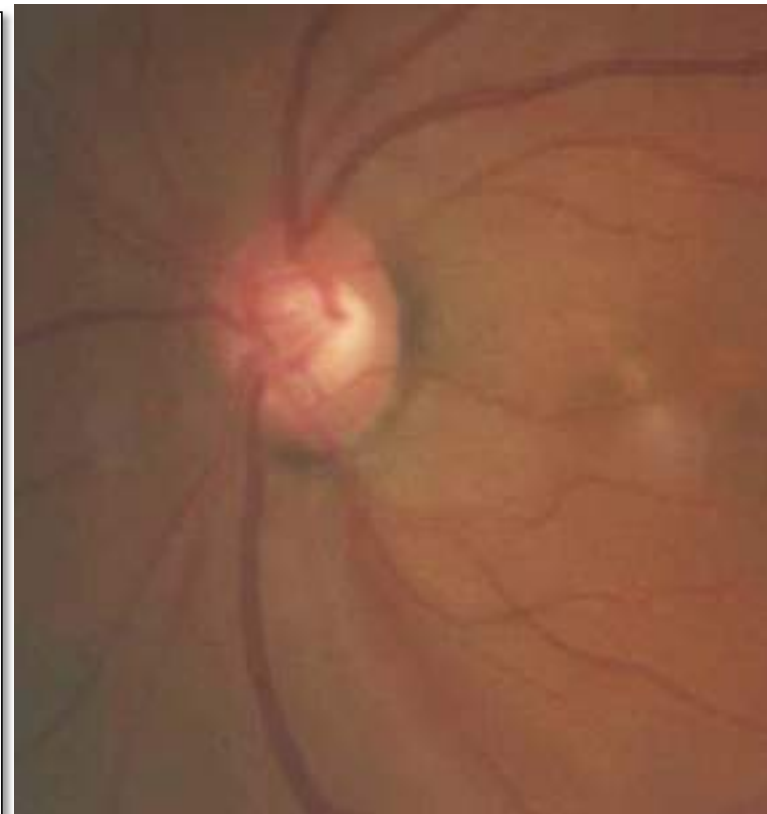
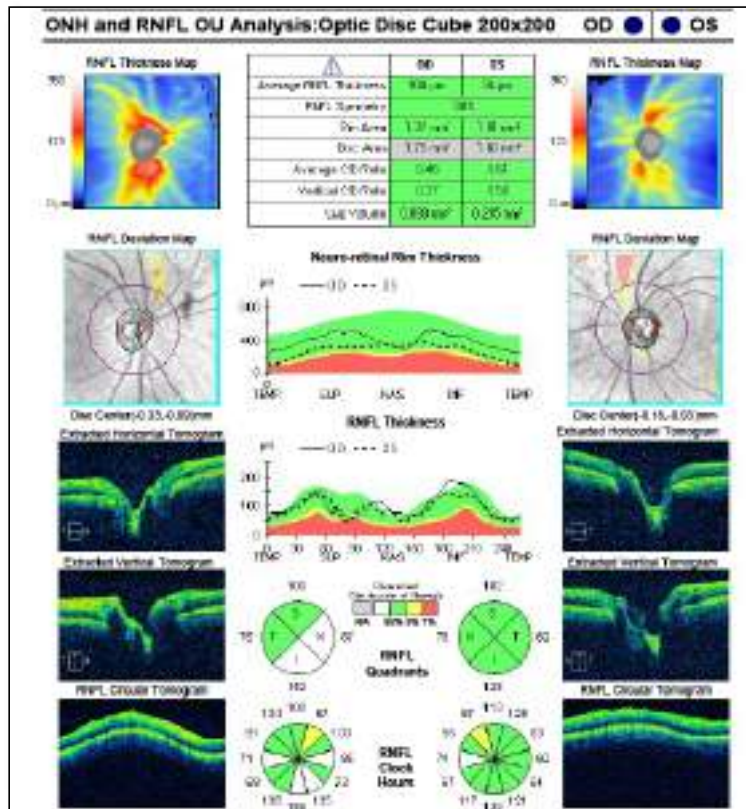
A example of Green Disease



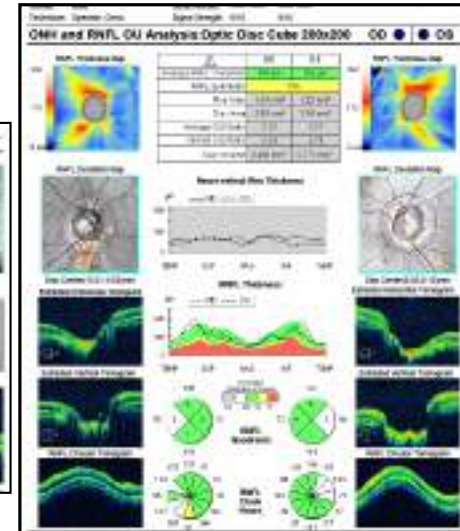
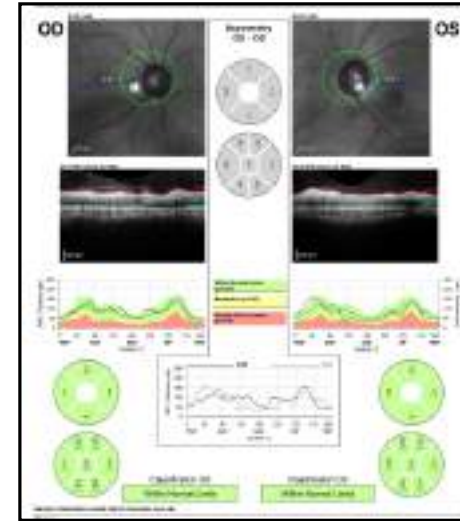
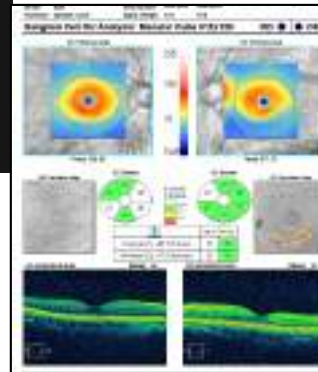
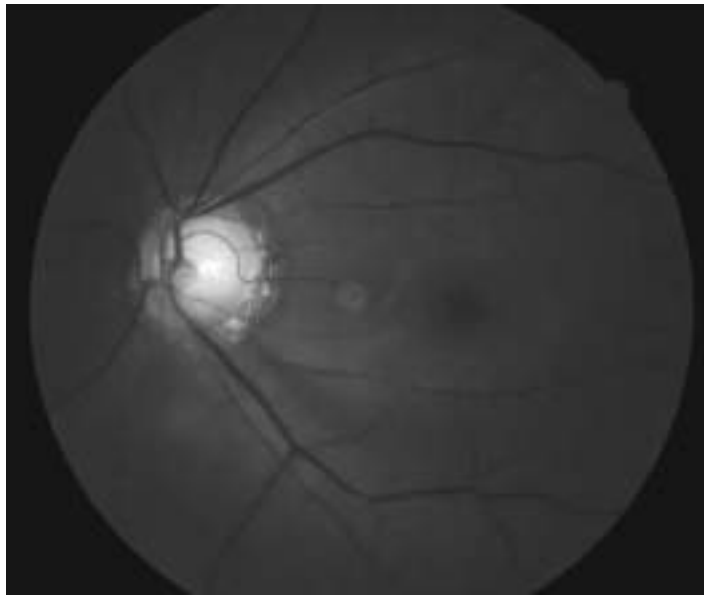
Green Disease



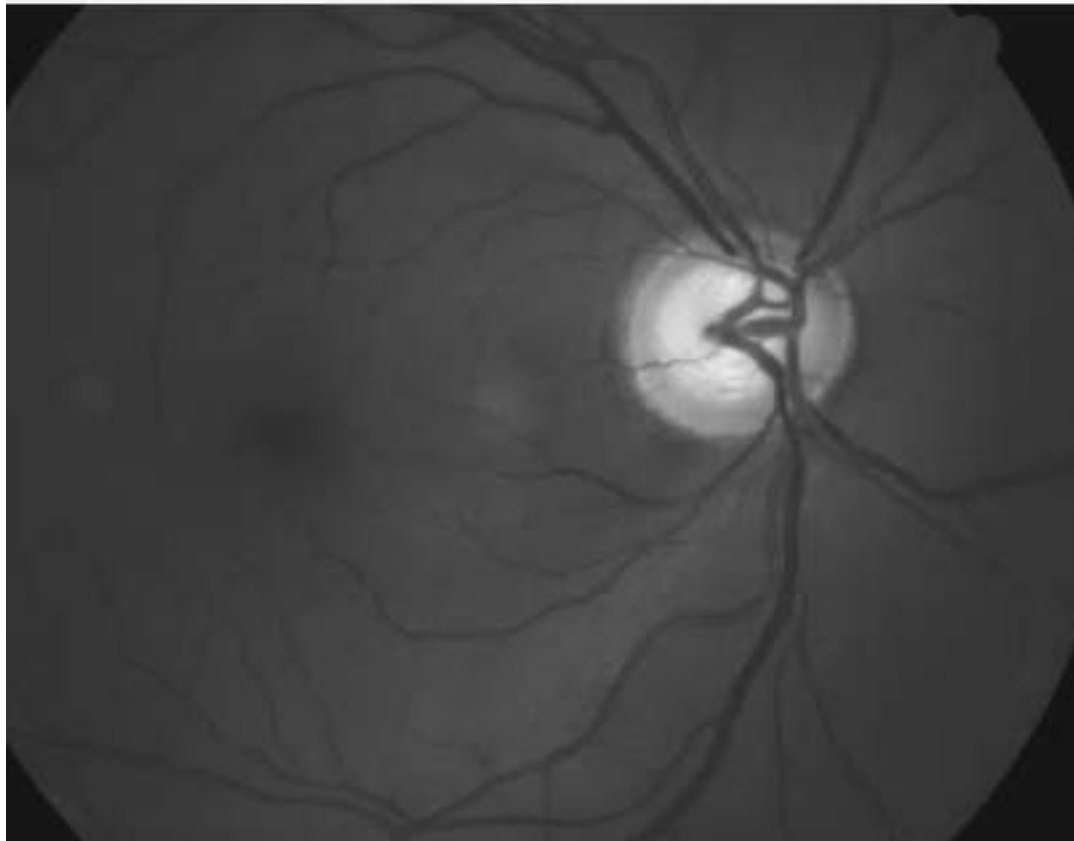
GREEN DISEASE

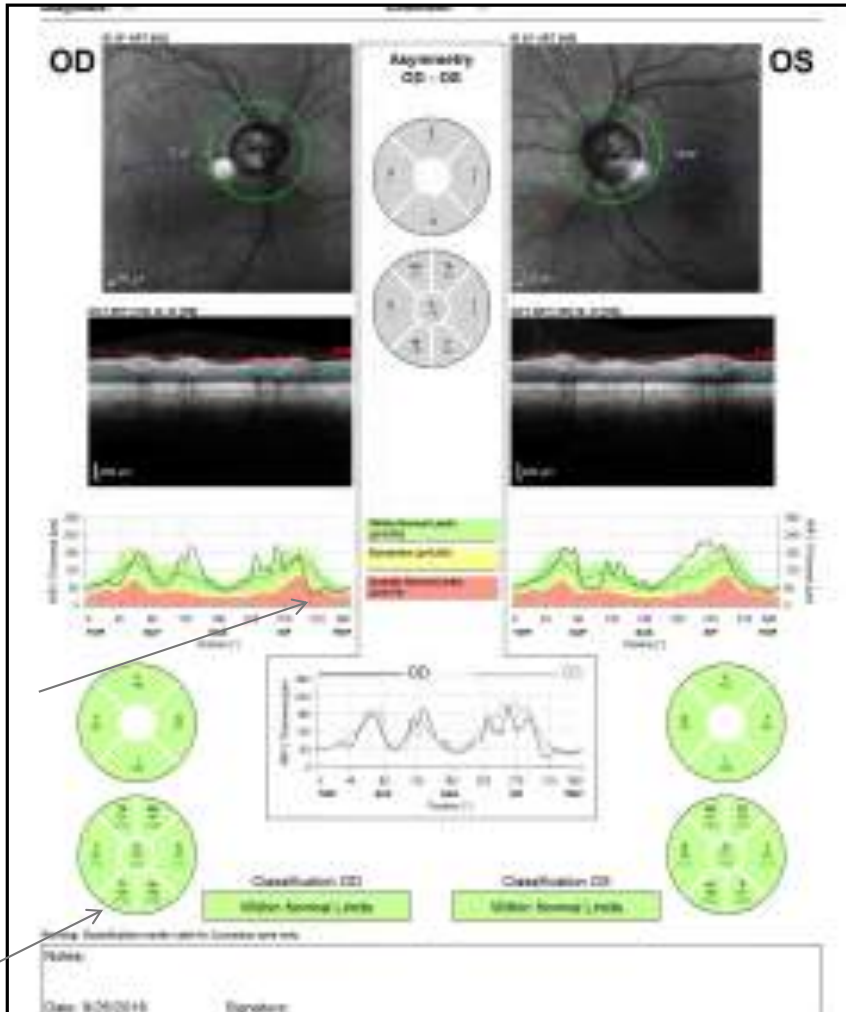


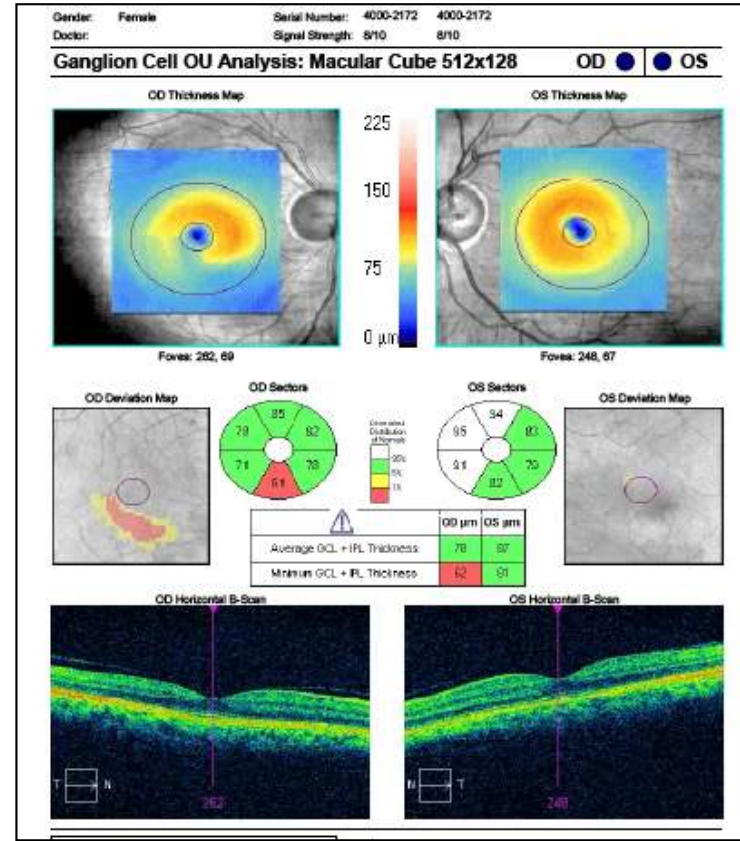
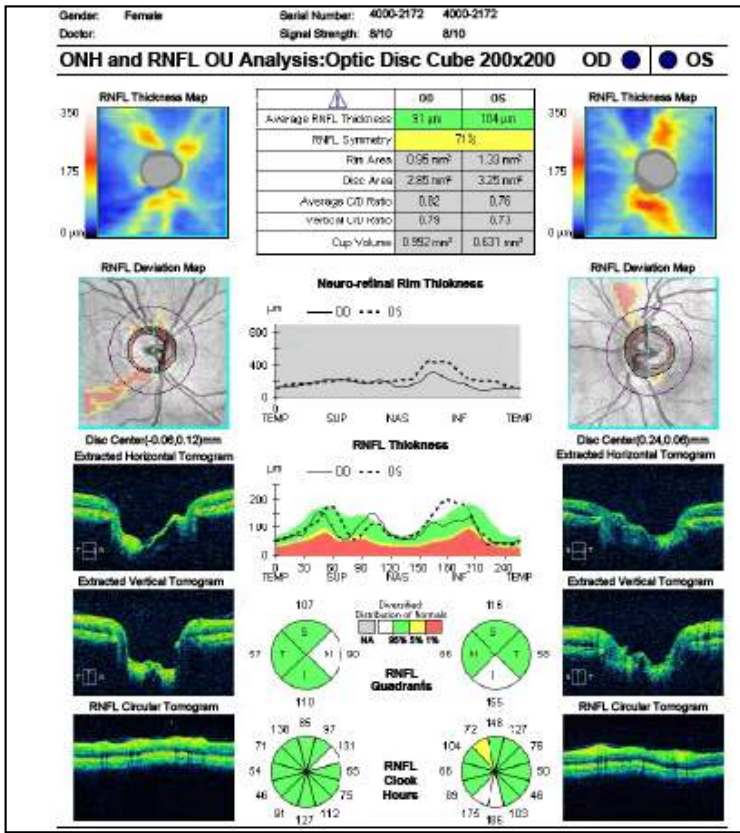
GREEN DISEASE

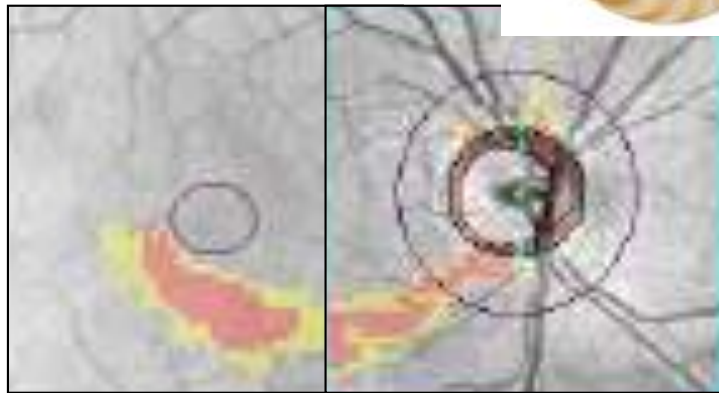
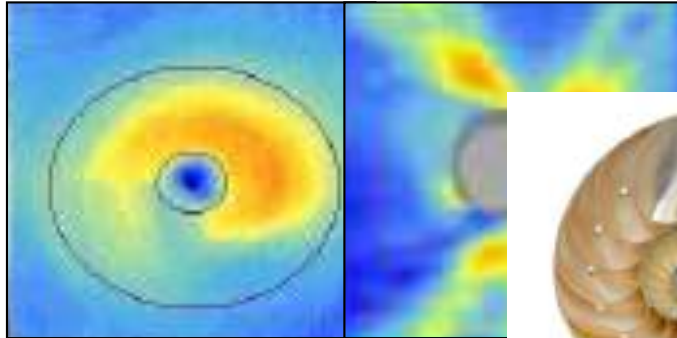


RED + GREEN = BROWN DISEASE?









Thank-You and Hope You Enjoyed

Greg Caldwell, OD, FAAO
Grubod@gmail.com

